

CASE REPORT

Treatment of intestinal Behçet's syndrome with chimeric tumour necrosis factor α antibody

S P L Travis, M Czajkowski, D P B McGovern, R G P Watson, A L Bell

Abstract

Few patients with Behçet's syndrome have gastrointestinal ulceration. Such patients are difficult to treat and have a higher mortality. Faced with refractory symptoms in two patients with intestinal Behçet's, we used the tumour necrosis factor α (TNF- α) monoclonal antibody infliximab to induce remission. Both women (one aged 27 years, the other 30 years) presented with orogenital ulceration, pustular rash, abdominal pain, bloody diarrhoea due to colonic ulceration, weight loss, and synovitis. One had thrombophlebitis, digital vasculitis, perianal fistula, and paracolic abscess; the other had conjunctivitis and an ulcer in the natal cleft. Treatment with prednisolone, methyl prednisolone, and thalidomide in one and prednisolone, colchicine, and cyclosporin in the other was ineffective. After full discussion, infliximab (3 mg/kg, dose reduced because of recent sepsis in one, and 5 mg/kg in the other) was administered. Within 10 days the ulcers healed, with resolution of bloody diarrhoea and all extraintestinal manifestations. A second infusion of infliximab was necessary eight weeks later in one case, followed by sustained (>15 months) remission on low dose thalidomide. Remission was initially sustained for 12 months in the other but thalidomide had to be stopped due to intolerance, and a good response to re-treatment lasted only 12 weeks without immunosuppression, before a third infusion. The cause of Behçet's syndrome is unknown but peripheral blood CD45 $\gamma\delta$ T cells in Behçet's produce >50-fold more TNF- α than controls when stimulated with phorbol myristate acetate and anti-CD3. Infliximab could have a role for inducing remission in Behçet's syndrome.

(Gut 2001;49:725-728)

Keywords: Behçet's syndrome; infliximab

The international criteria for diagnosis of Behçet's syndrome based on an analysis of 914 patients are oral ulceration occurring at least three times in a year, with two of the following: recurrent genital ulcers, skin lesions, eye

lesions, or a positive pathergy test.¹ As there is no accepted laboratory test, the diagnosis remains clinical. Diagnostic dilemmas arise with other mucocutaneous diseases, especially those associated with an arthropathy, such as Crohn's disease, Reiter's, Steven's Johnson syndrome, and conceivably systemic lupus erythematosus. Nevertheless, when a sufficient number and pattern of clinical features can be observed, a definitive diagnosis can reasonably be made in individual patients.²

A small proportion of patients with Behçet's have gastrointestinal ulceration although the prevalence varies according to the specialty of the investigators³ and geography. Gastrointestinal involvement appears to be more common in the easterly portion of the Silk Route (Korea and Japan) than in Europe, or indeed in Japanese emigrants to Hawaii.⁴ Mucosal ulcers can occur at any point along the gastrointestinal tract but typically affect the ileocaecal region, colon, or perineum. These have no specific histological features other than the notable absence of epithelioid granulomas. Korean investigators have classified Behçet's colitis into three types, according to the macroscopic appearance of colonic ulcers: volcano type (well demarcated, penetrating ulcers), geographic (shallow ulcers of variable shape), and aphthoid (shallow, ovoid ulcers).⁵ The type of ulcer may correlate with outcome although patients with Behçet's and any gastrointestinal involvement are more difficult to treat and have a higher mortality.³

Treatment of Behçet's is aimed at modifying the inflammatory response, especially hyper-reactivity of neutrophils and T cell function.⁶ Trials have largely concentrated on ocular inflammation with no controlled trials on the treatment of other manifestations, although relief of oral ulceration has been used as a marker of clinical efficacy.² In practice, patients with systemic features are treated along the lines for ocular disease. This usually includes corticosteroids (up to 1 mg/kg/day), azathioprine,⁷ or cyclosporin.⁸ Other agents include colchicine (for mucocutaneous lesions), mycophenolate, cyclophosphamide, and chlorambucil.⁹ Thalidomide has recently become more

Abbreviations used in this paper: TNF- α , tumour necrosis factor α ; BMI, body mass index; CRP, C reactive protein.

Gastroenterology Unit,
Derriford Hospital,
Plymouth PL6 8DH,
UK

S P L Travis
M Czajkowski
D P B McGovern

Gastroenterology Unit,
Royal Victoria
Hospital and Queen's
University Hospital,
Belfast BT9 7JB, UK
R G P Watson

Musculoskeletal
Education and
Research Unit, Royal
Victoria Hospital and
Queen's University
Hospital, Belfast
BT9 7JB, UK
A L Bell

Correspondence to:
Dr S Travis,
Gastroenterology Unit, John
Radcliffe Hospital, Oxford,
OX3 9DU, UK.
simon.travis@orh.nhs.uk

Accepted for publication
1 May 2001

popular, with 31% of 96 patients in a controlled trial entering remission (of oral ulcers) compared with 0% on placebo ($p=0.001$).¹⁰ Thalidomide is an immunomodulator that inhibits transcription of tumour necrosis factor α (TNF- α).

Faced with refractory symptoms in two patients with Behçet's involving the colon, we used the TNF- α monoclonal antibody infliximab to induce remission.

Case reports

PATIENT NO 1

A 27 year old Caucasian receptionist presented with severe oropharyngeal and genital ulceration, and a pustular rash on the neck, back, and upper limbs in April 1999. She was a non-smoker with no family history of inflammatory bowel disease. Three months later she developed abdominal pain, bloody diarrhoea, 15 kg weight loss, and ankle synovitis. Her C reactive protein (CRP) was 72 mg/l; autoantibodies (including dsDNA) were negative. Barium follow through was normal. Colonoscopy revealed serpiginous and aphthoid ulceration in the hepatic flexure, descending, and sigmoid colon. The rectum was normal. Biopsy of a deeply ulcerated area at the hepatic flexure was reported as possible Crohn's disease without granulomata. In view of the pustular rash and severe orogenital ulceration however a diagnosis of Behçet's was made and she was treated with prednisolone 40 mg daily with modest improvement. Her weight remained unchanged (49 kg, body mass index (BMI) 17 kg/m²) and her CRP decreased to 45 mg/l.

In June 1999, she relapsed with fever, severe abdominal pain, recurrence of large painful oral ulcers, a painful punched out vulval ulcer, and a deep posterior perianal fistula. She also had synovitis of the left knee, right elbow, and several proximal interphalangeal joints, vasculitis of the toes, and superficial thrombophlebitis of each forearm. Her CRP was 70 mg/l. Double contrast barium enema revealed a perforation and abscess formation at a segment of narrowing and mucosal irregularity in the proximal sigmoid colon. The pyrexia settled on parenteral antibiotics and a computed tomography scan confirmed resolution of the abscess. Synovitis and orogenital ulceration did not respond to three pulses of methyl prednisolone (500 mg) and there was limited improvement of abdominal pain, bloody diarrhoea, and oral ulceration on thalidomide 400 mg daily for six weeks.

After discussion with the patient, thalidomide was discontinued and infliximab (3 mg/kg, dose reduced because of recent sepsis) was administered in September 1999. Within 10 days the perianal fistula and genital ulcers healed completely, single formed motions daily replaced frequent episodes of bloody diarrhoea, and appetite and energy levels returned to normal. Synovitis, thrombophlebitis, and the rash resolved completely and weight increased by 3 kg. Six weeks later, abdominal pain and occasional loose stools recurred with a CRP of 29 mg/l despite sustained improvement in weight. Thalidomide was restarted. A second

infusion of infliximab (3 mg/kg) was given in November 1999, eight weeks after the initial dose, with symptomatic improvement. A repeat barium enema showed persistent narrowing and irregularity in the sigmoid colon but no abscess cavity. Areas of ulceration and mucosal irregularity in the transverse colon and hepatic flexure were thought to be more marked than previously. Nevertheless, 12 weeks later CRP was 12 mg/l and was <6 mg/l after six months. Weight returned to normal (56 kg) and digital vasculitis improved slowly. Thalidomide 100 mg daily was continued, with prednisolone 4 mg daily. As of March 2001, she had no complaints, had needed no further infliximab (17 months after the second dose), and was keen to stop the small doses of thalidomide and prednisolone.

PATIENT NO 2

A 30 year old Caucasian bank cashier presented in August 1998 with recurrent oral and vulval ulceration for four years. She then developed a pustular erythematous rash over the trunk and limbs, bilateral ankle synovitis, and conjunctivitis. She was a non-smoker with no family history of inflammatory bowel disease. Antinuclear antigen and antineutrophil cytoplasmic antibody were negative. Behçet's syndrome was diagnosed and treatment with prednisolone 20–40 mg/day relieved the conjunctivitis and synovitis, with a reduction in CRP from 109 to 25 mg/l over eight weeks. Addition of colchicine 0.5–1 mg/day had no effect on orogenital ulceration. In November 1998 she had diarrhoea and rectal bleeding, with recurrence of the rash and arthritis. Her CRP increased to 73 mg/l, weight decreased to 58 kg (BMI 18 kg/m²), haemoglobin declined to 8.6 g/dl, and colonoscopy showed punched out ulcers throughout the colon. Colonic biopsies showed chronic inflammation with focal acute inflammation but no granulomas. Small bowel radiology was normal. In June 1999, arthritis and diarrhoea recurred when prednisolone was reduced to less than 20 mg/day. Cyclosporin up to 300 mg/day (5 mg/kg) was ineffective and symptom control was inadequate on prednisolone up to 60 mg/day. Her CRP remained elevated at 41 mg/l. In September 1999, colonoscopy again showed punched out and linear ulcers throughout the colon, most prominently in the sigmoid colon, but with normal intervening mucosa. Colonic biopsies from the areas of ulceration confirmed a focal chronic inflammatory infiltrate with no granulomas and normal intervening mucosa. A 1.5 cm×0.75 cm ulcer (fig 1) was noted in the natal cleft.

After full discussion with the patient, an infusion of infliximab (5 mg/kg) was administered (December 1999). She experienced myalgia for three days but then noted a dramatic improvement in symptoms. Rectal bleeding stopped and bowel frequency decreased from six to 2–3 times daily. Arthritis and the rash resolved. Anorexia, oral ulcers, and fatigue disappeared. CRP declined from

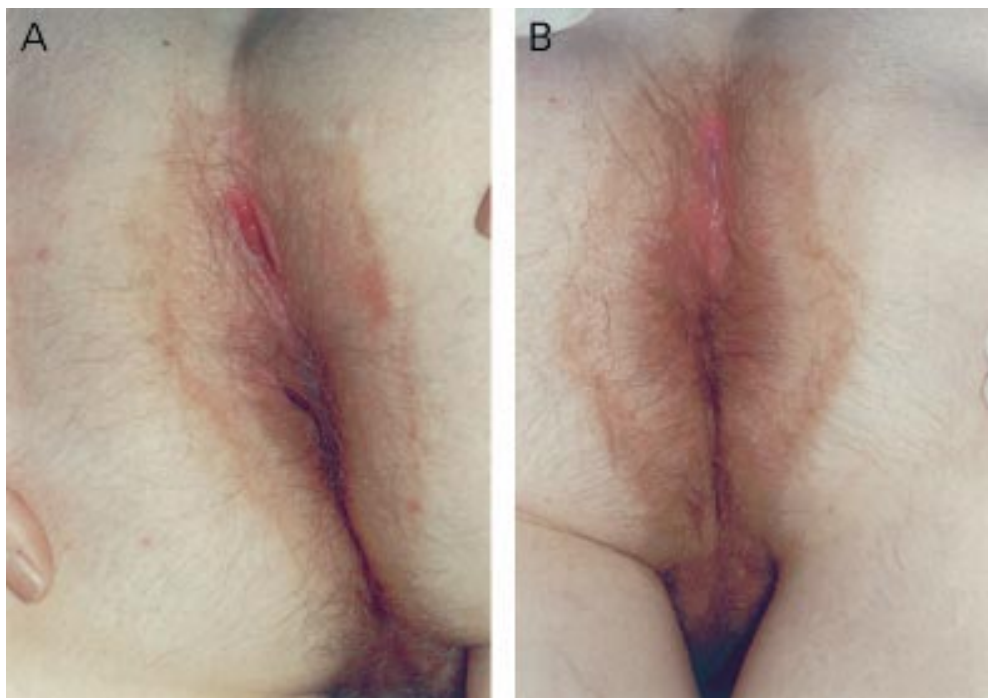


Figure 1 Ulcer in the natal cleft (case No 2) before (A) and three weeks after (B) infusion of infliximab.

53 to <6 mg/l. Three weeks after infusion, flexible sigmoidoscopy showed that the rectosigmoid ulcers had epithelialised and the natal cleft ulcer had healed (fig 1). Thalidomide 300 mg/day was started after normal nerve conduction studies and prednisolone reduced. Steroids were withdrawn over 10 weeks although she experienced dizzy spells, myalgia, and mood disturbance. Diarrhoea, and mouth and genital ulcers did not recur. A short Synacthen test was normal and symptoms resolved when thalidomide was stopped. She became asymptomatic for the first time in five years, on no immunosuppression until October 2000, when synovitis and then diarrhoea gradually recurred, with perianal ulceration, 4 kg weight loss, and fatigue. CRP increased to 36 mg/l. Another infusion of infliximab (5 mg/kg, December 2000) led to resolution of diarrhoea and perianal ulcer, with normal inflammatory markers. No further immunosuppression was introduced, but in March 2001 (12 weeks after the second infusion), diarrhoea, ulceration, and synovitis recurred with a CRP of 63 mg/l. A third infusion of infliximab has been administered with reintroduction of low dose (100 mg/day) thalidomide.

Discussion

The cause of Behçet's syndrome is unknown but a subpopulation of T cells (CD45RA⁺V γ 9⁺V δ 2⁺) expressing the $\gamma\delta$ receptor is increased in Behçet's compared with healthy individuals, irrespective of disease activity. When this subset of T cells is isolated from the peripheral blood of patients with Behçet's and stimulated with phorbol myristate acetate or anti-CD3, they produce extreme amounts of TNF- α (>5000 pg/ml compared with <100 pg/ml by $\gamma\delta$ T cells from normal donors).¹¹ This may account for the response

to infliximab and the modest response of Behçet's to thalidomide which inhibits transcription of TNF- α .¹²

As the efficacy of infliximab in Crohn's disease is well established,¹³ the principal point of interest in these cases is distinction between a diagnosis of Behçet's and Crohn's. The diagnosis of Behçet's was supported in the first case by recurrent genital ulceration, superficial thrombophlebitis, digital vasculitis, and pustular rash, any of which would be exceptionally uncommon in Crohn's. Perforation and fistulation are recognised features of Behçet's colitis which appears to have a worse prognosis than Crohn's disease. A South Korean group compared 140 patients with Crohn's disease and 67 patients with Behçet's.¹⁴ Surgery was more commonly necessary in Behçet's than Crohn's disease (20% at two years and 38% at five years compared with 6% and 26%; $p < 0.01$), with perforation in Behçet's being the most frequent indicator (52% *v* 31%; $p = 0.048$). In the second case, recurrent oral and vulval ulceration, pustular rash, synovitis, and conjunctivitis at presentation were entirely consistent with Behçet's. While extraintestinal manifestations can precede Crohn's disease, the punched out natal cleft ulcer without any perianal disease or fistula would be most atypical. It is of interest that while the more severe (volcano type) ulcers are reported to respond less well to medical treatment and more commonly need surgery,⁵ this case illustrates that all three types of ulceration can coexist in the same patient.

The dramatic response to infliximab in these two patients suggests that further study in Behçet's is warranted. A case of another patient with gastrointestinal Behçet's responding to infliximab has recently been reported but with limited follow up.¹⁵ Both of our patients with

Behçet's responded to retreatment with infliximab but in different ways. The first, who was retreated after only eight weeks, had an extended response while taking low dose thalidomide. The second, who had an extended initial response but reacted adversely to a moderate dose of thalidomide, had a short response to a second dose, possibly because there was no adjuvant immunosuppression. Infliximab may well find a role for inducing remission in Behçet's syndrome while immunosuppression takes effect.

We thank Dr Charles Hutton FRCP for his clinical expertise and support in the management of the second case.

- 1 International Study Group for Behçet's Disease. Criteria for diagnosis of Behçet's disease. *Lancet* 1990;**335**:1078–80.
- 2 Pickering MC, Haskard DO. Behçet's syndrome. *J R Coll Physicians Lond* 2000;**34**:169–77.
- 3 Yurdakul S, Tüzüner N, Yurkudal I, et al. Gastrointestinal involvement in Behçet's syndrome: a controlled study. *Ann Rheum Dis* 1996;**55**:208–10.
- 4 Nakae K, Nasaki F, Hashimoto T, et al. Recent epidemiological features of Behçet's disease in Japan. In: Wechsler B, Godeau P, eds. *Behçet's Disease*. Amsterdam: Excerpta Medica; 1993:94–103.
- 5 Kim JS, Moon H, Choi JJ, et al. Prediction of the clinical course of Behçet's colitis according to macroscopic-type classification by colonoscopy. *Gastroenterology* 2000;**118**:A4480.
- 6 Yamashita N. Hyperreactivity of neutrophils and abnormal T-cell homeostasis: a new insight for pathogenesis of Behçet's disease. *Int Rev Immunol* 1997;**14**:11–20.
- 7 Yazici H, Pazarli H, Barnes CG, et al. A controlled trial of azathioprine in Behçet's syndrome. *N Engl J Med* 1990;**322**:281–5.
- 8 Masuda K, Nakajima A, Urayama A, et al. Double masked trial of cyclosporin versus colchicines and long term open study of cyclosporin in Behçet's disease. *Lancet* 1989;**i**:1093–6.
- 9 Mochizuki M. Immunotherapy for Behçet's disease. *Int Rev Immunol* 1997;**14**:49–66.
- 10 Hamuryudan V, Mat C, Saip S, et al. Thalidomide in the treatment of the mucocutaneous lesions of the Behçet syndrome. *Ann Intern Med* 1998;**128**:443–50.
- 11 Yamashita N, Kaneoka H, Kaneko S, et al. Role of $\gamma\delta$ T lymphocytes in the development of Behçet's disease. *Clin Exp Immunol* 1997;**107**:241–7.
- 12 Tseng S, Pak G, Washenik K, et al. Rediscovering thalidomide: a review of its mechanism of action, side effects and potential uses. *J Am Acad Dermatol* 1996;**35**:969–79.
- 13 Rutgeerts P, D'Haens G, Targan S, et al. Efficacy and safety of re-treatment with anti-tumour necrosis factor antibody (infliximab) to maintain remission in Crohn's disease. *Gastroenterology* 1999;**117**:761–9.
- 14 Jung HC, Choi JJ, Kim YS, et al. Worse prognosis of intestinal Behçet's disease in comparison with Crohn's disease and risk factor evaluation. *Gastroenterology* 2000;**118**:A3027.
- 15 Hassard PV, Binder SW, Nelson V, et al. Anti-tumour necrosis factor monoclonal antibody therapy for gastrointestinal Behçet's disease: a case report. *Gastroenterology* 2001;**120**:995–9.



Have your say

eLetters

If you wish to comment on any article published in *Gut* you can send an eLetter using the eLetters link at the beginning of each article. Your response will be posted on *Gut* online within a few days of receipt (subject to editorial screening).

www.gutjnl.com