

## CASE REPORT

## Unruptured left ventricular pseudoaneurysm following myocardial infarction

M-J Hung, C-H Wang, W-J Cherng

### Abstract

**A 73 year old man developed a left ventricular pseudoaneurysm following acute myocardial infarction. Coronary angiography showed triple vessel disease with total occlusion of the right coronary artery. On left ventriculography, a serpentine-like pseudoaneurysm was demonstrated that originated from the posterobasal wall of the left ventricle and extended to the right ventricular free wall. He underwent coronary artery bypass surgery with no plication of the pseudoaneurysm. An organised thrombus was also found within the cavity of the pseudoaneurysm. He was doing well approximately eight months after the operation. The prognosis might be determined by the organised thrombus, the serpentine-like structure of pseudoaneurysm, the coronary revascularisation, and the vigorous medical management.**

(Heart 1998;80:94-97)

Keywords: acute myocardial infarction; pseudoaneurysm; coronary artery bypass surgery

Left ventricular pseudoaneurysm is a rare complication of acute myocardial infarction. It occurs as a consequence of rupture of the ventricular free wall and is confined by a portion of pericardium. Early surgical intervention is recommended because there is a risk of rupture even with a small pseudoaneurysm.<sup>1</sup> An electrical or mechanical event is usually the final cause of death. We report a patient who survived with pseudoaneurysm eight months following acute myocardial infarction.

### Case report

A 73 year old man was admitted to hospital on 11 January 1997 because of prolonged chest pain of 14 hours. Physical examination revealed a heart rate of 97 beats/min, a respiratory rate of 16 breaths/min, and a blood pressure of 154/106 mm Hg. He had no history of cardiovascular disease. No carotid bruit was heard. Auscultation of the lungs showed rales over the right basal area. There was no murmur, gallop, or friction rub. Other physical findings were unremarkable. Chest radiography was essentially normal. Acute inferior myocardial infarction was diagnosed by typical evolutionary

changes in a 12 lead electrocardiogram and raised creatine kinase (up to 3746 IU/l with MB form of 8.5%). There was no evidence of right ventricular infarction by initial right sided electrocardiogram. Hypotension (blood pressure 85/45 mm Hg) developed two days later and he was managed with aspirin, isosorbide dinitrate, and intravenous dopamine. Transthoracic cross sectional echocardiography (Sonos 2500; Hewlett-Packard, Andover, Massachusetts, USA) was done immediately to detect the possible aetiologies of hypotension. It showed inferior and posterior left ventricular wall hypokinesis and right ventricular free wall akinesis with mild mitral regurgitation. There was no pericardial effusion, intracardiac shunt, or cardiac rupture.

The patient underwent cardiac catheterisation, coronary angiography, and left ventriculography 12 days after admission. Coronary angiography showed triple vessel disease with total occlusion of the right coronary artery. Left ventriculography showed diaphragmatic, posterobasal, apical septal, and posterolateral akinesis with mild mitral regurgitation. Left ventricular ejection fraction was 48%. A pseudoaneurysm was demonstrated, originating from the posterobasal wall of the left ventricle extending to the right ventricular free wall, which was like a serpentine fistulous vessel (fig 1A). Subsequent transthoracic cross sectional echocardiography revealed a portion of pseudoaneurysm on the posterobasal wall of the left ventricle with a flow into the cavity. There was no pericardial effusion (fig 2).

The patient was scheduled to undergo plication of the pseudoaneurysm as well as saphenous vein bypass grafting to the left anterior descending coronary artery, first diagonal branch of left anterior coronary artery, and left circumflex coronary artery, 16 days after admission. A median sternotomy was performed and the pericardium was opened. Extensive myocardial infarction involving the posterolateral wall of left ventricle and diaphragmatic surface of right ventricle was found. There was a 5 × 4 × 3 cm organised clot at the subepicardial region of the posterior wall of the left ventricle. Plication of this posterior pseudoaneurysm was not performed because the surrounding tissues of pseudoaneurysm were all necrotic myocardium. He made a good recovery and was discharged 32 days after

Department of  
Internal Medicine,  
Division of Cardiology,  
Chang Gung Memorial  
Hospital, 222  
Mai-Chin Road,  
Keelung 204, Taiwan  
M-J Hung  
C-H Wang  
W-J Cherng

Correspondence to:  
Dr Hung.

Accepted for publication  
11 February 1998

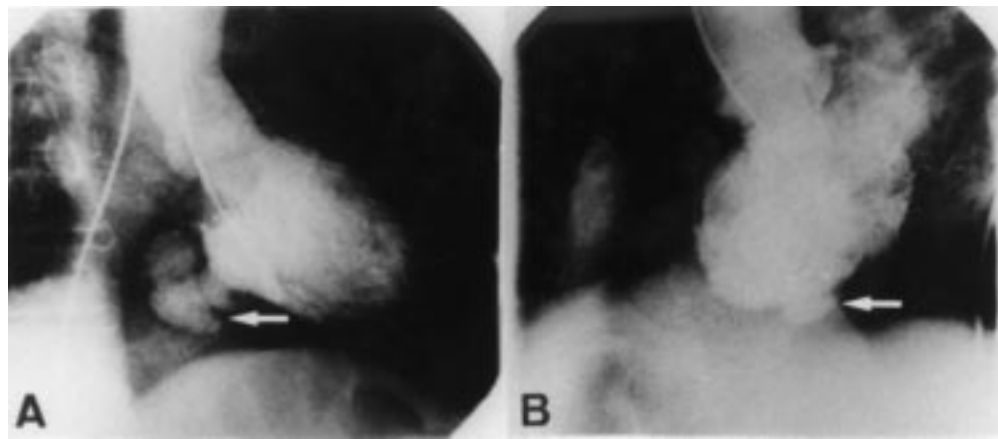


Figure 1 Left ventriculography in the right anterior oblique 30° (A) and left anterior oblique 60° (B) projection. A serpentine-like pseudoaneurysm (arrow) is shown to originate from the left ventricular posterobasal wall and extend to the right ventricular free wall.

admission. He was managed with aspirin, propranolol, furosemide, digitalis, and isosorbide dinitrate during a follow up of eight months.

Transthoracic cross sectional echocardiography on 28 July 1997 showed the same pseudoaneurysm with no obvious change in size (fig 3). Colour Doppler revealed a flow into the cavity. There was no pericardial effusion. The left ventricular ejection fraction was 52%. He was well without any evidence of angina pectoris or heart failure.

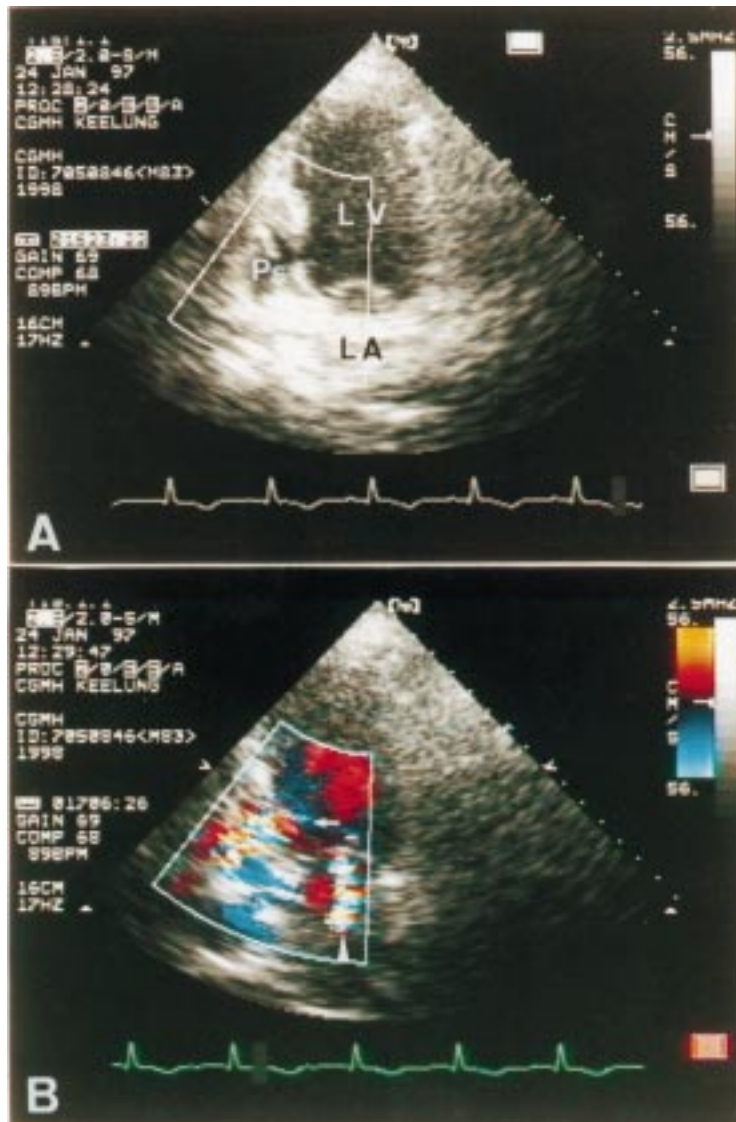


Figure 2 (A) Apical two chamber view of transthoracic cross sectional echocardiography showing an echo free space (pseudoaneurysm) posterior to the left ventricle. (B) Colour Doppler study demonstrating a flow entering the pseudoaneurysm (arrow) and a mitral regurgitant jet (arrowhead). LA, left atrium; LV, left ventricle; Ps, pseudoaneurysm.

### Discussion

Cardiac rupture, including rupture of the interventricular septum, papillary muscle, or left ventricular free wall, constitutes approximately 4–24% of complications following acute myocardial infarction. Ventricular free wall rupture occurs in most cases of cardiac rupture and is usually associated with sudden cardiac death because of haemopericardium and subsequent cardiac tamponade.<sup>2</sup> This catastrophic complication usually occurs within a week of acute myocardial infarction. Most ventricular free wall ruptures develop through the midlateral wall and usually complicate inferoposterolateral infarction related to an occlusion of the left circumflex coronary artery. Associated factors of cardiac rupture following acute myocardial infarction include sixth decade of life or later, female sex, pre-existing systemic hypertension, absence of previous angina pectoris or infarction, first acute transmural infarct, symptoms of pericarditis, repetitive unprovoked emesis with restlessness and agitation, a deviation of the ST segment or T wave, or both, from the usual evolutionary pattern, peak MB creatine kinase  $\geq 150$  IU/l, not having a mural thrombus, lack of coronary artery collateral vessels in the area of infarction, and thrombolytic treatment given more than seven hours after onset of chest pain.<sup>3–5</sup>

Occasionally, cardiac rupture may be confined by a portion of pericardium, leading to pseudoaneurysm formation. A pseudoaneurysm is a rare complication of acute myocardial infarction with unknown prevalence. Diagnosis of pseudoaneurysm used to be established by cardiac catheterisation; however, now it is most commonly detected using cross sectional echocardiography.<sup>1</sup> A narrow neck leading to the fundus is usually found on ventriculography.

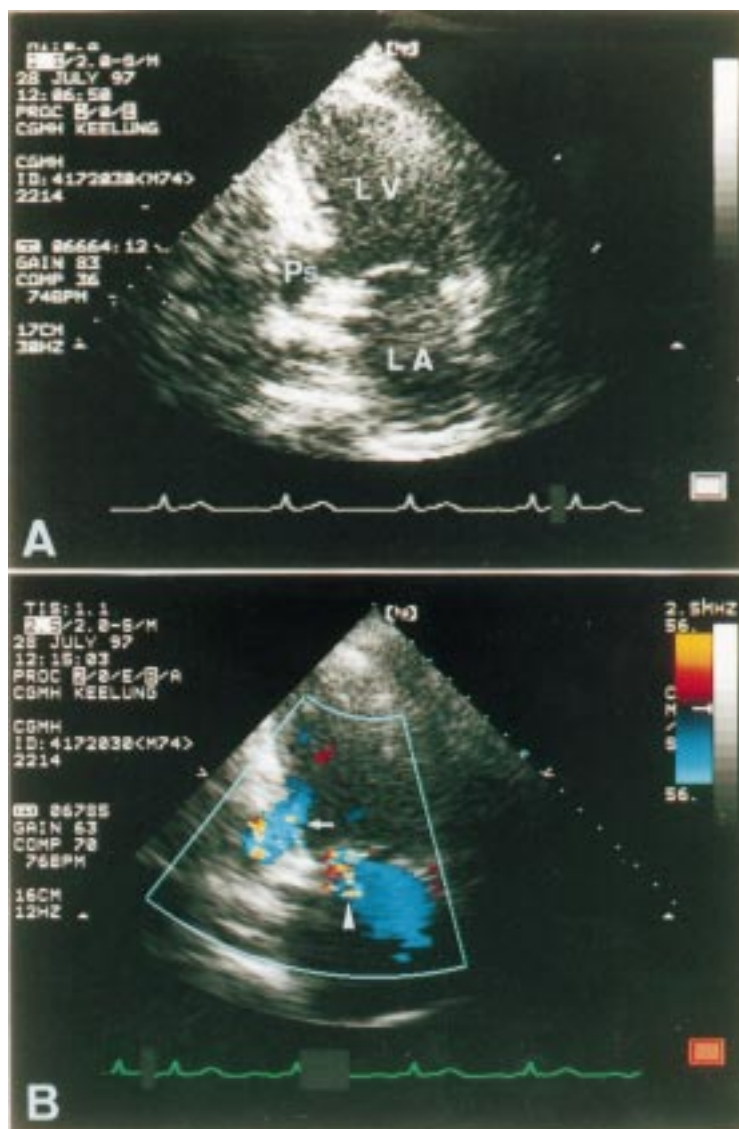


Figure 3 (A) Apical two chamber view of transthoracic cross sectional echocardiography six months after myocardial infarction, showing the pseudoaneurysm posterior to the left ventricle. (B) Colour Doppler study revealing a flow entering the pseudoaneurysm (arrow) and a mitral regurgitant jet (arrowhead). LA, left atrium; LV, left ventricle; Ps, pseudoaneurysm.

In contrast, a wide opening into the ventricular chamber is characteristic of true aneurysm. In addition, there are no coronaries draping the pseudoaneurysm because the wall of the pseudoaneurysm is avascular, unlike true aneurysm. On cross sectional echocardiography, the morphologies are similar to the result of cardiac catheterisation. With the aid of colour Doppler flow, pseudoaneurysm can be confirmed by an unusual continuous flow signal extending from the left ventricular cavity to the aneurysmal cavity through a narrow neck. Unlike true aneurysm, which seldom ruptures, the pseudoaneurysm has a greater tendency to rupture because there are no myocardial cells, but thrombus and pericardium in the walls of a pseudoaneurysm. Most commonly, an arrhythmic or mechanical event is the final cause of death. Therefore, urgent surgery is uniformly indicated when the diagnosis is confirmed by echocardiography or angiography. Sakai *et al* did not recommend surgery if pseudoaneu-

rysm presented with a narrow neck connecting the left ventricle with the pseudoaneurysm, or if it occurred in the presence of postsurgical mitral valve.<sup>6</sup>

Survival of a left ventricular pseudoaneurysm following acute myocardial infarction is rare. Lewis *et al* suggest that the poor prognosis of pseudoaneurysm is attributed to the thin walls of these structures and to the lack of organised haematoma.<sup>7</sup> In 1963, Hurst *et al* reported a patient who survived six years with pseudoaneurysm after acute posterolateral myocardial infarction.<sup>8</sup> The pseudoaneurysm was saccular in shape. Interestingly, in our patient, the pseudoaneurysm was serpentine-like in shape, which is quite uncommon. Bolognesi *et al* reported a 70 year old man with left ventricular pseudoaneurysm who was still alive 12 years after diagnosis. It was not certain if the aetiology was acute myocardial infarction. The patient also had rheumatic fever at age 47 and 56. They suggest that the prolonged survival might be due to the very narrow connection between the left ventricle and the pseudoaneurysm, the progressively deteriorated left ventricular systolic performance, and the formation of a large thrombus inside the pseudoaneurysm, which attenuated the strength of left ventricular systolic contraction.<sup>9</sup>

In our patient, the serpentine-like pseudoaneurysm was demonstrated on left ventriculography. The serpentine-like structure was not seen by cross sectional echocardiography because of the limited access to the posterior ventricular wall. However, echocardiography can yield information on anatomy and flow characteristics. Furthermore, cross sectional echocardiography is an excellent tool in following the unruptured pseudoaneurysm. The survival of our patient might be because of the formation of an organised thrombus and the serpentine-like structure that decreased left ventricular pressure to the distal walls of the pseudoaneurysm. In addition, the preserved left ventricular systolic performance after coronary artery bypass surgery and pharmacological management might play an important role. The role of coronary revascularisation in improving the survival of free wall rupture is unclear. There are reports of long term survivors following repair of ventricular rupture and coronary revascularisation.<sup>10</sup> From this limited experience, we suggest that vigorous medical treatment and coronary artery bypass surgery to reduce ventricular remodeling might be helpful in patients with a pseudoaneurysm formation without plication following acute myocardial infarction.

- 1 Catherwood E, Mintz GS, Kotler MN, *et al*. Two-dimensional echocardiographic recognition of left ventricular pseudoaneurysm. *Circulation* 1980;62:294-303.
- 2 Bates RJ, Beutler S, Resnekov L, *et al*. Cardiac rupture-challenge in diagnosis and management. *Am J Cardiol* 1977;40:429-37.
- 3 Pohjola-Sintonen S, Muller JE, Stone PH, *et al*. MILIS study group. Ventricular septal and free wall rupture complicating acute myocardial infarction: experience in the multicenter investigation of limitation of infarct size. *Am Heart J* 1989;117:809-18.
- 4 Honan MB, Harrell FE, Reimer KA, *et al*. Cardiac rupture, mortality and timing of thrombolytic therapy: a meta-analysis. *J Am Coll Cardiol* 1990;16:359-67.
- 5 Oliva PB, Hammill SC, Edwards WD. Cardiac rupture, a clinically predictable complication of acute myocardial



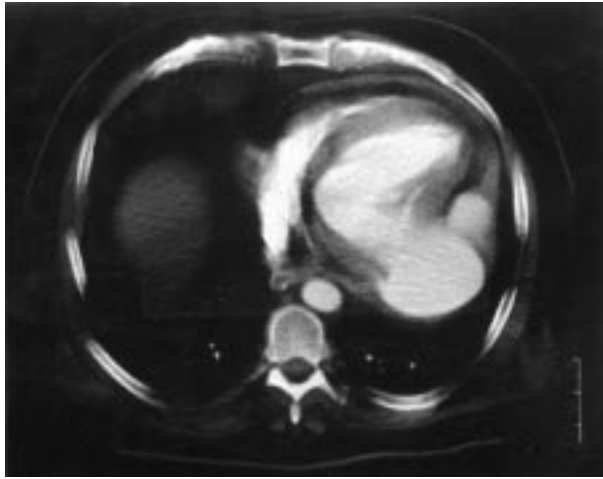
- infarction: report of 70 cases with clinicopathologic correlations. *J Am Coll Cardiol* 1993;22:720-6.
- 6 Sakai K, Nakamura K, Ishizuka N, *et al*. Echocardiographic findings and clinical features of left ventricular pseudoaneurysm after mitral valve replacement. *Am Heart J* 1992;124:975-82.
  - 7 Lewis AJ, Burchell HB, Titus JL, *et al*. Clinical and pathological features of postinfarction cardiac rupture. *Am J Cardiol* 1969;23:43-53.
  - 8 Hurst CO, Fine G, Keyes JW. Pseudoaneurysm of the heart. Report of a case and review of literature. *Circulation* 1963; 28:427-36.
  - 9 Bolognesi R, Cucchini F, Lettieri C, *et al*. Left ventricular false aneurysm: an unusually prolonged natural history. *Cathet Cardiovasc Diag* 1995;36:46-50.
  - 10 Pifarré R, Sullivan HJ, Grieco J, *et al*. Management of left ventricular rupture complicating myocardial infarction. *J Thorac Cardiovasc Surg* 1983;86:441-3.

---

## IMAGES IN CARDIOLOGY

---

### Ruptured ventricular pseudoaneurysm



A 66 year old man presented to the emergency room of a community hospital with a 12 hour history of severe retrosternal pain. The ECG showed ST-T segment elevation in the inferior leads. Assuming acute inferior myocardial infarction, systemic thrombolytic treatment with rt-PA was given. Following thrombolysis left sided hemiparesis was noted. A computed tomography (CT) scan of the brain showed no signs of cerebral haemorrhage. To exclude aortic dissection CT imaging was extended to the thoracic region. Surprisingly, these images (top left) revealed posterior ventricular rupture. At that time the patient was haemodynamically stable. He was transferred to our hospital for emergency repair; unfortunately, he deteriorated rapidly and surgery could not be performed. A ruptured posterior ventricular aneurysm and pericardial tamponade was demonstrated by echocardiography (lower left; LV, left ventricle; PSA, pseudoaneurysm). The patient died in electromechanical dissociation. Postmortem examination showed a pseudoaneurysm of the posterior wall with a large parietal thrombus and rupture into the pericardial space (lower right). The brain section showed no haemorrhage or infarction.

