

CASE REPORT

Brugada syndrome associated with an autonomic disorder

M Nomura, T Nada, J Endo, Y Kondo, M Yukinaka, K Saito, S Ito, H Mori, Y Nakaya, H Shinomiya

Second Department of Internal Medicine, School of Medicine, University of Tokushima, 2-50 Kuramoto-cho, Tokushima 770-8503, Japan

M Nomura
T Nada
J Endo
Y Kondo
M Yukinaka
K Saito
S Ito
H Mori

Department of Nutrition, School of Medicine, University of Tokushima, Y Nakaya

Muskat Naika Clinic, 11-53 Yokosu-cho, Komatsushima, Tokushima 773-0006, Japan
H Shinomiya

Correspondence to: Dr Nomura.

Accepted for publication 5 January 1998

Abstract

A 44 year old man with Brugada syndrome and ventricular fibrillation had an autonomic disorder, shown by spectral analysis of heart rate variability and ^{123}I -MIBG myocardial scintigraphy. Periodic variation of the ST segments was detected by Holter ECG. Increased high frequency power (0.15–0.40 Hz), an index of para-sympathetic nerve activity, was observed just before ST segment elevation. In addition, local dysfunction of sympathetic nerves in the left ventricle was detected by ^{123}I -MIBG myocardial scintigraphy. Unbalanced autonomic nerve function plays an important role in inducing Brugada-type ECG signs.

(Heart 1998;80:194–196)

Keywords: Brugada syndrome; autonomic disorder; ^{123}I -MIBG myocardial scintigraphy

As one of the causes of idiopathic ventricular fibrillation, Brugada and colleagues¹ reported some remarkable electrocardiographic (ECG) observations on eight patients with prodromes of sudden death, such as repeated syncopal attack. These characteristic findings consisted of right bundle branch block, a severely elevated ST segment in the right side chest leads (V1 and V2), and a normal QT interval. Usually, these electrocardiographic findings vary within a short period of time. It is clear that autonomic nerves are involved in these

variabilities, and vagal tone is thought to play an important role.^{2,3}

Recently, we encountered a patient with Brugada syndrome, which was accompanied by ventricular fibrillation. Autonomic imbalance was suspected in this patient, based on the results of spectral analysis of heart rate variability and ^{123}I -MIBG myocardial scintigraphy.

Case report

The patient was a 44 year old man. Incomplete right bundle branch block was detected on an ECG several years ago. In June 1995, at 20:00, the patient suddenly lost consciousness while watching television. He spontaneously recovered one minute later, but lost consciousness again at 22:00. The patient was referred to our hospital for further examination and treatment.

When admitted, the patient was completely conscious. He was 174 cm tall and weighed 70 kg. His nutritional status appeared normal. On examination, his pulse rate was 55 beats/min and regular, and his blood pressure was 116/66 mm Hg. Physical examination revealed no pallor, jaundice, or cyanosis. There was no abnormality in the thoracoabdominal area or any neurological abnormality.

No abnormality was detected on haematological or biochemical examinations and no increase in blood creatine kinase was observed. Chest radiography indicated no abnormality, and the cardiothoracic ratio was 41%. An ECG showed normal sinus rhythm and normal axis with an incomplete right bundle branch block (fig 1). In addition, an elevation of the ST segment on chest leads was observed, especially in the V1–3 leads. The late potential was positive on the signal averaged electrocardiogram (root mean square amplitude of the terminal 40 ms was 5 μV ; duration of the terminal QRS below 40 μV was 54 ms; duration of the filtered QRS was 118 ms). On a ventricular activation time map of the body surface ECG, ventricular excitation was delayed between the middle and upper precordium.

A Holter ECG revealed only seven premature atrial contractions in 24 hours, but no ventricular arrhythmias. Ventricular fibrillation was not induced during a treadmill exercise test. Cardiac catheterisation revealed no abnor-

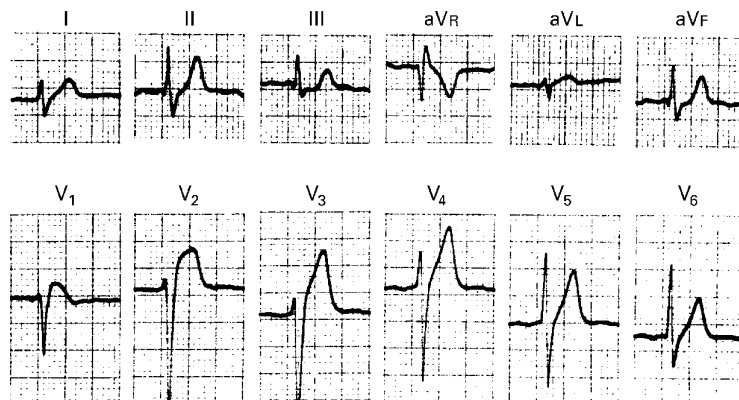


Figure 1 Standard 12 lead ECG on admission.

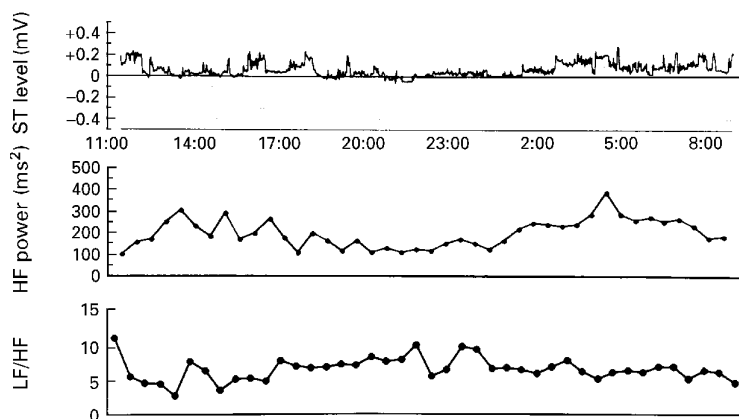


Figure 2 ST trendogram of Holter ECG and high frequency power obtained by analysis of spectral heart rate variability. ST segment elevation was observed in ST trendogram at 16:00 and 15:00 to 16:00. Before elevation of the ST segment, an increase in high frequency power, an index of parasympathetic nerve tension, was observed.

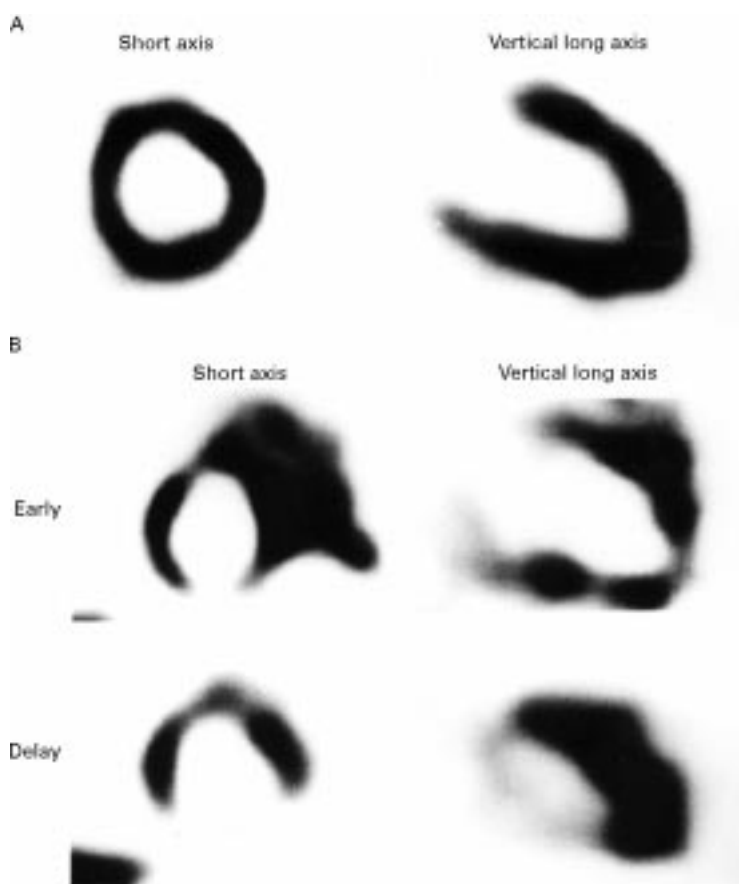


Figure 3 Myocardial scintigram using ^{99m}Tc -MIBI (A) or ^{123}I -MIBG (B). In ^{99m}Tc -MIBI myocardial scintigraphy, no abnormality was observed in myocardial blood flow; however, during early imaging of myocardial scintigraphy using ^{123}I -MIBG, a decreased accumulation or an unequal distribution of ^{123}I -MIBG was observed in part of the inferior wall, the apex, and anterior wall of the left ventricle; while in delay imaging, an increased wash out of ^{123}I -MIBG was observed in the inferior wall.

malinity in the right or left coronary arteries, and ventricular fibrillation was not induced during electrophysiological examinations. However, ventricular fibrillation occurred just after removal of the electrode catheters from the femoral vein, and the patient recovered sinus rhythm by cardioversion.

Figure 2 shows the ST trendogram of the Holter ECG and the high frequency power (0.15–0.40 Hz) obtained spectral heart rate

variability. Periodic variation of the ST segments on the trendogram could be detected in this patient by Holter ECG. Increased high frequency power, an index of parasympathetic nerve activity, was observed just before ST segment elevation. In addition, the low frequency:high frequency ratio was decreased with increases in high frequency power, suggesting a close relation between the elevated ST segment and increased parasympathetic nerve function.

Figure 3 shows the myocardial scintigraphy using ^{99m}Tc -MIBI and ^{123}I -MIBG. A decreased accumulation of isotopes was not observed on myocardial scintigraphy using ^{99m}Tc -MIBI (fig 3A); however, a decrease in the accumulation or an unequal distribution of ^{123}I -MIBG was observed in the inferior wall, apex, and anterior wall of the left ventricle (fig 3B). Moreover, on delay imaging, an increased washout of ^{123}I -MIBG was detected in the inferior wall.

Discussion

One of the causes of idiopathic ventricular fibrillation—a right bundle branch block accompanied by an elevated ST segment in the right side chest leads—has been reported by a number of investigators.^{1–5} This electrocardiographic syndrome has been described as Brugada syndrome as it was originally described in detail by Brugada *et al.*¹ As this syndrome is related to sudden cardiac death, a pronounced variation on ECG can be observed over a short period of time in the same patient. Although the cause of these variations in ECG findings in patients with Brugada syndrome remain unknown, it has gradually become clear that autonomic nerves play an important role.^{1–3}

The functional participation of autonomic nerves in the formation of Brugada-type ECG has been evaluated by investigating the effects of various autonomic drugs on ECG in patients with Brugada syndrome. Morace and colleagues⁴ investigated the effects of isoprenaline on the ECG and reported that the ST segment elevation disappears under sympathicotonic conditions. Furthermore, Miyazaki *et al* reported that ST segment elevation is decreased by administering isoprenaline or acetylcholine, while it was increased with propranolol or prazosin.⁵ They also examined the effects of autonomic drugs and antiarrhythmic drugs on the elevation of the ST segment and reported that dysfunction of the autonomic nerves is an important modulator, but not the primary disorder.⁵ They concluded that the ST segment elevation seen in patients with Brugada syndrome is caused by localised abnormal depolarisation or abnormal early repolarisation.⁵

Spectral heart rate variability in the Holter ECG of our patient revealed an increased high frequency power and a decreased low frequency:high frequency ratio before the ST segment elevation, suggesting a close relation between the ST segment elevation and sthenic vagotonia. It has been reported that unbalanced conductivity throughout the heart plays an important role in the occurrence of idiopathic ventricular fibrillation.^{6–9} As many ventricular

vagus nerves are distributed in the lower posterior walls of the ventricles, an imbalance in ventricular conductivity is thought to be induced by excitation of parasympathetic nerves.

Furthermore, ^{123}I -MIBG is an analogue of noradrenaline, and it is stored and excreted at the sympathetic nerve termini. ^{123}I -MIBG reflects the local activity of sympathetic nerves in the left ventricle.¹⁰ ^{123}I -MIBG scintigraphy of this patient revealed a partial decrease in the accumulation of and an increased washout of ^{123}I -MIBG, suggesting local dysfunction of sympathetic nerves in the left ventricle.

We speculate that the dysfunction of the sympathetic nerves observed in myocardial scintigraphy using ^{123}I -MIBG, in addition to the unbalanced parasympathetic nerves detected by Holter ECG, further increased the imbalance in ventricular conductivity, resulting in ventricular fibrillation. This is consistent with the hypothesis that unbalanced autonomic nerve function plays an important role in inducing Brugada-type ECG.

- 1 Brugada P, Brugada J. Right bundle branch block, persistent ST segment elevation and sudden cardiac death: a distinct clinical and electrocardiographic syndrome. *J Am Coll Cardiol* 1992;20:1391-6.
- 2 Sumiyoshi M, Nakata Y, Hisaoka T, et al. A case of idiopathic ventricular fibrillation with incomplete right bundle branch block and persistent ST segment elevation. *Jpn Heart J* 1993;34:661-6.
- 3 Bjerregaard P, Gussak I, Kotar SL, et al. Recurrent syncope in a patient with prominent J wave. *Am Heart J* 1994;127:1426-30.
- 4 Morace G, Padeletti L, Porciani MC, et al. Effect of isoproterenol on the "early repolarization" syndrome. *Am Heart J* 1979;97:343-7.
- 5 Miyazaki T, Mitamura H, Miyoshi S, et al. Autonomic and antiarrhythmic drug modulation of ST segment elevation in patients with Brugada syndrome. *J Am Coll Cardiol* 1996;27:1061-70.
- 6 Schwartz PJ, Snebold NG, Brown AM. Effects of unilateral cardiac sympathetic denervation threshold. *Am J Cardiol* 1976;37:1034-40.
- 7 Brooks WW, Verrier RL, Lown B. Influence of vagal tone on stellotomy-induced changes in ventricular electrical stability. *Am J Physiol* 1978;234:H503-7.
- 8 Schwartz PJ, Stone HL. Left stellotomy in the prevention of ventricular fibrillation caused by acute myocardial ischemia in conscious dogs with anterior myocardial infarction. *Circulation* 1980;62:1256-65.
- 9 Elharrar V, Watanabe AM, Molello J, et al. Adrenergically mediated ventricular fibrillation in probucol-treated dogs: roles of alpha and beta adrenergic receptors. *Pacing Clin Electrophysiol* 1979;2:435-43.
- 10 Wieland DM, Wu J, Brown LE, et al. Radiolabeled adrenergic neuron-blocking agents: adrenomedullary imaging with ^{123}I iodobenzylguanidine. *J Nucl Med* 1980;21:349-53.