

Decreased amplitude of left ventricular posterior wall motion with notch movement to determine the left posterior septal accessory pathway in Wolff-Parkinson-White syndrome

K Hina, T Murakami, S Kusachi, R Hirami, S Matano, N Ohnishi, K Iwasaki, T Kita, N Sakakibara, T Tsuji

Abstract

Objective—To determine preoperatively, by analysing asynchronous left ventricular wall motion, whether to approach through the right ventricle or the left ventricle when carrying out catheter ablation of the accessory pathway in Wolff-Parkinson-White syndrome, especially in patients with the pathway located on the septum.

Methods—73 patients with manifest Wolff-Parkinson-White syndrome who underwent successful catheter ablation were studied. Location of accessory pathway was classified as *right ventricular side*: right anterior paraseptum, right anterior, right lateral, right posterior, anterior septum, midseptum, right posterior septum; *left ventricular side*: left posterior septum, left posterior, left lateral, left anterior. Asynchronous systolic wall motion was analysed by cross sectional echocardiography.

Results—Echocardiography showed that the amplitude of left ventricular posterior systolic wall motion was reduced when the pathway was located on the left ventricular side as opposed to the right ventricular side (mean (SD), 11.1 (1.7) v 12.9 (1.1) mm, $p < 0.001$), especially in patients with left posterior septal accessory pathway (9.7 (0.8) mm). There were no overlapping values between the left posterior septal accessory pathway and the right ventricular side accessory pathway. Posterior wall notch motion was observed in all patients with a left posterior septal accessory pathway (9/9), but not at all in patients with pathways located on the right ventricular side of the septum. In patients with a septal accessory pathway, an ECG algorithm provided poor information (relatively low sensitivity, specificity, and predictive value) for determining whether the subsite faced either the left (left posterior septum) or the right ventricle (anterior septum, midseptum, right posterior septum).

Conclusions—Decreased amplitude of left ventricular posterior wall motion with notch movement is an important finding for accessory pathways located on the left posterior septum. These findings provided clinically useful information for deter-

mining whether to approach catheter ablation from the right or the left ventricle.

(Heart 1999;82:731-739)

Keywords: echocardiography; catheter ablation; pre-excitation; asynchronous wall motion; Wolff-Parkinson-White syndrome

Radiofrequency catheter ablation with high frequency current has been established in recent years as curative treatment for patients with Wolff-Parkinson-White (WPW) syndrome refractory to medical treatment.^{1,2} Estimating the location of the accessory pathway before the procedure is helpful for catheter mapping to determine the precise ablation site and for shortening the time required for ablation.

Several non-invasive methods of estimating the location of the accessory pathway have been proposed. Delta wave polarity or QRS polarity on a 12 lead ECG has been widely used to determine accessory pathway location.³⁻⁹ Although recent ECG criteria have provided a good level of sensitivity, specificity, and predictive value for determining accessory sites located on the right ventricular or left ventricular free wall or on the septum,^{6,7} these criteria provide poor information about the sublocation of septal pathways facing the right or left ventricle. To our knowledge, there are no previous reports describing useful non-invasive methods of determining the sublocation of such pathways.

M mode echocardiography has also been used.^{10,11} These studies classified patients into type A and type B WPW syndrome, based on conventional 12 lead ECG, but did not examine the relation of echocardiographic findings to the precise accessory pathway location. Therefore these reports did not provide sufficient information for precise sublocation of the accessory pathway.¹² Recently, more complicated methods, such as phase analysis of echocardiographic images^{13,14} and radionuclide ventriculography,¹⁵ have been employed to detect the accessory site. These methods have focused mainly on pre-excitation ventricular motion through the accessory pathway, but the diagnostic criteria are complicated and the accuracy of the methods is limited.

It can be hypothesised that when electric currents through the normal and accessory

Cardiovascular Center,
Sakakibara Hospital,
Okayama, Japan

K Hina
R Hirami
S Matano
N Ohnishi
K Iwasaki
T Kita
N Sakakibara

First Department of
Internal Medicine,
Okayama University
Medical School, 2-5-1,
Shikata-cho, Okayama
700-8558, Japan
T Murakami
S Kusachi
T Tsuji

Correspondence to:
Dr Kusachi.
email: zqbkytmm@
oka.urban.ne.jp

Accepted for publication
21 June 1999

pathways reach the left ventricular wall with close timing, asynchronous systolic left ventricular wall motion occurs. It is also reasonable to assume that the location and degree of asynchronous wall motion depends on the accessory site. Although there are some reports examining pre-excitation wall motion in patients with WPW syndrome,^{10–12} there have not been any studies analysing asynchronous systolic left ventricular wall motion in connection with the precise location of the accessory pathway. Accordingly, we studied asynchronous systolic left ventricular wall motion using cross sectional echocardiography to determine accessory pathway location, concentrating particularly on septal sublocation—that is, whether the pathway is on the right or the left ventricular side.

Methods

PATIENTS

Cross sectional echocardiograms were recorded in 82 consecutive patients with manifest WPW syndrome who underwent successful catheter ablation. Of the 82 patients, nine were excluded from analysis because the quality of echocardiographic recordings was insufficient for analysis in six, or because association with other types of heart diseases affected ventricular wall motion in three (Ebstein's anomaly (1), post-surgical ablation (1), left bundle branch block (1)). Thus in all, 73 patients were studied, 51 male and 22 female, ranging in age from 13 to 87 years (mean (SD), 43 (18) years). QRS width on the 12 lead ECG was ≥ 0.12 s in 65 patients and < 0.12 s in eight. One patient (a 22 year old man) with a right posteroseptal accessory pathway associated with complete left bundle branch block was also studied.

ECHOCARDIOGRAPHY

Cross sectional echocardiography was recorded two days before and one day after catheter ablation, using standard equipment (Toshiba SSH-160A, Tokyo, Japan). Measurements were performed on routine long axis view¹² by two cardiologists who were not aware of the clinical and electrophysiological findings in the patients. After the correct scanning position was determined in B mode scanning, M mode echocardiography was recorded at a paper speed of 50 mm/s for 10 continuous beats and the mean value for these beats was used for analysis.

RADIOFREQUENCY CATHETER ABLATION

Radiofrequency catheter ablation was performed according to the established method.^{1–2} In the case of a right sided accessory pathway, a right atrial approach was attempted. In a patient with a left sided accessory pathway, a transaortic left ventricular approach was attempted. Ablation for a posteroseptal accessory pathway was performed using a power of 20–30 W for 30–60 seconds by the regular transvenous or transaortic approach, using techniques similar to those applied for free wall accessory pathway ablation.¹⁶

ACCESSORY PATHWAY LOCATION

The location of the accessory pathway was identified by endocardial catheter mapping and finally confirmed as the site was cut by catheter ablation. The location was classified into 11 distinct locations as follows: *right ventricular side*—right anterior paraseptum, right anterior, right lateral, right posterior, anteroseptum, midseptum, right posterior septum; *left ventricular side*—left posterior septum, left posterior, left lateral, left anterior.

ASYNCHRONOUS WALL MOTION INDICES

Notch movement and amplitude of systolic posterior wall motion, paradoxical septal motion, and notch movement and amplitude of systolic interventricular wall motion were defined as asynchronous systolic wall motion indices. To confirm these findings, we compared the findings before and after catheter ablation.

PRE-EXCITATION WALL MOTION INDICES

Early septal wall motion and early posterior wall motion occurring simultaneously with a delta wave on the 12 lead ECG were defined as pre-excitation wall motion indices.^{10–12}

ECG ALGORITHM

Using the Oklahoma ECG algorithm⁶ and the St George's ECG algorithm,⁷ the location of the accessory pathway was estimated by three cardiologists who were not aware of the clinical and electrophysiological findings in the patients examined.

STATISTICAL ANALYSIS

Differences in data between the two groups were analysed by Student's *t* test. Analysis of variance with Bonferoni's *t* test was used for comparison of more than three groups. Data are expressed as the mean (SD). A probability (*p*) value of < 0.05 was regarded as significant.

Results

ASYNCHRONOUS SYSTOLIC WALL MOTION INDICES

Left ventricular posterior wall motion was less when the site was located on the left ventricular side than on the right ventricular side (11.1 (1.7) *v* 12.9 (1.1) mm, $p < 0.001$) (fig 1). In particular, posterior wall motion was reduced (9.7 (0.8) mm) when the accessory pathway was located on the left posterior septum. There were no overlapping values between a left posterior septal accessory pathway and a right ventricular side accessory pathway. Furthermore, the difference in amplitude of posterior wall motion between the left posterior septal and right posterior septal pathways (13.3 (1.1) mm) was notable.

ECG, radiofrequency catheter position, and M mode echocardiography tracings in a patient with a left posterior septal accessory pathway and in a patient with a right posterior septal pathway are shown in figs 2 and 3, respectively. A notch in the posterior wall systolic motion was observed all nine patients with a left posterior septal accessory pathway (fig 2, table 1), while this was not found when the pathways were located on the right ventricular side of the

septum (fig 3, table 1). Reduced wall motion in association with pathways located on the left ventricular side returned to the normal range after successful ablation, confirming that the reduced motion was caused by the accessory pathway before ablation.

Because two patients showed paradoxical septal motion, these were excluded from the analysis of notch movement in septal motion. The notch in the septal systolic motion was thus examined in 16 of the 18 patients with a right ventricular free wall accessory pathway and found to be present in 15 (94%). A notch was not observed in patients with a left ventricular free wall or left posterior septal

accessory pathway and was detected in only four of 11 patients (36%) with an accessory pathway located on the right ventricular side of the septum—that is, anterior septum, midseptum, or right posterior septum (table 1). Paradoxical septal motion was found in only two patients with a right anterior paraseptal accessory pathway. When a notch in either septal systolic motion or paradoxical septal motion was found, the accessory pathway was located on the right ventricular side. However, the incidence was low and the sensitivity was thus insufficient.

There were no significant differences in the amplitude of septal motion between right and

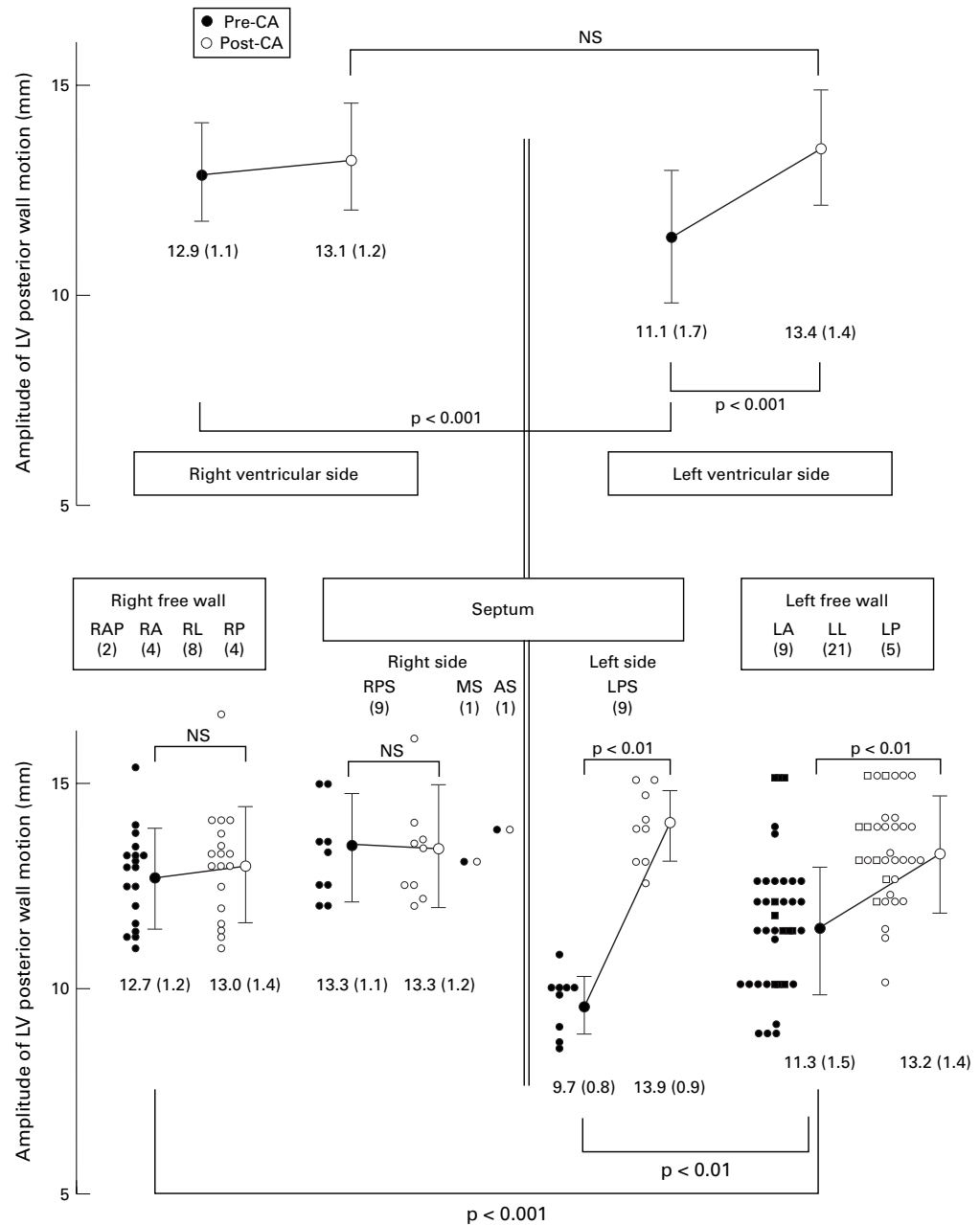


Figure 1 Amplitude of left ventricular posterior wall motion and accessory pathway location before and after successful catheter ablation. Empty and filled circles indicate the amplitude of posterior wall motion before and after catheter ablation, respectively, in patients with a QRS duration of ≥ 0.12 s. Empty and filled squares indicate the amplitude of posterior wall motion before and after catheter ablation, respectively, in patients with a QRS duration of < 0.12 s. Numbers in parentheses indicate the numbers of patients. AS, anteroseptum; CA, catheter ablation; LA, left anterior free wall; LL, left lateral free wall; LP, left posterior free wall; LPS, left posterior septum; LV, left ventricle; MS, midseptum; RA, right anterior; RAP, right anterior paraseptum; RL, right lateral; RP, right posterior, RPS, right posterior septum.

left ventricular sided accessory pathways, and the amplitude did not change after ablation. In one additional patient with a right posterior septal accessory pathway combined with left bundle branch block, the amplitude of left ventricular wall systolic motion was definitely decreased (9.3 mm), which was dramatically improved after ablation (16.7 mm) (fig 4).

PRE-EXCITATION WALL MOTION INDICES

Although early (pre-excitation) septal motion was observed in 15 of the 18 patients with a right ventricular free wall accessory pathway, it was found in only two of 11 patients with a right ventricular side septal accessory pathway (table 1). Conversely, early (pre-excitation) left ventricular posterior wall motion was found in only three of 35 patients with a left ventricular

free wall accessory pathway and not in patients with a left posterior septal accessory pathway.

ECG DIAGNOSTIC CRITERIA

The Oklahoma ECG algorithm provided better information on accessory pathway location than St George's ECG algorithm. In patients with $QRS \geq 0.12$ s, the Oklahoma ECG algorithm showed over 86% accuracy, specificity, and sensitivity for determining accessory pathway location among three sites (right or left ventricular free wall, septum; table 2). When the accessory pathway was located on the septum, the ECG algorithm provided insufficient information for determining sublocation—that is, anterior septum, midseptum, right posterior septum, or left posterior septum. When the septal accessory pathway

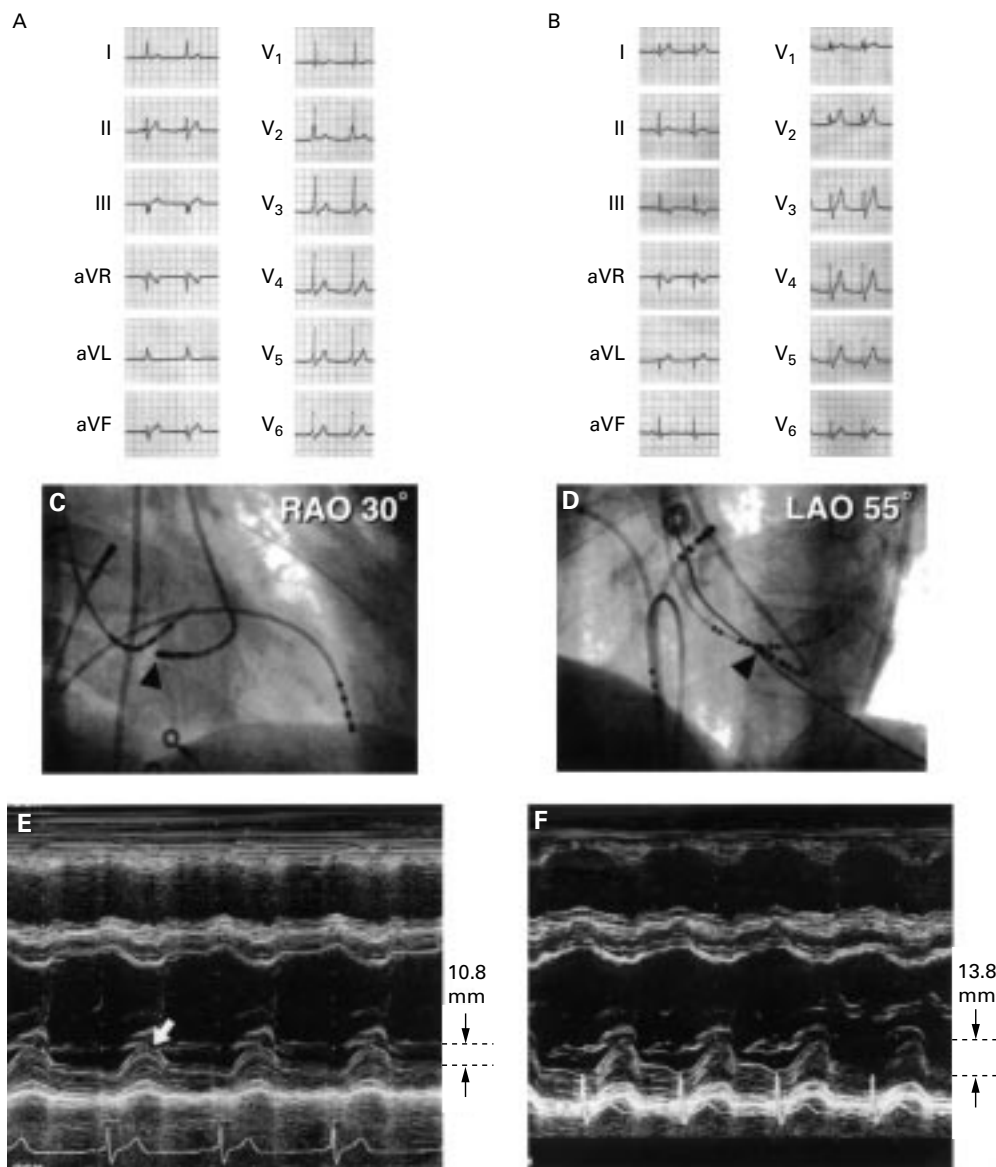


Figure 2 A patient with left posterior septal accessory pathway. (A) and (B), ECG recording before and after ablation. On the basis of the Oklahoma ECG algorithm, all three cardiologists assessed the location to be left posterior septum; on the basis of the St George's algorithm, the location was left posterior. (C) Right anterior view and (D) left anterior view: catheter position (indicated by arrowheads) for radiofrequency ablation. The catheter was positioned at the left posterior of the septum. (E) and (F): M mode echocardiography tracings before and after the ablation. Notch movement of the left ventricular posterior wall systolic motion can be seen in (E) (arrow) but the notch is not seen in (F). Reduced left ventricular posterior wall systolic wall motion (10.8 mm) can be seen before ablation. After ablation, the systolic motion was normalised (13.8 mm).

was divided into left and right ventricular side, the Oklahoma algorithm showed substantially lower sensitivity, specificity, and positive predictive value (table 2). The St George's ECG algorithm provided even lower diagnostic values than the Oklahoma algorithm.

Discussion

This short study is the first to demonstrate that reduced left ventricular posterior wall motion is helpful in localising the accessory site and showing whether ablation should be approached through the right or the left ventricle. Reduced left ventricular posterior wall motion with notch movement was a particularly important finding in relation to accessory pathways located on the left posterior septum.

ACCESSORY PATHWAY LOCATION

We determined accessory pathway location by endocardial ECG mapping and confirmed the site where the pathway was successfully cut by catheter ablation. Dhala *et al* reported that 47 of 50 patients with a posteroseptal accessory pathway (94%) were successfully ablated through a right atrial approach.¹⁷ In these patients, ECG and electrophysiological findings suggested that the pathway was located on the left ventricular side in some patients, indicating that a septal accessory pathway situated on the left ventricular could be ablated through a right atrial approach. Therefore, a question arises as to whether our patients with a right posterior septal accessory pathway included some with a left posterior septal accessory

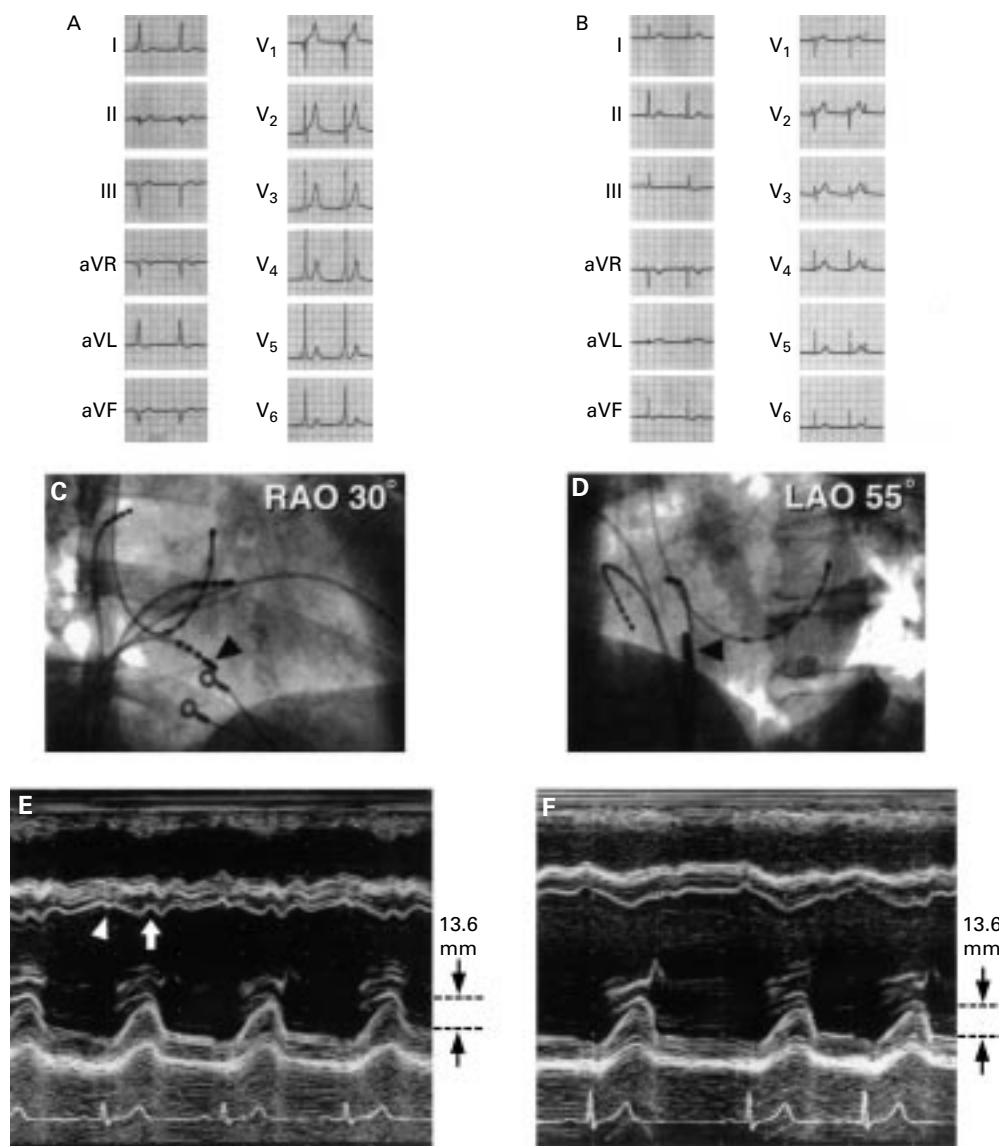


Figure 3 A patient with right posterior septal accessory pathway. (A) and (B): ECG recording before and after ablation. On the basis of the Oklahoma ECG algorithm, all three cardiologists assessed the location to be left posterior septum; on the basis of the St George's algorithm, one of the three assessed the location to be left posterior septum. (C) Right anterior view, and (D) left anterior view: catheter position (arrowheads) for radiofrequency ablation. Catheter was positioned at the right posterior septum. (E) and (F): M mode echocardiography tracings before and after ablation. Notch movement of the left ventricular posterior systolic motion cannot be seen in (D) and amplitude of left ventricular systolic motion was within the normal range. Pre-excitation wall motion—that is, early systolic movement (indicated by an arrowhead) and notch in the systolic septal motion (indicated by an arrow)—were observed in (E). Reduced posterior systolic wall motion cannot be seen. (F) After ablation, left ventricular systolic motion was unchanged.

Table 1 Wall motion abnormalities and accessory pathway location

	Ablation approach ventricle							Left ventricular side			
	Right ventricular side										
	Right free wall				Septal side			Left free wall			
Accessory pathway location	RAP	RA	RL	RP	AS	MS	RPS	LPS	LP	LL	LA
Number of patients:											
Total	2	4	8	4	1	1	9	9	5	21	9
QRS \geq 0.12 s	2	4	8	4	1	1	9	9	4	18	5
QRS < 0.12 s	0	0	0	0	0	0	0	0	1	3	4
<i>Pre-excitation wall motion indices</i>											
Early septal motion	2	3	7	3	0	0	2	0	0	0	0
Early posterior wall motion	0	0	0	0	0	0	0	0	1	2	0
<i>Asynchronous systolic wall motion indices</i>											
Paradoxical septal motion	2	0	0	0	0	0	0	0	0	0	0
Notch in septal motion	/	4	7	4	0	0	4	0	0	0	0
Notch in posterior wall motion	0	0	0	0	0	0	0	9	3	10	5

AS, anteroseptum; LA, left anterior free wall; LL, left lateral free wall; LP, left posterior free wall; LPS, left posterior septum; LV, left ventricle; MS, midseptum; RA, right anterior; RAP, right anterior paraseptum; RL, right lateral; RP, right posterior; RPS, right posteroseptum.

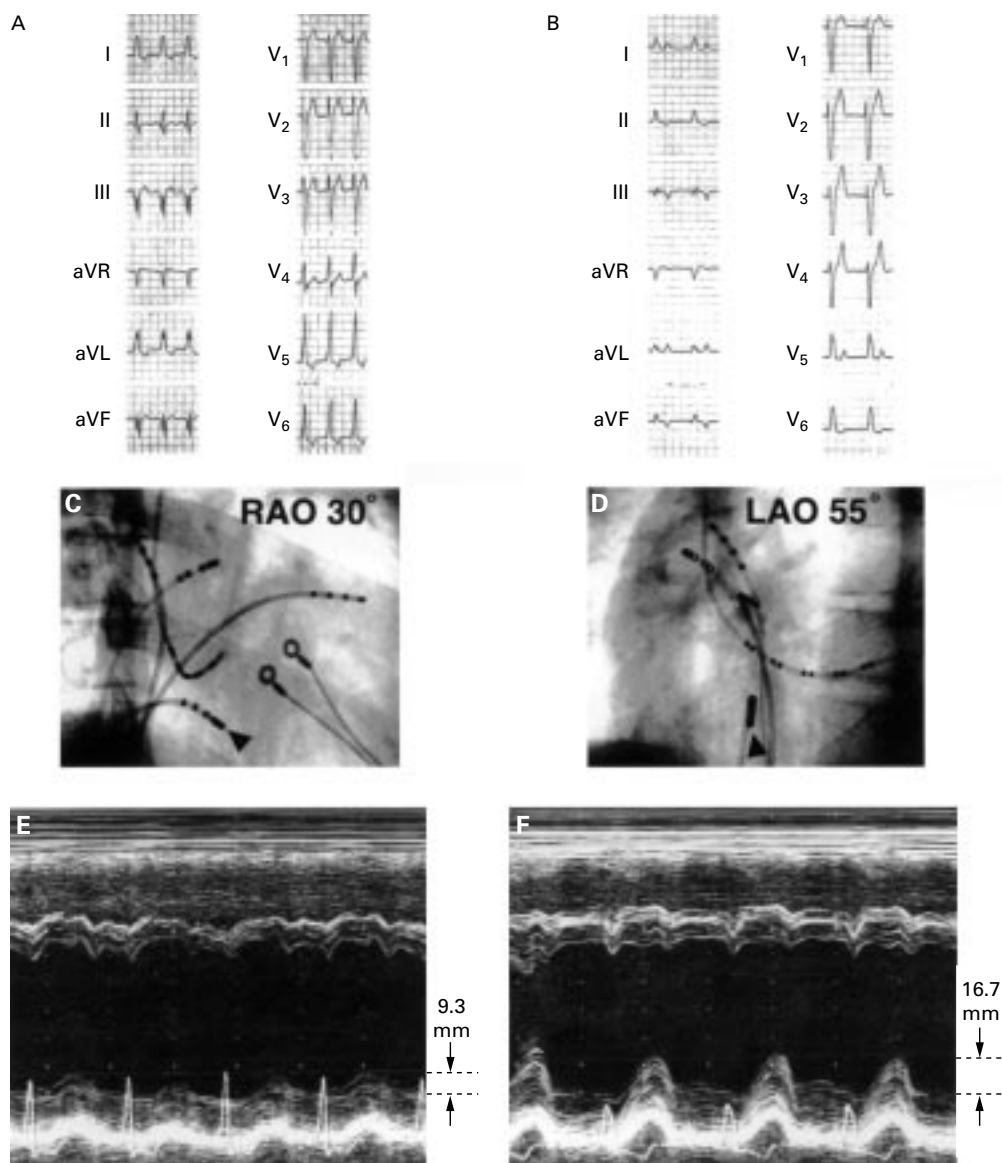


Figure 4 A patient with right posterior septal accessory pathway and complete left bundle branch block. (A) and (B): ECG recording before and after ablation. Left bundle branch block was observed after successful catheter ablation. (C) (right anterior view) and (D) (left anterior view): Catheter position (indicated by arrowheads) for radio frequency ablation. The catheter was positioned at the right posterior of the septum. (E) and (F): Tracings of M mode echocardiography before and after ablation. Paradoxical septal motion and markedly reduced left ventricular posterior wall systolic motion (9.3 mm) can be seen before ablation in (E). Improvement of left ventricular posterior wall systolic motion (16.7 mm) was observed after successful ablation in (F).

Table 2 Sensitivity, specificity, and predictive values of ECG algorithms for estimation of pathway site

Ablation approach ventricle										
Right ventricle							Left ventricle			
Right ventricular free wall				Septum			Left ventricular free wall			
RAP (n = 2)	RA (n = 4)	RL (n = 8)	RP (n = 4)	AS (n = 1)	MS (n = 1)	RPS (n = 9)	LPS (n = 9)	LP (n = 5)	LL (n = 21)	LA (n = 9)
Oklahoma ECG algorithm										
Sensitivity (%)							87 (86)		89 (100)	
Specificity (%)							93 (98)		100 (100)	
Predictive value (%)							76 (92)		100 (100)	
							AS + MS + RPS			
Sensitivity (%)							89 (89)		44 (44)	
Specificity (%)							91 (94)		95 (98)	
Predictive value (%)							62 (73)		57 (80)	
St George's ECG algorithm										
Sensitivity (%)							83 (90)		83 (90)	
Specificity (%)							94 (93)		94 (97)	
Predictive value (%)							94 (96)		94 (96)	
							AS + MS + RPS			
Sensitivity (%)							100 (100)		11 (11)	
Specificity (%)							84 (82)		94 (93)	
Predictive value (%)							44 (44)		20 (20)	

Values in parentheses are the data in patients with QRS ≥ 0.12 seconds. AS, antero-septum; LA, left anterior free wall; LL, left lateral free wall; LP, left posterior free wall; LPS, left posterior septum; LV, left ventricle; MS, midseptum; RA, right anterior; RAP, right anterior paraseptum; RL, right lateral; RP, right posterior; RPS, right posteroseptum.

pathway. This is, however, unlikely in our series. Dhala *et al* delivered radiofrequency energy at the terminal portion of the coronary sinus including the ostium, whereas we did not deliver ablative energy at the coronary sinus in any patient. Further, they delivered high energy (on average 47 W) for ablation and reported a high recurrence rate. In contrast, we delivered low radiofrequency energy (20–30 W) by the right atrial approach in patients with right posterior septal accessory pathway determined by the present method and did not find recurrence in any case. These results strongly indicate that our patients with a right posterior septal accessory pathway did not incorrectly include any patients with a left posterior septal accessory pathway.

ECG ALGORITHM

In 1945, Rosenbaum *et al* initially classified the ECG findings in patients with WPW syndrome into type A and type B.³ For catheter ablation, this classification is too rough and cannot be used to estimate the accessory pathway location precisely. Recently, five major ECG algorithms have been proposed for the detection of the accessory pathway: the Milstein,⁵ Oklahoma,⁶ Skeberis, St George's,⁷ and Fitzpatrick⁸ algorithms. The Milstein and Skeberis algorithms did not separate accessory pathways located on the posterior septum into those facing the right or left ventricular side, so the present results could not be compared. Although the St George's algorithm has been reported to be superior for estimating the precise location of the pathway and showed high predictability for septal sublocation,⁷ the report included only a small number of patients with an accessory pathway located on the septum, especially a left posterior septal accessory pathway. In our study, both Oklahoma and St George's ECG algorithms showed a limited ability to estimate the sublocation of septal accessory pathways (table 2). Although ECG algorithms are widely used to determine the

accessory site location and provide much information with high accuracy, specificity, and sensitivity for determining sites located on the right or left ventricular free wall or septum, nevertheless in determining the sublocation of accessory sites located in the septum—that is, discriminating anterior septum, midseptum, right posterior septum or left posterior septum—our results indicated that the ECG algorithm did not provide sufficient information. The reason for misclassification of a left posterior septal accessory pathway by the Oklahoma algorithm was difficulty in determining the polarity of the delta wave in the aVF lead in certain cases. The St George's algorithm uses the polarity of the QRS complex and this is easier to determine than a delta wave. Right ventricular free wall accessory pathways were, however, often misclassified as right posterior septal accessory pathways using the St George's algorithm. Thus the ECG algorithm is limited in determining the sublocation of the septal accessory pathway.

ECHOCARDIOGRAPHY

There have been some echocardiographic studies in patients with WPW syndrome.^{10, 11} Most of these classified patients into type A or type B and mainly analysed the pre-excitation septal or left ventricular posterior wall motion. Their results were consistent with the present results of pre-excitation indices and did not provide sufficient information for estimating the precise accessory pathway location. Regarding the amplitude of left ventricular posterior wall motion, only Francis *et al* reported no differences between patients with type A WPW syndrome and controls.¹¹ They used single beam echocardiography and did not compare the amplitude of posterior wall motion in patients with a left ventricular side accessory pathway with that in patients with a right ventricular side accessory pathway. The possibility that their type A WPW patients included patients with right ventricular side accessory

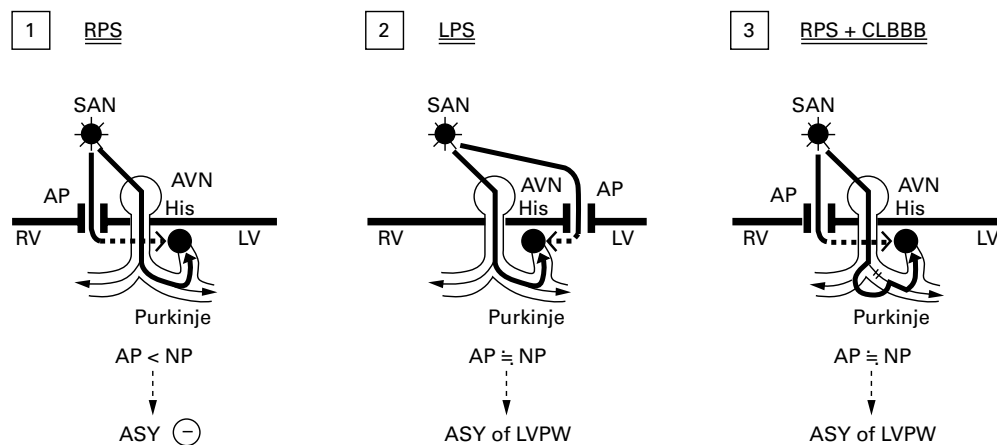


Figure 5 Speculation on the mechanism causing asynchronous left ventricular posterior wall systolic motion. (1) RPS, accessory pathway located in the right posterior septum. Electric current by the accessory pathway (AP) does not reach left ventricular wall during the systolic phase, resulting in the absence of asynchronous (ASY) left ventricular wall motion. (2) LPS, accessory pathway located in the left posterior septum. Electric current by the accessory pathway reaches the left ventricular wall in close timing with that by normal pathway (NP) during the systolic phase, resulting in asynchronous left ventricular wall systolic motion. (3) RPS + CLBBB, right posterior septum accessory pathway with complete left bundle branch block. Because of delayed conduction through the normal pathway owing to complete left bundle branch block, electric current by the right posterior septal pathway reaches the left ventricular wall in close timing with that by the normal pathway, resulting in asynchronous left ventricular wall motion. AVN, atrioventricular node; His, His bundle; LPS, left posterior septal accessory pathway; LV, left ventricle; LVPW, left ventricular posterior wall; RPS, right posterior septal accessory pathway; RV, right ventricle; SAN, sinoatrial node.

pathway cannot be excluded. The lack of sensitivity and accuracy of their method and their patient classification could account for their non-significant findings in relation to left ventricular posterior wall motion.

Hishida *et al*,¹⁰ using M mode echocardiography, found notch movement in left ventricular posterior wall motion or early posterior motion in all type A patients. In the present study, left ventricular posterior wall notch movement was found in approximately half the patients with a left ventricular side accessory pathway. The present results, together with those of Hishida *et al*,¹⁰ indicate that some but not all patients with a left ventricular side accessory pathway show notch movement in left ventricular posterior systolic wall motion. Further comparison of the present study with their results could not be made because they also classified patients with WPW syndrome into only two groups, type A and B.

More recently, phase analysis with atrial pacing¹³ or adenosine infusion¹⁴ has been reported. We attempted to identify sequential posterior wall motion movements but the findings were not statistically significant. Detection limitations of time related analysis of the conventional cross sectional echocardiographic analysis used in this study could account for non-significant results of phasic posterior analysis. Reports of phasic analysis described abnormal phasic pre-excitation wall motion where the accessory pathway was located, and the accuracy was similar to that in the present results. However, the former analysis did not classify posterior septal pathways into sublocations facing the right or left ventricular side. The latter analysis showed that phase imaging did not provide sufficient information and thus required adenosine infusion. Their methods were more complicated than the present methods.

Our study did not deal primarily with the mechanism of reduced posterior wall motion in patients with a left ventricular side accessory pathway. Possible mechanisms are as follows (fig 5). When the accessory pathway is located on the right ventricular side, electric current along the accessory pathway does not reach the left ventricular wall during the systolic phase because the pathway is located remote from the left ventricular wall and propagation of the electric wave in the left ventricle from an unusual source (that is, by the accessory pathway) is slight. Conversely, when the accessory pathway is located on the left ventricular side, electric current along the accessory pathway and through the normal conduction system reaches the left ventricular wall with closely related timing during the systolic phase, resulting in asynchronous left ventricular systolic motion. Decreased left ventricular posterior wall systolic motion in a patient with a right posterior septal accessory pathway in combination with complete left bundle branch block would support our explanation: although a right posterior septal accessory pathway on its own is not associated with decreased left ventricular wall systolic motion by the process described above, when a right posterior septal pathway is associated with complete left bundle branch block, conduction through the normal pathway is delayed owing to the block, and current from both the accessory and normal pathway reach the left ventricular wall with closely related timing during the systolic phase, resulting in asynchronous left ventricular wall systolic motion. Durrer *et al* examined the excitation process in the isolated human heart and showed that the left sided posterior septum is the last site reached by the excitation process.¹⁸ In cases with a left posterior septal accessory pathway, electric current along the accessory pathway thus collides head on with that along

the normal pathway in the left ventricle during the systolic phase, resulting in prominent asynchronous (decreased) left ventricular wall systolic motion.

LIMITATIONS

Because accessory pathway location is so variable,¹⁹ there was a relatively small number of patients with each sublocation. However, when the patients were divided into two groups based on right or left ventricular location, the numbers of patients were not less than the minimum necessary for statistical analysis.

CONCLUSION

Reduced left ventricular posterior systolic wall motion is an important phenomenon when the accessory pathway is located on the left ventricular side, especially the left posterior septal accessory pathway.

- 1 Jackman WM, Wang X, Friday KJ, *et al.* Catheter ablation of accessory atrioventricular pathways (Wolff-Parkinson-White syndrome) by radiofrequency current. *N Engl J Med* 1991;324:1605-11.
- 2 Kuck KH, Schluter M, Geiger M, *et al.* Radiofrequency current catheter ablation of accessory atrioventricular pathways. *Lancet* 1991;337:1557-61.
- 3 Rosenbaum FF, Hecht HH, Wilson FN, *et al.* The potential variations of the thorax and esophagus in anomalous atrioventricular excitation (Wolff-Parkinson-White syndrome). *Am Heart J* 1945; 29:281-326.
- 4 Gallagher JJ, Pritchett ELC, Sealy WC, *et al.* Preexcitation syndromes. *Prog Cardiovasc Dis* 1978;20:285-302.
- 5 Milstein S, Sharma AD, Guiraudon GM, *et al.* An algorithm for the electrocardiographic localization of accessory pathways in the Wolff-Parkinson-White syndrome. *PACE* 1987; 10:555-63.
- 6 Arruda M, Wang X, McClelland J, *et al.* ECG algorithm for predicting sites of successful radiofrequency ablation of accessory pathways. *PACE* 1993;16(suppl):865.
- 7 Xie B, Heald SC, Bashir Y, *et al.* Localization of accessory pathways from the 12-lead electrocardiogram using a new algorithm. *Am J Cardiol* 1994;74:161-5.
- 8 Fitzpatrick AP, Gonzales RP, Lesh MD, *et al.* New algorithm for the localization of accessory atrioventricular connections using a baseline electrocardiogram. *J Am Coll Cardiol* 1994;23:107-16.
- 9 Avila A, Brugada J, Skeberis V, *et al.* A fast and reliable algorithm to localize accessory pathways based on the polarity of the QRS complex on the surface ECG during sinus rhythm. *PACE* 1995;18:1615-27.
- 10 Hishida H, Sotobata I, Koike Y, *et al.* Echocardiographic patterns of ventricular contraction in the Wolff-Parkinson-White syndrome. *Circulation* 1976;54:251-63.
- 11 Francis LGS, Theroux P, O'Rourke RA, *et al.* An echocardiographic study of interventricular septal motion in the Wolff-Parkinson-White syndrome. *Circulation* 1976; 54:174-8.
- 12 Feigenbaum H. Echocardiographic findings with altered electrical activation. In: Feigenbaum H, ed. *Echocardiography*. Philadelphia: Lea & Febiger, 1994:216-38.
- 13 Kuecherer HF, Abbott JA, Botvinick EH, *et al.* Two-dimensional echocardiographic phase analysis: its potential for noninvasive localization of accessory pathways in patients with Wolff-Parkinson-White syndrome. *Circulation* 1992;85:130-42.
- 14 Kuecherer HF, Kleber GS, Melicherick J, *et al.* Transesophageal echo phase imaging for localizing accessory pathways during adenosine-induced preexcitation in patients with the Wolff-Parkinson-White syndrome. *Am J Cardiol* 1996;77:64-71.
- 15 Rakovec P, Kranjec I, Fettich JJ, *et al.* Detection of electrocardiographically imperceptible ventricular pre-excitation by phase imaging. *Clin Cardiol* 1986;9:475-8.
- 16 Wen MS, Yeh SJ, Wang CC, *et al.* Radiofrequency ablation therapy of the posteroseptal accessory pathway. *Am Heart J* 1996;132:612-20.
- 17 Dhala AA, Deshpande SS, Bremner S, *et al.* Transcatheter ablation of posteroseptal accessory pathways using a venous approach and radiofrequency energy. *Circulation* 1994;90:1799-810.
- 18 Durrer D, van Dam RT, Freud GE, *et al.* Total excitation of the isolated human heart. *Circulation* 1970;41:899-912.
- 19 Arruda MS, Beckman KJ, McClelland JH, Wang X, Nakagawa H, Widman LE, *et al.* Coronary sinus anatomy and anomalies in patients with posteroseptal accessory pathway requiring ablation within a venous branch of the coronary sinus [abstract]. *J Am Coll Cardiol* 1994;23:224A.