

## CONGENITAL HEART DISEASE

## Interventional catheterisation. Opening up II: venous return, the atrial septum, the arterial duct, aortopulmonary shunts, and aortopulmonary collaterals

John L Gibbs

The Yorkshire Heart Centre, Department of Paediatric Cardiology, Leeds General Infirmary, Leeds, UK

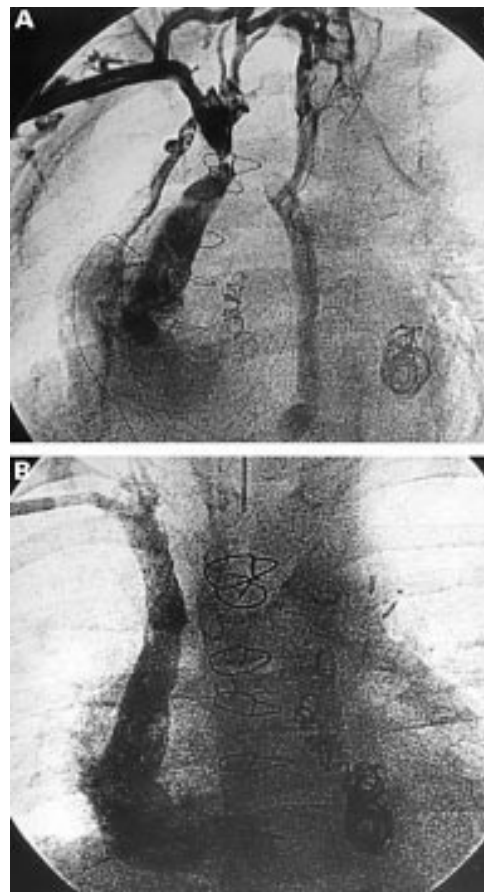
**O**bststruction to flow in the superior caval vein rarely occurs de novo. It is usually a consequence of scarring related to surgery, to the presence of venous catheters or pacemaker electrodes, or external compression by tumour. When obstruction occurs insidiously there may be no symptoms and no indication to intervene, but with rapid onset obstruction, when collateral veins have not had time to develop and enlarge, venous hypertension in the head and neck will prompt treatment (fig 1). Although these stenoses can be dilated using a balloon, stent implantation is usually required to prevent recoil.<sup>1</sup> Self expanding as well as balloon expandable stents have been used with good effect. In the presence of complete obstruction "reconstruction" is sometimes possible by passing a long needle and then a guide wire through the obstruction, followed by ballooning and stenting. Because the vein is usually surrounded by scar tissue accidental perforation is unlikely to cause any more harm than localised haematoma.

Intra-atrial obstruction to systemic venous return may occur after venous inflow redirection surgery for transposition of the great arteries. This is relatively common after Mustard's operation, when patches of material are sewn inside the atria to redirect the systemic veins to the left atrium and the pulmonary veins to the right atrium (fig 2). Obstruction is much less likely after Senning's operation, in which redirection is achieved using infoldings of the atrial wall. Obstruction may become evident many years after surgery (during teenage or adult life) and often presents with oedema, ascites or even protein losing enteropathy. Such symptoms are clearly an indication to intervene and rarely occur unless there is obstruction to both superior and inferior venous channels. Total obstruction of the superior channel may occur without being clinically obvious when collateral veins (often azygos or hemiazygos) are well established. Stenoses in the intracardiac venous channels often respond well to balloon dilatation alone, although some degree of elastic recoil is common. Self expanding or balloon expandable stents produce excellent results in such cases<sup>2-3</sup> and stenting appears surprisingly safe. It is easy to imagine that stenting the systemic venous pathways might produce compression

of the adjacent pulmonary venous pathways but in practice that does not appear to occur. The precise indications for intervention in asymptomatic patients remains controversial.

## Pulmonary venous obstruction

Pulmonary venous obstruction as an isolated anomaly is exceedingly rare; the vast majority of cases occur in association with anomalous pulmonary venous return and it may be seen both before and after surgical repair of anomalous venous connections. Obstruction to an anomalous common pulmonary venous channel is most often associated with infracardiac or supracardiac total anomalous pulmonary venous drainage (TAPVD) and in such circumstances the treatment of choice is almost invariably surgical redirection of the pulmonary veins. When associated with very complex cardiac abnormalities (usually with right atrial isomerism) in the neonate it may be venous obstruction that is the immediate haemodynamic problem, rather than the abnormal site of venous drainage, and there have been occasional reports of balloon dilatation or even stenting of obstructed anomalous pulmonary venous channels. Such procedures may produce some temporary relief of pulmonary



**Figure 1:** (A) Severe, symptomatic obstruction of the superior caval vein, with multiple small collateral channels, in a child who had undergone cardiac transplantation following numerous palliative operations for complex congenital heart disease. There was little improvement after simple balloon dilatation (using axillary venotomy), but stent implantation (B) produced complete relief of obstruction.

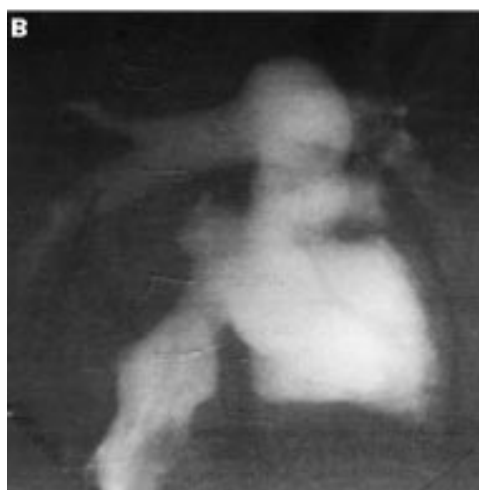
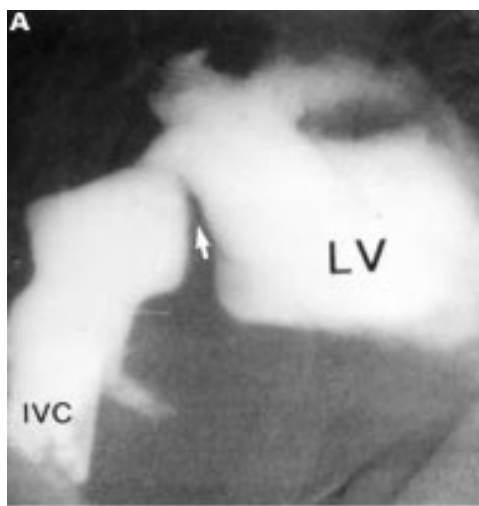
Correspondence to:  
Dr John L Gibbs, The  
Yorkshire Heart  
Centre, Department of  
Paediatric Cardiology,  
E Floor, Leeds General  
Infirmary, Great  
George Street, Leeds  
LS1 3EX, UK  
email: jgibbs@  
ulth.northy.nhs.uk

oedema but there can be no doubt that surgical redirection of the pulmonary veins offers a much more secure and longer lasting answer.

When pulmonary venous obstruction occurs after surgical repair of TAPVD it is rarely simply a problem of inadequate venous anastomosis, but usually affects the pulmonary veins (often all four) in their distal portions close to the left atrium. Surgical patching of the pulmonary veins, balloon dilatation and stent implantation (both transcatheter and surgically placed) all produce disappointing results, often with only short term improvement.<sup>4,5</sup> The mechanism behind this so called pulmonary veno-occlusive disease, responsible for the relentless recurrence of stenosis, is poorly understood; necropsy studies of the walls of the pulmonary veins show intimal and medial thickening.

### Creation of an atrial septal defect

The majority of patients who undergo atrial septostomy are neonates with transposition of the great arteries, but there are other situations where creation of an atrial septal defect may be helpful, even in adolescents or adults. In babies the traditional Rashkind balloon is still favoured, the balloon being pulled back to the right atrium after it has been passed across the foramen into the left atrium and inflated. For older patients, when the atrial septum may be too tough to allow an adequate hole to be torn with the Rashkind balloon, progressive dilatation (as opposed to forced balloon withdrawal) using a balloon introduced over a guide wire may be effective. This is probably safer than the alternative of blade septostomy when a folding blade at the tip of a catheter is withdrawn across the septum, the procedure being repeated with varying orientation of the blade to make a series of cuts. Not surprisingly, complications such as atrial perforation may occur. The defect created by the blade may be enlarged by balloon. In older patients who have an intact atrial septum it may be necessary first to perforate the septum using a transeptal needle or a radiofrequency or laser wire. The



**Figure 2:** (A) Obstruction in the systemic venous pathway in a 14 year old after Mustard's operation for transposition. The patch sewn inside the atria to redirect systemic venous return to the mitral valve and left ventricle has become distorted, causing a shelf like obstruction (arrowed). Balloon dilatation has resulted in sufficient widening of the pathway (B) to relieve completely symptoms of venous hypertension (protein losing enteropathy in this case). IVC, inferior vena cava; LV, left ventricle.

### Venous obstruction

#### Systemic circulation

- In the superior caval vein
  - Usually iatrogenic or caused by external compression
  - Ballooning rarely sufficient, stent usually required
- Within the atrium
  - Relatively common after Mustard's operation for transposition
  - Ballooning alone often sufficient to relieve symptoms

#### Pulmonary circulation

- Rare, often associated with anomalous pulmonary venous return
  - Ballooning, stenting and surgery all very rarely rewarding

risk of septostomy varies considerably, depending on the anatomical abnormality as well as the method employed.

### Simple and complex transposition

In simple transposition poor mixing between the pulmonary and systemic circulations may cause severe hypoxaemia and death even if the arterial duct is patent, so it is customary to perform immediate balloon septostomy. In most centres this is done under echocardiographic control.<sup>6</sup> It may be carried out anywhere, without the need for a catheterisation laboratory, is safe, and usually takes only a few minutes. Access to the heart is achieved through the umbilical or femoral vein; the former has the advantage of preserving the femoral vein for later use, although the ductus venosus may be awkward to cross in some cases.

**Mitral, pulmonary, and tricuspid atresia**

With mitral atresia the left atrium can empty only across the foramen to the right atrium. It is wise to decompress the left atrium even when the foramen does not appear to be obviously restrictive in the early neonatal period. Septostomy can be technically difficult because the left atrium is small. Immediate haemodynamic benefit (a fall in left atrial pressure) may occur but in some cases the sudden decompression of the left atrium produces a dramatic increase in pulmonary blood flow, resulting in acute deterioration or even death. When neonatal septostomy has not been carried out the atrial septum often becomes restrictive with time, giving signs and symptoms of pulmonary venous and arterial hypertension later in life. Decompression of the left atrium is difficult and hazardous in older patients (dilatation by balloon<sup>7</sup> or the Park blade<sup>8</sup> may help) and surgical septectomy may be required.

In patients with pulmonary atresia with an intact ventricular septum or with tricuspid atresia, the only route by which the right atrium can empty is across the foramen to the left atrium. There is divided opinion on the desirability of neonatal septostomy in such cases. In some countries it is routine but in practice it is rare for the foramen to be restrictive in infancy, and it is the author's opinion that septostomy is very rarely required.

**The failing Fontan circulation and end stage pulmonary hypertension in older patients**

When the chronically elevated systemic venous pressure associated with the Fontan operation (direct anastomosis of the right atrium to the pulmonary trunk) is poorly tolerated, creation of a small atrial septal defect may relieve the symptoms of high systemic venous pressure (albeit at the price of some degree of desaturation caused by right to left atrial shunting). Similarly, creation of a small atrial septal defect may reduce right atrial pressure and increase cardiac output in advanced pulmonary hypertension in adults. Because the atrial septum is intact (necessitating septal puncture), and it is difficult to judge as well as to create the appropriate size of defect, this approach has not been

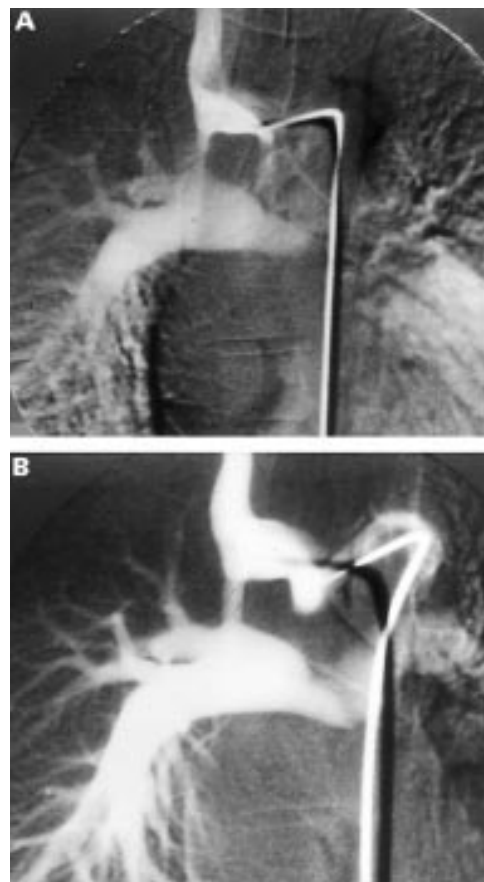
**Atrial septostomy**

- Beneficial in:
  - All neonates with simple transposition or mitral atresia
  - Most neonates with complex transposition
  - Occasional neonates with tricuspid atresia or hypoplasia of the right heart
  - Children or young adults with “failing” Fontan circulation
  - Selected adults with end stage pulmonary hypertension
- Techniques:
  - “Pullback” balloon (Rashkind)
  - Balloon dilatation
  - Park blade catheter

widely adopted. Nonetheless, it may be worth consideration if symptoms are severe.<sup>9</sup>

**Arterial duct**

Medical treatment with prostaglandin E allows short term maintenance of duct patency in neonates with duct dependent circulation. Attempts to keep the duct open in the longer term have included simple balloon angioplasty (unreliable),<sup>10</sup> “hot” balloon angioplasty (better but still unreliable),<sup>11</sup> and stent implantation. Stenting seems to keep the duct open effectively when the systemic circulation is dependent—that is, variants of the hypoplastic left heart syndrome.<sup>12</sup> It may be useful as a bridge to transplantation in some cases,<sup>13</sup> but unfortunately it does not prevent heart failure developing and recent results of palliative surgery (the Norwood operation and its modifications) are superior. When the pulmonary circulation is dependent the duct tends to be tortuous and while stenting is possible, it is technically very demanding and sudden death may occur during or after the procedure.<sup>14</sup> Neointimal proliferation producing stenosis within the stent is common, necessitating repeated balloon dilatations to cope with growth of the child. There are only rare circumstances (for instance bilateral pulmo-



**Figure 3:** (A) Severe obstruction of a classical Blalock–Taussig shunt in a teenager with complex pulmonary atresia. There was almost complete recoil after simple balloon dilatation but stent implantation notably improved blood flow to the right lung (B).

nary artery disconnection with bilateral ducts) where it may be a reasonable alternative to a surgical aortopulmonary shunt.

### Aortopulmonary shunts

The classical Blalock–Taussig shunt, where the subclavian artery is joined, end to side, to the ipsilateral pulmonary artery, may provide excellent palliation for complex cyanotic heart disease, but stenosis eventually occurs. This may be in the form of discrete stenosis (often at the distal anastomosis), may be diffuse along the length of the shunt, or a combination of these. Balloon angioplasty alone may improve the stenosis in many cases,<sup>15</sup> but elasticity is common and stent implantation may be the only means of improving the shunt diameter (fig 3).<sup>16</sup> Dramatic improvement in pulmonary blood flow, cyanosis, and symptoms may occur but the procedure is only indicated in complex disease unsuitable for surgical repair. A modified Blalock shunt, usually fashioned from Goretex tubing, has a limited life because of lack of growth and increasing thickness of the layer of tissue (a mixture of endothelial cells, fibrous tissue, and sometimes laminated thrombus, collectively known as “peel”) lining the synthetic tube. Although balloon angioplasty may result in enlargement of the shunt lumen this is often short lived, and there is some risk of inducing abrupt shunt occlusion (usually fatal) if the “peel” is dissected off the wall of the shunt.

### Aortopulmonary collaterals

When the pulmonary arteries have failed to develop the lungs are supplied by collateral vessels from the aorta. These vessels are prone to stenoses developing with associated progressive reduction in pulmonary blood flow, with worsening cyanosis and exercise tolerance.<sup>17</sup> The vessels are often extremely thick walled and elasticity is common, although in some cases they cannot be dilated even with high pressure balloons. It is wise to ensure the stenosis is dilatable by simple ballooning before proceeding to stenting, which may be required to maintain an effective increase in blood flow.<sup>18</sup>

**1: Wisselink W, Money SR, Becker O, et al.** Comparison of operative and percutaneous balloon dilatation for central venous obstruction. *Am J Surg* 1993;**166**:200–4.

**2: Bu'Lock FA, Tometzki AJ, Kitchener DJ, et al.** Balloon expandable stents for systemic venous pathway stenosis late after Mustard's operation. *Heart* 1998;**79**:225–9.

- Good results in terms of angiographic improvement after stent implantation, and the risks appear to be low. In some patients the stenosis was detected only on routine late angiography and there is controversy over the place of stent implantation in asymptomatic patients (see below).

**3: Rosenthal E, Qureshi SA.** Stenting of systemic venous pathways after atrial repair for complete transposition. *Heart* 1998;**79**:211–12.

- A useful overview of the subject, highlighting that indications to intervene are not clear cut.

**4: Driscoll DJ, Hesslein PS, Mullins CE.** Congenital stenosis of individual pulmonary veins: clinical spectrum and unsuccessful treatment by transvenous balloon dilatation. *Am J Cardiol* 1982;**49**:1767–72.

**5: Cullen S, Ho SY, Shore D, et al.** Congenital stenosis of pulmonary veins: failure to modify natural history by intraoperative placements of stents. *Cardiology in the Young* 1994;**4**:395–8.

**6: Beitzke A, Stein JL, Suppan C.** Balloon atrial septostomy under two dimensional echocardiographic control. *Int J Cardiol* 1991;**30**:33–42.

- 44 newborns all had successful septostomies under echo control. This, and other reports like it, led to most centres abandoning the catheter laboratory for neonatal septostomy.

**7: Thanopoulos BD, Georgakopoulos D, Tsaousis GS, et al.** Percutaneous balloon dilatation of the atrial septum: immediate and midterm results. *Heart* 1996;**76**:502–6.

**8: Park SC, Neches WH, Mullins CE, et al.** Blade atrial septostomy: collaborative study. *Circulation* 1982;**66**:258–66.

**9: Kerstein D, Lew PS, Hsu DT, et al.** Blade balloon atrial septostomy in patients with severe primary pulmonary hypertension. *Circulation* 1995;**91**:2028–35.

- 15 children and adults with advanced primary pulmonary hypertension, with either syncopal attacks or right heart failure. After blade septostomy cardiac output increased and there appeared to be a benefit in survival too, when compared with approximately matched patients who had conventional treatment. There were two procedural deaths, one before the septostomy was performed and one because of massive desaturation after a single pass of the blade, not surprising for such a sick group of patients.

**10: Walsh KP, Sreeram N, Franks R, et al.** Balloon dilatation of the arterial duct in congenital heart disease. *Lancet* 1992;**339**:331–2.

**11: Abrams SE, Walsh KP, Diamond MJ, et al.** Radiofrequency thermal angioplasty maintains arterial duct patency: an experimental study. *Circulation* 1994;**90**:442–8.

**12: Gibbs JL, Wren C, Watterson KG, et al.** Stenting of the arterial duct combined with banding of the pulmonary arteries and atrial septectomy or septostomy: a new approach to palliation for the hypoplastic left heart syndrome. *Br Heart J* 1993;**69**:551–5.

**13: Ruiz CE, Gamra H, Zhang HP, et al.** Brief report: stenting of the ductus arteriosus as a bridge to cardiac transplantation in infants with the hypoplastic left heart syndrome. *N Engl J Med* 1993;**328**:1605–8.

**14: Gibbs JL, Rothman MT, Rees M, et al.** Stenting of the arterial duct: a new approach to palliation for pulmonary atresia. *Br Heart J* 1991;**67**:240–5.

**15: Marx GR, Allen HD, Ovitt TW, et al.** Balloon dilatation angioplasty of Blalock-Taussig shunts. *Am J Cardiol* 1988;**62**:824–7.

**16: McLeod K, Blackburn MEC, Gibbs JL.** Enlargement of a classical Blalock Taussig shunt by implantation of a stent after failed balloon angioplasty. *Cardiology in the Young* 1994;**4**:411–12.

**17: Brown SC, Eyskens B, Mertens L, et al.** Percutaneous treatment of stenosed major aortopulmonary collaterals with balloon dilatation and stenting: what can be achieved? *Heart* 1998;**79**:24–8.

- 12 patients with 25 stenosed collaterals. Encouraging increase in oxygen saturation in the majority. Notable that some stenoses improved with ballooning alone, some were undilatable even with very high pressure balloons, and one patient developed an aneurysm.

**18: Redington AN, Somerville J.** Stenting of aortopulmonary collaterals in complex pulmonary atresia. *Circulation* 1996;**94**:2479–84.

- 12 severely cyanosed patients, in whom stent implantation was possible in 11. Saturations as well as exercise duration increased. It is not clear how long the improvement will last, but anything that can help these very difficult patients is good news.