

Prevalence of the Brugada sign in idiopathic ventricular fibrillation and healthy controls

S Viskin, R Fish, M Eldar, D Zeltser, M D Lesh, A Glick, B Belhassen

Abstract

Objective—To determine the prevalence of the Brugada sign (right bundle branch block with ST elevation in V1–V3) in idiopathic ventricular fibrillation and in an age matched healthy population.

Design—ECGs from 39 consecutive patients with idiopathic ventricular fibrillation and 592 healthy controls were reviewed. They were classified as definite, questionable, and no Brugada sign (according to predetermined criteria) by four investigators blinded to the subjects' status.

Results—Eight patients (21%) with idiopathic ventricular fibrillation but none of the 592 controls had a definite Brugada sign ($p < 0.005$). Thus the estimated 95% confidence limits for the prevalence of a definite Brugada sign among healthy controls was less than 0.5%. A questionable Brugada sign was seen in two patients with idiopathic ventricular fibrillation (5%) but also in five controls (1%) ($p < 0.05$). Normal ECGs were found following resuscitation and during long term follow up in 31 patients with idiopathic ventricular fibrillation (79%). Patients with idiopathic ventricular fibrillation and a normal ECG and those with the Brugada syndrome were of similar age and had similar spontaneous and inducible arrhythmias. However, the two groups differed in terms of sex, family history, and the incidence of sleep related ventricular fibrillation.

Conclusions—A definite Brugada sign is a specific marker of arrhythmic risk. However, less than obvious ECG abnormalities have little diagnostic value, as a “questionable” Brugada sign was observed in 1% of healthy controls. In this series of consecutive patients with idiopathic ventricular fibrillation, most had normal ECGs.

(Heart 2000;84:31–36)

Keywords: sudden death; cardiac arrest; ventricular fibrillation; Brugada syndrome

In 1987, Belhassen and colleagues reported the first series of patients with idiopathic ventricular fibrillation.¹ The original report included five patients with out of hospital ventricular fibrillation who had no identifiable aetiology and no evidence of heart disease. All these patients had a normal ECG, as well as normal atrioventricular conduction as assessed by invasive electrophysiological studies.¹ Five years later, Brugada and Brugada reported eight patients with idiopathic ventricular fibrillation who had a peculiar ECG, described as “right bundle branch block with ST elevation in V1–V3.” Half of these patients had infranodal conduction delay (HV interval ≥ 60 ms).² Since then, more than 100 patients have been identified with aborted sudden death from ventricular fibrillation associated with right bundle branch block and ST elevation,^{3–5} commonly referred to as the Brugada syndrome.^{6,7} Because idiopathic ventricular fibrillation is a rare disease,⁸ the rapidly increasing number of patients with the Brugada syndrome could indicate that the majority of patients with idiopathic ventricular fibrillation have abnormal ECGs. Alternatively, this large number of patients with the Brugada syndrome could represent publication bias or referral bias (that is, increased odds for reporting, or more frequent referral to specialised centres when the Brugada sign is present).

It is important to define the true prevalence of the Brugada sign in idiopathic ventricular fibrillation because it is an easily identifiable

ECG abnormality that could be used as a screening tool. Also, patients with idiopathic ventricular fibrillation (with or without the Brugada sign) appear to have unique characteristics⁹ that need to be better defined. We therefore reviewed the ECGs of consecutive patients with idiopathic ventricular fibrillation to determine the percentage of those with a Brugada sign. To reduce the odds of biased ECG classification, we included in our blinded review the ECGs of almost 600 controls.

Methods

PATIENTS

We studied 39 consecutive patients with idiopathic ventricular fibrillation referred for evaluation or consultation (24 male, 15 female; mean (SD) age 41 (15) years, range 14 to 69) and 592 controls (346 male, 246 female; age 36 (10) years, range 14 to 67). The diagnosis of idiopathic ventricular fibrillation was in accordance with the criteria of the US idiopathic ventricular fibrillation registry and the European unexplained cardiac arrest registry¹⁰: first, all the patients had one or more episodes of cardiac arrest with ventricular fibrillation documented at the time of resuscitation; second, all had normal results in the following tests: physical examination, ECG at rest and during exercise stress testing (except for the Brugada sign and the presence of ventricular arrhythmias), normal echocardiogram, and normal cardiac catheterisation with coronary angiography. In addition, the right ventricle

Department of
Cardiology,
Sourasky-Tel Aviv
Medical Center,
Sackler School of
Medicine, Tel Aviv
University, Weizman 6,
Tel Aviv 64239, Israel
S Viskin
R Fish
D Zeltser
A Glick
B Belhassen

Sheba Medical Center,
Sackler School of
Medicine
M Eldar

Cardiovascular
Research Institute,
University of
California, San
Francisco, California,
USA
M D Lesh

Correspondence to:
Dr Viskin
viskin_s@netvision.net.il

Accepted 22 February 2000

was visualised by right ventriculography during cardiac catheterisation or by magnetic resonance imaging. Invasive studies were waived in only one patient (a 22 year old man with Brugada sign who had nocturnal ventricular fibrillation and normal non-invasive studies) because he had anoxic brain damage. Patients with cardiac arrest and a normal heart, who could be better classified as suffering from other forms of “polymorphic ventricular arrhythmias in the absence of heart disease” (defined elsewhere⁹) were excluded. Some of our patients appear in previous publications dealing with different aspects of idiopathic ventricular fibrillation.^{1 8 11-15}

The control group consisted of 592 patients referred for electrophysiological evaluation of supraventricular arrhythmias (excluding those with ventricular preexcitation) or referred to one of the surgical services, who fulfilled all the following criteria: age within the age range observed in patients with idiopathic ventricular fibrillation, no history of syncope, no clinical evidence of organic heart disease, and no antiarrhythmic drug treatment.

Coded ECGs of all patients and controls were presented in random order to four experienced cardiologists who were blinded to the patients' status. Each of the investigators (all familiar with the published illustrations of the Brugada sign) graded the ECGs independently (see below).

ELECTROCARDIOGRAMS

All the ECGs were recorded at standard gain (1 mV/10 mm) and paper speed (25 mm/s). The investigators were requested to grade the traces as showing “definite,” “questionable,” or “no Brugada sign,” according to the following criteria.

Definite Brugada sign—A definite Brugada sign was considered to be present when the 12 lead ECG showed RsR' and ST elevation in the right precordial leads and looked like the ECGs shown in the publications by Brugada and Brugada.^{2 16} Accordingly, the investigators (at least three of the four cardiologists) felt that the trace would be “diagnostic of Brugada syndrome” when recorded in a patient with ventricular fibrillation and an apparently normal heart.

Questionable Brugada sign—A questionable Brugada sign was considered to be present when the traces showed QRS abnormalities and ST elevation in the right precordial leads that were of a lesser degree than the abnormalities shown in the figures of the original publications by Brugada and Brugada.^{2 16} Accordingly, the investigators (at least three of four) felt that these traces would be “consistent with” the Brugada syndrome when present in a patient with ventricular fibrillation and an apparently normal heart (fig 1).

No Brugada sign—It was considered that the Brugada sign was absent when the ECGs were normal or had minor abnormalities that were not similar to those shown in the figures of the original publications by Brugada and Brugada.^{2 16} Accordingly, the investigators felt that, with such traces, a diagnosis of Brugada syndrome would

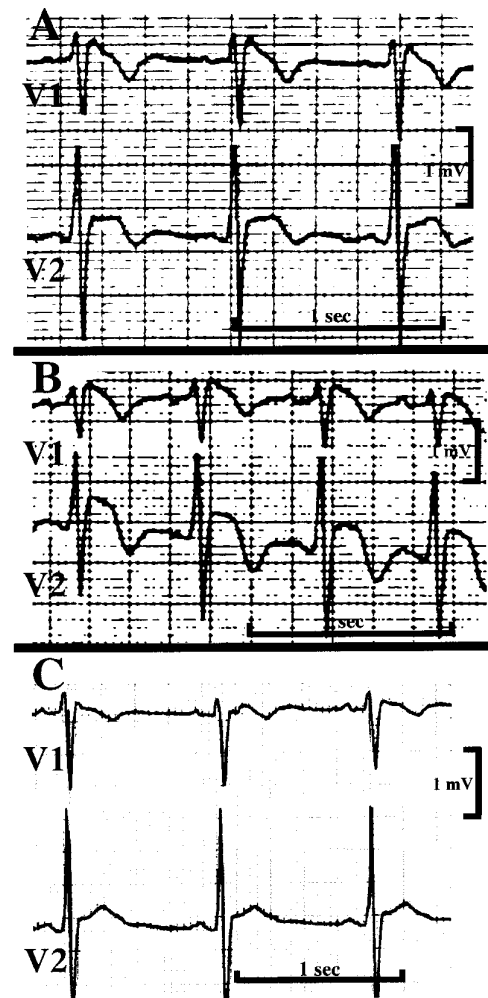


Figure 1 Three ECGs (leads V1-V2) of a patient with idiopathic ventricular fibrillation. The top and middle traces were graded as “definite Brugada sign”. The bottom trace (recorded three years after diagnosis) was graded as “questionable Brugada sign”. The middle and bottom traces were recorded during treatment with quinidine.

not be appropriate, even in a patient with ventricular fibrillation and an apparently normal heart.

We also provided a quantitative description of the abnormalities observed in the right precordial leads (table 1). Finally, as some reports have suggested that the Brugada sign might only become evident during repeated ECG recordings or following administration of class 1A drugs,^{6 16} we did further ECG recordings in the patients with idiopathic ventricular fibrillation during long term follow up. Selection of these supplementary ECGs was not blinded; they included traces recorded during the administration of class 1A drugs, either intravenously (six patients) or orally (26 patients), and traces showing the most pronounced and the least pronounced ST changes during long term follow up. All the traces in both patients and controls were presented in random order to the grading investigators, who were unaware of the number of traces included for each patient.

Table 1 Electrocardiographic characteristics observed in patients with idiopathic ventricular fibrillation and controls

	Idiopathic ventricular fibrillation (n=39)	Controls (n=592)	p Value*
Definite Brugada sign†	6 (15%)	0	p < 0.005
Probable Brugada sign‡	2 (5%)	5 (1%)	p < 0.05
RsR' (V1-V2) without ST elevation	6 (16%)	73 (12%)	NS
≥ 1 mm ST elevation (V1-V2)	5 (13%)	54 (9%)	NS

* χ^2 test.

†Numbers relate to the first ECG only, which is why they are slightly different from those in table 2.

‡One patient with a questionable Brugada sign at presentation had a definite Brugada sign during follow up and the other had normal traces.

Results

PATIENTS WITH IDIOPATHIC VENTRICULAR FIBRILLATION

Six patients with idiopathic ventricular fibrillation had a definite Brugada sign at presentation (fig 2), including three with a definite sign in all follow up traces and three with either a questionable sign or no Brugada sign in the follow up recordings (fig 1). In addition, two patients had a questionable Brugada sign at presentation, but with a definite sign observed at least once during follow up (fig 3). Thus eight patients (21%) with idiopathic ventricular fibrillation (seven male and one female) had the Brugada sign (table 2).

Twenty eight patients with idiopathic ventricular fibrillation had normal ECGs at presentation and three had incomplete right bundle branch block *without* ST elevation. Thus 31 patients (79%) with idiopathic ventricular fibrillation, aged 14–69 years, had no Brugada sign. None of these had traces graded as showing a “definite” or “questionable” Brugada sign during long term follow up.

Patients with and without a Brugada sign were of similar age at the onset of symptoms (table 2). The ventricular arrhythmias (spontaneous and induced) of both patient groups also had similar characteristics: first, recordings from 24 spontaneous arrhythmias in nine patients with a normal ECG and from nine arrhythmic episodes in three patients with the Brugada syndrome invariably showed precipitation of polymorphic ventricular tachycardia by a ventricular extrasystole with very short coupling interval (as previously described¹⁷); second, sustained polymorphic ventricular tachycardia degenerating to ventricular fibrillation was induced with programmed stimulation in the vast majority of patients in both groups (table 2). On the other hand, both groups differed in several characteristics:

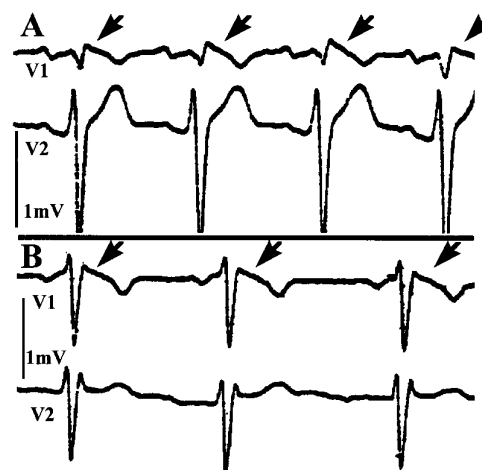


Figure 3 ECGs (leads V1–V2) of two patients with “questionable” Brugada sign. RsR' with minor ST elevation is shown (arrows). Both patients belong to the control group.

● Sex: seven of eight patients with Brugada syndrome, but only half of those with a normal ECG, were male (this difference did not reach significance because of the small number of patients).

● A familial history of sudden death was obtained only in the Brugada group, albeit rarely.

● Ventricular fibrillation while asleep occurred exclusively among patients with a definite Brugada sign (table 2).

Patients with sleep related ventricular fibrillation also had at least one documented episode of ventricular fibrillation (three patients) or one episode of syncope (one patient) while awake during the daytime.

Patients with sleep related ventricular fibrillation also had at least one documented episode of ventricular fibrillation (three patients) or one episode of syncope (one patient) while awake during the daytime.

EFFECTS OF CLASS 1A DRUGS ON THE ECG

Six patients received intravenous ajmaline or procainamide and 26 patients received oral treatment with class 1A drugs (mainly quinidine but also disopyramide) following the diagnosis of idiopathic ventricular fibrillation. Class 1A drugs did not unmask a Brugada sign in any patient.

CONTROL GROUP

A definite Brugada sign was not seen in any of the 592 controls. Accordingly, the estimated 95% confidence limits for the prevalence of a definite Brugada sign among healthy controls was less than 0.5%. However, RsR' and some

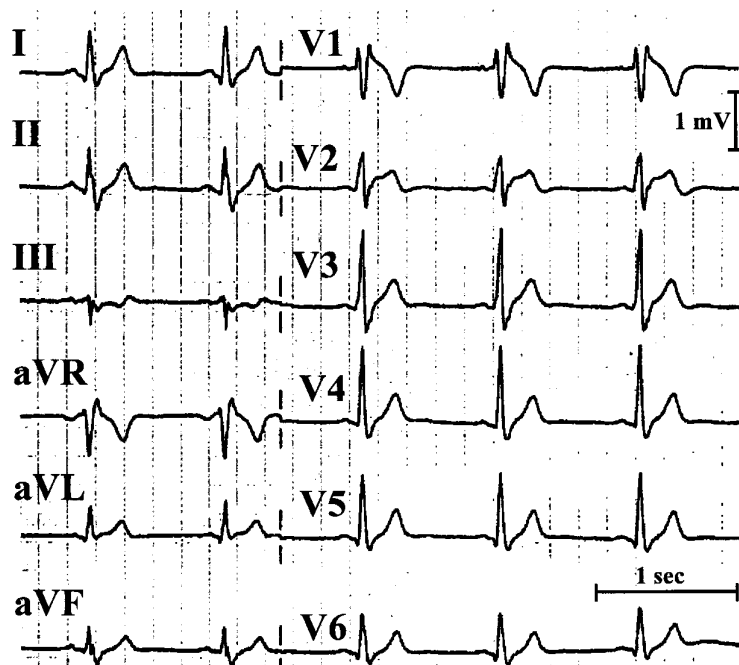


Figure 2 ECG of a patient with idiopathic ventricular fibrillation showing a “definite” Brugada sign. RsR' with obvious ST elevation is shown. Additional ECGs of this patient have been published previously.¹¹

Table 2 Consecutive patients with idiopathic ventricular fibrillation: characteristics of patients with and without a Brugada sign

	Brugada sign (n=8)	Normal ECG (n=31)	p Value*
Age (years) (mean (SD))	32 (14)	43 (14)	NS
Male sex	7 (87%)	17 (55%)	NS
Familial sudden death	2 (25%)	0	p < 0.05*
Ventricular fibrillation during sleep†	4 (50%)	0	p < 0.005*
Inducible ventricular fibrillation	7/7 (100%)‡	24 (75%)	NS

*Fisher's exact test.

†These four patients had additional episodes of ventricular fibrillation (n=3) or syncope (n=1) while awake during daytime.

‡One patient with Brugada sign did not undergo electrophysiological evaluation.

elevation of the ST segments in leads V1–V2 were commonly seen (table 1), and 1% of the traces of the healthy population were considered to represent a questionable Brugada sign. By study design, none of the controls received antiarrhythmic drugs.

Discussion

THE BRUGADA SIGN

An ECG pattern has been described as “right bundle branch block with ST segment elevation,”^{2, 6, 16, 18–20} or as “prominent J waves,”²¹ in patients with otherwise idiopathic ventricular fibrillation. Experimental studies suggest that a notch in the action potential is the cellular basis for these J waves.²² This notch is caused by transient outward (I_{to}) currents, which are more prominent in the right ventricular epicardium. Accordingly, “prominent J waves,” as seen in the Brugada syndrome, could be a marker of unequal spike and dome duration of the action potential in different cardiac regions (epicardium versus endocardium and right versus left ventricle), which identifies patients prone to phase 2 reentrant arrhythmias.²²

PREVALENCE OF THE BRUGADA SIGN

Chen and colleagues estimated that 40–60% of cases of idiopathic ventricular fibrillation are associated with the Brugada syndrome,²³ and these are the figures quoted in contemporary reviews.^{4, 5} However, Chen and colleagues based their estimation on “clinical experience” (their sample population was not described); moreover, Brugada and Brugada were coauthors in that study, and it is likely that cardiac arrest survivors with an obvious Brugada sign were specifically referred to those investigators. In other words, referral bias probably increased the percentage of patients with a Brugada sign in that particular series. In contrast, we studied consecutive patients with idiopathic ventricular fibrillation and found a Brugada sign in only 21%.

PREVIOUS STUDIES

Nademanee and colleagues described ECG findings indistinguishable from the Brugada sign in 14 of 17 survivors of cardiac arrest related to the sudden unexplained death syndrome (SUDS) in Thailand.²⁴ Also, six of 11 similar patients in a Japanese series²⁵ had the Brugada sign. However, it is not clear if SUDS—an entity that has been known for many years as nocturnal death syndrome in South East Asia^{26, 27}—and the Brugada syn-

drome are one disease, or whether they are different disorders that share a similar ECG pattern.⁹ Little is known about the prevalence of the Brugada sign outside South East Asia. For example, three years before the description of the Brugada sign,² Martini and colleagues portrayed this ECG appearance in one of six cases with “ventricular fibrillation without heart disease”,¹⁸ while “right bundle branch block with ST elevation in V1–V3” was noted in one of 19 patients in a European series of cases of idiopathic ventricular fibrillation.²⁸

Data on the prevalence of the Brugada sign in the healthy population are also limited. In their original description, Brugada and Brugada included a control group of patients with right bundle branch block.² As in the present study, none of their controls had a Brugada sign. However, because of the small number of controls in that study (only 38 patients), the upper limit of the 95% confidence limits for the prevalence of the Brugada sign in asymptomatic individuals remained high (almost 8%). This upper limit was brought down to less than 0.5% by the large size of our control group in the present study.

IDIOPATHIC VENTRICULAR FIBRILLATION WITH AND WITHOUT THE BRUGADA SIGN

It is not clear if the Brugada syndrome² and “idiopathic ventricular fibrillation with normal ECG”^{1, 8} represent different entities.⁹ Genetic data are limited for the former^{23, 29, 30} and lacking in the latter.

The small number of patients with the Brugada sign in our series limits comparisons between patients with and without this ECG sign. Nevertheless, our observations (table 2) are consistent with published data⁹ indicating that both groups have similar age at presentation and similar spontaneous and inducible arrhythmias. On the other hand, the two groups differed with respect to familial involvement, which is relatively common in the Brugada syndrome^{16, 18} (a genetic disease²³) but absent in idiopathic ventricular fibrillation.⁸ Finally, the male predominance in the Brugada syndrome⁹ is interesting because SUDS—a common form of idiopathic ventricular fibrillation in South East Asia⁹—also affects primarily male patients²⁷ who have the Brugada sign.²⁴ It is therefore intriguing that in our series, ventricular fibrillation during sleep (a peculiarity of SUDS) was more common among patients with a Brugada sign. To our knowledge, this is the first reported association of sleep related ventricular fibrillation and the Brugada syndrome in patients *not* of South East Asian origin.

LIMITATIONS

Without genotype analysis, classification of our patients was based exclusively on the ECG. However, the design of our study (which included a large control group and blinded ECG classification) probably reduced our bias toward overdiagnosis. Of more concern is the potential for underdiagnosis of the Brugada sign in our series. The Brugada sign might become evident only during repeated ECGs.

Although we reviewed subsequent ECGs (performed during long term follow up), it is possible that transient ST changes were missed, leading to underestimation of the prevalence of the Brugada sign. Also, the Brugada sign may become apparent following infusion of class 1A or 1C drugs.^{6,16} Intravenous administration of ajmaline or procainamide did not unmask a Brugada sign in any of our patients with ventricular fibrillation and normal ECGs. However, only six patients (19% of those with idiopathic ventricular fibrillation and a normal ECG) underwent such a challenge. It should be noted, however, that the specificity of ST elevation following class 1 drug administration is not at all clear. This point cannot be overemphasised in view of anecdotal reports suggesting that electrocardiographic features indistinguishable from a Brugada sign may appear in patients without documented or suspected ventricular arrhythmias following administration of class 1C drugs.^{31,32}

CLINICAL IMPLICATIONS

A decade after the description of idiopathic ventricular fibrillation^{1,8,33} and the Brugada syndrome,² it is still impossible to ascertain if these two entities are a single disease. We need to define further the similarities (and differences) between “idiopathic ventricular fibrillation with normal ECG”, the Brugada syndrome, and SUDS. An intriguing question is whether quinidine treatment, long advocated by our group for idiopathic ventricular fibrillation,^{1,8,13,15} can be beneficial for the Brugada syndrome and SUDS. The last two entities share an electrocardiographic phenomenon (the Brugada sign), and experimental evidence³⁴ suggest that I_{To} currents are not only responsible for this phenomenon but are also instrumental in the phase 2 re-entry arrhythmias causing ventricular fibrillation in these patients. Indeed, experimental³⁴ and limited clinical data¹⁵ suggest that quinidine—by virtue of its blocking effects on I_{To} currents—could eventually prove to be a specific antiarrhythmic agent for these patients.

The high specificity of the Brugada sign in our series supports the aggressive evaluation of syncope in patients in whom it is clearly present.¹⁶ Because of the poor diagnostic yield of non-invasive tests⁸ and the high inducibility rate with programmed stimulation,¹⁶ we recommend performance of electrophysiological studies whenever idiopathic ventricular fibrillation is suspected. On the other hand, minor abnormalities in V1–V3 had little diagnostic value in our study. Thus the decision as to how aggressively to investigate a syncopal episode in a patient with no apparent heart disease should be based on a clinical impression and not on the presence (or absence) of these minor “pseudo-Brugada” signs.

Addendum

New evidence suggesting that flecainide administration is a sensitive and specific test for exposing the Brugada sign (among patients carrying genetic mutations for this

disease) was recently published by Brugada and colleagues.³⁵ This new evidence underscores the need for systematic performance of a “flecainide challenge” in patients with idiopathic ventricular fibrillation and apparently normal electrocardiogram, and in patients with questionable symptoms and a questionable Brugada sign.

- 1 Belhassen B, Shapira I, Shoshani D, *et al*. Idiopathic ventricular fibrillation: inducibility and beneficial effects of class I antiarrhythmic agents. *Circulation* 1987;75:809–16.
- 2 Brugada P, Brugada J. Right bundle branch block, persistent ST segment elevation and sudden cardiac death: a distinct clinical and electrocardiographic syndrome. A multicenter report. *J Am Coll Cardiol* 1992;20:1391–6.
- 3 Brugada J, Brugada P. Right bundle branch block and ST segment elevation in leads V1 through V3. A marker for sudden death in patients without demonstrable structural heart disease. *Circulation* 1998;97:457–60.
- 4 Gussak I, Antzelevitch C, Bjerregaard P, *et al*. The Brugada syndrome: clinical, electrophysiologic and genetic aspects. *Circulation* 1999;33:5–15.
- 5 Alings M, Wilde A. “Brugada” syndrome. Clinical data and suggested pathophysiological mechanism. *Circulation* 1999;99:666–73.
- 6 Miyazaki T, Mitamura H, Miyoshi S, *et al*. Autonomic and antiarrhythmic drug modulation of ST segment elevation in patients with Brugada syndrome. *J Am Coll Cardiol* 1996;27:1061–70.
- 7 Scheinman M. Is the Brugada syndrome a distinct clinical entity? *J Cardiovasc Electrophysiol* 1997;8:332–6.
- 8 Viskin S, Belhassen B. Idiopathic ventricular fibrillation. *Am Heart J* 1990;120:661–71.
- 9 Viskin S, Belhassen B. Polymorphic ventricular tachyarrhythmias in the absence of organic heart disease. Classification, differential diagnosis and implications for therapy. *Prog Cardiovasc Dis* 1998;41:17–34.
- 10 Consensus Statement of the Joint Committees of the Unexplained Cardiac Arrest Registry of Europe and of the Idiopathic Ventricular Fibrillation Registry in the United States. Survivors of out-of-hospital cardiac arrest with apparently normal heart. Need for definition and standardized clinical evaluation. *Circulation* 1996;95:265–72.
- 11 Viskin S, Belhassen B. Clinical problem solving: when you only live twice. *N Engl J Med* 1995;332:1221–5.
- 12 Belhassen B, Pelleg A, Miller HI, *et al*. Serial electrophysiological studies in a young patient with recurrent ventricular fibrillation. *PACE* 1981;4:92–9.
- 13 Belhassen B, Viskin S. Idiopathic ventricular tachycardia and fibrillation. *J Cardiovasc Electrophysiol* 1993;4:356–68.
- 14 Belhassen B, Viskin S. Management of idiopathic ventricular fibrillation: implantable defibrillators? Antiarrhythmic drugs? *ANE* 1998;3:125–8.
- 15 Belhassen B, Viskin S, Fish R, *et al*. Effects of electrophysiologic-guided therapy with class 1A antiarrhythmic drugs on the long-term outcome of patients with idiopathic ventricular fibrillation with or without the Brugada syndrome. *J Cardiovasc Electrophysiol* 1999;10:1301–12.
- 16 Brugada J, Brugada P. What to do in patients with no structural heart disease and sudden arrhythmic death? *Am J Cardiol* 1996;78(suppl 5A):69–75.
- 17 Viskin S, Lesh M, Eldar M, *et al*. Mode of onset of malignant ventricular arrhythmias in idiopathic ventricular fibrillation. *J Cardiovasc Electrophysiol* 1997;8:1115–20.
- 18 Martini B, Nava A, Thiene G, *et al*. Ventricular fibrillation without apparent heart disease: description of six cases. *Am Heart J* 1989;118:1203–9.
- 19 Corrado D, Nava A, Buja G, *et al*. Familial cardiomyopathy underlies syndrome of right bundle branch block, ST segment elevation and sudden death. *J Am Coll Cardiol* 1996;27:443–8.
- 20 Atarashi H, Ogawa S, Haruni K, *et al*. Characteristics of patients with right bundle branch block and ST-segment elevation in right precordial leads. *Am J Cardiol* 1996;78:581–3.
- 21 Gussak I, Bjerregaard P, Egan TE, *et al*. ECG phenomenon called the J wave. History, pathophysiology and clinical significance. *J Electrocardiol* 1995;28:49–58.
- 22 Yan G, Antzelevitch C. Cellular basis for the electrocardiographic J wave. *Circulation* 1996;93:372–9.
- 23 Chen Q, Kirsch G, Zhang D, *et al*. Genetic basis and molecular mechanism for idiopathic ventricular fibrillation. *Nature* 1998;392:293.
- 24 Nademane K, Veerakul G, Nimmannit S, *et al*. Arrhythmogenic marker for the sudden unexpected death syndrome in Thai men. *Circulation* 1997;96:2595–600.
- 25 Kasanuki H, Ohnishi S, Ohnishi M, *et al*. Idiopathic ventricular fibrillation induced with vagal activity in patients without obvious heart disease. *Circulation* 1997;95:2277–85.
- 26 Aponte G. The enigma of “Bangungut”. *Ann Intern Med* 1960;52:1258–63.
- 27 Baron R, Thacker S, Gorenkin L, *et al*. Sudden death among Southeast Asian refugees. An unexplained nocturnal phenomenon. *JAMA* 1983;250:2947–51.

- 28 Wever EFD, Hauer RNW, Oomen A, et al. Unfavorable outcome in patients with primary electrical disease who survived an episode of ventricular fibrillation. *Circulation* 1993;**88**:1021–9.
- 29 Rook MB, Alshinawi C, Groenewegen WA, et al. Human SCN5A gene mutations alter Na-current kinetics and associate with VF in patients without structural heart disease [abstract]. *Circulation* 1998;**98**(suppl D):468.
- 30 Alshinawi C, Mannens M, Wilde A. Mutations in the human cardiac sodium channel gene (SCN5A) in patients with Brugada's syndrome [abstract]. *Eur Heart J* 1998;**19**(suppl):78.
- 31 Roden DM, Wilde AAM. Drug-induced J-point elevation: a marker for genetic risk of sudden death or ECG curiosity? *J Cardiovasc Electrophysiol* 1999;**10**:219–23.
- 32 Fujiki A, Usui M, Nagasawa H, et al. ST segment elevation in the right precordial leads induced with class 1C antiarrhythmic drugs: insight into the mechanism of Brugada syndrome. *J Cardiovasc Electrophysiol* 1999;**10**:214–18.
- 33 Lemery R, Brugada P, Della Bella P, et al. Ventricular fibrillation in six adults without overt heart disease. *J Am Coll Cardiol* 1989;**13**:911–16.
- 34 Antzelevitch C. The Brugada syndrome. *J Cardiovasc Electrophysiol* 1998;**9**:513–16.
- 35 Brugada R, Brugada J, Antzelevitch C, et al. Sodium channel blockers identify risk for sudden death in patients with ST-segment elevation and right bundle branch block but structurally normal hearts. *Circulation* 2000;**101**:510–15.

IMAGES IN CARDIOLOGY

Apparent induction of ventricular tachycardia after “appropriate pacing” by an implantable dual chamber defibrillator: confusing ICD electrograms

A 38 year old man with a recent large anterior wall myocardial infarction had sustained monomorphic ventricular tachycardia with a rate of 142 beats/min causing palpitations and signs of congestive heart failure. A Biotronik Phylax AV dual chamber defibrillator (ICD) (Biotronik, Berlin, Germany) with a Kainox RV 75 electrode (Biotronik, Berlin, Germany) and a Medtronic model 4568 electrode (Medtronic Inc, Minneapolis, Minneapolis, USA) were implanted.

Two months after implantation he received his first shock. Endocardial electrograms suggested that the episode of ventricular tachycardia was initiated by a paced ventricular complex (the long downward spike in channel

1) following a sudden delay in the AV conduction. The tachycardia was detected by the ICD and antitachycardia pacing was given. The figure shows a stored endocardial electrogram—upper tracing: marker channel (atrial/ventricular); second tracing: atrial intracardiac electrogram; lower tracing: ventricular intracardiac electrogram. Sinus rhythm, cycle length 710 ms, with a sudden delay in the AV node (250 ms), a ventricular paced beat followed by ventricular tachycardia, cycle length 420 ms; A, artefact.

In the tracing an artefact in the lower ventricular electrogram (channel 3) falling before the P wave in the atrial electrogram (channel 2) is observed. As our patient had premature ventricular beats, we hypothesise that this artefact presumably represents a premature ventricular beat with an amplitude that is different from the preceding sinus beats and the beats during ventricular tachycardia. Its timing in the atrial and ventricular electrogram coincides perfectly with the ventricular tachycardia, and what we initially considered as a ventricular paced beat is probably a fusion of the ventricular pacing synchronous with the ventricular tachycardia, without an apparent reset of this tachycardia. Furthermore, it is not uncommon that sustained monomorphic ventricular tachycardia is initiated by beats with another morphology. Whether the electrogram really reflects the signals as recorded by the amplifiers can be discussed, they certainly misled us in our initial interpretation.

DOMINIC THEUNS
GEERT JAN KIMMAN
LUC JORDAENS

