

Assessment of the geometric profile of the Amplatzer and Cardioseal septal occluders by three dimensional echocardiography

P Acar, Z Saliba, P Bonhoeffer, D Sidi, J Kachaner

Abstract

Objective—To apply three dimensional echocardiography to describe the geometric profile of the Amplatzer and Cardioseal occluders after deployment for closure of atrial septal defect.

Methods—20 patients (mean (SD) age, 14 (5) years) were enrolled for transcatheter closure of a secundum atrial septal defect with the Amplatzer occluder (10) or with the Cardioseal occluder (10). The two populations were matched for the stretched diameter of the defect (mean 18 (6) mm). The profile of the two occluders was examined.

Results—Transoesophageal echocardiography did not show any residual shunts after Amplatzer occluder deployment, whereas three patients had a small residual leak after Cardioseal deployment. One patient had transient atrioventricular block with the Amplatzer device. The mean surface area of the Amplatzer occluder was 6.9 (2) cm², and that of the Cardioseal device 5.4 (3) cm² (p = 0.03). The mean volume of the Amplatzer occluder was 9.2 (1) cm³, while that of the Cardioseal occluder was 3.5 (1) cm³ (p < 0.0001). From the three dimensional views, the Cardioseal occluder looked like a flat square after deployment whereas the Amplatzer occluder took up a ball shape in the atrial cavity.

Conclusions—Three dimensional views by multiplane transoesophageal echocardiography allow a realistic in vivo description of atrial septal occluders. The Amplatzer occluder, with its high geometric profile, allows complete closure of large atrial septal defects but with some risk of mechanical complications. Use of the Cardioseal device, with its small surface coverage and high residual shunt rate, should be limited to transcatheter closure of a patent foramen ovale or small atrial septal defects.

(Heart 2001;85:451-453)

Keywords: atrial septal occluder; three dimensional echocardiography

**Services de
Cardiologie
Pédiatrique, Hôpital
Necker/Enfants-malades,
149 rue de Sèvres,
75743 Paris cedex 15,
France**
P Acar
Z Saliba
P Bonhoeffer
D Sidi
J Kachaner

Correspondence to:
Dr Acar
philippeacar@yahoo.fr

Accepted 13 December 2000

Although the low surgical mortality and morbidity associated with closure of atrial septal defects is generally accepted, transcatheter closure is becoming an attractive alternative, because it eliminates or reduces the risks and morbidity inherent in surgery. Several transcatheter techniques and devices have been developed for transcatheter occlusion of defects. In particular, the Amplatzer and Cardioseal occluders are commonly used for closing atrial septal defects, with a high success rate (fig 1).^{1,2} However, questions have been raised about the profiles of these devices, and mechanical complications have been reported after deployment of septal occluders.³

While it is difficult to visualise the occluder configuration with cross sectional echocardi-

graphy, three dimensional echocardiography allows en face views of intracardiac structures such as the atrial septum.⁴ Volumetric measurements are also possible using the three dimensional method.⁵ Our aim was to apply three dimensional echocardiography to describe the geometric profile of atrial septal occluders after deployment.

Methods

PATIENTS

Twenty patients referred for transcatheter closure of a secundum atrial septal defect were enrolled. Eight were male and 12 female. Their mean (SD) age was 14 (5) years, range 5-20 years. The atrial septal defect was closed with the Amplatzer occluder in 10 patients and with the Cardioseal occluder in the other 10. The two populations were matched for the stretched defect diameter, measured by the balloon transcatheter method.

THREE DIMENSIONAL ECHOCARDIOGRAPHIC ACQUISITION

Transoesophageal echocardiography with three dimensional reconstruction was performed under general anaesthesia after deployment of the septal occluder. The system consisted of a 5-7 Hz multiplane transoesophageal probe connected to an Acuson Sequoia C256 platform (Acuson, Mountain View, California, USA). This was linked to a three dimensional reconstruction system (Echo-scan, TomTec




Figure 1 Atrial septal occluders. The Cardioseal occluder (left) is a spring loaded Dacron double umbrella. The Amplatzer occluder (right) is a circular double disk frame with a conjoint waist made of nitinol windings.

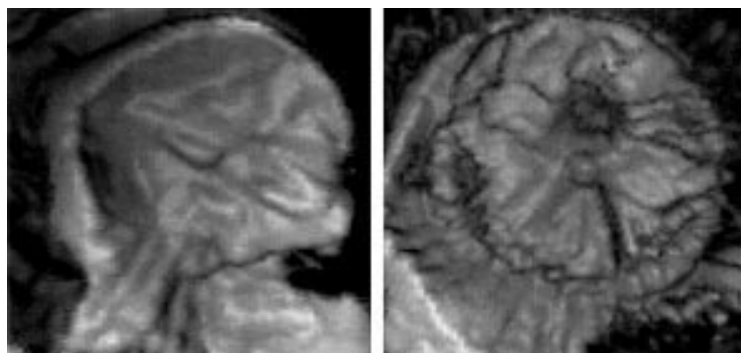


Figure 2 En face three dimensional views from the left atrium. The disk of the Cardioseal occluder (left) looks like a square and the four arms are applied to the left atrial side of the septum. The disk of the Amplatzer occluder (right) has a ball shape in the left atrial cavity.

GmbH, Munich, Germany). Multiplane transoesophageal echocardiography and three dimensional echocardiography were performed as previously described.⁶ The transoesophageal probe rotation was commanded by a steering logic for controlled image acquisition.

Electrocardiography and respiratory gating by thoracic impedance measurements ensured optimal spatial and temporal registration of the cardiac images. RR intervals were predetermined with a variability of 100 ms or less. Respiration was gated at the end expiratory phases.

The reference position was a basal transverse plane to visualise the long axis of the septal occluder. From this reference image, 90 sequential cross sections acquired every 2° were obtained, each during a complete cardiac cycle, and stored in the computer memory. On average, two acquisitions were obtained in each patient and the one with the least motion artefact was chosen for three dimensional measurements. The recorded images were formatted in their correct rotational sequence according to their ECG phase in volumetric datasets. Postprocessing of the datasets was performed off line, using the system's analysis program (Echo-view, TomTec). To fill the gaps in the far fields, a trilinear cylindrical interpolation algorithm was used.

DATA ANALYSIS

From the conical data volume, specific cut planes were used for three dimensional reconstructions to image the septal occluder en face from both the right and the left atrium. A transparency was placed over the extracted three dimensional image. The surface area of the septal occluder was traced using an off line measurement system (Freeland cine view, version 4, TomTec). The septal occluder was sliced into multiple equidistant parallel long axis views. The surface area of each cross section was measured by manual endocardial tracing and the volume of each slice calculated. The entire volume of the septal occluder was automatically derived by summing the volumes of each slice.⁵ All values used for comparison are reported as mean (SD). Unpaired *t* tests were used to analyse the grouped data. Significance is defined as $p < 0.05$.

Results

The mean (SD) stretched diameter was 18 (6) mm, range 12–25 mm. The Amplatzer septal occluder sizes were from 12 to 26 (equal to the stretched diameter), while the Cardioseal occluder sizes were from 23 to 40 (stretched diameter $\times 1.8$). Transoesophageal echocardiography did not show any residual shunt after deployment of the Amplatzer occluder, whereas three patients had a small residual leak (< 4 mm) around the Cardioseal device. One patient had a transient atrioventricular block after deployment of a size 26 Amplatzer device. No venous flow or valvar obstruction was observed.

En face three dimensional views of the septal occluder were obtained in all study patients, and it was possible to measure the surface area and the volume of the septal occluder. Acquisition time was within five minutes in all cases. The time needed for three dimensional measurements was 20 minutes.

The mean surface area of the Amplatzer septal occluder was 6.9 (2) cm² and of the Cardioseal occluder 5.4 (3) cm² ($p = 0.03$). The mean volume of the Amplatzer septal occluder was 9.2 (1) cm³, while that of the Cardioseal occluder was 3.5 (1) cm³ ($p < 0.0001$). From the three dimensional views, the Cardioseal occluder after deployment looked like a flat square (fig 2), while the Amplatzer occluder took up a ball shape in the atrial cavity.

Discussion

This study shows that three dimensional views of atrial septal occluders by multiplane transoesophageal echocardiography provide realistic visualisation of the deployment of the occluder in the atrial cavity. Measurements of the surface area and volume of the septal occluder are possible using the three dimensional method.

This study is the first to report the profile of the Amplatzer occluder from three dimensional views. The volumetric data measured by the extracted three dimensional images confirmed its high geometrical profile. Mechanical complications such as atrioventricular block or superior vena caval obstruction have been reported after deployment of the Amplatzer occluder.³ (In our small series we observed one transient atrioventricular block after deployment of a size 26 Amplatzer device.) These complications could be explained by the relatively large volume of the device, which may compress the atrioventricular node or obstruct venous flow. The mitral valve might also be compromised after deployment of the Amplatzer occluder.⁷ Fortunately the Amplatzer device was designed to be easily retrievable until released from the delivery wire, thereby allowing removal in the event of malpositioning. The large surface area covered by this device contributed to the very small amount of residual shunting. European series reported occlusion rates of at least 97% at three months.^{1 3 7} Despite its high geometric profile, the Amplatzer occluder is the preferred device in many institutions because of its ease of

handling. Moreover, it allows closure of large atrial septal defects (over 25 mm diameter).⁸

Other studies have reported three dimensional reconstructions of septal occluders of the double umbrella type, such as Das-Angel wings and the Cardioseal device.⁹⁻¹⁰ Transcatheter occlusion with the Cardioseal has several difficulties. The delivery technique is complicated and the device is not easily retrievable. Moreover, after deployment the rate of residual shunting is high.² This may be explained by the small surface area covered by the occluder. The absence of a self centring mechanism also increases the risk of incomplete closure. The new flexible, self centring device (the Starflex occluder) may improve the rate of total occlusion.¹¹ The use of these double umbrella occluders should be limited to the transcatheter closure of patent foramina ovale or small atrial septal defects.

Selection of patients for transcatheter closure of atrial septal defects requires accurate information about the anatomy of the defect. Exact measurements of its maximum diameter and of the size of the circumferential tissue rim allows one to choose the most suitable device for transcatheter closure. On three dimensional echocardiography, secundum atrial septal defects are seen to be complex structures.¹² From three dimensional views, variations in shape and changes in the surface area of the defect during the cardiac cycle have been reported.¹³⁻¹⁴ Three dimensional echocardiography has enhanced our understanding of the anatomy and pathophysiology of secundum atrial septal defects. En face three dimensional views can reveal the occluder profile in vivo. However, a decrease in the time required for three dimensional reconstruction and measurement is needed to make clinical application easier.

Several potential problems in the three dimensional reconstructions need to be addressed. From these reconstructions, atrial septal occluders often appeared to be thicker than they actually are, with decreased resolution. This is in part related to a spatial volume artefact and slow frame rates. The ability to make three dimensional reconstructions directly from the digital images without transformation into video signals would improve the quality of the images, which is still very dependent on the gain settings.

Our study is limited by the small number of patients and the range of devices. Further studies, including a larger population, would be helpful to determine whether the three dimensional reconstructions are predictive of device success, complications, or failure in a given

patient, in relation to the size of the atrial septal defect or its proximity to surrounding structures. However, three dimensional views by multiplane transoesophageal echocardiography allow a realistic in vivo description of the atrial septal occluder. The Amplatzer occluder, with its high geometric profile, allows complete closure of large atrial septal defects but with some risk of mechanical complications. Use of the Cardioseal device, with its rather small surface coverage and high rate of residual shunting, should be limited to the transcatheter closure of a patent foramen ovale or small atrial septal defects.

In conclusion, three dimensional echocardiography is an important technique in future initiatives to develop transcatheter devices for closing defects.

- Berger F, Ewert P, Bjornstad PG, *et al.* Transcatheter closure as standard treatment for most interatrial defects: experience in 200 patients treated with the Amplatzer septal occluder. *Cardiol Young* 1999;9:468-73.
- Kaulitz R, Paul T, Hausdorf G. Extending the limits of transcatheter closure of atrial septal defects with the double umbrella device (CardioSEAL). *Heart* 1998;80:54-9.
- Chan KC, Godman MJ, Walsh K, *et al.* Transcatheter closure of atrial septal defect and interatrial communications with a new self expanding nitinol double disc device (Amplatzer septal occluder): multicentre UK experience. *Heart* 1999;82:300-6.
- Marx GR, Fulton DR, Pandian NG, *et al.* Delineation of site, relative size and dynamic geometry of atrial septal defect by real-time three-dimensional echocardiography. *J Am Coll Cardiol* 1995;25:482-90.
- Acar P, Maunoury C, Antonietti T, *et al.* Left ventricular ejection fraction in children measured by three-dimensional echocardiography using a new transthoracic integrated 3D-probe. A comparison with equilibrium radionuclide angiography. *Eur Heart J* 1998;19:1583-8.
- Acar P, Laskari C, Rhodes J, *et al.* Determinants of mitral regurgitation after atrioventricular septal defect surgery: a three-dimensional echocardiographic study. *Am J Cardiol* 1999;83:745-9.
- Fischer G, Kramer HH, Stieh J, *et al.* Transcatheter closure of secundum atrial septal defects with the new self-centering Amplatzer septal occluder. *Eur Heart J* 1999;20:541-9.
- Dhillon R, Thanopoulos B, Tsaousis G, *et al.* Transcatheter closure of atrial septal defects in adults with the Amplatzer septal occluder. *Heart* 1999;82:559-62.
- Magni G, Hijazi Z, Pandian NG, *et al.* Two- and three-dimensional transoesophageal echocardiography in patient selection and assessment of atrial septal defect closure by the new DAS-Angel wings device. *Circulation* 1997;96:1722-8.
- Maeno Y, Benson LN, Boutin C. Impact of dynamic 3D transoesophageal echocardiography in the assessment of atrial septal defects and occlusion by the double-umbrella device (CardioSEAL). *Cardiol Young* 1998;8:368-78.
- Hausdorf G, Kaulitz R, Paul T, *et al.* Transcatheter closure of atrial septal defect with a new flexible, self-centering device (the Starflex occluder). *Am J Cardiol* 1999;84:1113-16.
- Acar P, Saliba Z, Bonhoeffer P, *et al.* Influence of atrial septal defect anatomy in patient selection and assessment of closure with the Cardioseal device. *Eur Heart J* 2000;21:573-81.
- Franke A, Kühl HP, Rulands D, *et al.* Quantitative analysis of the morphology of secundum-type atrial septal defects and their dynamic change using transoesophageal three-dimensional echocardiography. *Circulation* 1997;96(suppl II):323-7.
- Dall'Agata A, McGhie J, Taams MA, *et al.* Secundum atrial septal defect is a dynamic three-dimensional entity. *Am Heart J* 1999;137:1075-81.