

Dobutamine stress echocardiography versus quantitative technetium-99m sestamibi SPECT for detecting residual stenosis and multivessel disease after myocardial infarction

P Lancellotti, T Benoit, P Rigo, L A Pierard

Abstract

Objective—To compare the relative accuracy of dobutamine stress echocardiography (DSE) and quantitative technetium-99m sestamibi single photon emission computed tomography (mibi SPECT) for detecting infarct related artery stenosis and multivessel disease early after acute myocardial infarction.

Design—Prospective study.

Setting—University hospital.

Methods—75 patients underwent simultaneous DSE and mibi SPECT at (mean (SD)) 5 (2) days after a first acute myocardial infarct. Quantitative coronary angiography was performed in all patients after imaging studies.

Results—Significant stenosis (> 50%) of the infarct related artery was detected in 69 patients. Residual ischaemia was identified by DSE in 55 patients and by quantitative mibi SPECT in 49. The sensitivity of DSE and mibi SPECT for detecting significant infarct related artery stenosis was 78% and 70%, respectively, with a specificity of 83% for both tests. The combination of DSE and mibi SPECT did not change the specificity (83%) but increased the sensitivity to 94%. Mibi SPECT was more sensitive than DSE for detecting mild stenosis (73% *v* 9%; *p* = 0.008). The sensitivity of DSE for detecting moderate or severe stenosis was greater than mibi SPECT (97% *v* 74%; *p* = 0.007). Wall motion abnormalities with DSE and transient perfusion defects with mibi SPECT outside the infarction zone were sensitive (80% *v* 67%; NS) and highly specific (95% *v* 93%; NS) for multivessel disease.

Conclusions—DSE and mibi SPECT have equivalent accuracy for detecting residual infarct related artery stenosis of $\geq 50\%$ and multivessel disease early after acute myocardial infarction. DSE is more predictive of moderate or severe infarct related artery stenosis. Combined imaging only improves the detection of mild stenosis.

(Heart 2001;86:510-515)

Keywords: myocardial infarction; dobutamine echocardiography; single photon emission computed tomography; SPECT; myocardial ischaemia

The detection of residual ischaemia in the infarct zone and the presence of multivessel disease early after acute myocardial infarction is clinically important so as to identify patients at high risk of future cardiac events and to select those who should benefit from a revascularisation procedure.^{1,2} Several non-invasive methods can be used for detecting jeopardised myocardium. An exercise ECG is the most commonly used test, but its diagnostic accuracy is limited.³ Combined dynamic exercise and thallium-201 scintigraphy is a more accurate technique for identifying residual ischaemia.⁴ However, maximum exercise testing is not feasible in many patients surviving acute myocardial infarction because of physical constraints.⁵ Both dobutamine stress echocardiography (DSE) and technetium-99m sestamibi single photon emission computed tomography (mibi SPECT) are now widely used as alternative methods in the diagnosis and functional evaluation of coronary artery disease, with or without acute myocardial infarction.⁶⁻⁹ However, the ability of these techniques to predict residual stenosis of the infarct related artery and the presence of

multivessel disease early after acute myocardial infarction has not been compared.

Our aims in this study were first, to investigate the relative accuracy of DSE and quantitative mibi SPECT for detecting residual infarct related artery stenosis early after acute myocardial infarction; second, to investigate their relative value for identifying multivessel disease; and third, to determine whether the combination of both techniques could increase diagnostic accuracy.

Methods

PATIENTS

The study population consisted of a series of 88 consecutive patients admitted for a first non-complicated acute myocardial infarct. Acute myocardial infarction was suspected on the basis of chest pain lasting more than 30 minutes with acute ST segment deviation of ≥ 1 mm in two or more leads on the initial ECG, confirmed by a typical increase and decrease in serum creatine kinase and MB fraction concentrations. All patients gave informed consent, and the study was approved by the institutional ethics committee.

Division of Cardiology
University Hospital of
Liège, B-4000 Liège,
Belgium
P Lancellotti
L A Pierard

Division of Nuclear
Medicine, University
Hospital of Liège
T Benoit
P Rigo

Correspondence to:
Dr Pierard
lpierard@chu.ulg.ac.be

Accepted 25 July 2001

The patients underwent simultaneous DSE and mibi SPECT at (mean (SD)) 5 (2) days after acute myocardial infarction and before coronary angiography. None of these selected patients had any of the following exclusion criteria: intraventricular conduction defect, valvular or cardiomyopathic heart disease, overt heart failure or contraindications to dobutamine infusion including postinfarction angina, major ventricular arrhythmias, or severe systemic hypertension. Nine patients were excluded for non-interpretable scintigraphic ($n = 5$) or echocardiographic ($n = 4$) findings, and four other patients were excluded for technical reasons. The final study consisted of the remaining 75 patients.

DOBUTAMINE STRESS TEST

β Adrenergic blocking agents were withdrawn 48 hours before the study. Dobutamine was infused intravenously, starting at a dose of 5 $\mu\text{g}/\text{kg}/\text{min}$, increasing to 10 $\mu\text{g}/\text{kg}/\text{min}$ after three minutes), and then by 10 $\mu\text{g}/\text{kg}/\text{min}$ every three minutes up to 40 $\mu\text{g}/\text{kg}/\text{min}$. Atropine (0.25 mg to a maximum dose of 1 mg) was added if the target heart rate of 85% of the age predicted maximum heart rate was not achieved. End points for dobutamine infusion were: target heart rate, maximum dose, chest pain, ≥ 2 mm ST segment depression in two or more ECG leads, significant arrhythmias, severe hypertension (systolic blood pressure > 230 mm Hg), or hypotension (a fall in systolic blood pressure of > 30 mm Hg). The ECG was monitored continuously throughout the test and recorded at each stage. Blood pressure was measured at each stage by arm cuff sphygmomanometry.

STRESS ECHOCARDIOGRAPHY

All echocardiograms were digitised on-line on optical disks and displayed side by side in a quad screen format (Vingmed CFM 800 or System Five, General Electric Ultrasound, Belgium). Parasternal long and short axis and apical long axis four chamber and two chamber views were analysed. Images were interpreted qualitatively by two experienced observers who were unaware of the clinical, scintigraphic, and angiographic data. For both rest and stress studies, the left ventricular wall was divided into 16 segments and scored using a four point scale: 1, normal; 2, hypokinesis; 3, akinesis; 4, dyskinesis. The vascular distribution of segments was defined according to a previously described technique.¹⁰ Four different echocardiographic responses were identified:

- *sustained improvement*, when improvement in contractility was observed in dyssynergic segments until peak dose without deterioration
- a *biphasic response*, defined as an initial improvement in contractility score by ≥ 1 point in the infarct area at low dose dobutamine, followed by subsequent worsening at high dose
- *worsening in the adjacent area*, corresponded to the development of new dyssynergy in two or more segments adjacent to the infarcted

zone, with no change in the affected segments

- *akinesis without change*, defined as no change in basal asynergy throughout dobutamine test.

A patient was considered to have a contractile reserve on dobutamine echocardiography if wall thickening improved in two or more contiguous segments. A biphasic response and worsening in the adjacent area were the criteria for residual stenosis in the infarct related artery. Multivessel disease was defined as abnormal wall thickening in two or more contiguous segments in one or more remote vascular territories. Follow up resting ECGs were obtained 2 (1.5) months after the acute event in all patients, and functional recovery was considered to be present when the wall thickening score increased by at least one point in two contiguous segments of the affected area.

SCINTIGRAPHIC PERFUSION IMAGING

An injection of 20 mCi of technetium-99m ($^{99\text{m}}\text{Tc}$) sestamibi was given one minute before the end of the dobutamine infusion to allow tracer uptake under optimal stress conditions. Tomographic imaging was performed 60–90 minutes after the injection using a 90° dual head gamma camera (Sopha DST, General Electric Medical System Benelux) equipped with high resolution collimators.

Thirty two projections were acquired for 30 seconds per view over a 180° arc from left posterior oblique to right anterior oblique. A 20% energy window was used, centred on the 140 KeV $^{99\text{m}}\text{Tc}$ photopeak. Images were collected in a 64 \times 64 matrix. Particular care was taken to avoid patient motion as well as overlap from extracardiac activity. A rest study was done on a separate day, 60–290 minutes after the injection of 20 mCi of $^{99\text{m}}\text{Tc}$ and using 40 seconds per view. Image reconstruction was performed using a filtered back projection and a Butterworth filter, order 6, cut off frequency 0.25 cycle/pixel. Data were not corrected for scatter or attenuation. Images were reoriented to provide horizontal long axis, vertical long axis, and short axis slices according to the guidelines of the joint American Heart Association/American College of Cardiology task force.¹¹

Radial slices and polar maps were also produced using quantitative analysis software validated in our institution.¹² This software first creates 16 oblique long axis slices at different fixed angles around the left ventricular long axis taken as the rotation axis. A 360° elliptical sampling of the 16 radial slices is then used to produce a summary polar map. The polar map was subsequently divided in 16 segments corresponding to the echocardiographic segmentation of the heart used for comparative analysis. The posterior intersection of the right and left ventricles—the posterior interventricular groove—was used as an anatomical landmark to ensure reliable correspondence between SPECT and echocardiographic segmentation. Quantitation of this map was done by comparison with a $^{99\text{m}}\text{Tc}$ sestamibi

database of normal subjects. The threshold for perfusion abnormality was fixed pixel by pixel as the normal mean value minus 2.5 SD. In abnormally perfused areas, perfusion defect surface and severity were calculated, as well as a hypoperfusion index (hypoperfusion defect surface \times mean severity) which reflects the fractional mass of hypoperfused, ischaemic, or necrotic myocardium as per cent of the total extrapolated myocardial mass.

Interacquisition and interobserver reproducibility values for the index measurement have been described previously.¹² To detect the presence and location of ischaemic perfusion changes, dobutamine and rest tomograms were compared using the quantitative analysis software. According to the determined reproducibility of the index measurement, ischaemia was considered significant when the difference between stress and rest indices exceeded 10% in the peri-infarction area supplying by the infarct related artery, or in one or more remote vascular territories for the detection of multivessel disease.

ANGIOGRAPHY

Quantitative coronary angiography and left ventriculography were performed in all patients within one week after the DSE and mibi SPECT studies. All films were analysed using the cardiovascular medical system (CMS). All measurements were performed from end diastolic frames with optimal vessel opacification. Coronary stenoses were considered significant when there was $\geq 50\%$ luminal diameter stenosis. The infarct related artery was identified on the basis of lesion morphology, and the location of acute ECG changes and wall motion abnormalities on echocardiography and contrast ventriculography. Stenosis severity of the infarct related artery was graded as insignificant ($< 50\%$), mild (50–59%), moderate (60–69%), or severe (70–99%) stenosis. In the presence of an occluded infarct related artery, collateral circulation was classified as present or absent. Elective coronary angioplasty was performed in the presence of significant stenosis. The results of DSE and mibi SPECT were not used in this decision.

STATISTICAL ANALYSIS

Data are expressed as mean (SD). Continuous variables were tested by the Student *t* test and nominal findings by a χ^2 test or Fisher's exact test, depending on the sample size. Significance was defined as a two tailed probability value of $p \leq 0.05$. Sensitivity and specificity of DSE and mibi SPECT for detecting significant residual stenosis and multivessel disease were obtained according to standard definitions.

Results

CLINICAL AND ANGIOGRAPHIC CHARACTERISTICS

There were 61 men and 14 women, with a mean age of 56 (11) years (range 33–82 years). Thrombolytic agents were infused in 54 patients. Q waves evolved in 51 patients. Mean global left ventricular ejection fraction on angiography was 53 (16)%. The infarct related

artery was the left anterior descending coronary artery in 32 patients, the left circumflex coronary artery in 13, and the right coronary artery in 30. The infarct related artery was occluded in 20 patients, and a collateral circulation was present in 13. In only six patients was the infarct related artery not significantly narrowed. The infarct related artery stenosis was mild (50–59%) in 11 patients, moderate (60–69%) in 21, and severe ($\geq 70\%$) in 17. Elective coronary angioplasty was performed in 35 patients. Multivessel disease was present in 15 patients, including 11 with two vessel disease and four with three vessel disease.

DOBUTAMINE STRESS TESTING

Heart rate and systolic blood pressure increased significantly from rest to peak stress, from 76 (14) to 147 (29) beats/min, and from 131 (23) to 151 (28) mm Hg, respectively ($p < 0.001$ for both). The target heart rate was obtained in 56 of 75 patients. During stress test, chest pain occurred in 12 patients, supraventricular tachycardia in three, and non-sustained ventricular tachycardia in two. Twenty seven patients had significant ST segment depression and 21 had ST segment elevation in the infarct related leads. There were no clinical complications as a result of dobutamine stress testing.

ECHOCARDIOGRAPHY AND MIBI SPECT DURING DOBUTAMINE STRESS

During DSE, residual ischaemia was observed in 55 patients: 37 developed a biphasic response and 18 showed worsening in the adjacent area. Sustained improvement was observed in 10 patients and akinesis without change in 15. All but three patients had an abnormal mibi SPECT result at rest. In the infarcted area, mean perfusion defect surface and severity were 34 (23)% and 43 (12)%, respectively. Mean hypoperfusion index was 14 (11)%. Ischaemia was detected in 49 of 75 patients (65%). According to the definition, hypoperfusion index increased significantly from rest (11 (10)%) to peak stress (16 (12)%) in these patients ($p = 0.018$).

DETECTION OF SIGNIFICANT RESIDUAL STENOSIS OF THE INFARCT RELATED ARTERY

Table 1 shows the accuracy of clinical variables, dobutamine stress ECG, DSE, and mibi SPECT for detecting significant infarct related artery stenosis. Both imaging methods were more sensitive than the occurrence of dobutamine induced chest pain or ECG changes ($p < 0.0001$). DSE and mibi SPECT had similar sensitivity: 78% (54 of 69) and 70% (48 of 69), respectively. With DSE, a biphasic response was more sensitive than worsening in the adjacent area: 54% *v* 25% ($p < 0.001$). The combination of DSE and mibi SPECT increased the sensitivity to 94% (65 of 69): $p = 0.01$ *v* DSE alone; $p = 0.0003$ *v* mibi SPECT alone. The specificity remained 83% (five of six). The accuracy of combined imaging methods for detecting significant stenosis of the infarct related artery was high (93%).

Table 1 Accuracy of clinical, ECG, DSE, and mibi SPECT for the detection of $\geq 50\%$ diameter stenosis of the infarct related artery

| Variables | Sensitivity (% (n)) | Specificity (% (n)) | Accuracy (%) |
|---|---------------------|---------------------|--------------|
| Number of patients | 69 | 6 | 75 |
| Chest pain (n=12) | 16 (11) | 83 (5) | 21 |
| ST depression (n=27) | 33 (23) | 67 (4) | 36 |
| ST elevation (n=21) | 25 (17) | 67 (4) | 28 |
| Biphasic response on DSE (n=37) | 54 (37) | 100 (6) | 57 |
| Worsening in adjacent area on DSE (n=18) | 25 (17) | 83 (5) | 29 |
| Infarct zone ischaemia on DSE (n=55) | 78 (54) | 83 (5) | 79 |
| Infarct zone ischaemia on mibi SPECT (n=49) | 70 (48) | 83 (5) | 71 |
| Combined DSE and mibi SPECT | 94 (65) | 83 (5) | 93 |

DSE, dobutamine stress echocardiography; mibi SPECT, ^{99m}Tc sestamibi single photon emission computed tomography; n, number of true positive (sensitivity column) and true negative (specificity column) values.

Table 2 Agreement of mibi SPECT and DSE in patients with $\geq 50\%$ diameter stenosis of the infarct related artery in predicting functional recovery

| | Mibi SPECT | |
|-------|------------|----|
| | + | - |
| DSE + | 24 | 13 |
| DSE - | 5 | 3 |

Agreement = 60%; $\kappa = 0.56$.

DSE, dobutamine stress echocardiography; mibi SPECT, ^{99m}Tc sestamibi single photon emission computed tomography.

FUNCTIONAL RECOVERY OF ISCHAEMIC MYOCARDIUM

During follow up, no cardiac event was registered. Functional recovery occurred in 45 of 69 patients (65%) with significant infarct related artery stenosis. Among these patients, ischaemic myocardium was found in 37 (82%) by DSE and in 29 (64%) by mibi SPECT. Agreement of mibi SPECT and DSE in these patients for predicting functional recovery was good (60%; $\kappa = 0.56$) (table 2). Elective coronary angioplasty was more often performed in patients with functional recovery (28 of 45, 62%) than in those without (seven of 24, 29%) ($p = 0.02$).

ROLE OF INFARCT RELATED ARTERY STENOSIS SEVERITY

Table 3 presents four groups of patients ranged according to the severity of their infarct related artery stenosis as defined above: mild (50–59%), moderate (60–69%), or severe stenosis (70–99%), and occluded artery. Both hypoperfusion index and wall motion score index at

Table 3 Comparison between patients with and without infarct related coronary artery occlusion

| | Mild stenosis, 50–59% (n=11) | Moderate stenosis, 60–69% (n=21) | Severe stenosis, 70–99% (n=17) | Occluded artery (n=20) |
|---------------------------------|------------------------------|----------------------------------|--------------------------------|------------------------|
| DSE | | | | |
| Wall motion score index at rest | 1.29 (0.12) | 1.35 (0.16) | 1.46 (0.13) | 1.47 (0.22) |
| Sustained improvement | 6 (55%) | 0 (0%) | 0 (0%) | 1 (5%) |
| Biphasic response | 1 (9%) | 18 (86%) | 12 (71%) | 6 (30%) |
| Worsening in adjacent area | 0 (0%) | 3 (14%) | 4 (24%) | 10 (50%) |
| Akinesis without change | 4 (36%) | 0 (0%) | 1 (6%) | 3 (15%) |
| Residual ischaemia | 1 (9%) | 21 (100%) | 16 (94%) | 16 (80%) |
| Mibi SPECT, rest | | | | |
| Mean severity (%) | 32 (8) | 28 (14) | 38 (11) | 38 (11) |
| Defect surface (%) | 27 (18) | 25 (22) | 42 (23) | 43 (22) |
| Hypoperfusion index (%) | 7 (5) | 9 (11) | 18 (14) | 18 (11) |
| Index difference | 8 (13) | 6 (5) | 4 (3) | 5 (2) |
| Residual ischaemia | 8 (73%) | 17 (81%) | 11 (65%) | 12 (60%) |

Values are mean (SD) or n (%).

DSE, dobutamine stress echocardiography; mibi SPECT, ^{99m}Tc sestamibi single photon emission computed tomography.

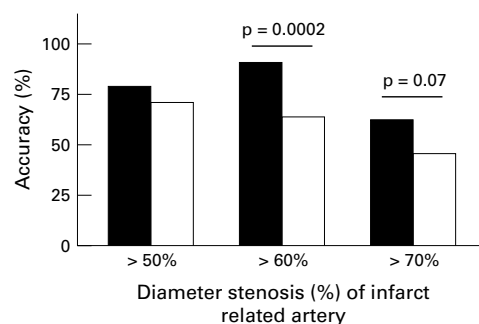


Figure 1 Bar graph showing accuracy of quantitative ^{99m}Tc sestamibi single photon emission computed tomography (mibi SPECT) and dobutamine stress echocardiography (DSE) for detecting residual infarct related artery stenosis, using different cut off values (50%, 60%, 70%). Black bars, residual ischaemia on DSE; white bars, residual ischaemia on mibi SPECT.

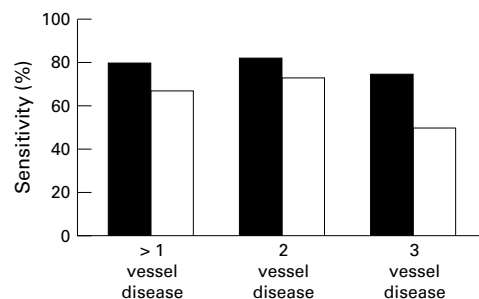


Figure 2 Bar graph showing sensitivity of quantitative ^{99m}Tc sestamibi single photon emission computed tomography (mibi SPECT) and dobutamine stress echocardiography (DSE) for detecting multivessel disease. Black bars, residual ischaemia on DSE; white bars, residual ischaemia on mibi SPECT.

rest were significantly lower in mild (7 (5%); 1.29 (0.12)) and moderate stenosis (9 (11%); 1.35 (0.16)) than in severe stenosis (18 (14%); 1.46 (0.13)) or occluded artery (18 (11%); 1.47 (0.22)) ($p < 0.05$). However, the index difference was homogeneously distributed in each subgroup without statistical differences. The sensitivity of mibi SPECT for detecting mild stenosis was 73%, compared with only 9% by DSE ($p = 0.008$). The sensitivity for detecting moderate or severe stenosis was significantly higher with DSE (97%) than with mibi SPECT (74%): $p = 0.007$. The accuracy of the two imaging methods is presented in fig 1 in relation to different cut off values of the residual stenosis (50%, 60%, or 70%). The accuracy of DSE was superior to that of mibi SPECT only for a 60% cut off value, at 91% v 64% ($p = 0.0002$).

DETECTION OF MULTIVESSEL DISEASE

Wall motion abnormalities on DSE and perfusion defects on mibi SPECT outside the infarct area (more than one coronary territory) were highly specific (57 of 60 (95%) v 56 of 60 (93%); NS) and sensitive (12 of 15 (80%) v 10 of 15 (67%); NS) for multivessel disease detection (fig 2). Nine of 11 patients with two vessel disease and three of four patients with triple vessel disease were correctly identified by DSE, versus eight of 11 and two of four, respectively, by mibi SPECT. Combined imaging did not improve either the sensitivity (13 of 15 (87%))

or the specificity (58 of 60 (97%)) for the detection of multivessel disease.

Discussion

Recent reports indicate that residual stenosis of the infarct related artery is common after acute myocardial infarction.^{13,14} Patients with a significant residual coronary stenosis after thrombolytic treatment represent a high risk subgroup for recurrent ischaemia and reocclusion.^{1,2} Early detection of these patients is therefore of clinical importance for selecting those who may benefit most from early revascularisation of the infarct related artery. The present study assessed the relative accuracy of echocardiography and mibi SPECT performed during the dobutamine stress test, and the potential value of combined imaging, for predicting residual stenosis of the infarct related artery and the presence or absence of multivessel disease within the first week after acute myocardial infarction.

Our results can be summarised as follows:

- the overall accuracy of the imaging modes for predicting the residual infarct related artery stenosis was similar when the cut off value of $\geq 50\%$ diameter stenosis was used
- the sensitivity of mibi SPECT was better for detecting mild stenosis, while the sensitivity of DSE was better for detecting moderate or severe stenosis
- combined imaging only improved the detection of mild stenosis
- the accuracy of the two methods was not different for predicting multivessel disease, and the combination of the two methods did not enhance the accuracy of either method alone.

DETECTION OF SIGNIFICANT INFARCT RELATED ARTERY STENOSIS

Whether or not additional ischaemia develops after acute myocardial infarction is dependent on the extent and completeness of the necrosis. Less residual ischaemia should be expected with greater infarct size. In our population, infarct size was relatively small, as suggested by the high incidence of functional recovery; this may lead to easier detection of peri-infarction ischaemia by both the imaging techniques assessed. We found that dobutamine echocardiography and mibi SPECT imaging had equivalent sensitivity (78% *v* 70%) and similar specificity (83%) for detecting significant infarct related artery stenosis. Our DSE results are comparable with previous studies performed in acute myocardial infarction.^{9,15} The sensitivity of mibi SPECT for detecting residual stenosis was higher than recently reported,^{16,17} perhaps because of the use of quantitative analysis. Indeed, as previously described in our laboratory,¹² the use of the hypoperfusion index—combining defect extent and severity—allows a more accurate definition of the infarct size, provides a more reproducible criterion for distinguishing normal and abnormal regions, and improves the diagnosis of ischaemia.

EFFECTS OF THE SEVERITY OF INFARCT RELATED ARTERY STENOSIS

The sensitivity for detecting an infarct related artery with mild stenosis was only 9% with DSE but 73% with mibi SPECT. These results may be explained by the different pathophysiological basis of the two imaging techniques. Flow heterogeneity induced by stress in the territory of a mild stenosis can be detectable with mibi SPECT but is insufficient to induce echocardiographically detectable ischaemia. Mibi uptake plateaus when blood flow reaches 2.5 times the normal flow and underestimates high coronary flow.¹⁸ Compared with adenosine, dobutamine produces a smaller increase in flow. Thus dobutamine stress may cause flow heterogeneity over a range in which mibi uptake remains proportional to flow, leading to adequate detection of mild coronary stenoses. The low sensitivity of mibi SPECT in patients with 70–100% infarct related artery stenosis could be related to extensive necrosis with a more severe resting hypoperfusion index, limiting detectable extension of the perfusion defect during stress. Contractile recovery was observed at follow up in 11 of 14 patients with 70–100% stenosis and negative SPECT, indicating that these results were not related to transmural infarction. The failure to diagnose severe stenosis in the absence of extensive necrosis in these patients may be related to more severe resting wall motion abnormality in the affected area; this may render the myocardium thinner, resulting in “partial volume” effect with the appearance of severe hypoperfusion. When flow reserve is absent, the myocardium fails to respond to dobutamine.¹⁹ This may explain some false negative DSE results in the presence of critical stenosis or an occluded infarct related artery. In such myocardial regions, restricted blood flow with no flow reserve may induce regional supply–demand imbalance with impairment of cell metabolic activity.

DETECTION OF MULTIVESSEL DISEASE

The sensitivity of DSE (80%) and dobutamine mibi SPECT (67%) for identifying patients with multivessel coronary artery disease in our study was similar to the values reported by Elhendy and colleagues (80% and 78%, respectively).¹⁶ In a previous study from our laboratory,²⁰ we found a similar sensitivity (85%) of DSE for detecting multivessel disease. The sensitivity of dobutamine mibi SPECT in the present study is similar to that observed by Mahmarian and colleagues (69%)²¹ using adenosine thallium SPECT. Several factors may contribute to the failure of DSE or mibi SPECT to identify induced ischaemia in remote territories in some patients. Complex coronary stenosis of the infarct related artery is found in the majority of patients with acute myocardial infarction.²² The results of DSE are influenced by stenosis severity but more importantly by plaque morphology.²³ Moreover, not all vessels with a diameter stenosis of $> 50\%$ have an abnormal flow reserve.²⁴ Normal mibi SPECT during

dobutamine stress may reflect too low perfusion heterogeneity during stress. Gould has previously shown that a flow disturbance ratio of 2:1 is required to be detected by scintigraphy.²⁵

STUDY LIMITATIONS

Several limitations of our study deserve further consideration.

First, myocardial ischaemia detected during dobutamine stress imaging was used to predict the presence or absence of significant coronary stenosis. However, coronary angiography does not always reflect the functional significance of a coronary artery stenosis.

Second, the quantitative SPECT analysis has potential limitations¹² such as surface distortion, background correction, and the use of mean normal values. We did not distinguish between visual and quantitative perfusion imaging analysis in this study. We showed in a previous study that myocardial infarct size was best defined by using a hypoperfusion index.¹² However, the ischaemic threshold selected in this study may have underestimated the myocardium at jeopardy.

Third, patients with complete myocardial infarction were not excluded from analysis and this may explain in part some negative DSE and mibi SPECT studies. Unchanged wall motion was considered to indicate significant residual stenosis by Takeuchi and colleagues.¹⁵ Because of the high incidence of residual stenosis after acute myocardial infarction, the inclusion of this criterion in their study tended to inflate values for sensitivity of DSE.

Fourth, the small number of patients with non-significant residual stenosis may preclude an accurate estimation of specificity.

Finally, DSE interpretation was made qualitatively, but this analysis remains the standard. Quantitative methods such as Doppler myocardial imaging or colour kinesis are being developed, but are not yet validated.

CONCLUSIONS

Our results suggest that dobutamine stress echocardiography and mibi SPECT have equivalent accuracy for detecting residual infarct related artery stenosis of $\geq 50\%$ and the presence of multivessel disease early after acute myocardial infarction. DSE is more predictive of moderate or severe infarct related artery stenosis. Combined imaging only improves the detection of mild stenosis.

- 1 Brown KA, Weiss RM, Clemens JP, *et al.* Usefulness of residual ischemic myocardium within prior infarct zone for identifying patients at high risk late after acute myocardial infarction. *Am J Cardiol* 1987;**60**:15-19.
- 2 Multicenter Postinfarction Research Group. Risk stratification and survival after myocardial infarction. *N Engl J Med* 1983;**309**:331-6.
- 3 Theroux P, Waters DD, Halphen C, *et al.* Prognostic value of exercise testing soon after myocardial infarction. *N Engl J Med* 1979;**301**:341-5.
- 4 Gibson RS, Watson DD, Craddock GB, *et al.* Prediction of cardiac events after uncomplicated myocardial infarction: a prospective study comparing pre-discharge exercise thallium-201 scintigraphy and coronary angiography. *Circulation* 1983;**68**:321-36.
- 5 Schwartz KM, Turner JD, Sheffield LT, *et al.* Limited exercise testing soon after myocardial infarction: Correlation with early coronary and left ventricular angiography. *Am Intern Med* 1981;**81**:727-34.
- 6 Günalp B, Dokumaci B, Uyan C, *et al.* Value of dobutamine technetium-99m-sestamibi SPECT and echocardiography in the detection of coronary artery disease compared with coronary angiography. *J Nucl Med* 1993;**34**:889-94.
- 7 Marwick T, D'Hondt AM, Baudhuin T, *et al.* Optimal use of dobutamine stress for the detection and evaluation of coronary artery disease: combination with echocardiography or scintigraphy, or both. *J Am Coll Cardiol* 1993;**22**:159-67.
- 8 Senior R, Sridhara BS, Anagnostou E, *et al.* Synergic value of simultaneous stress dobutamine sestamibi single-photon emission computerized tomography and echocardiography in the detection of coronary artery disease. *Am Heart J* 1994;**128**:713-18.
- 9 Smart SC, Knickelbine T, Stoiber TR, *et al.* Safety and accuracy of dobutamine-atropine stress echocardiography for the detection of residual stenosis of the infarct-related artery and multivessel disease during the first week after myocardial infarction. *Circulation* 1997;**95**:1394-401.
- 10 Piérard LA, Sprynger M, Carlier J. Echocardiographic prediction of the site of coronary artery obstruction in acute myocardial infarction. *Eur Heart J* 1987;**8**:116-23.
- 11 Ritchie JL, Bateman TM, Bonow RO, *et al.* Guidelines for clinical use of cardiac radionuclide imaging. Report of the American College of Cardiology/American Heart Association task force on assessment of diagnostic and therapeutic cardiovascular procedures (committee on radionuclide imaging) developed in collaboration with the American Society of Nuclear Cardiology. *J Am Coll Cardiol* 1995;**25**:521-47.
- 12 Benoit T, Vivegnis D, Foulon J, *et al.* Quantitative evaluation of myocardial single-photon emission tomographic imaging: application to the measurement of perfusion defect size and severity. *Eur J Nucl Med* 1996;**23**:1603-12.
- 13 The TIMI Study Group. Comparison of invasive and conservative strategies after treatment with intravenous tissue plasminogen activator in acute myocardial infarction: results of the thrombolysis in myocardial infarction (TIMI) phase II trial. *N Engl J Med* 1989;**320**:618-27.
- 14 Topol EJ, Califf RM, George BS, *et al.* and the Thrombolysis and Angioplasty in Myocardial Infarction Study Group. A randomized trial of immediate versus delayed elective angioplasty after intravenous tissue plasminogen activator in acute myocardial infarction. *N Engl J Med* 1987;**317**:581-8.
- 15 Takeuchi M, Araki M, Nakashima Y, *et al.* The detection of residual ischemia and stenosis in patients with acute myocardial infarction with dobutamine stress echocardiography. *J Am Soc Echocardiogr* 1994;**7**:242-52.
- 16 Elhendy A, Van Domburg RT, Roelandt JRTC, *et al.* Accuracy of dobutamine stress echocardiography for the diagnosis of coronary artery stenosis in patients with myocardial infarction: the impact of extent and severity of left ventricular dysfunction. *Heart* 1996;**76**:123-8.
- 17 Elhendy A, Geleijnse ML, Roelandt JRTC, *et al.* Comparison of dobutamine stress echocardiography and 99m technetium sestamibi SPECT myocardial perfusion scintigraphy for predicting extent of coronary artery disease in patients with healed myocardial infarction. *Am J Cardiol* 1997;**79**:7-12.
- 18 Glover DK, Ruiz M, Edwards NC, *et al.* Comparison between ²⁰¹Tl and ^{99m}Tc sestamibi uptake during adenosine-induced vasodilation as a function of coronary stenosis severity. *Circulation* 1995;**91**:813-20.
- 19 Calnon DA, Glover DK, Beller GA, *et al.* Effects of dobutamine stress on myocardial blood flow, ^{99m}Tc sestamibi uptake, and systolic wall thickening in the presence of coronary artery stenoses. Implications for dobutamine stress testing. *Circulation* 1997;**96**:2353-60.
- 20 Berthe C, Piérard LA, Hiernaux M, *et al.* Predicting the extent and location of coronary artery disease in acute myocardial infarction by echocardiography during dobutamine infusion. *Am J Cardiol* 1986;**58**:1167-72.
- 21 Mahmarian JJ, Pratt C, Nishimura S, *et al.* Quantitative adenosine TL 201 single-photon emission computed tomography for early assessment of patients surviving acute myocardial infarction. *Circulation* 1993;**87**:1197-210.
- 22 Ambrose JA, Winters SL, Arora RR, *et al.* Coronary angiographic morphology in myocardial infarction: a link between the pathogenesis of unstable angina and myocardial infarction. *J Am Coll Cardiol* 1985; **6**: 1233-38.
- 23 Beleslin BD, Ostojic M, Djordjevic-Dikic A, *et al.* Integrated evaluation of relation between coronary lesion features and stress echocardiography results: the importance of coronary lesion morphology. *J Am Coll Cardiol* 1999;**33**:717-26.
- 24 White CW, Wright CB, Doty DB, *et al.* Does visual interpretation of the coronary arteriogram predict the physiologic importance of a coronary stenosis? *N Engl J Med* 1984;**310**:819-24.
- 25 Gould LK. Noninvasive assessment of coronary stenoses by myocardial perfusion imaging during pharmacologic coronary vasodilatation. *J Am Coll Cardiol* 1978;**41**:267-77.