

## *Chlamydia pneumoniae* antigens, rather than viable bacteria, persist in atherosclerotic lesions

A Meijer, P J M Roholl, S K Gielis-Proper, J M Ossewaarde

### Abstract

**Aims**—To evaluate the nature of the presence of *Chlamydia pneumoniae* or of other members of the order Chlamydiales in atherosclerotic lesions.

**Methods**—Consecutive sections of 13 carotid artery specimens obtained at necropsy and of *C pneumoniae* infected HEp2 cells were analysed using: (1) immunocytochemistry (ICC) to detect *C pneumoniae* membrane protein; (2) in situ hybridisation (ISH) using a polymerase chain reaction (PCR) fragment of the *omp1* gene to detect *C pneumoniae* specific DNA; (3) ISH using an oligonucleotide probe to detect Chlamydiales specific 16S rRNA; (4) PCR to detect *C pneumoniae* 16S rDNA; and (5) in situ DNA nick end labelling (TUNEL) to detect fragmented DNA.

**Results**—Staining by ICC and ISH of infected HEp2 cells showed characteristic inclusions. *Chlamydia pneumoniae* membrane protein was demonstrated in macrophages in advanced atherosclerotic lesions (six of six), but not in fatty streaks (none of two), or normal arteries (none of five). ISH assays using both probes and PCR were all negative, indicating the absence of both specific *C pneumoniae* DNA and Chlamydiales specific 16S rRNA. Only after treatment with DNase I were uniformly sized dots demonstrated by the TUNEL assay in inclusions of infected HEp2 cells. The TUNEL assay showed a similar staining pattern in macrophages in five carotid artery specimens, of which four were also positive for *C pneumoniae* membrane protein. Both macrophage populations were morphologically similar and were similarly distributed.

**Conclusions**—No evidence was obtained for the involvement of other members of the order Chlamydiales in atherosclerosis. The presence of *C pneumoniae* antigen in the absence of DNA and 16S rRNA suggests that antigens, rather than viable bacteria, persist in atherosclerotic lesions. (J Clin Pathol 2000;53:911-916)

**Keywords:** *Chlamydia pneumoniae*; Chlamydiales; immunocytochemistry; in situ hybridisation; polymerase chain reaction; DNA fragmentation; atherosclerosis

*Chlamydia pneumoniae*, an important respiratory pathogen and a member of the third recognised species of the family of Chlamydiaceae, has recently been associated with atherosclerotic

vascular diseases.<sup>1</sup> *Chlamydia pneumoniae* has been demonstrated in atherosclerotic lesions of all major arteries by immunocytochemistry (ICC), electron microscopy, the polymerase chain reaction (PCR), or in situ hybridisation (ISH).<sup>2-7</sup> However, large discrepancies exist between results obtained using these techniques, especially between detection by PCR and by ICC.<sup>3-6</sup> These discrepancies have been explained by sampling error, PCR inhibitors, or different avidities of the antibodies used in ICC.<sup>3-5</sup> However, despite the demonstration of numerous cells positive for *C pneumoniae* antigen by ICC in several studies, *C pneumoniae* DNA could not always be detected by PCR,<sup>3-10</sup> even when using a more sensitive nested PCR protocol.<sup>9-10</sup> Previously, with the use of ICC and paraffin wax embedded sections of abdominal aortic aneurysm specimens, we have detected *C pneumoniae* membrane protein and chlamydial lipopolysaccharide (LPS).<sup>6</sup> However, *C pneumoniae* DNA could not be detected, either by PCR or by ISH. We suggested two possible explanations, namely: (1) the involvement of an antigenically related (unknown) member of the order Chlamydiales; and (2) rapid degradation of DNA, and the persistence of LPS and membrane protein after infection of the vessel wall with *C pneumoniae*.<sup>6</sup> In our present study, we evaluated these explanations by analysing carotid artery specimens for the presence of the following: (1) *C pneumoniae* membrane protein, using ICC; (2) *C pneumoniae* DNA, using ISH and PCR; (3) chlamydial 16S rRNA, using ISH and a Chlamydiales specific probe<sup>11</sup>; and (4) the presence of *C pneumoniae* DNA fragments, using in situ DNA nick end labelling (TUNEL).

### Methods

#### PATIENTS AND SPECIMENS

Carotid artery specimens taken during necropsy of 13 men were obtained from the pathology department of the National Centre for Occupational Health in Johannesburg, South Africa, within one to seven days after death in January 1997 (kindly provided by Dr A Shor) (table 1). The specimens were routinely fixed in 10% buffered formalin for 48 hours, embedded in paraffin wax, and shipped to the National Institute of Public Health and the Environment, Bilthoven, The Netherlands. One 4 µm section of each paraffin wax embedded specimen was stained with haematoxylin and eosin for characterisation of the microscopic pathology, according to the classification of atherosclerosis defined by the American Heart Association.<sup>12</sup>

Research Laboratory for Infectious Diseases, National Institute of Public Health and the Environment, PO Box 1, 3720 BA Bilthoven, The Netherlands  
A Meijer  
J M Ossewaarde

Laboratory for Pathology and Immunobiology, National Institute of Public Health and the Environment  
P J M Roholl  
S K Gielis-Proper

Correspondence to:  
Dr Meijer  
Adam.Meijer@rivm.nl

Accepted for publication  
13 June 2000

Table 1 Demonstration of immunoreactivity for *Chlamydia pneumoniae* membrane protein by immunocytochemistry and of cytoplasmic DNA fragmentation by the in situ DNA nick end labelling (TUNEL) assay in paraffin wax embedded sections of carotid arteries

Case	Age (years)	Cause of death	Days post mortem	Lesion type	Immunoreactivity for <i>C pneumoniae</i> membrane protein	Cytoplasmic DNA fragmentation
1	19	Meningitis	1	II	-	-
2	73	Respiratory failure	4	V	+	+
3	76	Uraemia	5	Vb	++	+
4	64	Heart failure	6	II	-	+++
5	70	Coronary artery disease	6	I	-	-
6	70	Melanoma	2	I	-	-
7	52	Respiratory failure	7	I	-	-
8	51	Pneumonia	7	I	-	-
9	30	Natural causes	6	I	-	-
10	66	Heart failure	3	IVa	+++	-
11	89	Pneumonia	6	V/VI	+++	++
12	60	Heart failure	1	V/VI	++	++
13	50	Heart failure	5	V	++	-

Days post mortem refers to the delay between death and the collection of specimens.

Lesion type is classified according to Stary *et al* as follows: I, normal artery/initial lesion; II, fatty streak; IV-V/VI, advanced lesion.<sup>12</sup> Immunoreactivity for *C pneumoniae* membrane protein and cytoplasmic DNA fragmentation (small dots of uniform size) refer to the number of positive cells: -, none; +, some; ++, regular; +++, many.

#### IMMUNOCYTOCHEMISTRY AND IN SITU HYBRIDISATION

Sections of HEp2 cells (code CCL23; American Type Culture Collection, Manassas, Virginia, USA) infected with *C pneumoniae* strain TW-183 (Washington Research Foundation (WRF), Seattle, Washington, USA) at a multiplicity of infection of 0.1 inclusion forming units, and of mock infected HEp2 cells, fixed and embedded in paraffin wax similar to the clinical specimens, were used as positive and negative controls, respectively.

*Chlamydia pneumoniae* antigen was detected in 4 µm sections by immunocytochemistry using an indirect immunoperoxidase method, as described and evaluated previously.<sup>6,13</sup> A species specific monoclonal antibody, RR-402 (WRF), against a *C pneumoniae* membrane protein was used.<sup>14</sup> An irrelevant mouse monoclonal antibody of the same isotype as monoclonal antibody RR-402 (IgG3) was used as a negative control antibody. For the identification of macrophages and smooth muscle cells, monoclonal antibodies PG-M1, directed against the macrophage marker CD68, and 1A4, directed against smooth muscle cell actin (DAKO A/S, ITK Diagnostics BV, Uithoorn, The Netherlands), were used.

The detection of *C pneumoniae* DNA by in situ DNA hybridisation (ISDH) and of Chlamydiales specific 16S rRNA by in situ RNA hybridisation (ISRH) on 4 µm sections adjacent to the sections used for ICC was carried out as described and evaluated previously.<sup>6,13</sup> ISDH was carried out with a digoxigenin (DIG) labelled *C pneumoniae* major outer membrane protein (MOMP) gene fragment as a probe and with a DIG labelled minute virus of mouse (MVM) genome fragment as a negative control probe. ISRH was carried out with the following DIG labelled oligonucleotide probes: (1) an antisense probe specific for 16S rRNA of the order Chlamydiales; (2) a sense probe to assess the specificity of the antisense probe for rRNA; and (3) a nonsense probe composed of the same nucleotides as the antisense probe but in a different sequence as a negative control probe. A 3' and 5' DIG labelled probe of 33 nucleotides, specific for eukaryotic 28S rRNA, was used to

assess the presence of hybridisable RNA in the carotid artery sections.<sup>15</sup>

Specimens were considered positive for *C pneumoniae* antigen or DNA, or Chlamydiales specific 16S rRNA when clear cell associated staining was observed.

#### PCR ASSAYS

Before DNA extraction, five 4 µm sections of each specimen were dewaxed using UltraClear (Mallinckrodt Baker BV, Deventer, The Netherlands), washed with ethanol and acetone, and dried. As a positive control, one 4 µm section of the lung of a mouse two days post intranasal infection with *C pneumoniae*<sup>13</sup> was used. DNA isolation using the Easy DNA kit (Invitrogen BV, Leek, The Netherlands) and PCR assays for *C pneumoniae* 16S rDNA (165 bp fragment) and for the human β-globin gene (110 bp fragment) were carried out as described previously.<sup>16,17</sup>

#### TERMINAL DEOXYNUCLEOTIDYL TRANSFERASE (TdT) MEDIATED FLUORESCIN dUTP NICK END LABELLING (TUNEL) ASSAY

The "in situ cell death detection kit, POD" (Boehringer Mannheim, Mannheim, Germany) was used to detect free 3' ends of DNA. Sections (4 µm thick) adjacent to those used for ICC were dewaxed, rehydrated, and treated with 2.5 mg/litre proteinase K in 50 mmol/litre Tris/HCl (pH 7.6) containing 2 mmol/litre CaCl<sub>2</sub> for 15 minutes at 37°C. They were then washed twice for two minutes with PBS, blocked for endogenous peroxidase by incubation in 0.3% H<sub>2</sub>O<sub>2</sub> in methanol for 30 minutes, and washed twice for five minutes with PBS. Optimal staining was achieved by using a dilution of the TdT enzyme (1/2 in 30 mmol/litre Tris/HCl (pH 7.2) containing 140 mmol/litre sodium cacodylate and 1 mmol/litre CoCl<sub>2</sub>), and of the peroxidase labelled anti-fluorescein antibody (1/2 in 100 mmol/litre Tris/HCl (pH 7.5) containing 150 mmol/litre NaCl and 30 g/litre bovine serum albumin (BSA) fraction V), according to the manufacturer's instructions. Sections were incubated for 60 minutes at 37°C with TUNEL reaction mixture (5 µl 1/2 diluted TdT enzyme, 45 µl labelling solution containing fluorescein la-

belled dUTP and unlabelled dNTPs), washed three times for one minute with PBS, and incubated for 30 minutes at 37°C with 1% BSA fraction V in PBS. This was followed by 30 minutes at 37°C with 1/2 diluted peroxidase labelled antiferuorescein antibody, after which the sections were washed three times for two minutes with PBS. Peroxidase was visualised with diaminobenzidine (Sigma-Aldrich Chemie BV, Zwijndrecht, the Netherlands). The sections were counterstained with Mayer's haematoxylin. An artificial positive control of a carotid artery section was prepared by treatment of the section with  $1 \times 10^6$  U/litre DNase I (Boehringer Mannheim) in 50 mmol/litre Tris/HCl (pH 7.5) containing 1 mmol/litre MgCl<sub>2</sub> and 1 g/litre BSA fraction V for 10 minutes at room temperature. For each carotid artery specimen, a background staining control was included, which was incubated with the TUNEL reaction mixture without the TdT enzyme. Sections that showed staining of matrix vesicles were pretreated with 10% EDTA in PBS for one hour, as described previously.<sup>18</sup>

Sections of *C pneumoniae* infected HEp2 cells that were incubated with the complete TUNEL mixture, with and without pretreatment of the sections with DNase I, or incubated with the TUNEL mixture without the TdT enzyme, were used as controls.

## Results

### HISTOLOGY

Of the 13 carotid artery specimens, five were classified as type I (normal artery/initial lesion), two as type II (fatty streak), and six as advanced lesions of type IV to V/VI (table 1).

### IMMUNOCYTOCHEMISTRY AND IN SITU HYBRIDISATION

Inclusions in HEp2 cells infected with *C pneumoniae* stained strongly with the *C pneumoniae* membrane protein specific monoclonal antibody RR-402, the *C pneumoniae* specific MOMP probe, and the Chlamydiales 16S rRNA specific antisense oligonucleotide probe, whereas no staining was seen in mock infected HEp2 cells. No staining of inclusions was observed with the MVM probe, the sense oligonucleotide probe, or the nonsense oligonucleotide probe.

Immunoreactivity with the *C pneumoniae* membrane protein specific monoclonal antibody was detected in all type IV–VI lesions (fig 1A), whereas it was not detected in type I and II lesions (table 1). Immunoreactivity was always seen in cells within or in close proximity to the lesion, but not in adjacent normal artery tissue. No staining was observed with the control monoclonal antibody. Cells immunoreactive for *C pneumoniae* membrane protein appeared to be macrophages and were found in areas in which cells showed immunoreactivity for the macrophage marker CD68 (fig 1B) in adjacent sections. Cells immunoreactive for smooth muscle cell actin were not seen in these areas. The specimens gave strong signals in ISRH with the eukaryotic 28S rRNA probe (fig 1C), demonstrating the suitability of the speci-

mens for hybridisation experiments. None of the specimens from the 13 cases was positive in ISDH for *C pneumoniae* DNA (fig 1D). Sections from cases 2, 4, 5, and 9 detached from the slides during ISRH and were not included further in the ISRH experiments. Chlamydiales 16S rRNA was not detected in any of the other specimens.

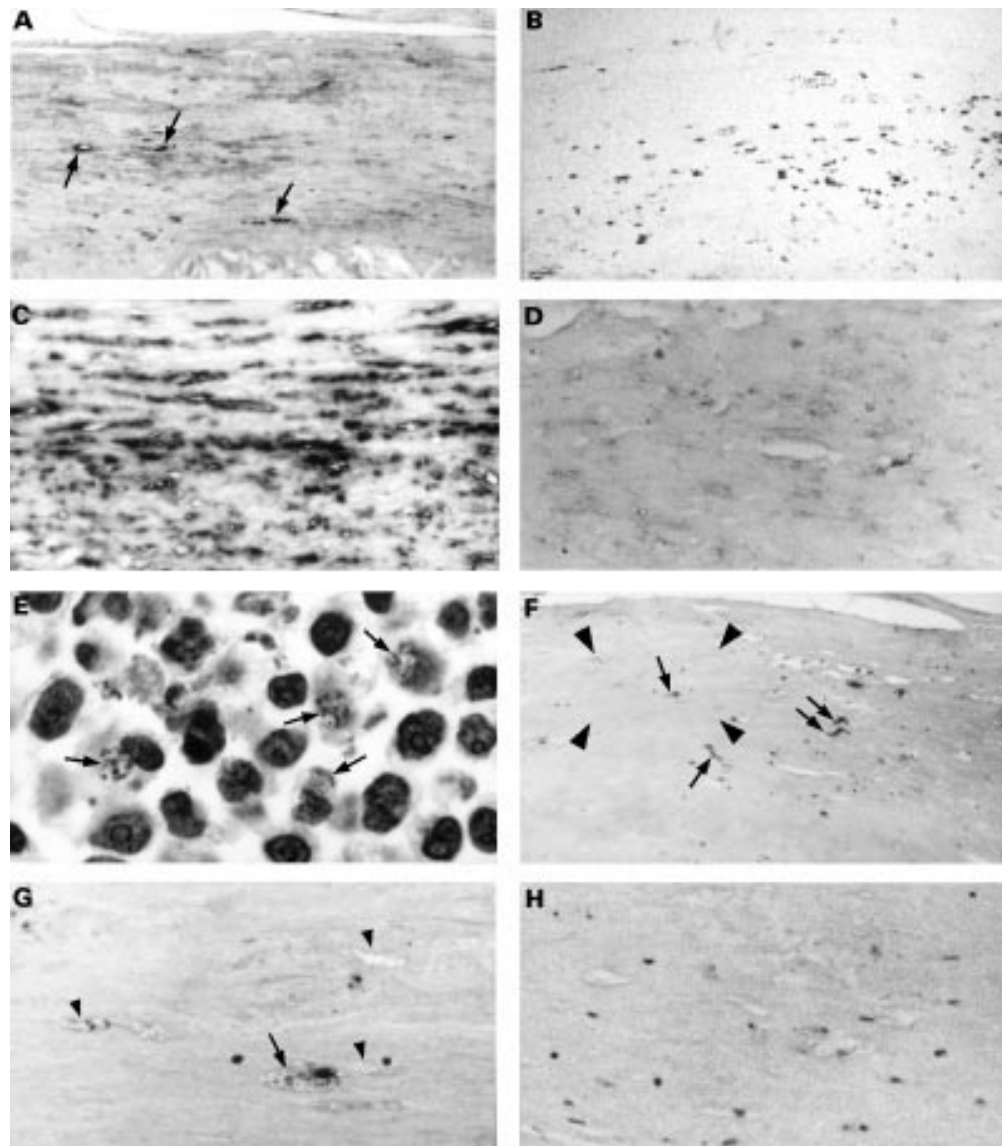
### PCR ASSAYS

The DNA extracted from the positive control showed a strong *C pneumoniae* specific band upon PCR analysis. The 110 bp β-globin fragment was amplified from the DNA extracted from the 13 patient specimens, indicating the presence of PCR amplifiable DNA. Nonetheless, the *C pneumoniae* specific 16S rDNA fragment could not be amplified from any of the DNA extracts from these patients.

### TUNEL ASSAY

A carotid artery section pretreated with DNase I and subsequently processed by the TUNEL assay showed partial to total staining of the nuclei of most cells, indicating the ability of the procedure to label fragmented DNA. To investigate whether fragmented chlamydial DNA could be visualised, the TUNEL assay was applied to HEp2 cells infected with *C pneumoniae*. No staining for fragmented DNA was seen when these cells were incubated with the TUNEL reaction mixture, with or without TdT enzyme. However, stained fragmented chlamydial DNA could be seen in clearly recognisable inclusions in these cells with the TUNEL assay after DNase I pretreatment of the cells (fig 1E). The staining pattern of fragmented chlamydial DNA appeared as small dense dots of uniform size. Therefore, this pattern of TUNEL staining was analysed in the carotid artery specimens and could easily be distinguished from the typical staining pattern of fragmented eukaryotic DNA from apoptotic nuclei and apoptotic bodies (not uniform in size) in the cytoplasm of cells. The TUNEL assay without the TdT enzyme in the reaction mixture applied to sections of cases 2, 3, 4, 11, 12, and 13 showed staining of clearly recognisable calcium deposits and faint staining of some other structures. This type of staining was abolished by EDTA pretreatment of the sections. Sections from the other patients showed no staining in the TUNEL assay without the TdT enzyme in the reaction mixture. Table 1 summarises the results of the TUNEL assay on the carotid artery specimens. Small uniformly sized dots stained by the TUNEL assay were observed in the cytoplasm of cells in the pathological areas of the arteries (fig 1F and G). Without the TdT enzyme in the reaction mixture, this type of staining was not seen (fig 1H). The cells with cytoplasmic TUNEL staining were found in areas where cells positive for the macrophage marker CD68 but not smooth muscle cell actin were found in adjacent sections. This cytoplasmic TUNEL staining was not caused by calcium deposits, which can cause non-specific TUNEL staining,<sup>18</sup> because EDTA pretreatment of the sections did not affect this type of staining. In four of the six cases that showed cells immuno-





**Figure 1** Representative photomicrographs of an area with atherosclerotic changes in consecutive sections of the carotid artery specimen of case 11 (A–D, and F–H), and of HEp2 cells infected with *Chlamydia pneumoniae* (E). Several cells in this atherosclerotic area were immunoreactive for *C pneumoniae* membrane protein (A; some positive cells indicated with an arrow). These cells are part of the population of cells that immunostained for macrophage marker CD68 (B). In situ hybridisation reactivity for eukaryotic 28S rRNA (C) demonstrated the suitability of the specimen for hybridisation experiments. However, *C pneumoniae* DNA was not detected by in situ hybridisation (D). Fragmented DNA of *C pneumoniae* in a section of HEp2 cells infected with *C pneumoniae* pretreated with DNase I and then processed in the in situ DNA nick end labelling (TUNEL) assay was visible as uniformly sized dots in clearly recognisable inclusions (E; arrows) next to TUNEL stained nuclei of the HEp2 cells. Uniformly sized dots stained using the TUNEL assay were also found in the carotid artery specimen (F and G; arrows) in a cell type in which *C pneumoniae* membrane protein was also observed. An enlargement of the area enclosed by the arrowheads in (F) is shown in (G). Note that cells similar in morphology to TUNEL reactive cells were also not reactive in the TUNEL assay (G; arrowheads). These vacuolated cells are part of the population of cells that immunostained for macrophage marker CD68 (B). No staining was observed without transferase in the TUNEL reaction mixture (H). Counterstaining, panels A–D, nuclear fast red; panels E–H, Mayer's haematoxylin. Original magnifications,  $\times 31$  (A, B, and F),  $\times 62$  (C),  $\times 125$  (D, G, and H), and  $\times 250$  (E).

reactive for *C pneumoniae* membrane protein, cells with cytoplasmic TUNEL staining were also seen (table 1). Cells immunoreactive for *C pneumoniae* membrane protein were morphologically similar to those cells in which the cytoplasm stained positive in the TUNEL assay in adjacent sections, and the stained cells showed a similar distribution pattern in both assays.

### Discussion

We have demonstrated the presence of immunoreactivity for *C pneumoniae* membrane protein in macrophages in advanced atherosclerotic

lesions (type IV–VI) of carotid arteries, but not in carotid arteries at lesion prone sites (type I) or in fatty streaks (type II). Genomic *C pneumoniae* DNA and chlamydial 16S rRNA could not be detected in any of the carotid arteries by in situ hybridisation, and neither could *C pneumoniae* 16S rDNA by PCR. Fragmented chlamydial DNA, demonstrated by the TUNEL assay, was present as uniformly sized dots in cultured cells infected with *C pneumoniae* and pretreated with DNase I. This type of TUNEL staining was also detected in carotid artery specimens, in the cytoplasm of cells that

were also immunoreactive for *C pneumoniae* membrane protein in adjacent sections.

First, we analysed the presence of *C pneumoniae* in carotid arteries by ICC for membrane protein and by ISDH and PCR. Immunoreactivity for *C pneumoniae* membrane protein was detected in six carotid arteries, whereas *C pneumoniae* specific DNA could not be demonstrated by ISDH or PCR, in agreement with our previous results using specimens from abdominal aortic aneurysms.<sup>6</sup> The presence of immunoreactivity for *C pneumoniae* membrane protein in advanced lesions was in agreement with the results of Kuo *et al.*<sup>19</sup> We did not see immunoreactivity for *C pneumoniae* membrane protein in fatty streaks from two patients, although Kuo *et al* found the antigen in fatty streaks of seven of 16 patients.<sup>19</sup> This discrepancy probably results from the small number of specimens in our study. *Chlamydia pneumoniae* membrane protein was found in cells of the macrophages population, as determined by their morphology and immunoreactivity for the macrophage marker CD68 but not for smooth muscle cell actin. These findings are in agreement with results from coronary atherectomy specimens, presented previously.<sup>20</sup> However, in another study *C pneumoniae* antigens were found in macrophages as well as in smooth muscle cells in aortic lesions.<sup>21</sup> It should be noted, however, that atherectomy specimens do not always contain the deeper layers in which the positive smooth muscle cells were observed in the aorta biopsies.<sup>22</sup> Our carotid artery specimens included all layers.

Thus, we were not able to demonstrate the presence of *C pneumoniae* DNA, whereas antigens reactive with the monoclonal antibody RR-402 were found regularly. Therefore, we evaluated the possible involvement of other members of the order Chlamydiales. No evidence was obtained for the presence of 16S rRNA from any member of the order Chlamydiales by ISRH. This observation is consistent with the absence of any hybridisable *C pneumoniae* DNA, supporting the hypothesis that only antigens persist after infection of the vessel wall.

The in situ hybridisation results can be considered reliable because control sections of HEp2 cells infected with *C pneumoniae* consistently showed staining of inclusions with the MOMP and the antisense 16S rRNA probes, and these methods have been evaluated and used successfully in studying *C pneumoniae* infected mice.<sup>13</sup> Furthermore, sections of all carotid artery specimens that could be analysed showed staining for eukaryotic 28S rRNA, indicating the suitability of these specimens for in situ hybridisation experiments.

Finally, we evaluated the possibility of the rapid degradation of DNA and the persistence of membrane protein to explain our results. Fragmented chlamydial DNA was present as uniformly sized dots in cultured cells infected with *C pneumoniae* and treated with DNase I. The absence of TUNEL staining without DNase I pretreatment showed that viable *C pneumoniae* does not contain fragmented DNA. Cells with uniformly sized dots in their

cytoplasm stained by the TUNEL assay were found in four of six cases with cells immunoreactive for *C pneumoniae* membrane protein. The distribution of TUNEL positive cells was similar to that of cells positive for *C pneumoniae* membrane protein. This suggests that fragmented DNA in these cells might originate from *C pneumoniae*. The bacterial DNA might have been fragmented in the natural process of clearing an infection by phagocytosis of bacteria and subsequent degradation in lysosomes, or as a consequence of conditions in the infected cell initiating a process of DNA fragmentation. The first process is most likely because *C pneumoniae* specific membrane protein (our study), chlamydial specific LPS, and heat shock protein 60 (hsp60) have been found in macrophages (professional phagocytes).<sup>6 20 21 23</sup> However, limited replication of *C pneumoniae* in in vitro experiments using the monocytic cell line U-937, or fresh human peripheral blood mononuclear cells, suggests that the second option is also possible.<sup>24 25</sup>

An analogy of *C pneumoniae* infection in atherosclerosis with chronic infections caused by *Chlamydia trachomatis* has been suggested.<sup>26</sup> These chronic infections are characterised by the presence of persistent forms of *C trachomatis*. A hallmark of persistence of *C trachomatis* in trachoma, tubal occlusion, and Reiter's syndrome is the presence of nucleic acids, whereas only small amounts of antigens are detected in a small fraction of specimens positive for nucleic acids.<sup>27-30</sup> In contrast, in this and a previous study,<sup>6</sup> we noted an abundance of *C pneumoniae* antigens in the complete absence of hybridisable DNA and 16S rRNA in atherosclerotic lesions. Thus, it is more likely that antigens of *C pneumoniae*, rather than viable bacteria, persist in atherosclerotic lesions after infection. Alternatively, the presence of *C pneumoniae* antigens in atherosclerotic lesions in the absence of its DNA might be explained by the "travelling" of macrophages, which have ingested and degraded bacteria at other sites in the body infected by *C pneumoniae* (for example, the lung), to the area of inflammation in the atherosclerotic lesion, as suggested by Capron.<sup>31</sup> Nevertheless, this might have important implications for prevention and treatment strategies, as has already been demonstrated in rabbits infected with *C pneumoniae*.<sup>32</sup> A seven week course of azithromycin had no effect on the presence of antigens in aortic tissue compared with untreated rabbits. Furthermore, persistent chlamydial antigens, such as LPS and hsp60, but not necessarily viable bacteria, might very well contribute to the pathogenesis of atherosclerosis through the induction of macrophage foam cell formation and the activation of macrophages.<sup>23 25 33 34</sup>

In contrast to our findings, viable *C pneumoniae* has been cultured more<sup>3 4 35</sup> or less<sup>8</sup> successfully from atherosclerotic tissue. An explanation for this discrepancy might be that specimens were collected during episodes of circulating *C pneumoniae* in the blood, and cultures might become positive as a result of bacteria or infected blood cells trapped in the vasa vasorum. In a large proportion of patients with

cardiovascular disease, and in blood donors, *C pneumoniae* DNA can be detected in peripheral blood mononuclear cells.<sup>36</sup> In situ techniques, as used in our present study, are the only way to locate viable *C pneumoniae* organisms and their components in cells in the lesion of the vessel wall.

In conclusion, evidence has been obtained for the presence of fragmented DNA in cells positive for *C pneumoniae* membrane protein in advanced atherosclerotic lesions. No evidence was found for the involvement of other members of the order Chlamydiales in atherosclerosis. The demonstration of the presence of *C pneumoniae* membrane protein in the absence of DNA and 16S rRNA supports the hypothesis of the persistence of antigens, rather than of viable bacteria, in atherosclerotic lesions.

We thank Dr A Shor from the National Centre for Occupational Health, Johannesburg, South Africa for providing the carotid artery specimens, and E Rozendal for photographic assistance.

- 1 Kuo CC, Jackson LA, Campbell LA, et al. Chlamydia pneumoniae (TWAR). *Clin Microbiol Rev* 1995;8:451-61.
- 2 Stille W, Dittmann R, Just-Nübling G. Atherosclerosis due to chronic arteritis caused by Chlamydia pneumoniae: a tentative hypothesis. *Infection* 1997;25:281-4.
- 3 Ramirez JA. The Chlamydia pneumoniae/atherosclerosis study group. Isolation of Chlamydia pneumoniae from the coronary artery of a patient with coronary atherosclerosis. *Ann Intern Med* 1996;125:979-82.
- 4 Jackson LA, Campbell LA, Kuo CC, et al. Isolation of Chlamydia pneumoniae from a carotid endarterectomy specimen. *J Infect Dis* 1997;176:292-5.
- 5 Jackson LA, Campbell LA, Schmidt RA, et al. Specificity of detection of Chlamydia pneumoniae in cardiovascular atheroma. Evaluation of the innocent bystander hypothesis. *Am J Pathol* 1997;150:1785-90.
- 6 Meijer A, van der Vliet JA, Roholl PJM, et al. Chlamydia pneumoniae in abdominal aortic aneurysms. Abundance of membrane components in the absence of heat shock protein 60 and DNA. *Arterioscler Thromb Vasc Biol* 1999;19:2680-6.
- 7 Maass M, Krause E, Engel PM, et al. Endovascular presence of Chlamydia pneumoniae in patients with hemodynamically effective carotid artery stenosis. *Angiology* 1997;48:699-706.
- 8 Weiss SM, Roblin PM, Gaydos CA, et al. Failure to detect Chlamydia pneumoniae in coronary atheromas of patients undergoing atherectomy. *J Infect Dis* 1996;173:957-62.
- 9 Lindholt JS, Østergård L, Henneberg EW, et al. Failure to demonstrate Chlamydia pneumoniae in symptomatic abdominal aortic aneurysms by a nested polymerase chain reaction (PCR). *Eur J Vasc Endovasc Surg* 1998;15:161-4.
- 10 Paterson DL, Hall J, Rasmussen SJ, et al. Failure to detect Chlamydia pneumoniae in atherosclerotic plaques of Australian patients. *Pathology* 1998;30:169-72.
- 11 Ossewaarde JM, Meijer A. Molecular evidence for the existence of additional members of the order Chlamydiales. *Microbiology* 1999;145:411-17.
- 12 Stary HC, Chandler AB, Dinsmore RE, et al. A definition of advanced types of atherosclerotic lesions and a histological classification of atherosclerosis. *Arterioscler Thromb Vasc Biol* 1995;15:1512-31.
- 13 Meijer A, Roholl PJM, Gielis-Proper SK, et al. Chlamydia pneumoniae in vitro and in vivo: a critical evaluation of in situ detection methods. *J Clin Pathol* 2000;53:904-10.
- 14 Puolakkainen M, Parker J, Kuo CC, et al. Further characterization of Chlamydia pneumoniae specific monoclonal antibodies. *Microbiol Immunol* 1995;39:551-4.
- 15 Yoshii A, Koji T, Ohsawa N, et al. In situ localization of ribosomal RNAs is a reliable reference for hybridizable RNA in tissue sections. *J Histochem Cytochem* 1995;43:321-7.
- 16 Meijer A, Van der Vliet JA, Roholl PJM, et al. Detection of microorganisms in vessel wall specimens of the abdominal aorta: development of a PCR assay in the absence of a gold standard. *Res Microbiol* 1998;149:577-83.
- 17 Greer CE, Peterson SL, Kiviat NB, et al. PCR amplification from paraffin-embedded tissues: effects of fixative and fixation time. *Am J Clin Pathol* 1991;95:117-24.
- 18 Kockx MM, Muhring J, Bortier H, et al. Biotin- or digoxigenin-conjugated nucleotides bind to matrix vesicles in atherosclerotic plaques. *Am J Pathol* 1996;148:1771-7.
- 19 Kuo CC, Shor A, Campbell LA, et al. Demonstration of Chlamydia pneumoniae in atherosclerotic lesions of coronary arteries. *J Infect Dis* 1993;167:841-9.
- 20 Campbell LA, O'Brien ER, Cappuccio AL, et al. Detection of Chlamydia pneumoniae TWAR in human coronary atherectomy tissues. *J Infect Dis* 1995;172:585-8.
- 21 Kuo CC, Gown AM, Benditt EP, et al. Detection of Chlamydia pneumoniae in aortic lesions of atherosclerosis by immunocytochemical stain. *Arterioscler Thromb* 1993;13:1501-4.
- 22 Casas-Ciria J, Rodriguez-Iglesias MA, Campbell LA, et al. Chlamydia pneumoniae and atherosclerotic plaque [correspondence]. *J Infect Dis* 1996;173:1519-20.
- 23 Kol A, Sukhova GK, Lichtman AH, et al. Chlamydial heat shock protein 60 localizes in human atheroma and regulates macrophage tumor necrosis factor- $\alpha$  and matrix metalloproteinase expression. *Circulation* 1998;98:300-7.
- 24 Numazaki K, Suzuki K, Chiba S. Replication of Chlamydia trachomatis and C pneumoniae in the human monocytic cell line U-937. *J Med Microbiol* 1995;42:191-5.
- 25 Kaukoranta-Tolvanen SS, Teppo AM, Laitinen K, et al. Growth of Chlamydia pneumoniae in cultured human peripheral blood mononuclear cells and induction of a cytokine response. *Microb Pathog* 1996;3:215-21.
- 26 Blanchard T, Bailey R, Holland M, et al. Chlamydia pneumoniae and atherosclerosis [letter]. *Lancet* 1993;341:825.
- 27 Holland SM, Hudson AP, Bobo L, et al. Demonstration of chlamydial RNA and DNA during a culture-negative state. *Infect Immun* 1992;50:2040-7.
- 28 Hudson AP, McEntee CM, Reacher M, et al. Inapparent ocular infection by Chlamydia trachomatis in experimental and human trachoma. *Curr Eye Res* 1992;11:279-83.
- 29 Campbell LA, Patton DL, Moore DE, et al. Detection of Chlamydia trachomatis deoxyribonucleic acid in women with tubal infertility. *Fertil Steril* 1993;59:45-50.
- 30 Beutler AM, Schumacher HR, Whittum-Hudson JA, et al. Case report: in situ hybridization for detection of inapparent infection with Chlamydia trachomatis in synovial tissue of a patient with Reiter's syndrome. *Am J Med Sci* 1995;310:206-13.
- 31 Capron L. Chlamydia in coronary plaques—hidden culprit or harmless hobo? *Nat Med* 1996;2:856-7.
- 32 Muhlenstein JB, Anderson JL, Hammond EH, et al. Infection with Chlamydia pneumoniae accelerates the development of atherosclerosis and treatment with azithromycin prevents it in a rabbit model. *Circulation* 1998;97:633-6.
- 33 Ward ME. The immunobiology and immunopathology of chlamydial infections. *APMIS* 1995;103:769-96.
- 34 Kalayoglu MV, Byrne GI. A Chlamydia pneumoniae component that induces macrophage foam cell formation is chlamydial lipopolysaccharide. *Infect Immun* 1998;11:5067-72.
- 35 Maass M, Bartels C, Engel PM, et al. Endovascular presence of viable Chlamydia pneumoniae is a common phenomenon in coronary artery disease. *J Am Coll Cardiol* 1998;31:827-32.
- 36 Boman J, Soderberg S, Forsberg J, et al. High prevalence of Chlamydia pneumoniae DNA in peripheral blood mononuclear cells in patients with cardiovascular disease and in middle-aged blood donors. *J Infect Dis* 1998;178:274-7.