

Histopathological changes associated with high intensity focused ultrasound (HIFU) treatment for localised adenocarcinoma of the prostate

G J L H Van Leenders, H P Beerlage, E Th Ruijter, J J M C H de la Rosette, C A van de Kaa

Abstract

Aims—Investigation of the histopathological changes in prostatectomy specimens of patients with prostate cancer after high intensity focused ultrasound (HIFU) and identification of immunohistochemical markers for tissue damage after HIFU treatment.

Methods—Nine patients diagnosed with adenocarcinoma of the prostate underwent unilateral HIFU treatment seven to 12 days before radical prostatectomy. The prostatectomy specimens were analysed histologically. Immunohistochemical staining and electron microscopy were performed to characterise more subtle phenotypic changes.

Results—All prostatectomy specimens revealed well circumscribed HIFU lesions at the dorsal side of the prostate lobe treated. Most epithelial glands in the centre of the HIFU lesions revealed signs of necrosis. Glands without apparently necrotic features were also situated in the HIFU lesions, raising the question of whether lethal destruction had occurred. This epithelium reacted with antibodies to pancytokeratin, prostate specific antigen (PSA), and Ki67, but did not express cytokeratin 8, which is indicative of severe cellular damage. Ultrastructural examination revealed disintegration of cellular membranes and cytoplasmic organelles consistent with cell necrosis. HIFU treatment was incomplete at the ventral, lateral, and dorsal sides of the prostate lobe treated.

Conclusions—HIFU treatment induces a spectrum of morphological changes ranging from apparent light microscopic necrosis to more subtle ultrastructural cell damage. All HIFU lesions are marked by loss of cytokeratin 8. HIFU does not affect the whole area treated, leaving vital tissue at the ventral, lateral, and dorsal sides of the prostate.

(J Clin Pathol 2000;53:391-394)

Keywords: prostate cancer; high intensity focused ultrasound treatment

Once a patient has been diagnosed with prostate cancer, few options for treatment are available. Radical prostatectomy is currently the standard treatment for organ confined prostate cancer in patients with a life expectancy of at least 10 years who are in a good

physical state. Radical prostatectomy is, however, a major surgical procedure that is potentially complicated by impotence, incontinence, and anastomotic strictures.¹ Therefore, during the past decade, minimally invasive procedures such as cryosurgery and brachytherapy have been developed as alternatives for patients not eligible for prostatectomy.²⁻⁴

High intensity focused ultrasound (HIFU) is another minimally invasive treatment currently being investigated for its efficacy in prostate diseases. In HIFU treatment, high energy converging ultrasound waves induce a rise in temperature and subsequent destruction of the tissue being treated. HIFU has been investigated extensively in patients with benign prostatic hyperplasia, and has achieved release of bladder outlet obstruction.⁵⁻⁸ The first clinical experiences using HIFU for prostate cancer have shown effective tumour destruction.⁹⁻¹² Although many studies have described the clinical effects of HIFU in patients with prostate disease, knowledge about the histomorphological changes associated with this treatment is limited.¹³ In our study, we evaluated the histological changes in prostatectomy specimens of nine patients with prostate cancer after HIFU treatment. Because we found a spectrum of reactive and necrotic changes after HIFU, we studied the immunohistochemical staining of several proteins to define markers for the detection of HIFU induced tissue damage. We performed electron microscopy to characterise the subcellular effects of HIFU.

Methods

We studied nine men who underwent unilateral HIFU therapy for clinically localised (T1/T2) prostate adenocarcinoma followed by radical prostatectomy. The patients' mean age was 62 years (range, 58-69). The patients were diagnosed by prostatic needle biopsy, prompted by abnormal findings during digital rectal examination, transrectal ultrasound sonography, or by raised serum prostate specific antigen (PSA) concentrations (mean, 10.5 ng/ml; range, 3.5-20). The needle biopsies showed a unilateral tumour in seven patients and bilateral tumour localisation in two patients. All patients gave informed consent for HIFU followed by radical prostatectomy. HIFU treatment was performed using a rectangular 2.25 MHz endorectal transducer, generating 1000 W/cm² during a four second period at 40 mm distance from the transducer (Ablatherm™, Technomed, Lyon,

Department of Pathology, University Hospital Nijmegen, PO Box 9101, 6500 HB Nijmegen, The Netherlands
G J L H Van Leenders
E Th Ruijter
C A van de Kaa

Department of Urology, University Hospital Nijmegen
H P Beerlage
J J M C H de la Rosette

Correspondence to:
Dr van Leenders
email:
G.vanleenders@pathol.azn.nl

Accepted for publication
29 November 1999

Table 1 Antigen, antibodies, and staining modalities for immunohistochemistry

Antigens	Antibodies	Clonality	Company	Dilution	Method
panCK	AE1/AE3	Monoclonal	Biogenex/Klinip	1/200	ABC
CK7 and CK8	CAM5.2	Monoclonal	B&D	1/20	ABC
PSA	Anti-PSA	Polyclonal	ITK	1/1000	PAP
Ki67	MIB1	Monoclonal	Immunotech/ Coulter	1/100	ABC
CK1, CK5, CK10, and CK14	34βE12	Monoclonal	Dako	1/250	ABC

ABC, avidin–biotin complex; CK, cytokeratin; PAP, peroxidase antiperoxidase; PSA, prostate specific antigen.

France). To protect the rectum from ultrasound induced damage, the probe was surrounded by a balloon containing cooling fluid. Because the procedure lasted three hours for each patient, only the side that was clinically suspected to have the largest tumour mass was treated. Patients underwent radical retropubic prostatectomy seven to 12 days (mean, 9.5 days) after HIFU.

The prostatovesiculectomy specimens were fixed overnight in 10% neutral buffered formaldehyde. After fixation, the specimens were sliced from apex to base at 4 mm intervals and embedded in paraffin wax. Sections (4 µm thick) were stained with haematoxylin and eosin for histological evaluation.

Epithelial cell damage after HIFU was analysed immunohistochemically using AE1/AE3, CAM5.2, anti-PSA, and MIB1 antibodies. The basal cell specific antibody 34βE12 was used to verify or exclude adenocarcinoma (table 1). Primary antibodies were diluted in phosphate buffered saline (PBS) with 1% bovine serum albumin and incubated for 60 minutes at room temperature. After washing in PBS, the slides were incubated for 30 minutes with biotinylated rabbit antimouse antibody (1/200) for the AE1/AE3, CAM5.2, MIB1, and 34βE12 antibodies, or with peroxidase labelled swine antirabbit antibody (1/20) for anti-PSA. The slides were conjugated with a 1/50 dilution of avidin–biotin complex (Vector Laboratories, Burlingame, California, USA) for 45 minutes and a 1/1600 dilution of peroxidase antiperoxidase complex (Dako, Glostrup, Sweden) for 30 minutes, respectively. After washing, the slides were reacted for five to 10 minutes in the dark with 0.01% 3-3'-diaminobenzidine (Sigma, Zwijndrecht, the Netherlands) in PBS containing 0.05% hydrogen peroxide. The sections were counterstained with haematoxylin.

Paraffin wax embedded tissue samples from three patients were processed for electron microscopy to evaluate subcellular tissue damage after HIFU. The samples were dewaxed using xylol, rehydrated, and buffered in sodium cacodylate. After fixation with osmium tetroxide, the tissues were dehydrated, submerged in propyleneoxide, and embedded in Epon 812. After staining with uranylacetate and lead citrate, ultrathin sections were analysed using a transmission electron microscope at 60 kV (Jeol 1200EX, Tokyo, Japan).

Results

MACROSCOPY

After fixation and slicing of the specimens, circular to elliptical lesions were identified at the

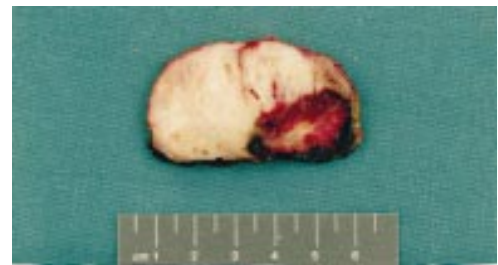

Figure 1 Prostate slice showing a high intensity focused ultrasound (HIFU) lesion. The HIFU lesion is characterised by a central yellow/white, necrotic zone surrounded by an outer dark red, haemorrhagic zone. The distance between two cross bars represents 0.5 cm.

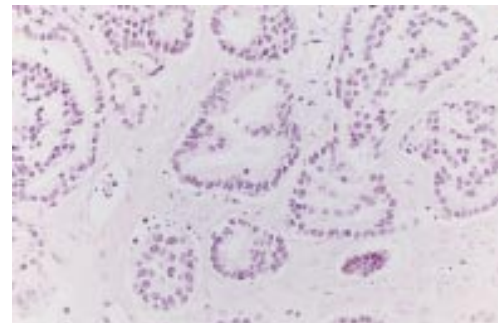


Figure 2 Adenocarcinoma in the centre of a high intensity focused ultrasound lesion without morphological signs of necrosis. Nuclear structures are well preserved and cell borders are locally identified.

dorsal side of the prostate lobe treated. The lesions consisted of a central yellow/white zone surrounded by an outer, dark red zone (fig 1). They were localised in all transverse slices of the prostate and extended into the apical and basal slice in four and five specimens, respectively. The lesions had a mean sagittal diameter of 16 mm (range, 8–20), transverse diameter of 28 mm (range, 22–34), and a height of 35 mm (range, 32–36). The mean volume of the HIFU lesions was 8.0 cm³ (range, 3.4–12.4).

MICROSCOPY

In the centre of the HIFU lesions, epithelium was desquamated into the gland lumina and showed a homogenised, eosinophilic cytoplasm usually with identifiable cell borders. The nuclei of epithelial and stromal cells were either pyknotic or totally absent, corresponding to cell necrosis. In six prostates, epithelium without apparently necrotic features was also found in the centre of the HIFU lesions. This epithelium had pale to eosinophilic cytoplasm containing few vacuoles. Although cell borders were not discernable in most of these cells, they could be identified locally. The nuclei were of normal size with a fine chromatin structure and sporadically small nucleoli. In malignant glands, the nuclei were enlarged and had conspicuous nucleoli (fig 2). At the periphery of the HIFU lesions, glands were lined by hyperplastic epithelium. Extensive haemorrhage occurred in this zone.

The HIFU lesions were not confined to the prostate. In all specimens, necrosis locally extended into the prostate capsule and the extraprostatic fat tissue. Biopsies performed in four patients showed necrosis of the pelvic

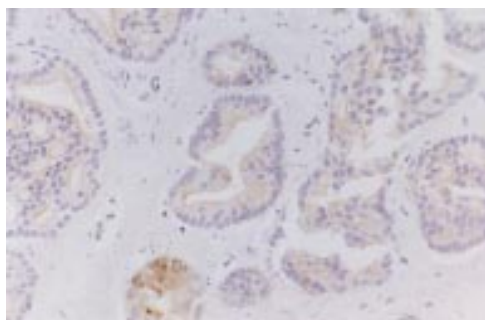


Figure 3 Weak expression of pancytokeratin in histomorphologically unaffected malignant epithelium within the high intensity focused ultrasound lesion. AE1/AE3 antibody.

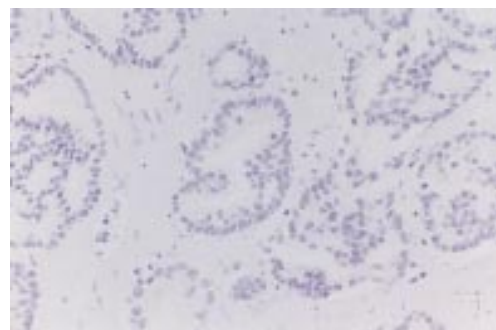

Figure 4 Absence of cyokeratin 8 expression in histomorphologically unaffected malignant epithelium within the high intensity focused ultrasound lesion. CAM5.2 antibody.

diaphragm in three cases. The proximal part of the seminal vesicles was affected unilaterally in three patients and bilaterally in two. In four patients, a 1–2 mm broad subcapsular rim of histologically unaffected prostate tissue was preserved at the dorsal side of the HIFU lesion, indicating incomplete tissue destruction. In all patients, unaffected tissue was also found at the ventral and lateral side of the HIFU lesions.

In eight prostates, adenocarcinoma was present outside the HIFU lesion. In all these patients carcinoma was found in the untreated lobe. In seven patients, adenocarcinoma was located at the ventral side of the treated lobe and in two prostates at the dorsal side of the HIFU lesion. The tumours were staged as follows: five patients, pT2b; two patients, pT3a; and one patient, pT4a.¹⁴ In one prostate, carcinoma was not found within or outside the HIFU lesion, and we presume that HIFU had been curative in this case.

IMMUNOHISTOCHEMISTRY

To detect markers for tissue damage after HIFU treatment we analysed the expression of PSA, pancytokeratin (panCK), Ki67, and cyokeratin 8 (CK8) in the prostate epithelium. The expression of PSA, panCK, and Ki67 in non-treated regions of the prostate was marginally stronger than in the HIFU region (fig 3). Interestingly, pre-existing and malignant epithelium within the HIFU lesion did not express CK8, regardless of the histomorphological changes in conventional light microscopy (fig 4). CK8 was strongly expressed in luminal cells of normal and malignant glands outside the HIFU lesion. The hyperplastic epithelium at the periphery of the HIFU lesions reacted with the basal cell antibody 34βE12.

ELECTRON MICROSCOPY

Electron microscopy was performed to confirm submicroscopical cellular damage in two CK8 negative adenocarcinomas in the centre of the HIFU lesion that showed no apparent morphological cell necrosis by conventional light microscopy (fig 5). The carcinomas lacked nuclear membranes, but showed a fine chromatin pattern that was clumped at the periphery of the nuclei, and conspicuous nucleoli. The cytoplasm contained some vacuoles, but organelle structures and cell membranes were not identified. A CK8 positive adenocarcinoma

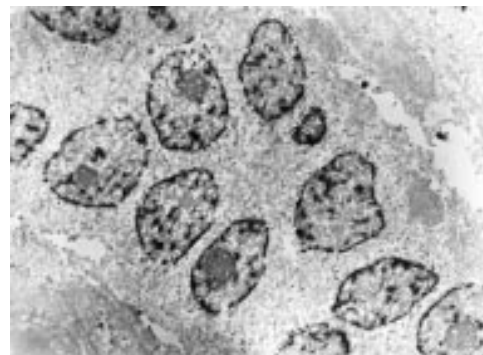

Figure 5 Electronmicrograph of an adenocarcinoma within the high intensity focused ultrasound lesion reveals destruction of cellular membranes and organelles but a relatively preserved nuclear structure. Magnification, $\times 3000$.

outside the HIFU lesion was analysed to exclude fixation artefacts because the prostates had been formalin fixed and paraffin wax embedded. This carcinoma revealed well recognisable cell membranes and organelles despite the presence of fixation artefacts (not shown).

Discussion

HIFU induced tissue damage varies in histomorphological aspect and extent. Most neoplastic and pre-existent glands within the HIFU area revealed coagulative necrosis, as was also found by Susani *et al.*¹³ At the periphery of the HIFU lesions, basal cell hyperplasia was observed, consistent with reactive or reparative changes to HIFU induced hyperthermia. Interestingly, some malignant and non-malignant glands in the centre of the lesion did not reveal signs of necrosis by conventional light microscopy, raising the question of whether lethal destruction had occurred in all epithelial glands. We presume that local differences in temperature, exposure time, and environmental characteristics cause the heterogeneous histomorphological changes after HIFU.¹⁵ The relatively unaffected nuclear morphology in some of the epithelial glands within the HIFU lesion probably results from the high thermostability of chromatin, whereas other cell organelles are more sensitive to hyperthermia.¹⁶

We evaluated the patency of cytoskeletal proteins, PSA, and Ki67, which are normally expressed in prostate epithelium, to find more

subtle phenotypic changes in the epithelial glands and to define markers for necrosis after HIFU treatment. Although the expression of pancytokeratin, PSA, and Ki67 was only marginally weaker within the HIFU lesion, CK8 expression was absent in both apparently necrotic and morphologically unaffected glands within the HIFU lesion.

During HIFU treatment heat shock occurs in the prostate tissue focused on. Heat shock induces protein denaturation, which can be defined as the unfolding of proteins from the native state to a more random state of lower organisation.¹⁶ The crucial temperature needed for denaturation varies between proteins. The unfolding of the three dimensional protein structure can lead to loss of antigenic determinants and withdrawal of antibody reactivity (for example, CAM5.2). In other cases, the antigenic determinants might be preserved after denaturation, leaving antibody reactivity intact (for example, MIB1). We speculate that antibodies reacting with a limited number of epitopes, such as the monoclonal CAM5.2, are more sensitive to denaturation than antibodies reacting with a large number of epitopes, such as the antibody cocktail AE1/AE3 or the polyclonal anti-PSA. Because the loss or decline of antibody reactivity represents structural changes in proteins, severe dysregulation of cell biological processes is expected after HIFU. However, the pattern of antibody reactivity by itself is not sufficient to confirm cell necrosis. The severe subcellular damage shown in two CK8 negative adenocarcinomas without apparent light microscopic changes indicates that cell necrosis did accompany the loss of CK8 expression.

HIFU treatment did not affect the whole target area but left vital appearing tissue at the ventral, lateral, and dorsal sides of the prostate lobe treated as analysed by conventional, immunohistochemical, and ultrastructural microscopy. Because of the convergence of ultrasound waves, hyperthermia is maximal at the focus distance (40 mm) corresponding to the centre of the HIFU lesion. Temperatures are lower between the focus and the transducer (< 40 mm), and further away from the focus area (> 40 mm). At the periphery of the HIFU lesions, temperatures are marginally raised, causing reactive or reparative changes. The decrease of temperature away from the focus

gives a physical explanation for the incomplete tissue destruction at these specific sites.

Because of the interest in minimally invasive treatments for prostate carcinoma we think it is important to consider the regular multifocal localisation of this malignancy. The lack of a reliable technique to indicate the presence and extent of prostate tumours complicates the use of minimally invasive treatments in patients with prostate cancer. Therefore, the analysis of prostatectomy specimens can help investigate the specific limitations of these new treatment modalities. Our results suggest that the incomplete destruction seen at the ventral, lateral, and dorsal sides of the prostate lobe treated means that HIFU is currently not an option for the treatment of prostate cancer.

- 1 Bratt O, Elfving P, Flodgren P, et al. Morbidity of pelvic lymphadenectomy, radical retropubic prostatectomy and external radiotherapy in patients with localised prostatic cancer. *Scand J Urol Nephrol* 1994;28:265-71.
- 2 Schwarzer JU, Hofmann R, Kneschaurek P, et al. High-dose-rate brachytherapy of prostatic carcinoma with iridium 192. *Strahlenther Onkol* 1992;168:17-22.
- 3 Zippe CD. Cryosurgical ablation for prostate cancer: a current review. *Semin Urol* 1995;13:148-56.
- 4 Pisters LL, von Eschenbach AC, Scott SM, et al. The efficacy and complications of salvage cryotherapy of the prostate. *J Urol* 1997;157:921-5.
- 5 Ebert T, Graefen M, Miller S, et al. High-intensity focused ultrasound (HIFU) in the treatment of benign prostatic hyperplasia (BPH). *Keio J Med* 1995;44:146-9.
- 6 Madersbacher S, Klingler CH, Schatzl G, et al. The urodynamic impact of transrectal high-intensity focused ultrasound on bladder outflow obstruction. *Eur Urol* 1996;30:437-45.
- 7 Mulligan ED, Lynch TH, Mulvin D, et al. High-intensity focused ultrasound in the treatment of benign prostatic hyperplasia. *Br J Urol* 1997;79:177-80.
- 8 Sullivan LD, McLoughlin MG, Goldenberg LG, et al. Early experience with high-intensity focused ultrasound for the treatment of benign prostatic hyperplasia. *Br J Urol* 1997;79:172-6.
- 9 Madersbacher S, Pedevilla M, Vingers L, et al. Effect of high-intensity focused ultrasound on human prostate cancer in vivo. *Cancer Res* 1995;55:3346-51.
- 10 Gelet A, Chapelon JY, Bouvier R, et al. Treatment of prostate cancer with transrectal focused ultrasound: early clinical experience. *Eur Urol* 1996;29:174-83.
- 11 Gelet A, Chapelon JY, Bouvier R, et al. Local control of prostate cancer by transrectal high intensity focused ultrasound therapy: preliminary results. *J Urol* 1999;161:156-62.
- 12 Beerlage HP, Van Leenders GJLH, Oosterhof GON, et al. High-intensity focused ultrasound (HIFU) followed after one to two weeks by radical retropubic prostatectomy: results of a prospective study. *Prostate* 1999;39:41-6.
- 13 Susani M, Madersbacher S, Kratzik C, et al. Morphology of tissue destruction induced by focused ultrasound. *Eur Urol* 1993;23(suppl 1):34-8.
- 14 Schröder FH, Hermanek P, Denis L, et al. The TNM classification of prostate cancer. *Prostate* 1992;(suppl 4):129-38.
- 15 Overgaard K, Overgaard J. Hyperthermic tumour-cell devitalization in vivo. *Acta Radiol Ther Phys Biol* 1977;16:1-16.
- 16 Lepock JR, Frey HE, Ritchie KP. Protein denaturation in intact hepatocytes and isolated cellular organelles during heat shock. *J Cell Biol* 1993;122:1267-76.