

# Fatal acute myocarditis in an infant with human herpesvirus 6 infection

T Yoshikawa, M Ihira, K Suzuki, S Suga, H Kito, T Iwasaki, T Kurata, T Tanaka, Y Saito, Y Asano

## Abstract

A 5 month old girl had typical clinical features of acute myocarditis just after the febrile period of exanthem subitum and died immediately. She had been healthy, with normal development, and there was no family history of particular note. Myocardial postmortem findings were compatible with acute myocarditis. Although the isolation of human herpesvirus 6 (HHV-6) was not attempted, positive IgM antibody to HHV-6 was detected in the patient's serum. Moreover, HHV-6 variant B DNA was detected in several tissues, including myocardium, by the polymerase chain reaction (PCR). In contrast, antibody responses to human herpesvirus 7, another causal agent of exanthem subitum, were not found, and enteroviral RNA was not detected in myocardial tissues by reverse transcription PCR. Apoptotic changes were seen in infiltrating cells within the myocardial tissues by means of the TUNEL method. HHV-6 antigen was not detected in several tissues (including

myocardium) by immunohistochemical analysis. In conclusion, HHV-6 may have been the causative agent of fatal acute myocarditis in this infant.

(J Clin Pathol 2001;54:792-795)

Keywords: human herpesvirus 6; myocarditis; polymerase chain reaction

Human herpesvirus 6 (HHV-6) is a recently discovered member of the herpesvirus family, and is the causative agent of exanthem subitum.<sup>1</sup> Primary infection with HHV-6 is thought to be a benign, self limited, febrile disease in infancy.<sup>2</sup> However, several fatal complications have been reported including fulminant hepatitis,<sup>3</sup> virus associated haemophagocytic syndrome,<sup>4</sup> and encephalitis/encephalopathy.<sup>5</sup> Meanwhile, an association between virus infection, particularly coxsackie B virus, and myocarditis has been demonstrated. It was also reported that human herpesviruses including cytomegalovirus, herpes simplex virus, and Epstein-Barr virus are potential aetiological agents for viral myocarditis. We report here a case of fatal acute myocarditis probably caused by primary HHV-6 infection.

## Case report

A 5 month old girl was seen in the department of paediatrics of a municipal hospital because of lethargy and poor feeding. Six days before admission she had a fever, which persisted for five days. Because skin eruptions appeared on her body after the fever subsided, she was diagnosed with exanthem subitum by the attending paediatrician (one day before admission). From the late afternoon of the day before admission, she became lethargic and exhibited poor feeding. Because her condition deteriorated, she was transferred to a municipal hospital. She had previously been healthy, with normal development, and there was no family history of particular note.

On examination, axillary temperature was 36.1°C, pulse was 186 beats/min, and blood pressure was not evaluated. She was unconscious, and her extremities were flaccid. There was no significant lymphadenopathy, hepatosplenomegaly, respiratory tract signs, or murmurs. The skin rash had already disappeared, and the anterior fontanel was flat. Cranial computed tomography gave normal results. The peripheral leucocyte count was 15 200/mm<sup>3</sup>, with 66% lymphocytes, and the following enzymes were greatly increased: aspartate aminotransferase (228 U/litre; normal range, 10-40), lactate dehydrogenase (2154 U/litre; normal range, 220-430), and creatine kinase

Department of  
Pediatrics, Fujita  
Health University  
School of Medicine,  
Toyoake, Aichi, Japan

T Yoshikawa  
M Ihira  
K Suzuki  
S Suga  
Y Asano

Department of  
Pediatrics, Seirei  
Hamamatsu General  
Hospital, Hamamatsu,  
Shizuoka, Japan

H Kito

Department of  
Pathology, National  
Institute of Infectious  
Diseases, Tokyo, Japan

T Iwasaki  
T Kurata

Special Reference  
Laboratories Inc,  
Tokyo, Japan  
T Tanaka  
Y Saito

Correspondence to:  
Dr Yoshikawa, Laboratory of  
Virology, Research Institute  
for Disease Mechanism and  
Control, Nagoya University  
School of Medicine, Nagoya,  
Aichi, 4668550, Japan  
tetsushi@med.nagoya-u.ac.jp

Accepted for publication  
28 February 2001

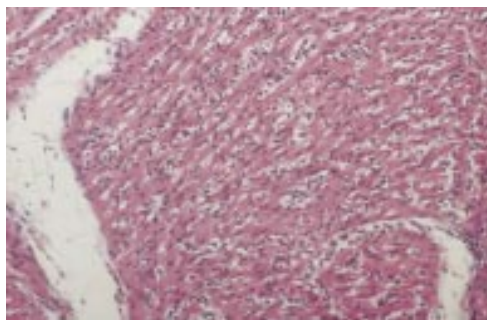


Figure 1 Diffuse infiltration of mononuclear cells and neutrophils is seen in the myocardium with oedematous change and degeneration and loss of myocardial cells (haematoxylin and eosin stained; original magnification,  $\times 200$ ).

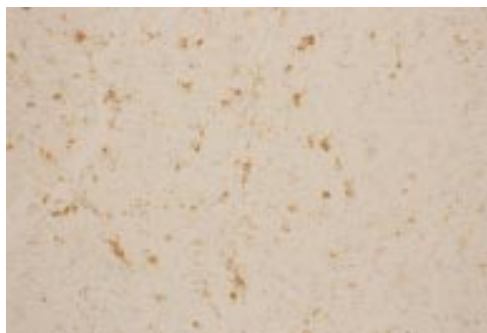

Figure 2 Infiltrating mononuclear cells in the myocardium are confirmed to be apoptotic by means of the TUNEL method using an ApoTag peroxidase kit (DAB-peroxidase; original magnification,  $\times 200$ ).

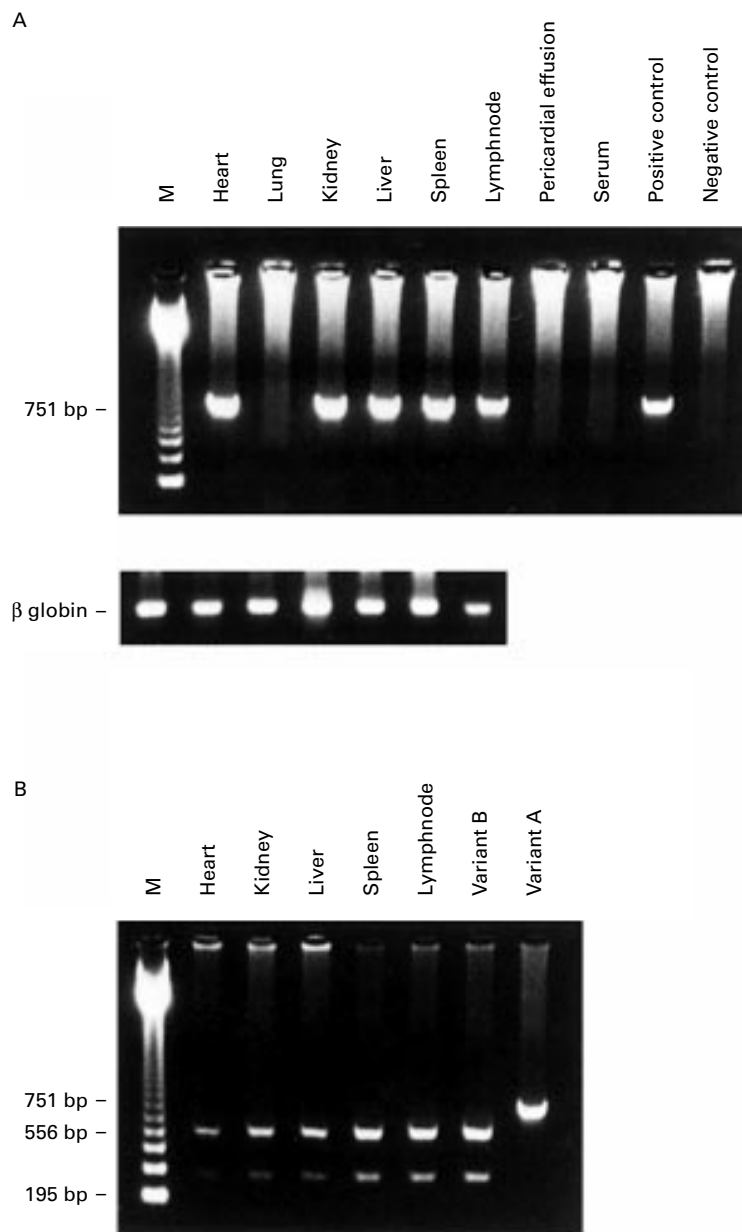


Figure 3 (A) Human herpesvirus 6 (HHV-6) DNA amplified by nested PCR. Positive bands are seen in the lanes indicating heart, liver, kidney, spleen, and lymph node. The  $\beta$  globin gene was amplified in all DNA specimens. (B) Second round PCR products extracted from heart, kidney, liver, spleen, and lymph node were digested in an HHV-6 variant B specific manner by HindIII. Variant B, FG-1 strain isolated from a patient with *exanthem subitum* in our facility; variant A, GS strain.

(815 U/litre; normal range, 50–210), indicating myocardial damage. Moreover, wide QRS tachycardia was evident on the electrocardiogram. During examinations, she had generalised convulsions and premature ventricular contractions. She was given diazepam and disopyramide phosphate intravenously. Finally, she was diagnosed with acute myocarditis, and transferred to Seirei Hamamatsu General Hospital to receive intensive treatment. However, she experienced cardiopulmonary arrest at the time of arrival. Resuscitation attempts were unsuccessful.

Serological examinations were carried out on a serum sample obtained at the time of necropsy. HHV-6 and human herpesvirus 7 (HHV-7) antibody titres were measured by an immunofluorescent assay, as described previously.<sup>6,7</sup> The results of the serological assays were: HHV-6 IgG, < 1 : 8; HHV-6 IgM, 1 : 8; HHV-7 IgG, 1 : 10; and HHV-7 IgM, < 1 : 10.

The postmortem examination disclosed that the main pathological lesion was in the heart. Diffuse infiltration of mononuclear cells and neutrophils, with oedematous change and degeneration and loss of myocardial cells, were seen in the interstitium of the myocardium and pericardial tissue, compatible with typical acute interstitial myocarditis (fig 1). The most characteristic observation was that many of the infiltrating cells in the lesion had apoptotic nuclei, which was confirmed by the TdT mediated dUTP biotin nick end labelling (TUNEL) method using ApoTag (Oncor, Gaithersburg, Maryland, USA), according to the manufacturer's instructions (fig 2). However, no apoptotic changes were seen in myocardial cells. In addition, calcification was occasionally seen in some myocardial cells. No arteriovascular malformation was found. No other abnormal findings were seen in lung, liver, kidneys, spleen, and thymus, except for generalised lymphadenopathy, with mild to moderate degrees of follicular hyperplasia.

At necropsy, we obtained serum and post-mortem tissue specimens including heart, lung, lymph node, thymus, liver, kidney, and spleen, and stored these samples at  $-80^{\circ}\text{C}$ . DNA was extracted by phenol/chloroform treatment, followed by ethanol precipitation from the tissue specimens. Total DNA (1  $\mu\text{g}$ , measured spectrophotometrically) extracted from each sample was used for the polymerase chain reaction (PCR). Nested PCR was carried out to detect HHV-6 and HHV-7 DNA in these samples. Details of the procedure for HHV-6 and HHV-7 PCR have been described elsewhere.<sup>8</sup> Figure 3A shows the PCR results. HHV-6 DNA was detected in heart, liver, kidney, spleen, and lymph node. However, HHV-7 DNA was not detected in these samples (data not shown). Aliquots of Tris/EDTA buffer were processed as negative controls, and appropriate precautions to avoid cross contamination were taken during sample preparation and while performing PCR. Moreover, all specimens were analysed using a primer to the  $\beta$  globin gene to confirm the absence of residual PCR inhibitors in the sample. Reverse transcription PCR was also carried out to detect enteroviral RNA in myocardial tissue, and was found to be negative (data not shown). The HHV-6 variant was identified by the presence or absence of the characteristic HindIII site in the second round PCR product; all products had the site that is indicative of the B variant (fig 3B).

We also carried out immunohistochemical analysis to detect HHV-6 antigens in tissue specimens including heart, lung, lymph node, thymus, liver, kidney, and spleen. A variant specific monoclonal antibody reactive with the p101 structural protein of HHV-6 variant B was used for this assay. The antibody, which

does not crossreact with the homologous protein of variant A HHV-6, was kindly supplied from Dr PE Pellet (Centers for Disease Control and Prevention, Atlanta, Georgia, USA). Moreover, the antibody was used to detect the virus antigen in postmortem tissues.<sup>9</sup> Immunohistochemical analysis was performed on paraffin wax embedded sections by an avidin–biotin complex (ABC) peroxidase method. None of these specimens was positive for HHV-6 antigen (data not shown).

### Discussion

HHV-6 is now classified into two distinct variants (variants A and B). Exanthema subitum, benign infantile febrile disease, is caused by primary infection with HHV-6 variant B.<sup>1</sup> Although the isolation of HHV-6 was not attempted, our patient demonstrated a typical clinical course of exanthem subitum, and was positive for anti-HHV-6 IgM. Moreover, both infection with HHV-7 (another aetiological agent for exanthem subitum) and enteroviruses was excluded. To identify the HHV-6 variant, we looked for the presence of a variant specific HindIII site in the second round PCR products from several tissues. All second round products would be digested at the appropriate site by the enzyme, indicating HHV-6 variant B. Therefore, we think that the aetiological agent in our patient was HHV-6 variant B.

Prezioso *et al* reported a 13 month old immunocompetent girl with fatal disseminated HHV-6 infection.<sup>10</sup> According to the postmortem findings, many organs including heart showed parenchymal damage. However, details of the pathological findings of the myocardium in the patient were not clearly described. Moreover, the clinical course of the patient was quite different from our case. In the Prezioso case, it seems that parenchymal damage in the patient's myocardium occurred secondarily to the main pathology caused by disseminated HHV-6 infection, and was not linked directly to the cause of her death. Recently, two children with myocardial damage have been reported, one suffered sudden infant death syndrome<sup>11</sup> and the other had encephalitis with subsequent infantile spasm.<sup>12</sup> However, the clinical features of these patients were clearly different from our patient. Our case showed a typical clinical course with pathological findings of acute myocarditis. Myocardial calcification has been seen in acute myocarditis,<sup>13</sup> and the absence of fibrotic changes excluded chronic myocarditis. The myocardial calcification was therefore considered to be caused by the acute myocarditis. To our knowledge, this is the first report of a fatal case with acute myocarditis, which appears to be caused by primary HHV-6 infection.

Our patient's past history did not suggest the presence of an obvious pre-existing immunodeficiency. Moreover, the patient's thymus and lymphoid tissues appeared to be morphologically adequate. Although productive infection of HHV-6 (HHV-6 antigen positive cells in the myocardial tissue) was not demonstrated, probably because of diminishing viraemia, HHV-6 DNA was detected in several tissues,

including the myocardium. We do not know whether these findings are related to unidentified immunosuppression in the host or whether they represent normal occurrences in immunocompetent children. Immunodeficiency caused by direct damage to thymic epithelial cells, which was speculated in the patient reported by Prezioso *et al*,<sup>10</sup> might be a possible mechanism for the dissemination of viral DNA. Alternatively, the HHV-6 DNA identified in these tissues might be attributable to infiltrating mononuclear cells latently infected with HHV-6. In any event, it is important to elucidate the complete pathophysiology of primary HHV-6 infection. The establishment of an animal model of HHV-6 infection might help to clarify the issue.

Mechanisms by which viral agents cause cardiac damage are still not completely understood; however, direct virus induced myocardial injury and virus induced autoimmune myocardial damage have been postulated. In our patient, it seems that myocarditis occurred just after cessation of HHV-6 viraemia. It is thought that natural killer cell activity and a virus specific immune response were induced at that time. Thus, it is speculated that the host immune response might have an important role in the pathogenesis of myocarditis. Moreover, in our case apoptotic changes were present in infiltrating mononuclear cells and neutrophils. Gebhard *et al* reported that, in perforin positive mice, which developed severe myocarditis as a result of coxsackie B infection, apoptotic cells were detected within the inflammatory infiltrate.<sup>14</sup> This finding is similar to that of our patient. Although the mechanisms of myocardial damage are not known, the infiltrating apoptotic cells might play an important role in the pathogenesis of the viral myocarditis. To elucidate the precise mechanisms for myocardial damage, further studies are necessary to characterise infiltrating cells, and to detect perforin in myocardial tissues by immunohistochemical analysis. Even though either direct myocardial damage by the viral infection or immune mediated myocardial impairment is involved in the pathogenesis of the myocarditis, it is probable that replication of the virus in the myocardial tissues is important. It is not known why viral antigen was not detected in the patient's myocardial tissues. The investigation of similar cases and pathological analysis using a more sensitive immunohistochemical method to detect the viral antigen is needed to determine whether replication of the virus occurs in the myocardial tissues.

This work was supported in part by grants from Fujita Health University and a Grant-in-Aid for Scientific Research, The Ministry of Education, Science and Culture, Japan. We thank Dr S Morimoto, Department of Internal Medicine, Fujita Health University for critically reviewing this manuscript. We also thank Mrs Y Sato for technical assistance in the detection of HHV-6 antigen. Recombinant human interleukin-2 was kindly supplied by Takeda Chemical Industries Ltd, Osaka, Japan.

- 1 Yamanishi K, Okuno T, Shiraki K, *et al*. Identification of human herpesvirus-6 as a causal agent for exanthem subitum. *Lancet* 1988;1:1065–7.
- 2 Asano Y, Yoshikawa T, Suga S, *et al*. Clinical features of infants with primary human herpesvirus 6 infection (exanthem subitum, roseola infantum). *Pediatrics* 1994;93:104–8.

- 3 Asano Y, Yoshikawa T, Suga S, *et al.* Fatal fulminant hepatitis in an infant with human herpesvirus 6 infection. *Lancet* 1990;1:862-3.
- 4 Huang LM, Lee CY, Lin KH, *et al.* Human herpesvirus-6 associated with fatal haemophagocytic syndrome. *Lancet* 1990;336:60-1.
- 5 Asano Y, Yoshikawa T, Kajita Y, *et al.* Fatal encephalitis/encephalopathy in primary human herpesvirus-6 infection. *Arch Dis Child* 1992;67:1484-5.
- 6 Yoshikawa T, Suga S, Asano Y, *et al.* Distribution of antibodies to a causative agent for exanthem subitum (human herpesvirus-6) in healthy individuals. *Pediatrics* 1989;84:675-7.
- 7 Yoshikawa T, Asano Y, Kobayashi I, *et al.* Seroepidemiology of human herpesvirus 7 in healthy children and adults in Japan. *J Med Virol* 1993;41:319-23.
- 8 Asano Y, Suga S, Yoshikawa T, *et al.* Clinical features and viral excretion in an infant with primary human herpesvirus 7 infection. *Pediatrics* 1995;95:187-90.
- 9 Drobyski WR, Knox KK, Majewski D, *et al.* Brief report: fatal encephalitis due to variant B human herpesvirus-6 infection in a bone marrow-transplant recipient. *N Engl J Med* 1994;330:1356-60.
- 10 Prezioso PJ, Cangiarella J, Lee M, *et al.* Fatal disseminated infection with human herpesvirus-6. *J Pediatr* 1992;120:921-3.
- 11 Hoang MP, Ross KF, Dawson DB, *et al.* Human herpesvirus-6 and sudden death in infancy: report of a case and review of the literature. *J Forensic Sci* 1999;44:432-7.
- 12 Rantala H, Mannonen L, Ahiluoto S, *et al.* Human herpesvirus-6 associated encephalitis with subsequent infantile spasms and cerebellar astrocytoma. *Dev Med Child Neurol* 2000;42:418-21.
- 13 Stallion A, Rafferty JF, Warner BW, *et al.* Myocardial calcification: a predictor of poor outcome for myocarditis treated with extracorporeal life support. *J Pediatr Surg* 1994;29:492-4.
- 14 Gebhard JR, Perry CM, Harkins S, *et al.* Coxsackievirus B3-induced myocarditis perforin exacerbates disease, but plays no detectable role in virus clearance. *Am J Pathol* 1998;153:417-28.



Want to know more?

### Data supplements

Limited space in printed journals means that interesting data and other material are often edited out of articles; however, limitless cyberspace means that we can include this information online. Look out for additional tables, references, illustrations.

[www.jclinpath.com](http://www.jclinpath.com)