

# Expression of killer cell inhibitory receptors is restricted to true NK cell lymphomas and a subset of intestinal enteropathy-type T cell lymphomas with a cytotoxic phenotype

D F Dukers\*, M H Vermeer\*, L H Jaspars, C A Sander, M J Flaig, W Vos, R Willemze, C J L M Meijer

## Abstract

**Background/Aims**—Killer inhibitory receptors (KIR) have a modulating effect on the cytotoxic functions of natural killer (NK) cells and T cells. Because lymphoma cells often have the same receptors as their non-neoplastic counterparts, this study investigated the expression of KIR on well defined groups of NK and T cell lymphomas, with and without a cytotoxic phenotype, from different sites of origin.

**Methods**—Nine CD56<sup>+</sup>/CD3<sup>-</sup> NK cell lymphomas, 29 CD3<sup>+</sup>/CD56<sup>-</sup> T cell lymphomas with a cytotoxic phenotype, and 19 T cell lymphomas without a cytotoxic phenotype were stained for KIR using monoclonal antibodies specific for CD94, CD158a, and CD158b. In addition, the expression of KIR was studied on normal lymphoid tissues.

**Results**—KIR expression was seen in five of nine true NK cell lymphomas including three of four nasal, one of four cutaneous, and one of one intestinal lymphoma nasal type. Double staining for CD56 and CD94 in normal lymphoid tissues revealed that KIR was predominantly expressed by CD56<sup>+</sup> NK cells and sporadically on CD8<sup>+</sup> T cells. Moreover, enteropathy-type T cell lymphomas with a cytotoxic phenotype showed KIR expression (three cases expressing CD94 and one case expressing CD158a). All nodal and extranodal non-intestinal T cell lymphomas with or without a cytotoxic phenotype lacked expression of KIR.

**Conclusions**—These results show that KIR expression is restricted to CD56<sup>+</sup>/CD3<sup>-</sup> true NK cell lymphomas originating from the nose, gut, and skin, as well as in a subset of extranodal T cell lymphomas originating from the small intestine, which possessed a cytotoxic phenotype. Thus, the presence of KIR on NK/T cell lymphomas seems to mimic the distribution of KIR found on NK and T cells in normal lymphoid tissue.

(J Clin Pathol 2001;54:224-228)

Keywords: lymphoma; granzyme B; killer inhibitory receptors; CD94

The classification of extranodal T cell and natural killer (NK) cell lymphomas is based on a combination of clinical, immunophenotypic,

cytogenetic, and molecular genetic features.<sup>1</sup> The development of monoclonal antibodies directed against components of cytotoxic granules, such as perforin, granzyme, and T cell intracytoplasmic antigen 1 (TIA-1),<sup>2,3</sup> has further detailed the immunophenotypical characteristics of T cell and NK cell lymphomas and led to the recognition of T cell and NK cell neoplasms with a cytotoxic phenotype.<sup>4-9</sup> The expression of cytotoxic proteins has been demonstrated in nodal anaplastic large cell lymphomas (ALCLs), angiocentric (nasal and nasal-type) NK/T lymphomas, hepatosplenic  $\gamma\delta$  T cell lymphomas, subcutaneous panniculitis-like T cell lymphomas, intestinal lymphoma nasal-type lymphomas, NK/T cell lymphomas in immunocompromised patients, mycosis fungoides (MF), and CD30 positive lymphoproliferative disorders arising in the skin.<sup>4,5,7-11</sup>

A new class of molecules has been discovered recently that can modulate the cytotoxic activity of NK and T cells. These killer cell inhibitory receptors (KIRs) were initially found on a subset of NK cells but subsequent studies revealed that in addition to NK cells, KIRs can also be detected on a subset of CD8 and, rarely, on CD4 positive lymphocytes. At present, two groups of KIR are known: the immunoglobulin (Ig) superfamily-like receptors (CD158a, CD158b, and NK1), which specifically recognise human major histocompatibility complex (MHC) antigen C (HLA-C) and HLA-B alleles, and the lectin-like receptors (CD94/NKG2A), which specifically recognise self MHC peptides presented by HLA-E.<sup>12-16</sup> In vitro studies revealed that ligation of KIR by HLA class I molecules on target cells results in inhibition of the NK cell mediated cytotoxicity or T cell receptor (TCR) mediated killing.<sup>17</sup> This inhibitory effect of KIRs on cellular cytotoxicity is mediated by so called ITIMs (immunoreceptor tyrosine based inhibition motifs), which upon phosphorylation can abrogate intracytoplasmic signal transduction. Current evidence suggests that KIRs are involved in peripheral regulatory mechanisms avoiding overwhelming immune responses during strong and/or long lasting immune activation.<sup>18,19</sup>

Earlier studies on the expression of KIRs are largely restricted to in vitro experiments and have focused on normal lymphoid subpopulations. The aims of our present study were to characterise the expression of KIRs on NK cell and T cell lymphomas. To this end, KIR

Departments of Pathology and Dermatology, Vrije Universiteit Amsterdam, De Boelelaan 1117, 1081 HV Amsterdam, The Netherlands  
D F Dukers  
M H Vermeer  
L H Jaspars  
W Vos  
R Willemze  
C J L M Meijer

Department of Dermatology, Ludwig Maximilians Universität München, 080337 Munich, Germany  
C A Sander  
M J Flaig

\*Both authors contributed equally to this study

Correspondence to: Dr Dukers  
d.dukers@azvu.nl

Accepted for publication 20 September 2000

Table 1 Expression of cytotoxic proteins and EBV status of neoplastic cells in nodal and extranodal lymphomas

Diagnosis	N	GrB/TIA-1	EBV	CD3	CD4	CD8	CD56
<i>True NK cell lymphomas</i>							
Nasal	4	4/4	4/4	0/4	0/4	0/4	4/4
Cutaneous	4	4/4	0/4	0/4	4/4	0/4	4/4
Intestinal lymphoma, nasal type	1	1/1	0/1	0/1	0/1	0/1	1/1
<i>T cell lymphomas with a cytotoxic phenotype</i>							
Enteropathy-type T cell lymphoma	5	5/5	0/2*	5/5	0/5	3/5	0/5
Nodal CD30 <sup>+</sup> ALCL	5	5/5	0/5	5/5	5/5	0/5	0/5
CD30 <sup>+</sup> cutaneous LTCL	5	3/5	0/5	5/5	5/5	0/5	0/5
Lymphomatoid papulosis	8	8/8	0/8	8/8	8/8	0/8	0/8
Mycosis fungoides	6	6/6	0/6	6/6	5/6	1/6	0/6
<i>T cell lymphomas without a cytotoxic phenotype</i>							
Mycosis fungoides	12	0/12	0/12	12/12	12/12	0/12	0/12
CD30 <sup>-</sup> cutaneous LTCL	2	0/2	0/2	2/2	2/2	0/2	0/2
Nodal T cell lymphoma NOS	5	0/5	0/5	5/5	5/5	0/5	0/5

\*Only two cases tested.

ALCL, anaplastic large cell lymphoma; EBV, Epstein-Barr virus; GrB, granzyme B; LTCL, large T cell lymphoma; NK, natural killer; NOS, not otherwise specified.

expression was investigated on a panel of CD56<sup>+</sup>/CD3<sup>-</sup> NK cell and CD56<sup>-</sup>/CD3<sup>+</sup> T cell lymphomas, and results were correlated with immunophenotype and the expression of cytotoxic proteins. As a control, KIR expression on normal lymphoid tissue was investigated.

## Materials and methods

### TISSUES

Frozen samples of NK and T cell lymphomas were selected from the archive of the department of pathology of the Academic Hospital Vrije Universiteit Amsterdam, department of pathology of the Leiden University Medical Center, and the department of dermatology, University Hospital Munich. These lymphomas were classified according to the World Health Organisation (WHO) classification,<sup>20</sup> whereas cutaneous lymphomas were classified according to the European Organisation for Research and Treatment of Cancer (EORTC) classification based on a combination of clinical, histological, and immunophenotypical data, as described previously.<sup>21</sup>

Three groups of NK/T cell lymphomas were investigated. The first group comprised true NK cell lymphomas originating from the nasopharyngeal tract (n = 4), the skin (n = 4), and gut (n = 1) as defined by the expression of CD56 and absence of CD3 (table 1). In all NK cell lymphomas the tumour cells expressed a cytotoxic phenotype as determined by granzyme B and TIA-1 staining. All NK cell lymphomas originating from the nasal mucosa and the intestinal lymphoma harboured the Epstein-Barr virus (EBV) in more than 90% of the neoplastic cells as detected by in situ hybridisation using the EBV encoded RNA 1 and 2 (EBER1/2) probe and immunohistochemical detection of latent membrane protein 1 (LMP1).<sup>22</sup>

The second group of lymphomas tested were T cell lymphomas with a cytotoxic phenotype defined by a CD3<sup>+</sup> immunophenotype in combination with granzyme B and TIA-1 expression. This group consisted of enteropathy-type T cell lymphoma (n = 5), nodal CD30<sup>+</sup> ALCL (n = 5), primary cutaneous CD30<sup>+</sup> large T cell lymphoma (LTCL; n = 5), lymphomatoid papulosis (LyP; n = 8), and MF (n = 6). All cases

had an CD3<sup>+</sup>/CD4<sup>+</sup> phenotype with the exception of two enteropathy-type T cell lymphoma (CD3<sup>+</sup>CD4<sup>-</sup>) and one case of MF, which expressed CD3 and CD8.

The third group were cutaneous T cell lymphomas without a cytotoxic phenotype, and comprised two cutaneous CD30<sup>-</sup> LTCLs, five nodal T cell lymphomas not otherwise specified (NOS), and 12 cases of MF without a cytotoxic phenotype. All 19 cases had a CD3<sup>+</sup>/CD4<sup>+</sup>/CD8<sup>-</sup> immunophenotype

### MONOCLONAL ANTIBODIES

Primary antibodies used for phenotyping the lymphoma cases were CD30 (BerH2; Dako, Glostrup, Denmark), CD3 (leu4; B&D, San Jose, California, USA), CD4 (leu3a; B&D), CD8 (RIV4; RIVM, De Bilt, the Netherlands), CD56 (B&D; IgG1 subtype), CD57 (B&D), CD68 (Dako), LMP1 (Organon Teknika, Boxtel, the Netherlands), granzyme B (GrB7; Kummer and colleagues<sup>2</sup>), and TIA-1 (Coulter Immunology, Hialeah, Florida, USA). For the detection of KIR, the following monoclonal antibodies were used: CD94 (Coulter; IgG2a subtype), CD158a (Coulter), and CD158b (Coulter)

### IMMUNOHISTOCHEMISTRY

Frozen tissue sections were fixed with paraformaldehyde (4%, 10 minutes) and subsequently stained using a standard three step streptavidin-biotin complex based method with diaminobenzidine (DAB) as chromogen, as described previously.<sup>23</sup> Only GrB7 required antigen retrieval by microwave irradiation for 10 minutes in citrate buffer (10 mM/litre, pH 6.0, at 700 W).

For the detection of KIR expression, frozen acetone fixed sections were incubated with the primary antibodies (60 minutes), followed by incubation of a biotinylated second antibody (30 minutes). After washing in phosphate buffered saline, streptavidin alkaline phosphatase was applied and subsequently the alkaline phosphatase label was visualised by new fuchsin.

Double staining for CD94/CD56 or CD94/CD8 on acetone fixed frozen tissue was performed by simultaneous incubation with primary antibodies, followed by simultaneous

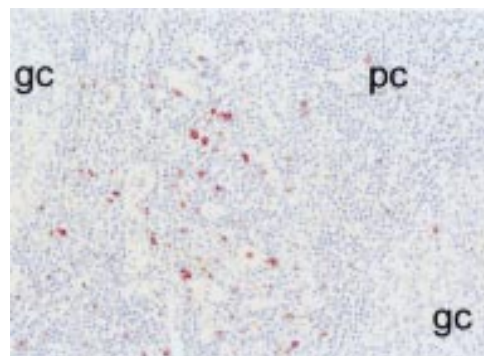


Figure 1 Staining of a tonsil for CD94. CD94 positive cells are predominantly detected in the paracortical areas of tonsils. gc, germinal centre; pc, paracortical area.

incubation with horseradish peroxidase labelled goat antimouse IgG1 and biotin labelled goat antimouse IgG2a (30 minutes) for the detection of CD56 and CD94, respectively. The horseradish peroxidase was visualised by fluorescein conjugated tyramine,<sup>24,25</sup> whereas the biotin label was detected with cy3 conjugated streptavidin.

#### CONTROLS

Frozen sections of lymphoid tissue (tonsil, lymph nodes, spleen, and thymus) were used as controls for the immunohistochemical detection of KIR expression. In addition, double staining for CD94 in combination with either CD56 or CD8 was performed to identify the cellular origin of the KIR expressing cells.

#### INTERPRETATION OF IMMUNOHISTOCHEMISTRY

The identification of neoplastic T cells was based on a combination of morphology and phenotype. In all cases, serial sections stained with monoclonal antibodies against CD3, CD4, CD8, CD56, and CD68 were used as an additional tool to differentiate the neoplastic T cells from reactive CD8<sup>+</sup>/CD56<sup>+</sup> T/NK cells and dendritic cells/macrophages. Cases were scored positive when > 50% of morphologically recognisable neoplastic cells stained positive.

#### Results

##### CONTROL TISSUE

In all lymphoid tissue tested (tonsil, lymph nodes, thymus, and spleen) KIR positive cells were identified. KIR positivity (either CD94, CD158a, or CD158b) was seen as membranous staining in T cell areas (fig 1). Positive cells comprised up to 5% of the total number of lymphocytes. In all cases, there were more CD94 positive cells than CD158b positive cells, which in turn outnumbered the CD158a cells. Double staining for CD56 and CD94 demonstrated co-expression of these molecules in most CD94 positive cells, but colocalisation of CD8 with CD94 was limited to a few scattered cells (fig 2), indicating that KIRs are predominantly found on NK cells and sporadically on CD8<sup>+</sup> T cells.

##### TRUE NK CELL LYMPHOMAS

KIR expression was found in five of nine true NK cell lymphomas (table 2). The expression of CD94 was detected in five of nine cases,

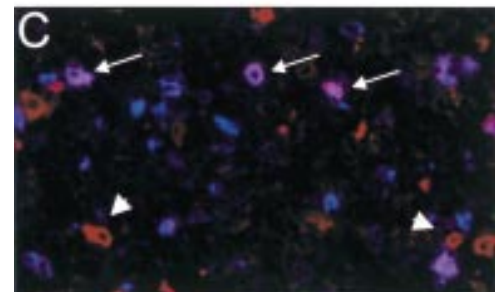
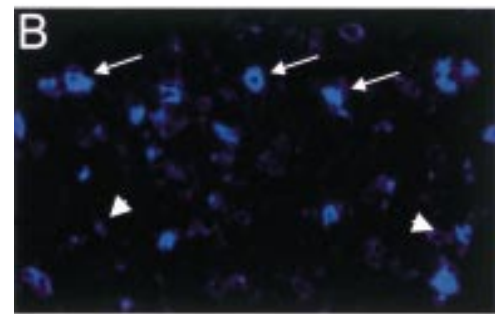
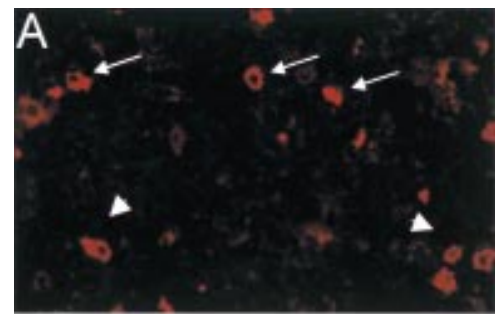


Figure 2 Immunofluorescent double staining for (A) CD56 (red) and (B) CD94 (blue) on normal tonsil. (C) CD56<sup>+</sup>/CD94<sup>+</sup> natural killer (NK) cells (purple) are indicated by arrows, whereas arrowheads indicate CD56<sup>+</sup>/CD94<sup>+</sup> NK cells.

whereas the expression of CD158a was limited to three of nine cases and the expression of CD158b was found in only one of nine cases.

In all cases positive for CD94, CD158a, or CD158b a strong membranous staining was seen in nearly all the tumour cells. The expression of multiple KIRs was seen in three cases, two nasal NK lymphomas (fig 3) and one case of intestinal lymphoma, nasal type. In two cases, a combination of CD94 and CD158a was detected and in one case a combination of CD94 with both CD158a and CD158b was found. The proportion of cases expressing KIRs varied between different localisations of NK lymphomas. KIR expression was detected in the one case of intestinal lymphoma, nasal type, in three of four nasal NK/T cell lymphomas, and in one of four cutaneous NK cell lymphomas.

Scattered CD94, CD158a, or CD158b positive lymphocytes in the reactive infiltrate were seen in all cases.

Table 2 Expression of killer cell inhibitory receptor in nodal and extranodal lymphomas

Diagnosis	N	CD94	CD158a	CD158b
<i>True NK cell lymphomas</i>				
Nasal	4	3/4	2/4	0/4
Cutaneous	4	1/4	0/4	0/4
Intestinal lymphoma, nasal type	1	1/1	1/1	1/1
<i>T cell lymphomas with a cytotoxic phenotype</i>				
Enteropathy-type T cell lymphoma	5	3/5	1/5	0/5
Nodal CD30 <sup>+</sup> ALCL	5	0/5	0/5	0/5
CD30 <sup>+</sup> cutaneous LTCL	5	0/5	0/5	0/5
Lymphomatoid papulosis	8	0/8	0/8	0/8
Mycosis fungoides	6	0/6	0/6	0/6
<i>T cell lymphomas without a cytotoxic phenotype</i>				
Mycosis fungoides	12	0/12	0/12	0/12
CD30 <sup>+</sup> cutaneous LTCL	2	0/2	0/2	0/2
Nodal T cell lymphoma NOS	5	0/5	0/5	0/5

ALCL, anaplastic large cell lymphoma; LTCL, large T cell lymphoma; NK, natural killer; NOS, not otherwise specified.

#### T CELL LYMPHOMAS WITH A CYTOTOXIC PHENOTYPE

Despite the presence of a cytotoxic phenotype in the enteropathy-type T cell lymphomas (n = 5), nodal CD30<sup>+</sup> ALCLs (n = 5), primary cutaneous CD30<sup>+</sup> LTCLs (n = 5), LyPs (n = 8), and MFs (n = 6), CD94 expression was detected in only four cases of enteropathy-type T cell lymphoma, and in the other T cell lymphomas CD94, CD158a, or CD158b expression was not found. In these biopsies, the reactive lymphocytes served as a useful internal control showing scattered CD94<sup>+</sup> and CD158b<sup>+</sup> cells in up to 5% of the total infiltrating lymphocytes. The expression of CD158a in reactive lymphocytes was detected in a few cases and was always < 1% of the total number of reactive lymphocytes. Adjacent enteropathy associated mucosa could not be evaluated in the frozen sections of the five enteropathy-type T cell lymphomas.

#### T CELL LYMPHOMAS WITHOUT A CYTOTOXIC PHENOTYPE

In the two cutaneous CD30<sup>-</sup> LTCLs, five nodal T cell lymphomas NOS, and 12 cases of MF without a cytotoxic phenotype, KIR expression was not detected on the neoplastic T cells. Again, the reactive lymphocytes served as a useful internal control, showing scattered CD94<sup>+</sup> and CD158b<sup>+</sup> cells in up to 5% of the total infiltrating lymphocytes. However, CD158a expression was not detected on reactive cells.

#### Discussion

Non-Hodgkin's lymphoma (NHL) cells are considered to be neoplastic counterparts of functional, recirculating, site restricted lymphocytes and as such have many characteristics in common with their normal counterparts. The main finding of our present study is that the expression of KIRs, a new class of MHC class I specific receptors, is restricted to true NK cell lymphomas. We demonstrate the expression of KIRs in CD56<sup>+</sup>/CD3<sup>-</sup> NK cell lymphomas arising in the nasopharyngeal tract, and in intestinal lymphomas, nasal-type lymphomas, and primary cutaneous NK cell lymphomas.

Expression of CD94 was more frequently detected (five of nine cases) than CD158a (three of nine cases) and CD158b (one of nine cases), similar to the staining pattern of KIRs in normal NK cells in lymph nodes, tonsils, spleen, and thymus. In addition, combinations of CD94 with CD158a and CD158b were detected in a few cases. Interestingly, in a study by Mingari *et al* an identical pattern of KIR expression was described in blood derived NK cells as determined by fluorescence activated

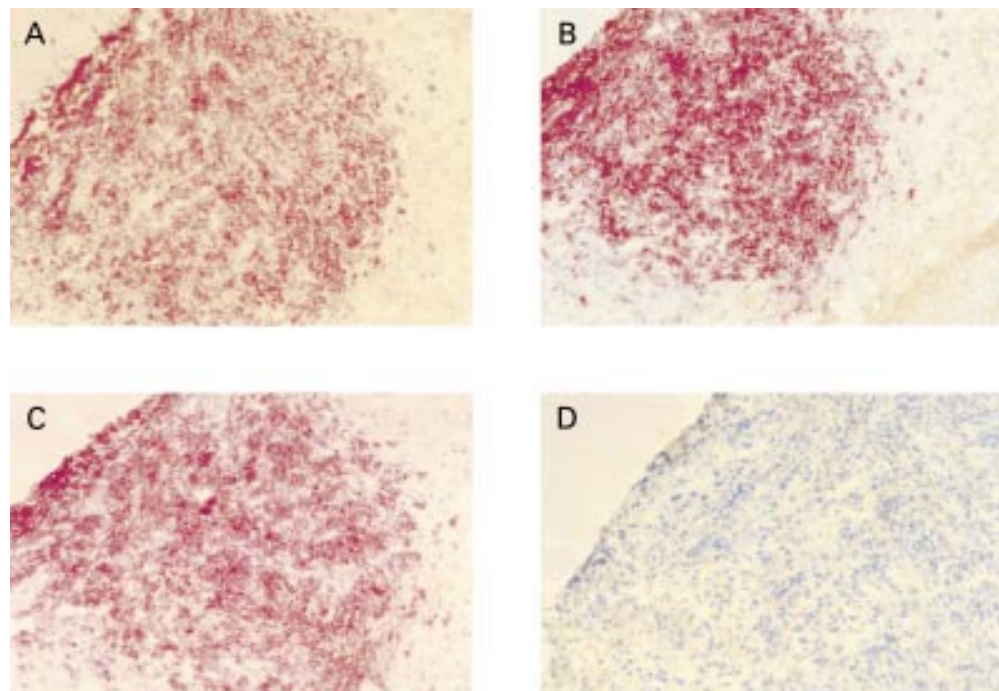


Figure 3 (A) Killer cell inhibitory receptor (KIR) expression on a CD56<sup>+</sup>/CD3<sup>-</sup> nasal natural killer cell lymphoma. In addition, neoplastic cells were (B) positive for CD94 and (C) CD158a, but (D) negative for CD158b.

cell sorter (FACS) analysis.<sup>26</sup> Taken together, these data further support the concept that the neoplastic cells of lymphomas with a CD56<sup>+</sup>/CD3<sup>-</sup> NK cell phenotype in the nasopharyngeal tract, the gastrointestinal tract, and skin all originate from NK cells.

In contrast to true NK cell lymphomas, the expression of CD94 was also found on four cases of enteropathy-type T cell lymphoma with a cytotoxic phenotype. Again, this is in line with *in vitro* experiments where chronic activation of T cells induces the expression of cytotoxic proteins in a subset of T cells in combination with the expression of KIRs on a few of these lymphocytes.<sup>26</sup> Our data are in line with the study of Haedicke *et al*, in which three T cell lymphomas with a cytotoxic phenotype originating from the small intestine showed expression of CD94.<sup>27</sup> One of these cases was a  $\gamma\delta$  T cell lymphoma arising from the spleen. Because of the lack of frozen material, no  $\gamma\delta$  T cell lymphomas were included in our study.

Previous studies showed that NK cells can express several members of the KIR family at the same time, resulting in different NK cell subsets, probably with distinct functions.<sup>15, 28</sup> It would be worthwhile to perform a large multicentre study to see whether lymphomas expressing certain subsets of KIR on their neoplastic cells form separate clinicopathological entities.

In conclusion, our study reveals that KIR expression is restricted to CD56<sup>+</sup>/CD3<sup>-</sup> true NK cell lymphomas originating from the nose, gut, and skin, as well as in a subset of extranodal T cell lymphomas originating from the small intestine, which possessed a cytotoxic phenotype. Thus, the presence of KIRs on NK/T cell lymphomas seems to mimic the distribution of KIRs found on NK and T cells in normal lymphoid tissue.

We thank Professor Ph M Kluin and Dr A Neefjes-Borst for providing material. Professor A Chott is gratefully acknowledged for helpful discussions.

- 1 Jaffe ES, Krenacs L, Kumar S, *et al*. Extranodal peripheral T-cell and NK-cell neoplasms. *Am J Clin Pathol* 1998;110(suppl):46–55.
- 2 Kummer JA, Kamp AM, van Katwijk M, *et al*. Production and characterization of monoclonal antibodies raised against recombinant human granzymes A and B showing cross reactions with the natural proteins. *J Immunol Methods* 1993;163:77–83.
- 3 Anderson P, Nagler-Anderson C, O'Brien C, *et al*. A monoclonal antibody reactive with a 15 kDa cytoplasmic granule-associated protein defines a subpopulation of CD8<sup>+</sup> T-lymphocytes. *J Immunol* 1990;144:574–82.
- 4 Bruin de PC, Kummer JA, Valk van der P, *et al*. Granzyme B expressing peripheral T-cell lymphomas: neoplastic equivalents of activated cytotoxic T-cells with preference for mucosa associated lymphoid tissue (MALT) localization. *Blood* 1994;84:3785–91.
- 5 Bruin de PC, Connolly CE, Oudejans JJ, *et al*. Enteropathy-associated T cell lymphomas have a cytotoxic T-cell phenotype. *Histopathology* 1997;31:313–17. [Erratum published in *Histopathology* 1997;31:578.]
- 6 Foss HD, Anagnostopoulos I, Araujo I, Assaaf C, *et al*. Anaplastic large cell lymphomas of T-cell and null cell phenotype express cytotoxic molecules. *Blood* 1996;88:4005–11.

- 7 Krenacs L, Wellmann A, Sorbara L, *et al*. Cytotoxic cell antigen expression in anaplastic large cell lymphomas of T- and null cell type and Hodgkins disease: evidence for distinct cellular origin. *Blood* 1997;89:980–9.
- 8 Kummer JA, Vermeer MH, Dukers D, *et al*. Most primary cutaneous CD30 positive lymphoproliferative disorders have a CD4 positive cytotoxic T-cell phenotype. *J Invest Dermatol* 1997;109:636–40.
- 9 Dukers DF, ten Berge RL, Oudejans JJ, *et al*. A cytotoxic phenotype does not predict clinical outcome in anaplastic large cell lymphomas. *J Clin Pathol* 1999;52:129–36.
- 10 Oudejans JJ, Kummer JA, Jiwa NM, *et al*. Granzyme B expression in Reed-Sternberg cells of Hodgkin's disease. *Am J Pathol* 1996;148:233–40.
- 11 Vermeer MH, Geelen FAMJ, Kummer JA, *et al*. Expression of cytotoxic proteins by neoplastic T cells in mycosis fungoides increases with progression from plaque stage to tumour stage disease. *Am J Pathol* 1999;154:1203–10.
- 12 Moretta A, Boltino C, Pende D, *et al*. Identification of subsets of human CD3–CD16<sup>+</sup> NK cells by the expression of clonally distributed surface molecules. Correlation between subset assignment of NK clones and ability to mediate specific allo antigen recognition. *J Exp Med* 1990;172:1589–98.
- 13 Moretta L, Ciccone E, Mingari MC, *et al*. Human NK receptors: origin, clonality specificity and receptors. *Adv Immunol* 1994;55:341–80.
- 14 Moretta A, Moretta L. HLA class I specific inhibitory receptors. *Curr Opin Immunol* 1997;9:694–701.
- 15 Wagtman N, Biassoni R, Cantoni C, *et al*. Molecular clones of the p58 NK cell receptor reveal immunoglobulin-related molecules with diversity in both the extra- and intracellular domains. *Immunity* 1995;2:439–49.
- 16 Lee M, Llano M, Carratero M, *et al*. HLA-E is a major ligand for the NK inhibitory receptor CD94/NKG2a. *Proc Natl Acad Sci U S A* 1998;95:4791–4.
- 17 Mingari MC, Schiavetti F, Ponte M, *et al*. Human CD8<sup>+</sup> T lymphocyte subsets that express HLA I-specific inhibitory receptors represent oligoclonally or monoclonally expanded cell populations. *Proc Natl Acad Sci U S A* 1996;93:12433–8.
- 18 Azuma M, Phillips JH, Lanier LL. CD28<sup>+</sup> T lymphocytes. Antigenic and functional properties. *J Immunol* 1993;150:1147–59.
- 19 Speiser DE, Valmori D, Rimoldi D, *et al*. CD28<sup>+</sup> cytolytic effector T cells frequently express NK receptors and are present at variable proportions in circulating lymphocytes from healthy donors and melanoma patients. *Eur J Immunol* 1999;29:1990–9.
- 20 Harris NL, Jaffe ES, Diebold J, *et al*. The World Health Organisation classification of neoplastic diseases of the hematopoietic and lymphoid tissues. Report of the clinical advisory committee meeting—Airlie House, Virginia, November 1997. *J Clin Oncol* 1999;17:3835–49.
- 21 Willemze R, Kerl H, Sterry W, *et al*. EORTC classification for primary cutaneous lymphomas—a proposal from the cutaneous lymphoma study group of the European Organization for Research and Treatment of Cancer. *Blood* 1997;90:354–71.
- 22 Jiwa NM, Kanavaros P, De Bruin PC, *et al*. Presence of Epstein-Barr virus harbouring small and intermediate-sized cells in Hodgkin's disease: is there a relationship with Reed-Sternberg cells? *J Pathol* 1993;170:129–36.
- 23 Oudejans JJ, Kummer JA, Jiwa M, *et al*. Granzyme B expression in Reed-Sternberg cells of Hodgkin's disease. *Am J Pathol* 1996;148:233–40.
- 24 Bobrow MN, Harris TD, Shaughnessy KJ, *et al*. Catalyzed reporter deposition, a novel method of signal amplification. I. Application to immunoassays. *J Immunol Methods* 1989;125:279–85.
- 25 Bobrow MN, Shaughnessy KJ, Litt GJ. Catalyzed reporter deposition, a novel method of signal amplification. II. Application to membrane immunoassays. *J Immunol Methods* 1991;137:103–12.
- 26 Mingari MC, Ponte M, Cantoni C, *et al*. HLA-class I specific inhibitory receptors in human cytolytic T lymphocytes. Molecular characterization, distribution in lymphoid tissues and coexpression by individual T cells. *Int Immunol* 1997;9:485–91.
- 27 Haedicke W, Ho FCS, Chott A, *et al*. Expression of CD94/NKG2A and killer immunoglobulin-like receptors in NK-cell and a subset of extranodal cytotoxic T-cell lymphomas. *Blood* 2000;95:3628–30.
- 28 Valiante NM, Uhrberg M, Shilling HG, *et al*. Functionally and structurally distinct NK cell receptor repertoires in the peripheral blood of two human donors. *Immunity* 1997;7:739–51.