

# The histopathology of non-steroidal anti-inflammatory drug induced gastroduodenal damage: correlation with *Helicobacter pylori*, ulcers, and haemorrhagic events

M Frezza, N Gorji, M Melato

## Abstract

**Aims**—The spectrum of microscopic lesions resulting from the chronic use of non-steroidal anti-inflammatory drugs (NSAIDs), known as chemical gastritis, remains unclear, and the variable prevalence reported in different studies makes this issue a matter of lively debate. The aim of this study was to evaluate the prevalence and importance of chemical gastritis in patients regularly taking NSAIDs. Owing to the high prevalence of *Helicobacter pylori* infection, particularly in subjects over 60 years of age, and in view of a possible association with damage, the presence of *H pylori* infection in the same tissue sample was also determined in all patients.

**Methods**—One hundred and ninety seven subjects were enrolled, 118 of whom were receiving chronic treatment with NSAIDs and 79 of whom were controls, pair matched for age, sex, and clinical symptoms (ulcer-like dyspepsia or upper digestive tract haemorrhage). Antral biopsies taken during upper gastroduodenal endoscopy were assessed for chemical gastritis according to a modified version of Dixon's score, and for helicobacter correlated chronic active gastritis, according to the updated Sydney system.

**Results**—Chemical gastritis was identified in 11 patients taking NSAIDs (9%) and in four controls (5%) ( $p < 0.05$ ). *Helicobacter pylori* was detected in 53 patients taking NSAIDs (45%) and in 34 controls (43%). Patients taking NSAIDs had a significantly higher number of erosions and ulcers and worse endoscores than controls. The presence of *H pylori* did not appear to increase histological damage, ulcer prevalence, or haemorrhagic events.

**Conclusions**—Chemical gastritis is present in a limited number of patients regularly taking NSAIDs, and is not strongly correlated with NSAID induced damage. In many cases of peptic ulcer or upper gastrointestinal bleeding in patients taking NSAIDs, the presence of chemical gastritis or *H pylori* infection cannot solely account for the development of mucosal damage.

(J Clin Pathol 2001;54:521–525)

Keywords: chemical gastritis; non-steroidal anti-inflammatory drugs; *Helicobacter pylori*

The chronic use of non-steroidal anti-inflammatory drugs (NSAIDs) is a common cause of gastroduodenal erosions and peptic ulcers resulting, in many cases, in fatal haemorrhage.<sup>1–10</sup>

NSAIDs and *Helicobacter pylori* infection are thought to be the two most important exogenous factors in gastric and duodenal ulcer disease. The relative frequency of *H pylori* and NSAIDs as the cause of peptic ulcers varies and is, at least in part, correlated to the prevalence of *H pylori* infection and the use of NSAIDs in a population,<sup>11</sup> as well as to the expertise in identifying the presence of *H pylori* infection.<sup>12</sup>

The clinical and demographic data of NSAIDs and *H pylori* related gastroduodenal ulcers are considerably different. Whereas the histopathology of *H pylori* correlated gastritis is associated with well defined histological features,<sup>13</sup> the spectrum of microscopic gastric lesions caused by chronic ingestion of NSAIDs is unspecific and is currently a matter of lively debate.<sup>14–18</sup>

Moreover, because NSAIDs are widely used in the elderly<sup>19</sup> and the incidence of *H pylori* infection is increased in the elderly,<sup>20</sup> *H pylori* should be present in almost 50% of those patients over 60 years taking NSAIDs.

Although the damage mechanisms of these two factors probably follow independent pathways,<sup>21–23</sup> from a practical point of view it is important to establish whether their effects are the sum of two independent forms of injury (additive effect) or whether one form of injury can enhance the effect of the other (synergistic effect). Similarly, it is crucial to determine whether we should diagnose and cure *H pylori* infection in all patients about to undergo long term treatment with NSAIDs.

The aim of our study was to define the histological spectrum of the gastric damage seen in symptomatic patients who are regular users of NSAIDs and its relation to *H pylori* infection, endoscopic lesions (erosions and/or ulcers), and a major clinical event such as haemorrhage.

## Patients and methods

One hundred and eighteen adult patients treated regularly with NSAIDs for a variety of conditions and observed in our unit for signs of potential injury to the gastroduodenal mucosae (such as ulcer-like dyspepsia or upper intestinal tract haemorrhage) were examined by upper gastroduodenal endoscopy. All the patients

Unit of  
Gastroenterology,  
General Hospital,  
I-34149 Trieste, Italy  
M Frezza

Department of  
Pathological Anatomy,  
General Hospital and  
University of Trieste  
N Gorji  
M Melato

Correspondence to:  
Professor Frezza, Servizio di  
Gastroenterologia ed  
Endoscopia Digestiva,  
Ospedale di Cattinara,  
Strada di Fiume 447,  
I-34149 Trieste, Italy  
mario.frezza@aots.sanita.fvg.it

Accepted for publication 16  
January 2001

with haemorrhage presented melena or haematemesis of mild or medium severity; to be enrolled, however, they had to be able to undergo the endoscopic examination. The drugs, which had been used for at least one month at the dosage indicated, were: aspirin (100–200 mg), diclofenac (100–200 mg), naproxen (500–1000 mg), and ketoprofen (100–200 mg/day) in 68, 22, nine, and 19 patients, respectively. Seventy nine subjects not regularly taking NSAIDs, pair matched for age, sex, race, and symptoms, were used as controls. The exclusion criteria were: recent use of antibiotics, antisecretory (particularly proton pump inhibitors) or cytostatic drugs, and previous gastroduodenal surgery. All patients were asked for complete clinical notes and were questioned about habits such as smoking and alcohol intake. Informed consent was obtained before the upper gastroduodenal endoscopy, which was performed without medication.

The endoscopic lesions were graded according to the following score<sup>14</sup>: 0, minor erythema; 1, antral or duodenal erosions ( $\leq 5$ ); 2, antral and duodenal erosions (or  $> 5$ ); 3, ulcerations measuring 5 mm in diameter or more.

A set of two to four mapped antrum biopsy specimens was obtained from patients and controls. Histology of all biopsies, processed routinely and stained by haematoxylin and eosin, according to the method of May-Grünwald-Giemsa, was assessed independently and blindly by two different pathologists trained in gastrointestinal pathology, and a third pathologist was consulted in the event of disagreement.

Chronic inflammation (CI), *H pylori* density (HpD), polymorphonuclear neutrophil activity (PNA), glandular atrophy (GA), and intestinal metaplasia (IM) were classified according to the updated Sydney system.<sup>24</sup> To improve comparability of parameters, specimens were scored for HpD, IM, and GA as positive (1) or negative (0); CI and PNA were graded as negative (0), mild (1), moderate (2), or pronounced (3). Patients scoring 4 or more were considered to have chronic active gastritis. This form is characterised by a high infiltration of polymorphonuclear neutrophils (PMN) attracted to the tissue by the presence of *H pylori* (fig 1).

All biopsies were also graded according to a modified version of Dixon's system for chemical gastritis.<sup>25</sup> Foveolar hyperplasia, oedema, and prominent smooth muscle fibres were graded as absent (0) or present (1) because, in our experience, a more extensive score does not work; loss of PMN and plasma cells were scored inversely from many (0) to absent (3). Vasodilatation and congestion were not considered because, in our view, they are mostly the result of bioptic trauma and are therefore also present in patients from the control group. Patients scoring more than 6 were considered to have chemical gastritis (fig 2).

The data were analysed using the  $\chi^2$  test for the per cent values and the Student's paired *t* test for the comparison of mean values; *p*

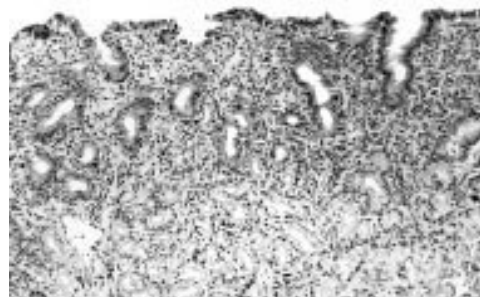


Figure 1 A case of helicobacter correlated chronic active gastritis with evident infiltration of polymorphonuclear neutrophils (haematoxylin and eosin stained).

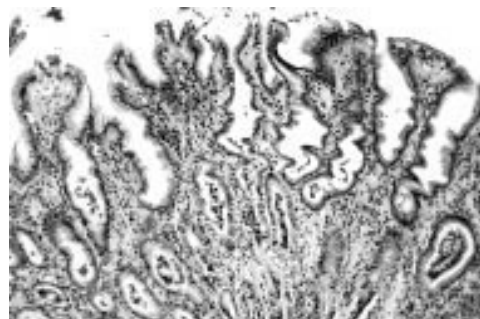


Figure 2 A case of chemical gastritis showing absence of polymorphonuclear neutrophils and evident foveolar hyperplasia (haematoxylin and eosin stained).

values  $< 0.05$  were considered significant. Statistical analysis was performed with the SPSS for Windows Release 7.1 (Microsoft).

## Results

A total of 197 subjects were examined, 118 of whom were regular NSAID users, and 79 of whom were controls. Table 1 gives the demographic and clinical details of the patients and controls.

Table 2 details the histological pattern of the antral mucosa seen in the two groups. Chemical gastritis was only present in a minority of patients using NSAIDs, but its prevalence was

Table 1 Demographic and clinical details of patients and controls

	NSAID users (n = 118)	Controls (n = 79)
Sex (M/F)	51/67	31/48
Mean age (range), years	66.5 (22–88)	67.3 (21–87)
Smokers	40	18
Alcoholics	No	No
Signs of potential gastroduodenal mucosal injury		
Ulcer-like dyspepsia	94	63
Haemorrhages	24	16

NSAID, non-steroidal anti-inflammatory drugs.

Table 2 Histological pattern of antral mucosa in the two groups

	NSAID users (n = 118)	<i>p</i> Value	Controls (n = 79)
Chemical gastritis	11 (9%)	$< 0.05$	4 (5%)
Active gastritis	34 (29%)	NS	15 (19%)
Chronic gastritis	64 (54%)	NS	53 (67%)
No lesions	9 (8%)	NS	7 (9%)
<i>Helicobacter pylori</i>	53 (45%)	NS	32 (41%)

Significance was calculated by means of the  $\chi^2$  test.

NS, not significant; NSAID, non-steroidal anti-inflammatory drugs.

Table 3 Endoscopic and histological findings in NSAID users and controls complaining of ulcer-like dyspepsia

	NSAID users (n = 94)	p Value	Controls (n = 63)
Erosions	33 (35%)	<0.05	15 (24%)
Ulcers	22 (23%)	<0.001	4 (6%)
Mean endoscore (SD)	1.20 (0.48)	<0.05	0.46 (0.21)
Chemical gastritis	8 (8%)	NS	3 (5%)
Active gastritis	20 (21%)	NS	12 (19%)
<i>Helicobacter pylori</i>	45 (48%)	NS	26 (41%)

Significance was calculated by means of the Student's *t* test for mean values and the  $\chi^2$  test for percentages.

NS, not significant; NSAID, non-steroidal anti-inflammatory drugs.

Table 4 Endoscopic and histological findings in NSAID users according to *Helicobacter pylori* infection

	<i>Helicobacter present</i> (n = 53)		<i>Helicobacter absent</i> (n = 65)
Age (years)	67.3 (40–84)		66.1 (22–88)
Erosions	23 (43%)	NS	24 (37%)
Ulcers	17 (32%)	NS	21 (32%)
Mean endoscore (SD)	1.28 (0.38)	NS	1.27 (0.21)
Chemical gastritis	0 (0%)	–	11 (17%)
Active gastritis	17 (32%)	p <0.03	7 (11%)

Significance is calculated by means of the Student's *t* test for means and  $\chi^2$  for percentages.

NS, not significant; NSAID, non-steroidal anti-inflammatory drug.

higher than in controls. The other types of gastritis (chronic active gastritis and chronic non-active gastritis, or, strictly speaking, chronic gastritis) were equally distributed across the two groups, with the most common form being chronic non-active gastritis. The prevalence of *H pylori* (~40–50%) was not significantly different in the two groups.

Of the patients complaining of ulcer-like dyspepsia (table 3), the group of NSAID users had significantly more endoscopic lesions (erosions and/or ulcers), although the percentage of chemical or active gastritis did not reach significance. The number of patients infected with *H pylori* was similar in the two groups (48% v 41%).

With regard to *H pylori* in the NSAID user group (table 4), the 53 *H pylori* positive patients had similar endoscopic patterns to the 65 *H pylori* negative patients, as well as a higher percentage of active gastritis and no cases of chemical gastritis.

A total of 38 ulcers—21 duodenal, 15 gastric, and two gastric and duodenal—were diagnosed in the patients taking NSAIDs, 17 of whom were *H pylori* positive (seven gastric and 12 duodenal ulcers). Within this group, the distribution of chemical and active gastritis was not significantly different between the patients with and without ulcers, whereas the number of erosions was higher in the last subgroup (table 5).

Table 5 Endoscopic and histological findings in NSAID users according to the presence of ulcers and haemorrhagic events

Patients	Erosions	Mean endoscore (SD)	Chemical gastritis	<i>Helicobacter pylori</i>
Ulcers (n = 38)	6 (16%)	3.0 (0.0)	3 (8%)	17 (45%)
No ulcers (n = 80)	40 (49%)*	0.57 (0.31)*	7 (9%)	36 (45%)
Haemorrhages (n = 24)	10 (42%)	2.41 (0.51)	3 (12%)	8 (33%)
No haemorrhages (n = 94)	33 (35%)	1.20 (0.48)†	8 (8%)	45 (48%)

Significance was calculated by means of the Student's *t* test for means and  $\chi^2$  test for percentages.

\*p <0.01 between patients with and without ulcers.

†p <0.05 between patients with and without haemorrhages.

NSAID, non-steroidal anti-inflammatory drug.

Patients in the control group had a total of 12 ulcers—nine duodenal, two gastric, and one gastric and duodenal—and only six of these patients were positive for *H pylori* infection.

NSAID users complaining of one or more haemorrhagic episodes had more ulcers and worse endoscores than the others, although the prevalence of chemical and active gastritis did not reach significance. The prevalence of *H pylori* was considerably, although not significantly, lower (33% v 48%) than in those patients without haemorrhage (table 5).

Finally, all the NSAIDs used in our series had a low damaging profile, which might account for the fact that we did not find a significant correlation between the severity of the endoscopic and/or histological finding and the type of drug used.

## Discussion

In 1986, Dixon *et al* investigated several morphological parameters of the gastric mucosa (foveolar hyperplasia, occurrence of smooth muscle fibres and oedema in the lamina propria, vasodilatation, congestion of superficial capillaries, and paucity of both acute and chronic inflammatory cells) and found a strong association between severe grades of each of these histological variables and both hypochlorhydria and increased bile acid concentrations in the stomach, suggesting that reflux gastritis was a distinct histopathological entity.<sup>25</sup> A few years later, Sobala *et al* stated that most cases of so called “reflux gastritis” in the intact stomach did not result from the reflux of bile, but were caused by NSAID use, and suggested calling this type of gastritis “C” or “chemical”.<sup>26</sup> In 1992, Laine *et al* considered a different set of morphological parameters and concluded that the development of ulcers (but not gastritis) in patients taking NSAIDs did not require *H pylori*.<sup>27</sup>

Caselli *et al* reported that distinguishing features in patients treated with NSAIDs were erosions, macroerosions, and the presence of prominent capillaries in suberosive areas of the lamina propria.<sup>16</sup> Finally, El-Zimaity *et al* concluded that none of these histological features could be used singularly to characterise the diagnosis of chemical gastropathy.<sup>15</sup>

The variability of the data reported in the literature may have a variety of explanations, the most plausible being the fact that the parameters used to define chemical gastritis are not well defined. Foveolar hyperplasia, which appears to be a result of excessive cell exfoliation from the surface epithelium or of stimulation by cytokines or other inflammatory mediators, was first reported in patients with bile reflux<sup>28, 29</sup> and subsequently observed after gastric surgery<sup>25</sup> in long term NSAID users.<sup>26</sup> Currently, according to the updated Sydney system,<sup>24</sup> it “may be seen in all forms of gastritis, but is most pronounced in chemical gastritis”. Oedema, vasodilatation, haemorrhage, and telangiectasia are unstable features that are possibly related to local factors and/or biopsy. The increased number of smooth muscle fibres in the lamina propria was originally demonstrated by Dixon and colleagues<sup>25</sup> but, although

usually reported as characteristic of chemical gastritis, in later studies it was not seen in long term NSAID users with chemical gastritis<sup>26</sup> or in chemical gastritis induced by naproxen.<sup>17</sup> Erosion and macroerosion are not often present in biopsy specimens because they are dependent on the sectioning and localisation of the endoscopic biopsy.

Nonetheless, the prevalence of chemical gastritis in chronic NSAID users, described by the different authors, varies between 26%<sup>14</sup> and 45%.<sup>17</sup> In our study, we calculated a prevalence of about 10% in the whole population studied (table 2), with prevalence being only slightly lower among those patients with ulcers and not significantly higher in those reporting digestive haemorrhage (table 5). As can be seen in table 2, four patients in the control group had scores consistent with chemical gastritis. These patients had not taken NSAIDs in the three months preceding the study, and neither were they alcohol abusers. However, it cannot be excluded that these patients had taken other medications or ingested foods that were potentially harmful to the mucosa. In statistical terms they have to be considered false positives. These data confirm, in our view, that chemical gastritis is not a pathognomonic histotype of the chronic gastric damage caused by the use of NSAIDs. According to El-Zimaity and colleagues<sup>15</sup> this may be accounted for by a variety of reasons, including the facts that of all the patients regularly taking NSAIDs, only a few (those with greater sensitivity) develop chemical gastritis, and mucosal damage can be patchy rather than uniform.

Other findings of our study are also worthy of note. The first is the relation between chronic NSAID use and colonisation by *H pylori*. The first papers on this question reported a lower prevalence of *H pylori* in the gastric mucosa of patients receiving chronic NSAID treatment.<sup>14 16 27 30</sup> It was thought that the gastric environment created by the use of anti-inflammatory medication might be unfavourable to *H pylori* implantation,<sup>14</sup> a view confirmed by the fact that NSAIDs can block the growth of the bacterium in vitro.<sup>31</sup>

Later, possibly because of improved accuracy of diagnostic methods, other studies reported an equal prevalence of *H pylori* in chronic NSAID users and control groups.<sup>15 17 32</sup>

Similarly, the prevalence of *H pylori* seen in our study (~45–50%) was similar in the two groups, leading us to exclude the possibility that anti-inflammatory drugs can impair implantation and growth of *H pylori* in the stomach mucosa. Thus, we can conclude that bacteria and medications are two frequent but independent aetiological damaging factors.

Another much debated topic is whether the presence of *H pylori* can modify the histological picture associated with NSAID induced damage and, if so, in what way. According to some authors, chemical gastritis is only prevalent where *H pylori* infection is absent.<sup>14 17</sup> This may be because the inflammation caused by the infection alters the characteristics of the pharmacological damage that has partly reverse histological features. In Dixon's scoring

system,<sup>25</sup> chemical gastritis and chronic active gastritis are in fact mutually exclusive. Even El-Zimaity *et al* concluded that simultaneous infection by *H pylori* makes the histological diagnosis of chemical gastritis extremely difficult.<sup>15</sup> In agreement with these data, none of our 53 *H pylori* positive patients who were chronic users of NSAIDs had chemical gastritis, whereas about a third of these patients had a score consistent with active chronic gastritis.

NSAIDs can cause considerable damage and are associated with a high prevalence of gastroduodenal ulcers. NSAID related ulcers might originate by two possible mechanisms: the concomitant presence of *H pylori* infection and/or the mucosal damage that was thought to show up as chemical gastritis.<sup>24</sup> Laine *et al* have already shown that gastric ulcers associated with the use of NSAIDs are an important subgroup of ulcers that do not require the presence of *H pylori* infection for their formation.<sup>27</sup>

In our series of patients taking NSAIDs, *H pylori* infection was invariably close to 45%, both in those with ulcers and in those without (table 5). Of the 38 patients with ulcers, 17 were *H pylori* positive and three had chemical gastritis, but in 18 neither of these factors could explain the presence of the ulcer.

It must be concluded that, at least in our cases, the presence of *H pylori* does not seem to enhance the risk of the development of ulcers, so that in many cases NSAIDs might be responsible for producing the lesions via different pathways to those mentioned above. NSAIDs also act by means of other damage mechanisms, the most important being inhibition of the synthesis of prostaglandins<sup>33</sup> and functional rupture of the mucosal barrier.<sup>34</sup> These factors may underlie erosion and/or ulcers in *H pylori* negative cases not presenting evidence of chemical gastritis.

Even in patients taking NSAIDs it is still unclear whether concomitant infection with *H pylori* plays a synergic role in causing bleeding. This hypothesis has been supported by some authors,<sup>35–37</sup> but not confirmed by others.<sup>38–41</sup> One paper has even shown that the presence of *H pylori* significantly prevents the depletion of tissue prostaglandins caused by NSAIDs, thus reducing their damage potential.<sup>42</sup>

In our 24 chronic users of NSAIDs who reported one or more episode of upper intestinal tract haemorrhage, the bleeding originated from a gastric ulcer in 10 patients, a duodenal ulcer in four, a haemorrhagic gastropathy with erosions in eight, and a duodenal ulcer with gastric erosions in two. In this group, in agreement with the literature data that report a low prevalence of *H pylori* in patients with haemorrhage,<sup>43</sup> we identified *H pylori* infection in only eight cases; three other cases had chemical gastritis. In 13 patients, none of whom were alcoholics, the mechanism underlying the mucosal damage was not easily identifiable on the basis of the histological findings (table 5).

These results seem to indicate that, as was noted for ulcers, the presence of *H pylori* does not increase the prevalence of haemorrhage.

In conclusion, our study has shown that neither chemical gastritis nor the presence of *H pylori* strongly correlates with the gastroduodenal damage induced by NSAIDs. This damage eludes all attempts at histological characterisation: the histological parameters put forward to date lack sufficient sensitivity or specificity to be considered reliable.

- 1 Lanza FL. A review of gastric ulcer and gastroduodenal injury in normal volunteers receiving aspirin and other nonsteroidal anti-inflammatory drugs. *Scand J Gastroenterol* 1989;24(suppl 163):24-31.
- 2 CMS update: Non-steroidal anti-inflammatory drugs and serious gastrointestinal adverse reactions. *BMJ* 1986;1: 1190-1.
- 3 Clinich D, Sanergee AK, Ostick G. Non-steroidal anti-inflammatory drugs and gastrointestinal adverse effects. *J R Coll Physicians Lond* 1983;17:228-30.
- 4 Collier DSTJ, Pain JA. Non-steroidal anti-inflammatory drugs and peptic ulcer perforation. *Gut* 1985;26:359-63.
- 5 Llewelyn IG, Pritchard MN. Acute gastric haemorrhage and its relationship to the use of anti-inflammatory analgesics (NSAIDs). *Ann Rheum Dis* 1983;42:228-9.
- 6 Alexander AM, Veitch GSA, Wood JS. Anti-rheumatic and analgesic drug usage and acute gastrointestinal bleeding in elderly patients. *J Clin Hosp Pharm* 1985;10:89-93.
- 7 Armstrong GP, Blower AL. Non-steroidal anti-inflammatory drugs and life-threatening complications of peptic ulceration. *Gut* 1987;28:527-32.
- 8 Jolobe OMP, Montgomery RD. Changing clinical pattern of gastric ulcer: are anti-inflammatory drugs involved? *Digestion* 1984;29:164-70.
- 9 Somerville K, Faulkner G, Langman MJS. Non-steroidal anti-inflammatory drugs and bleeding peptic ulcer. *Lancet* 1986;1:462-4.
- 10 Graham DY, Smith JL. Gastroduodenal complications of chronic NSAID therapy. *Am J Gastroenterol* 1988;83:1081-4.
- 11 Al-Assi MT, Genta RM, Karttunen TJ, et al. Ulcer site and complications: relation to *Helicobacter pylori* infection and NSAID use. *Endoscopy* 1966;28:229-33.
- 12 Genta RM, Robason GO, Graham DY. Simultaneous visualization of *Helicobacter pylori* and gastric morphology: a new stain. *Hum Pathol* 1994;25:221-6.
- 13 Whitehead R, Truelove SC, Gear MWL. The histological diagnosis of chronic gastritis in fiberoptic gastroscopy biopsy specimens. *J Clin Pathol* 1972;25:1-11.
- 14 Taha AS, Nakshabendi I, Lee FD, et al. Chemical gastritis and *Helicobacter pylori* related gastritis in patients receiving non-steroidal anti-inflammatory drugs: comparison and correlation with peptic ulceration. *J Clin Pathol* 1992;45:135-9.
- 15 El-Zimaity HMT, Genta RM, Graham DY. Histological features do not define NSAID-induced gastritis. *Hum Pathol* 1996;27:1348-54.
- 16 Caselli M, La Corte R, De Carlo L, et al. Histological findings in gastric mucosa in patients treated with non-steroidal anti-inflammatory drugs. *J Clin Pathol* 1995;48:553-5.
- 17 McCarthy CJ, McDermott M, Hourihane D, et al. Chemical gastritis induced by naproxen in the absence of *Helicobacter pylori* infection. *J Clin Pathol* 1995;48:61-3.
- 18 Shah K, Price AB, Talbot IC, et al. Effect of longterm misoprostol coadministration with non-steroidal anti-inflammatory drugs: a histological study. *Gut* 1995;37:195-8.
- 19 Committee on Safety of Medicines. Non-steroidal anti-inflammatory drugs and serious gastrointestinal adverse reactions. *BMJ* 1986;292:614-15.
- 20 Graham DY, Lidsky MD, Cox AM, et al. Long-term non-steroidal anti-inflammatory drug use and *Helicobacter pylori* infection. *Gastroenterology* 1991;100:1653-7.
- 21 Malfertheiner P, Labenz J. La presenza di *Helicobacter pylori* influenza la patologia gastroduodenale associata ai farmaci anti-infiammatori non steroidei? *Am J Med* 1998 [Ed. italiana];104:37-43.
- 22 Vane JR. Inhibition of prostaglandin synthesis as a mechanism of action for aspirin-like drugs. *Nature New Biology* 1971;231:232-5.
- 23 Crabtree JE. Gastric mucosal inflammatory responses to *Helicobacter pylori*. *Aliment Pharmacol Ther* 1996;10(suppl 1):29-37.
- 24 Dixon MF, Genta RM, Yardley JH, et al. Classification and grading of gastritis. The updated Sydney system. *Am J Surg Pathol* 1996;20:1161-81.
- 25 Dixon MF, O'Connor HJ, Axon ATR, et al. Reflux gastritis: distinct histopathological entity? *J Clin Pathol* 1986;39: 524-30.
- 26 Sobala GM, King RFG, Axon ATR, et al. Reflux gastritis in the intact stomach. *J Clin Pathol* 1990;43:303-6.
- 27 Laine L, Marin-Sorensen M, Weinstein WM. Nonsteroidal anti-inflammatory drug-associated gastric ulcers do not require *Helicobacter pylori* for their development. *Am J Gastroenterol* 1992;87:1398-402.
- 28 Dewar EP, Dixon MF, Johnston D. Bile reflux and degree of gastritis after highly selective vagotomy, truncal vagotomy, and partial gastrectomy for duodenal ulcer. *World J Surg* 1983;7:743-50.
- 29 Dewar EP, Dixon MF, Johnston D. Bile reflux and degree of gastritis in patients with gastric ulcer: before and after operation. *J Surg Res* 1984;37:277-84.
- 30 Talley NJ, Evans JM, Fleming KC, et al. Nonsteroidal anti-inflammatory drugs and dyspepsia in the elderly. *Dig Dis Sci* 1995;40:1345-50.
- 31 Caselli M, Pazzi P, La Corte R, et al. *Campylobacter*-like organism nonsteroidal anti-inflammatory drugs and gastric lesion in patients with rheumatoid arthritis. *Digestion* 1989; 44:101-4.
- 32 Santucci L, Fiorucci S, Patoia L, et al. Severe gastric mucosal damage induced by NSAIDs in healthy subjects is associated with *Helicobacter pylori* infection and high levels of serum pepsinogens. *Dig Dis Sci* 1995;40:2074-80.
- 33 Whittle BJR, Higgs GA, Eakins KE, et al. Selective inhibition of prostaglandin production in inflammatory exudates and gastric mucosa. *Nature* 1980;284:271-3.
- 34 Cooke AR. The role of the mucosal barrier in drug-induced gastric ulceration and erosions. *Dig Dis Sci* 1976;21:155-64.
- 35 Russell RI. *Helicobacter pylori* eradication may reduce the risk of gastroduodenal lesions in chronic NSAID users. *Ital J Gastroenterol Hepatol* 1997;29:465-9.
- 36 Taha AS, Russel RI. H. pylori and non-steroidal anti-inflammatory drugs. Uncomfortable partners in peptic ulcer disease. *Gut* 1993;34:580-4.
- 37 Chan FK, Sung JJ, Chung SC, et al. Randomised trial of eradication of *H. pylori* before non-steroidal anti-inflammatory drug therapy to prevent peptic ulcers. *Lancet* 1997;350:975-9.
- 38 Yeomans ND, Tulassay Z, Juhasz L, et al. A comparison of omeprazole with Ranitidine for ulcers associated with non-steroidal anti-inflammatory drugs. *N Engl J Med* 1998;338: 719-26.
- 39 Hawkey CJ, Karrasch JA, Szczepanski L, et al. Omeprazole compared with misoprostol for ulcers associated with non-steroidal anti-inflammatory drugs. *N Engl J Med* 1998;338: 727-34.
- 40 Hawkey CJ, Tulassay Z, Szczepanski L, et al. Randomised controlled trial of *Helicobacter pylori* eradication in patients on nonsteroidal anti-inflammatory drugs: HELP NSAIDs study. *Lancet* 1998;352:1016-21.
- 41 Wu CY, Poon SK, Chen GH, et al. Interaction between *Helicobacter pylori* and NSAID in peptic ulcer bleeding. *Scand J Gastroenterol* 1999;3:234-7.
- 42 Hudson N, Balsitis M, Filipowicz F, et al. Effect of *Helicobacter pylori* colonisation on gastric mucosal eicosanoid synthesis in patients taking NSAIDs. *Gut* 1993;34:748-51.
- 43 Bianchi Porro G, Lazzaroni M. The conflicting relationship between *Helicobacter pylori* and non-steroidal anti-inflammatory drugs in peptic ulcer bleeding. *Scand J Gastroenterol* 1999;3:225-8.