

Review article

Clinical and molecular genetics of Stickler syndrome

Martin P Snead, John R W Yates

Abstract

Stickler syndrome is an autosomal dominant disorder with characteristic ophthalmological and orofacial features, deafness, and arthritis. Abnormalities of vitreous gel architecture are a pathognomonic feature, usually associated with high myopia which is congenital and non-progressive. There is a substantial risk of retinal detachment. Less common ophthalmological features include paravascular pigmented lattice degeneration and cataracts. Non-ocular features show great variation in expression. Children with Stickler syndrome typically have a flat midface with depressed nasal bridge, short nose, anteverted nares, and micrognathia. These features can become less pronounced with age. Midline clefting, if present, ranges in severity from a cleft of the soft palate to Pierre-Robin sequence. There is joint hypermobility which declines with age. Osteoarthritis develops typically in the third or fourth decade. Mild spondyloepiphyseal dysplasia is often apparent radiologically. Sensorineural deafness with high tone loss may be asymptomatic or mild. Occasional findings include slender extremities and long fingers. Stature and intellect are usually normal. Mitral valve prolapse was reported to be a common finding in one series but not in our experience. The majority of families with Stickler syndrome have mutations in the COL2A1 gene and show the characteristic type 1 vitreous phenotype. The remainder with the type 2 vitreous phenotype have muta-

tions in COL11A1 or other loci yet to be identified. Mutations in COL11A2 can give rise to a syndrome with the systemic features of Stickler syndrome but no ophthalmological abnormality.

(J Med Genet 1999;36:353-359)

Keywords: Stickler syndrome; collagen; vitreous

It is 30 years since Gunnar Stickler and colleagues^{1,2} published their report on hereditary arthro-ophthalmopathy and a decade since the condition we now call Stickler syndrome was reviewed in this journal.³ The purpose of this article is to provide an overview of this disorder in the light of recent advances in both clinical and molecular genetic analysis.

Clinical features

Stickler syndrome is a dominantly inherited disorder of collagen connective tissue with predominantly ophthalmic, orofacial, auditory, and articular manifestations. It is the commonest inherited cause of rhegmatogenous retinal detachment in childhood and although the systemic features are widespread, the sight threatening complications are perhaps the most conspicuous and serious manifestations.

Stickler syndrome has been subclassified into type 1 and type 2 to reflect the locus heterogeneity (OMIM Nos 108300, 184840) and this correlates with the vitreoretinal phenotype as discussed below. The systemic features are similar for both subgroups. There are no agreed diagnostic criteria for Stickler syndrome. The criteria we have used for research purposes are (1) congenital vitreous

Vitreoretinal Service,
Department of
Ophthalmology, Box
41, Addenbrooke's
Hospital, Hills Road,
Cambridge CB2 2QQ,
UK
M P Snead

Department of
Medical Genetics,
University of
Cambridge, Box 134,
Addenbrooke's
Hospital, Hills Road,
Cambridge CB2 2QQ,
UK
J R W Yates

Correspondence to:
Dr Snead.

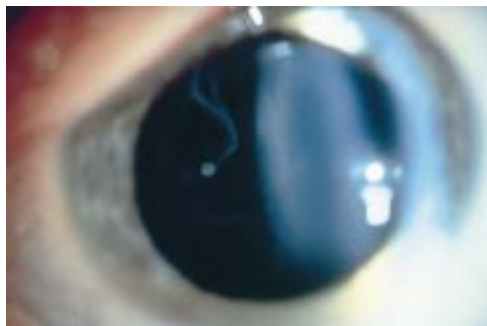

Figure 1 Type 1 vitreous anomaly.

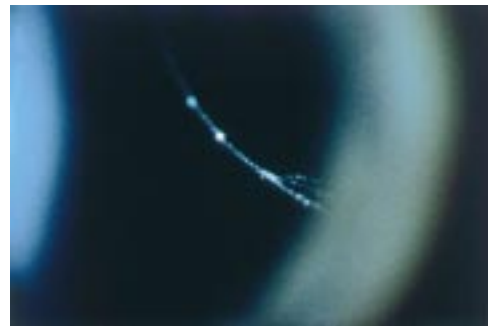


Figure 2 Type 2 vitreous anomaly.



Figure 3 (A) Facial features in a 4 year old child with type 1 Stickler syndrome. (B) Same patient aged 10 years.

anomaly (figs 1 and 2) and, in addition, any three of the following: (2) myopia with onset before 6 years of age, usually stable (fig 3), (3) rhegmatogenous retinal detachment or paravascular pigmented lattice degeneration (fig 4), (4) joint hypermobility with abnormal Beighton score, with or without radiological evidence of joint degeneration (fig 5), (5) audiometric confirmation of sensorineural hearing defect, and (6) midline clefting (fig 6).

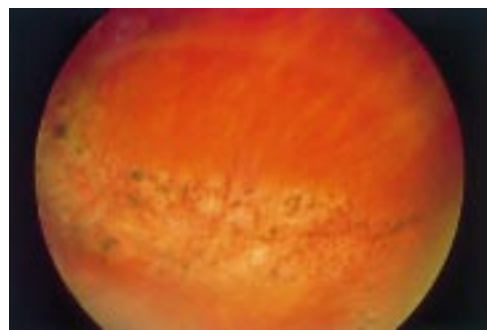


Figure 4 Typical pigmented paravascular retinal lattice degeneration.

EYES

Most, but not all patients with Stickler syndrome are myopic. Unlike the common developmental type of myopia (typically with onset in the early teens), the myopia of Stickler syndrome is usually congenital, non-progressive, and of high degree. There is a well recognised association with cataract.^{4,5} The cataracts may be congenital and non-progressive, and many show an unusual and characteristic curved cortical distribution (fig 7).

Abnormalities of vitreous formation and gel architecture are pathognomonic of Stickler syndrome and in our view a prerequisite for diagnosis.⁶ Two distinct phenotypes can be recognised.⁷⁻⁹ The majority of patients have a characteristic congenital anomaly of the vitreous (the type 1 phenotype, fig 1) and this correlates with defects in type II procollagen.^{7,8} An apparently vestigial vitreous gel occupies the immediate retrolental space and is bordered by a distinct folded membrane. In a minority of pedigrees there is a different phenotype with sparse and irregularly thickened bundles of fibres throughout the vitreous cavity (the type 2 phenotype, fig 2).

Developmental abnormalities of the anterior chamber drainage angle predispose patients to glaucoma,¹⁰ but the most serious ophthalmic complication relates to the high risk of retinal detachment, usually as a result of giant retinal tear formation. At the time of Stickler's original report, giant retinal tear was generally considered untreatable and blindness ensued. Modern ophthalmic surgical techniques now allow successful retinal reattachment but the risk of sudden and bilateral blindness remains a threat in patients with both vitreoretinal phenotypes.

OROFACIAL FEATURES

Classically, patients show a flat midface with a depressed nasal bridge, reduced nasal protrusion, anteverted nares, and micrognathia (fig 3A). These findings are usually most evident in childhood and with increasing age often become less distinctive (fig 3B). This is well illustrated in the previous review.³ The facial features are so variable that in isolation they are unreliable for making a diagnosis. A quarter of patients have some evidence of midline clefting. This can range from the extreme of the Pierre-Robin sequence, through clefting of the hard/soft palate, to the mildest manifestation of bifid uvula.

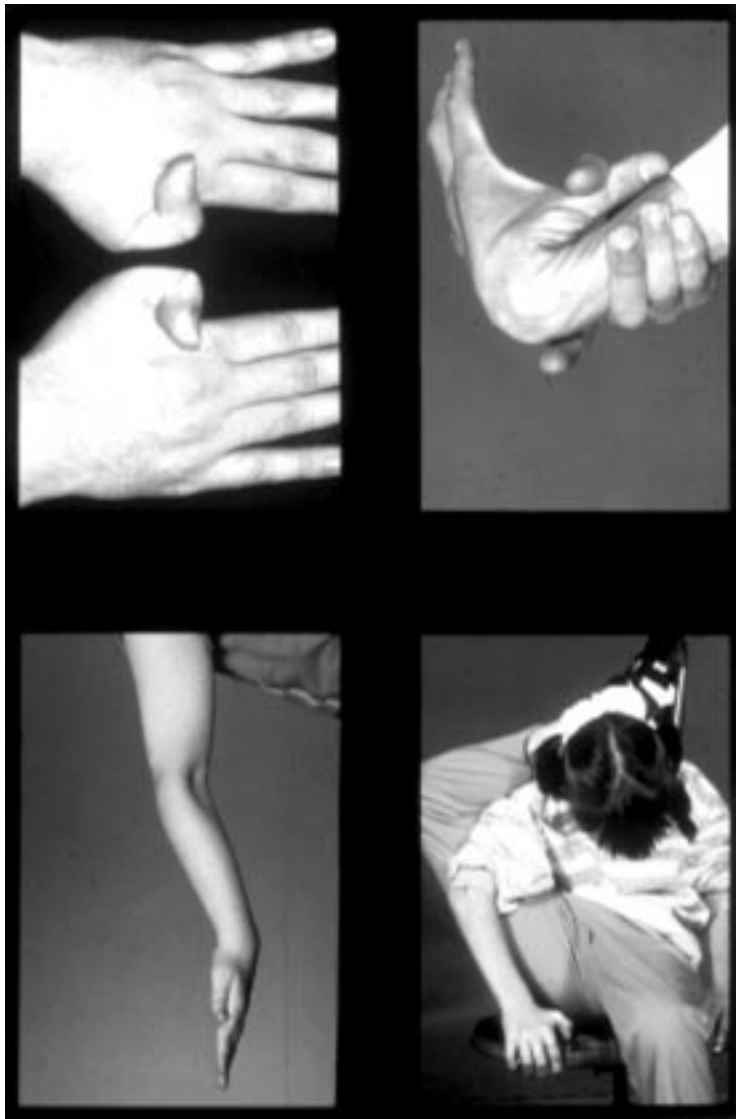

Figure 5 Joint hypermobility in patients with type 1 Stickler syndrome.

DEAFNESS

Patients with Stickler syndrome may suffer hearing difficulties for two reasons. Firstly, the association with cleft and high arch palate leads to an increased incidence of serous otitis media causing a conductive hearing deficit which may be remedial. In some patients a mild conductive element persists because of ossicle defects.³ Secondly, there can be an associated sensorineural defect. Forty percent of Stickler syndrome patients show some evidence of sensorineural hearing loss, which is typically high tone and in many patients so subtle that they are unaware of the deficit.

The pathogenesis of the sensorineural hearing loss in Stickler syndrome patients is unknown. Chondrodysplastic mice with type II collagen defects show marked hearing impairment when tested with brain stem auditory responses.¹¹ The temporal bone showed underdevelopment of the organ of Corti in the lower turn of the cochlea. In addition, there were no supporting cells, inner or outer hair cells, nerve endings, or pillar cells. The upper part of the organ of Corti, however, was almost normal in

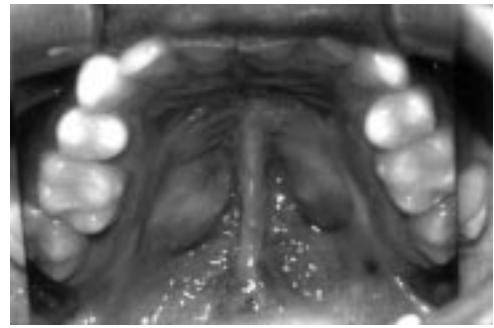


Figure 6 Midline cleft palate repair.

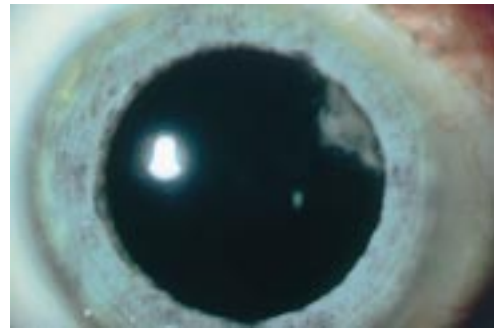


Figure 7 Characteristic curved cortical cataract.

structure. These findings provide a possible explanation for the sensorineural component to the hearing loss in Stickler syndrome, particularly as this is also typically a congenital neural deafness. Whether this mirrors the facial, mandibular, and external auditory developmental delay evident in these patients is unknown (see below) and the frequency of true progression is difficult to ascertain. The cross sectional study by Lucarini *et al*¹² did not support a correlation between hearing loss and orofacial abnormality.

JOINT ABNORMALITIES

Many younger patients with Stickler syndrome have joint hypermobility (fig 5) and the diagnosis should be considered in hypermobile patients who are myopic. Joint mobility should be assessed objectively using the Beighton scoring system to allow comparison with an age, sex, and race matched population.¹³

With increasing age the hypermobility reduces or is lost completely and a degenerative arthropathy of variable severity may develop by the third or fourth decade¹⁴ (fig 8). Typical radiological changes show irregularity of articular contour and loss of joint space. By middle age some patients require joint replacement surgery for hips or knees.

OTHER FEATURES

Slender extremities, long fingers, and normal height characterise the body habitus.¹⁵ Mild spondyloepiphyseal dysplasia is often apparent radiologically. Mitral valve prolapse was found in almost half the patients in one reported series¹⁶ and, as a result, screening for valvular disease and antibiotic prophylaxis before surgery have been recommended.³ However, this is not supported by our experience of echocardiographic screening in a series of over 100

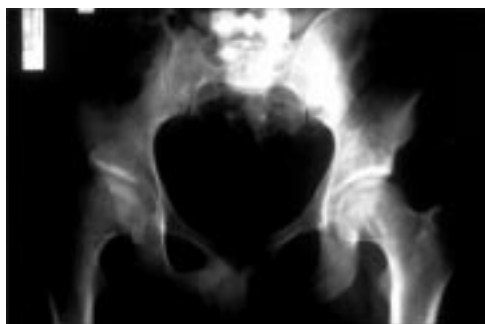

Figure 8 Degenerative arthropathy (right hip) in a 28 year old male.

Stickler syndrome patients, none of whom showed evidence of mitral valve prolapse.⁹

Molecular genetics

The suggestion that disorders in connective tissue proteins,⁵ and specifically collagen, may underlie Stickler syndrome has been substantiated by recent research. Because of the combination of articular, auditory, and ocular abnormalities in Stickler syndrome, fibrillar collagens in particular have been leading candidates for investigation.

Collagen is the major macromolecule of most connective tissues.^{17,18} It consists of three polypeptide chains which are folded into a rod-like triple helical molecule. Each of the constituent chains of the triple helix are called α chains and are coiled in a left handed helix with three amino acids per turn. The constituent amino acids are regularly arranged in the order Gly-X-Y such that glycine, which is the smallest of all amino acids, occupies the restricted space in which the three α helical chains come together. This is crucial for the stability of the macromolecule.

So far, 19 collagen types have been identified designated by the Roman numerals I-XIX.¹⁹ These collagen types are formed by trimer combinations of three polypeptide chains designated by Arabic numerals. These chains may be the same or different so that the collagen molecule may depend on the products of one, two, or three genes. There are over 30 genes coding for the different types of polypeptide chains.

The repetitive sequence of collagen amino acids Gly-X-Y means that the coding sequence is also highly repetitive. Furthermore, collagen

gene exons are typically multiples of nine base pairs, common standard exon sizes being 45, 54, 63, 81, 108, and 162 base pairs.²⁰

The majority of patients (perhaps 75%) with Stickler syndrome have the characteristic type 1 vitreous phenotype and show linkage to the gene encoding type II collagen (COL2A1) on chromosome 12q13.^{7,8} Type II collagen is one of the group of fibrillar collagens, namely, I, II, III, V, and XI²¹ and is found chiefly in cartilage, vitreous, and nucleus pulposus.²² Type II collagen is a homotrimer of three $\alpha 1$ (II) procollagen chains. Mutation screening has shown a high propensity for stop mutations and in this respect Stickler syndrome appears unique among the inherited connective tissue disorders. An interesting exception is the family reported by Ballo *et al.*²³ with an Arg704Cys substitution, in whom ocular problems and conductive deafness predominated, skeletal changes resembled a mild form of multiple epiphyseal dysplasia, and unusually all affected patients had stubby digits. Other types of mutations in the COL2A1 gene have been associated with spondyloepiphyseal dysplasia congenita, Kniest dysplasia, achondrogenesis type II, hypochondrogenesis, or premature osteoarthritis.²⁴

In most families, with the type 2 vitreous phenotype, linkage to COL2A1 can be excluded and other collagen and collagen associated protein candidates are currently being examined. Mutations in the gene encoding the $\alpha 1$ chain of type XI collagen (COL11A1) on chromosome 1p21 have so far been found in three UK families and these are, to date, the only mutations associated with the type 2 vitreous phenotype.^{25,26} The $\alpha 2$ chain of type XI collagen is not expressed in vitreous²⁷ and mutations of its encoding gene (COL11A2) on chromosome 6p21.3 have been reported in Stickler-like syndromes which lack any ocular abnormality, as discussed below under differential diagnosis. Mutations reported in Stickler syndrome are summarised in table 1.

In several pedigrees with the full Stickler syndrome phenotype including vitreous abnormality, we and others²⁸ have excluded linkage to collagens II and XI showing that there is further genetic heterogeneity still to be resolved.

Diagnosis

Clinical diagnosis using the criteria we have suggested above requires slit lamp examination

Table 1 Mutation spectrum in Stickler syndrome

Phenotype	Gene	Mutation	Effect	Refs
Stickler syndrome*	COL2A1	Ins 10bp, exon 4	Frameshift	53
Stickler syndrome*	COL2A1	Arg9Ter, exon 7	Nonsense mutation	54
Stickler syndrome*†	COL2A1	A ⁻² →G, IVS17	Aberrant splicing, frameshift	55
Stickler syndrome*	COL2A1	Del A, exon 20	Frameshift	53
Stickler syndrome*	COL2A1	Arg704Cys, exon 39	Missense mutation	23
Stickler syndrome*	COL2A1	Arg732Ter, exon 40	Nonsense mutation	56
Stickler syndrome*	COL2A1	Del T, exon 40	Frameshift	57
Stickler syndrome*	COL2A1	Del T, exon 43	Frameshift	58
Stickler syndrome*	COL2A1	Ins G, exon 48	Frameshift	53
Stickler syndrome*	COL2A1	Del C, exon 50	Frameshift	59
Stickler syndrome with type 2 vitreous	COL11A1	Del 1bp, acceptor splice site	Aberrant splicing, in frame exon skip	26
Stickler syndrome with type 2 vitreous	COL11A1	Gly97Val	Missense mutation	25
Stickler syndrome with type 2 vitreous	COL11A1	Del 40kb (multiple exons)	Large in frame deletion	26

*Families with COL2A1 mutations are likely to have the type 1 vitreous phenotype (see text).

†Original family reported by Stickler *et al.*^{1,2}

of the vitreous. However, in practice, it may be difficult to obtain an adequate slit lamp vitreous examination in children under 4 years of age. Molecular genetic diagnosis is not currently available on a service basis because of the size, complexity, and number of genes involved. The diagnosis of Stickler syndrome should be considered in (1) neonates with Pierre-Robin sequence or midline cleft, (2) infants with spondyloepiphyseal dysplasia associated with myopia or deafness, (3) patients with a family history of rhegmatogenous retinal detachment, and (4) sporadic cases of retinal detachment associated with joint hypermobility, midline clefting, or deafness.

Differential diagnosis

Several disorders resembling Stickler syndrome have been described and their status as distinct entities remains controversial. Molecular genetic data are beginning to inform this debate but uncertainty remains. This will only be resolved when more genotype data become available combined with detailed descriptions of the associated ocular and non-ocular phenotype.

WAGNER SYNDROME

Wagner²⁹ reported a large Swiss family with an autosomal dominant eye disorder resembling Stickler syndrome but without retinal detachment. Many of the families subsequently reported as Wagner syndrome have had systemic features in common with Stickler syndrome and the distinction between the two conditions has become blurred. Indeed, some authors have suggested that they are the same disorder.³⁰ Evidence that families showing only the ocular manifestations of Wagner syndrome have a condition distinct from Stickler syndrome has come from the finding of linkage to 5q13-q14 in the original Wagner family³¹ and exclusion of linkage to COL2A1 in another family.³² In view of these findings, the term "Wagner-Stickler syndrome" should be abandoned. Korkko *et al*³³ reported a patient with Wagner syndrome resulting from a substitution of the bulky amino acid aspartate for glycine in exon 10 of COL2A1 and postulated a possible link between the type of mutation and the Stickler or Wagner phenotypes. However, frequent retinal detachment and to a lesser extent cataract were ascribed to Wagner syndrome, whereas in the original report²⁹ no patient suffered a retinal detachment, "cataracta complicata" was almost universal, and myopia was low in all cases. It could be argued that in the family reported by Korkko *et al*³³ the phenotype more closely resembles Stickler syndrome than Wagner syndrome.

EROSIVE VITREORETINOPATHY

Brown *et al*³⁴ have described an autosomal dominant eye disorder they called erosive vitreoretinopathy with a phenotype resembling Wagner syndrome and lacking any systemic abnormalities. This condition has also been mapped to 5q13-q14 suggesting it may be an allelic variant of Wagner syndrome.³¹

MARSHALL SYNDROME

Marshall³⁵ reported a large family showing autosomal dominant inheritance of cataracts, myopia, abnormal vitreous, midfacial hypoplasia, and congenital deafness. Marshall thought the phenotype might represent an incomplete form of hereditary anhidrotic ectodermal dysplasia but acknowledged that the hair was normal and evidence of hypodontia and hypohidrosis was "not strongly convincing". Shanske *et al*³⁶ noted from the published photographs that one of Marshall's patients had striking hypertelorism with perhaps mild hypertelorism in others. There has been much debate about whether Marshall syndrome is a distinct entity³⁷ and, if so, whether ectodermal dysplasia is a feature of the condition.³⁶ Ayme and Preus³⁸ carried out cluster analysis on published reports of Marshall and Stickler syndrome patients and concluded they were different. It remains to be seen whether this issue can be resolved by molecular genetic analysis. Griffith *et al*³⁹ have reported a COL11A1 mutation in a family said to have Marshall syndrome. Shanske *et al*⁴⁰ suggested the family had Stickler syndrome but the authors responded that, as in the original family reported by Marshall, their patients had congenital and juvenile cataracts, fluid vitreous, hearing loss, and similar craniofacial appearance and radiology.⁴¹ As these are all recognised features of Stickler syndrome and there is no information given on vitreous phenotype, the issue remains unresolved.

WEISSENBACHER-ZWEYMULLER SYNDROME AND OSMED

Weissenbacher and Zweymuller⁴² described a newborn with the Pierre-Robin sequence, snub nose, proximal limb shortening, dumb bell shaped femora and humeri, and coronal vertebral clefts. The parents were healthy and unrelated. Giedion *et al*⁴³ followed up the same patient at 18 years of age. Sensorineural deafness had developed at the age of 5. By adult life limb shortening had all but resolved and height and appearance were essentially normal. There was no eye abnormality. Enlarged epiphyses were a prominent radiological feature in adolescence. Giedion *et al*⁴³ reported three other patients with the same phenotype and coined the name otospondylomegaepiphyseal dysplasia (OSMED). They concluded that Weissenbacher-Zweymuller syndrome (WZS) and OSMED were the same. Pihlajamaa *et al*⁴⁴ subsequently showed that the original WZS patient was heterozygous for a mutation in COL11A2. Other families showing autosomal dominant inheritance of a similar non-ocular Stickler syndrome phenotype as a result of COL11A2 mutations have been described.⁴⁵⁻⁴⁷ Van Steensel *et al*⁴⁸ reported three sibs of consanguineous parents who were homozygous for a COL11A2 mutation and had the OSMED phenotype. Vikkula *et al*⁴⁹ reported several members of a consanguineous family who were homozygous for a mutation in COL11A2. They had severe congenital sensorineural deafness, midface hypoplasia, short, upturned nose, prominent eyes, prominent supraorbital

ridges, and early adult onset of severe osteoarthritis of the hips, knees, shoulders, and elbows. Adult height was slightly reduced with increased lumbar lordosis. The interphalangeal joints were prominent with short fifth metacarpals. As in all reported families with COL11A2 mutations, ophthalmological examination was normal.

OTHER DISORDERS

Other disorders with some features in common with Stickler syndrome include spondyloepiphyseal dysplasia congenita,⁴⁹ Kniest dysplasia,⁴⁹⁻⁵¹ and Marfan syndrome.⁵²

Management

Once the diagnosis of Stickler syndrome has been established, a coordinated multidisciplinary approach is desirable, comprising the following. (1) Ophthalmological assessment with refraction and correction of myopic/astigmatic error. The quality of best corrected vision may be improved with contact lens rather than spectacle correction. Many centres are now offering prophylactic retinopexy to reduce the risk of retinal detachment. Because of the risk of detachment, all patients require long term follow up and should be advised that if they see new floaters or shadows in their vision they should seek urgent ophthalmological assessment. (2) Maxillofacial assessment if midline clefting is present. (3) Hearing assessment and management of combined conductive and sensorineural deafness if present. (4) Educational assessment. Although intelligence is normal, patients of school age may face considerable educational difficulties because of combined visual and auditory impairment. Educational authorities may need to be notified of a child's special needs. Patient support and public education has been helped substantially by the formation of the Stickler Syndrome Support Group which was founded in the UK in 1994 (The Stickler Syndrome Support Group, 27 Braycourt Avenue, Walton-on-Thames, Surrey KT12 2AZ, UK. Tel: 01932 229421). (5) Rheumatological assessment and follow up is indicated in older patients who may benefit from physiotherapy for arthropathy.

Genetic counselling

Stickler syndrome shows autosomal dominant inheritance but with wide variation in expression so that the disease status of mildly affected relatives may only become apparent on careful clinical evaluation, including slit lamp examination of the vitreous. Affected members of the family should be identified so that they can be assessed for prophylaxis against retinal detachment and be offered genetic advice. For prospective parents, variation in expression complicates counselling because of the uncertainty about severity in affected offspring. First trimester prenatal diagnosis based on the analysis of linked markers may be possible in suitable type 1 families but direct mutation analysis is not currently an option for the reasons discussed above. In taking the linkage approach, careful clinical and ophthalmological examination is essential to confirm that the

typical type 1 vitreoretinal phenotype is present and also to establish the disease status of relatives used in the analysis. Moreover, if the family is not large enough to provide confirmation of linkage to COL2A1, patients need to be advised that the correlation between the type 1 phenotype and involvement of COL2A1 is only supported by a modest number of families, which limits the reliability of the result. For type 2 Stickler syndrome, the linkage based approach is complicated by the unresolved locus heterogeneity and is not a realistic option for most families. In the second trimester, the finding of features such as micrognathia or cleft palate by ultrasound scanning offers an alternative approach to prenatal diagnosis, but if these are absent it by no means excludes the diagnosis.

We thank Dr Allan Richards for helpful advice and gratefully acknowledge the support of The Iris Fund for Prevention of Blindness. We thank the reviewers for their constructive comments.

- 1 Stickler GB, Belau PG, Farrell FJ, *et al*. Hereditary progressive arthro-ophthalmopathy. *Mayo Clinic Proc* 1965;40:433-55.
- 2 Stickler GB, Pugh DG. Hereditary progressive arthro-ophthalmopathy. II. Additional observations on vertebral abnormalities, a hearing defect, and a report of a similar case. *Mayo Clinic Proc* 1967;42:495-500.
- 3 Temple IK. Stickler's syndrome. *J Med Genet* 1989;26:119-26.
- 4 Scott JD. Duke-Elder lecture. Prevention and perspective in retinal detachment. *Eye* 1989;3:491-515.
- 5 Seery CM, Pruett RC, Liberfarb RM, Cohen BZ. Distinctive cataract in the Stickler syndrome. *Am J Ophthalmol* 1990;110:143-8.
- 6 Maumenee IH. Vitreoretinal degeneration as a sign of generalized connective tissue diseases. *Am J Ophthalmol* 1979;88:432-49.
- 7 Snead MP, Payne SJ, Barton DE, *et al*. Stickler syndrome: correlation between vitreoretinal phenotypes and linkage to COL 2A1. *Eye* 1994;8:609-14.
- 8 Snead MP, Yates JR, Pope FM, Temple IK, Scott JD. Masked confirmation of linkage between type 1 congenital vitreous anomaly and COL 2A1 in Stickler syndrome. *Graefes Arch Clin Exp Ophthalmol* 1996;234:720-1.
- 9 Snead MP. Hereditary vitreopathy. *Eye* 1996;10:653-63.
- 10 Nielson CE. Stickler's syndrome. *Acta Ophthalmol* 1981;59:286-95.
- 11 Cho H, Yamada Y, Yoo TJ. Ultrastructural changes of cochlea in mice with hereditary chondrodysplasia (cho/cho). *Ann N Y Acad Sci* 1991;630:259-61.
- 12 Lucarini JW, Liberfarb RM, Eavey RD. Otolaryngological manifestations of the Stickler syndrome. *Int J Pediatr Otorhinolaryngol* 1987;14:215-22.
- 13 Beighton P. *McKusick's heritable disorders of connective tissue*. 5th ed. St Louis: Mosby, 1993.
- 14 Rai A, Wordsworth P, Coppock JS, Zaphiropoulos GC, Struthers GR. Hereditary arthro-ophthalmopathy (Stickler syndrome): a diagnosis to consider in familial premature osteoarthritis. *Br J Rheumatol* 1994;33:1175-80.
- 15 Beals RK. Hereditary arthro-ophthalmopathy (the Stickler syndrome). Report of a kindred with protrusio acetabuli. *Clin Orthop* 1977;125:32-5.
- 16 Liberfarb RM, Goldblatt A. Prevalence of mitral-valve prolapse in the Stickler syndrome. *Am J Med Genet* 1986;24:387-92.
- 17 Prockop DJ, Kivirikko KI, Tuderman L, Guzman NA. The biosynthesis of collagen and its disorders (second of two parts). *N Engl J Med* 1979;301:77-85.
- 18 Prockop DJ, Kivirikko KI, Tuderman L, Guzman NA. The biosynthesis of collagen and its disorders (first of two parts). *N Engl J Med* 1979;301:13-23.
- 19 Francomano CA. Key role for a minor collagen. *Nat Genet* 1995;9:6-8.
- 20 Pope FM. Molecular abnormalities of collagen and connective tissue. In: Maddison PJ, Isenberg DA, Woo P, Glass DN, editors. *Oxford textbook of rheumatology*. Oxford: Oxford University Press, 1998:353-404.
- 21 Prockop DJ, Kivirikko KI. Collagens: molecular biology, diseases and potentials for therapy. *Annu Rev Biochem* 1995;64:403-34.
- 22 Upholt WB, Strom CM, Sandell LJ. Structure of the type II collagen gene. *Ann N Y Acad Sci* 1985;460:130-40.
- 23 Ballo R, Beighton PH, Ramesar RS. Stickler-like syndrome due to a dominant negative mutation in the COL2A1 gene. *Am J Med Genet* 1998;80:6-11.
- 24 Horton WA. Progress in human chondrodysplasias: molecular genetics. *Ann N Y Acad Sci* 1996;785:150-9.
- 25 Richards AJ, Yates JR, Williams R, *et al*. A family with Stickler syndrome type 2 has a mutation in the COL11A1 gene

- resulting in the substitution of glycine 97 by valine in alpha 1 (XI) collagen. *Hum Mol Genet* 1996;5:1339-43.
- 26 Martin S, Richards AJ, Yates JRW, Pope FM, Scott JD, Snead MP. Stickler syndrome types 1 and 2: confirmation of genetic heterogeneity and evidence for another locus. *Presentation XXI Meeting Club Jules Gonin* 1998:A34.
 - 27 Mayne R, Brewton RG, Mayne PM, Baker JR. Isolation and characterization of the chains of type V/type XI collagen present in bovine vitreous. *J Biol Chem* 1993;268:9381-6.
 - 28 Wilkin DJ, Mortier GR, Johnson CL, et al. Correlation of linkage data with phenotype in eight families with Stickler syndrome. *Am J Med Genet* 1998;80:121-7.
 - 29 Wagner H. Ein bisher unbekanntes Erbleiden des Auges (Degeneratio hyaloideo-retinalis hereditaria), beobachtet im Kanton Zurich. *Klin Monatsbl Augenheilkd* 1938;100:840-57.
 - 30 Liberfarb RM, Hirose T, Holmes LB. The Wagner-Stickler syndrome: a study of 22 families. *J Pediatr* 1981;99:394-9.
 - 31 Brown DM, Graemiger RA, Hergersberg M, et al. Genetic linkage of Wagner disease and erosive vitreoretinopathy to chromosome 5q13-14. *Arch Ophthalmol* 1995;113:671-5.
 - 32 Fryer AE, Upadhyaya M, Littler M, et al. Exclusion of COL2A1 as a candidate gene in a family with Wagner-Stickler syndrome. *J Med Genet* 1990;27:91-3.
 - 33 Korkko J, Ritvaniemi P, Haataja L, et al. Mutation in type II procollagen (COL2A1) that substitutes aspartate for glycine alpha 1-67 and that causes cataracts and retinal detachment: evidence for molecular heterogeneity in the Wagner syndrome and the Stickler syndrome (arthro-ophthalmopathy). *Am J Hum Genet* 1993;53:55-61.
 - 34 Brown DM, Kimura AE, Weingeist TA, Stone EM. Erosive vitreoretinopathy. A new clinical entity. *Ophthalmology* 1994;101:694-704.
 - 35 Marshall D. Ectodermal dysplasia. Report of a kindred with ocular deformities and hearing defect. *Am J Ophthalmol* 1958;45:143-56.
 - 36 Shanske AL, Bogdanow A, Shprintzen RJ, Marion RW. The Marshall syndrome: report of a new family and review of the literature. *Am J Med Genet* 1997;70:52-7.
 - 37 Cohen MM Jr. The demise of the Marshall syndrome. *J Pediatr* 1974;85:878.
 - 38 Ayme S, Preus M. The Marshall and Stickler syndromes: objective rejection of lumping. *J Med Genet* 1984;21:34-8.
 - 39 Griffith AJ, Sprunger LK, Sirko-Osadsa DA, Tiller GE, Meisler MH, Warman ML. Marshall syndrome associated with a splicing defect at the COL11A1 locus. *Am J Hum Genet* 1998;62:816-23.
 - 40 Shanske A, Bogdanow A, Shprintzen RJ, Marion RW. Marshall syndrome and a defect at the COL11A1 locus. *Am J Hum Genet* 1998;63:1558-61.
 - 41 Warman ML, Tiller GE, Griffith AJ. Reply to Shanske et al. *Am J Hum Genet* 1998;63:1559-61.
 - 42 Weissenbacher G, Zweymuller E. Coincidental occurrence of Pierre Robin and foetal chondrodysplasia. *Monatsschr Kinderheilkd* 1964;112:315-17.
 - 43 Giedion A, Brandner M, Lecannellier J, et al. Oto-spondylo-megaepiphyseal dysplasia (OSMED). *Helv Paediatr Acta* 1982;37:361-80.
 - 44 Pihlajamaa T, Prockop DJ, Faber J, et al. Heterozygous glycine substitution in the COL11A2 gene in the original patient with the Weissenbacher-Zweymuller syndrome demonstrates its identity with heterozygous OSMED (nonocular Stickler syndrome). *Am J Med Genet* 1998;80:115-20.
 - 45 Brunner HG, van Beersum SE, Warman ML, Olsen BR, Ropers HH, Mariman EC. A Stickler syndrome gene is linked to chromosome 6 near the COL11A2 gene. *Hum Mol Genet* 1994;3:1561-4.
 - 46 Vikkula M, Mariman EC, Lui VC, et al. Autosomal dominant and recessive osteochondrodysplasias associated with the COL11A2 locus. *Cell* 1995;80:431-7.
 - 47 Sirko-Osadsa DA, Murray MA, Scott JA, Lavery MA, Warman ML, Robin NH. Stickler syndrome without eye involvement is caused by mutations in COL11A2, the gene encoding the alpha2(XI) chain of type XI collagen. *J Pediatr* 1998;132:368-71.
 - 48 van Steensel MA, Buma P, de Waal Malefijt MC, van den Hoogen FH, Brunner HG. Oto-spondylo-megaepiphyseal dysplasia (OSMED): clinical description of three patients homozygous for a missense mutation in the COL11A2 gene. *Am J Med Genet* 1997;70:315-23.
 - 49 Spranger J, Winterpacht A, Zabel B. The type II collagenopathies: a spectrum of chondrodysplasias. *Eur J Pediatr* 1994;153:56-65.
 - 50 Kniest W. Zur abgrenzung der dysostosis enchondrallis von der chondrodystrophie. *Z Kinderheilkd* 1952;70:633-40.
 - 51 Maumenee IH, Traboulsi EI. The ocular findings in Kniest dysplasia. *Am J Ophthalmol* 1985;100:155-60.
 - 52 Gray JR, Davies SJ. Marfan syndrome. *J Med Genet* 1996;33:403-8.
 - 53 Brown DM, Vandenburgh K, Kimura AE, Weingeist TA, Sheffield VC, Stone EM. Novel frameshift mutations in the procollagen 2 gene (COL2A1) associated with Stickler syndrome (hereditary arthro-ophthalmopathy). *Hum Mol Genet* 1995;4:141-2.
 - 54 Ahmad NN, McDonald-McGinn DM, Zackai EH, et al. A second mutation in the type II procollagen gene (COL2A1) causing Stickler syndrome (arthro-ophthalmopathy) is also a premature termination codon. *Am J Hum Genet* 1993;52:39-45.
 - 55 Williams CJ, Ganguly A, Considine E, et al. A-2→G transition at the 3' acceptor splice site of IVS17 characterizes the COL2A1 gene mutation in the original Stickler syndrome kindred. *Am J Med Genet* 1996;63:461-7.
 - 56 Ahmad NN, Ala-Kokko L, Knowlton RG, et al. Stop codon in the procollagen II gene (COL2A1) in a family with the Stickler syndrome (arthro-ophthalmopathy). *Proc Natl Acad Sci USA* 1991;88:6624-7.
 - 57 Brown DM, Nichols BE, Weingeist TA, Sheffield VC, Kimura AE, Stone EM. Procollagen II gene mutation in Stickler syndrome. *Arch Ophthalmol* 1992;110:1589-93.
 - 58 Ritvaniemi P, Hyland J, Ignatius J, Kivirikko KI, Prockop DJ, Ala-Kokko L. A fourth example suggests that premature termination codons in the COL2A1 gene are a common cause of the Stickler syndrome: analysis of the COL2A1 gene by denaturing gradient gel electrophoresis. *Genomics* 1993;17:218-21.
 - 59 Ahmad NN, Dimascio J, Knowlton RG, Tasman WS. Stickler syndrome. A mutation in the nonhelical 3' end of type II procollagen gene. *Arch Ophthalmol* 1995;113:1454-7.