

Phenotypic findings of Cowden syndrome and Bannayan-Zonana syndrome in a family associated with a single germline mutation in PTEN

Julide Tok Çelebi, Hui C Tsou, Fei Fei Chen, Hong Zhang, Xiao Li Ping, Mark G Lebowhl, Jeffrey Kezis, Monica Peacocke

Abstract

Cowden syndrome (CS) and Bannayan-Zonana syndrome (BZS) are two hamartoma syndromes with distinct phenotypic features. Although partial clinical overlap exists between CS and BZS, they are considered to be separate entities. PTEN has been identified as the susceptibility gene for both disorders, suggesting allelism. We have identified a germline mutation, R335X, in PTEN in a family consisting of two female members with the phenotypic findings of CS and two male members with the phenotypic findings of BZS. To our knowledge, this is the first report that shows the presence of separate subjects with CS and with BZS in a single family associated with a single germline PTEN mutation.

(*J Med Genet* 1999;36:360-364)

Keywords: Cowden syndrome; Bannayan-Zonana syndrome; PTEN

Cowden syndrome (CS) and Bannayan-Zonana syndrome (BZS) are both autosomal dominantly inherited diseases characterised by hamartomas and distinct phenotypic features. CS, described by Lloyd and Dennis¹ in 1963, also known as multiple hamartoma syndrome, is characterised by skin findings and hamartomas in a variety of tissues including the breast, thyroid, skin, gastrointestinal tract, endometrium, and the brain.¹⁻² Many, but not all patients with CS have skin findings, usually developing in the second decade of life. The skin lesions fall into four broad categories including facial papules (trichilemmomas), oral papillomatoses, and acral and palmo-plantar keratoses.³ Identification of multiple trichilemmomas, or benign tumours of the hair infundibulum, are pathognomonic of CS.⁴ In addition to the hamartomas and benign tumours, patients with CS have an increased risk of developing breast (25-50%) and thyroid cancers (3-10%).⁵⁻⁶ Moreover, women with this disease appear to develop breast cancer at a

younger age.⁷ Central nervous system (CNS) manifestations of CS include macrocephaly (38%), Lhermitte-Duclos disease (LDD) or dysplastic gangliocytoma of the cerebellum, and less commonly mental retardation.⁸⁻⁹

Bannayan-Zonana syndrome (BZS), described by Riley and Smith,¹⁰ Bannayan,¹¹ Zonana *et al*,¹² and Ruvalcaba *et al*,¹³ has been recognised under different names, including Bannayan-Zonana syndrome, Ruvalcaba-Myre syndrome, Riley-Smith syndrome, and recently Bannayan-Riley-Ruvalcaba syndrome.¹⁰⁻¹⁷ Macrocephaly is the predominant finding in patients with this disease.¹⁸ Characteristic features other than macrocephaly are CNS abnormalities, lentiginos of the penis, and hamartomatous growths, such as subcutaneous and visceral lipomas, intestinal polyposis, and vascular malformations. At least half of the patients with BZS have CNS anomalies including hypotonia, delayed psychomotor development, mild to severe mental retardation, and seizures. Ocular abnormalities, such as prominent Schwalbe lines and corneal nerves, lipid storage myopathy, and a variety of skeletal system abnormalities, including joint hyperextensibility, pectus excavatum, and scoliosis are additional associated manifestations of the syndrome.¹⁹ Unlike CS, an increased risk of malignancy has not been documented in patients with BZS.²⁰ Although CS and BZS have distinct phenotypic features, the presence of macrocephaly, intestinal polyposis, and lipomas in both diseases suggests a partial clinical overlap. Moreover, the presence of features common in CS and BZS within the same family has been reported in a few kindreds.²¹

Linkage analysis of 12 families with CS have determined the locus for this syndrome to be on chromosome 10q23.²² Subsequently, a putative tumour suppressor gene, PTEN/MMAC1/TEP1, was identified in this CS critical region²³⁻²⁵ and germline mutations in the PTEN gene were found in subjects with CS.²⁶⁻²⁸ PTEN is a dual specificity phosphatase. While the core phosphatase domain is present at residues 122-134, other areas of significance include three potential tyrosine phosphorylation sites at

Department of
Dermatology,
Columbia
Presbyterian Hospital,
Columbia University,
College of Physicians
and Surgeons, 630
West 168th Street, New
York, New York 10032,
USA

J T Çelebi
H C Tsou
F F Chen
H Zhang
X L Ping
J Kezis
M Peacocke

Department of
Dermatology, The
Mount Sinai School of
Medicine, The Mount
Sinai Medical Center,
One Gustave L Levy
Place, Box 1130, New
York, New York 10029,
USA
M G Lebowhl

Correspondence to:
Dr Peacocke.

Received 27 October 1998
Revised version accepted for
publication 14 December
1998

residues 233-240, 308-315, and 336. Sequence analysis of PTEN shows homology to tensin, a protein associated with focal adhesions, and to auxillin, a cytoskeletal protein.²⁴

The identification of PTEN as the susceptibility gene for BZS followed soon after the

identification of germline mutations of PTEN in CS, suggesting allelism.²⁹ Of interest, a non-sense mutation, R233X, has been previously reported in a family with CS, as well as in an unrelated family with BZS.^{20,30} We describe here, for the first time, a family with two female

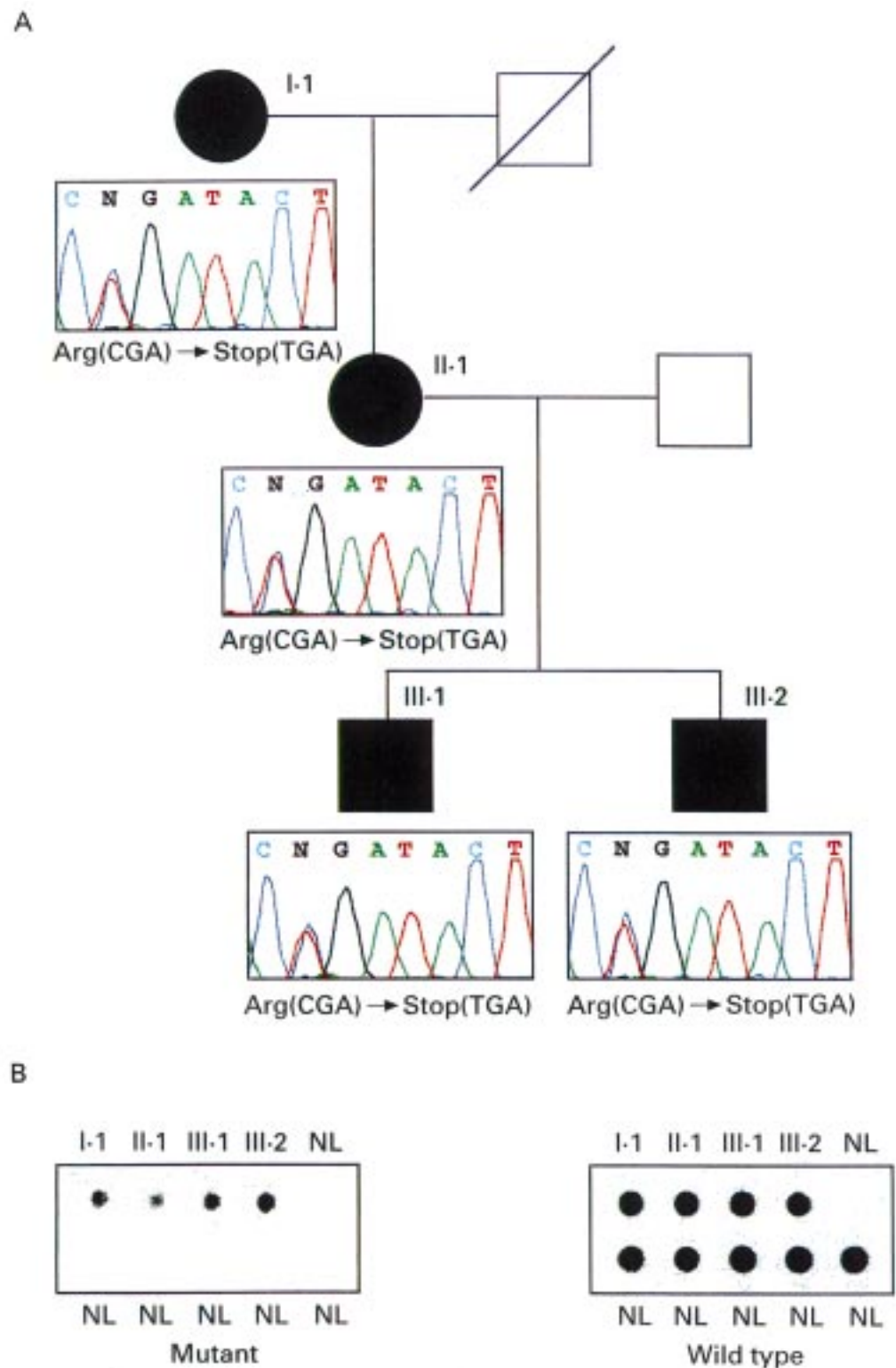


Figure 1 (A) DNA sequence analysis of the PTEN gene in four members from three generations in this family. A C→T transition was evident in all four affected subjects which resulted in a premature stop at codon 335. (B) Analysis of PCR products flanking exon 8 of the PTEN gene by allele specific hybridisation with mutant and wild type oligonucleotides showed the presence of the two alleles in the affected subjects but not in the unaffected population.

Table 1 Summary of family MHSF-066, clinical phenotype and associated mutations

Patient	Age/ sex	Diagnosis	Mutation/ predicted effect	Skin	Thyroid	Breast	CNS	GI	Other
MHSF066-1	31/F	CS	1003 C→T R335X	Trichilemmomas Oral papillomas Acral keratoses	Follicular carcinoma (10) Metastasis (lung) (12)	Ductal carcinoma (21)	Macrocephaly Multiple sclerosis (26)	—	Osteosarcoma (12) Lipoma (12)
MHSF066-2	54/F	CS	1003 C→T R335X	Trichilemmomas Oral papillomas Acral keratoses	Hashimoto's thyroiditis (42)	Ductal carcinoma (48)	Macrocephaly Slurred speech	—	—
MHSF066-3	9/M	BZS	1003 C→T R335X	Lentiginos of the penis	—	—	Macrocephaly Developmental delay Dysarthria Hypotonia	—	—
MHSF066-4	6/M	BZS	1003 C→T R335X	Lentiginos of the penis	—	—	Macrocephaly Developmental delay Dysarthria Hypotonia	—	—

() : age at diagnosis.

members phenotypically fulfilling the criteria for CS and two male members with the phenotypic findings of BZS associated with a single germline mutation in the PTEN coding sequence. The transition, C to T, at nucleotide 1003 in exon 8 resulted in the arginine being replaced by a stop codon (R335X). While CS and BZS are considered to be allelic disorders, this is the first report showing the existence of a single PTEN mutation in the same germline conferring the phenotypic findings of both syndromes. Moreover, these data support the notion that a family history of breast tumour can be identified in males with BZS.

Materials and methods

FAMILY

The diagnosis of CS was made using the international Cowden's Consortium CS diagnosis criteria. The diagnosis of BZS was made according to accepted clinical criteria. Blood samples were obtained after informed consent from subjects with CS.

DNA EXTRACTION

Genomic DNA was extracted from whole blood using a QIAamp Blood Maxi Kit (Qiagen). DNA concentration was measured by OD₂₆₀ and purity was checked by the ratio of OD₂₆₀/OD₂₈₀.

PCR AMPLIFICATION AND MUTATION DETECTION

Genomic DNA was amplified with primers flanking the exons of PTEN/MMAC1 as described.^{7,24} For mutation detection, PCR products were sequenced using an Applied Biosystem 310 automated sequencing system.

ALLELE SPECIFIC HYBRIDISATION

Oligonucleotides (20 base pairs) were synthesised with either the wild type or the mutant nucleotide located in the centre. DNA from subjects with a mutation and normal controls were amplified and blotted onto the nylon membranes. Oligonucleotides were then labelled with ³²PγATP and used as probe in the hybridisation reactions. Two identical membranes containing mutant and normal PCR products were hybridised with wild type and mutant oligonucleotides respectively in a buffer (5 × Denhardt's, 5 × SSPE, 0.5% SDS) at 48°C for two hours. Blots were then washed in 2 ×

SSPE, 0.1% SDS at 48°C for 30 minutes. The blots were then air dried and autoradiology performed at -70°C with Kodak XAR film and intensifying screens.

Results

As shown in the pedigree (fig 1), the MHSF066 family consists of affected family members in three generations, two subjects with CS and two with BZS. MHSF066-01 and her mother, MHSF066-02, both phenotypically fulfil the criteria for CS, by the presence of classical skin lesions and benign and malignant neoplasms. The germline mutations in PTEN and associated phenotypes are listed in table 1. MHSF066-01, who has been reported previously,³¹ is a 31 year old white female with a unique presentation of CS. She was diagnosed with a follicular thyroid carcinoma at the age of 10, which later metastasised to the left lung and was treated successfully with surgical resection. At the age of 12, she developed an osteosarcoma of the left proximal tibia and a large lipoma (10 × 15 cm) in the mediastinum. Intraductal breast carcinoma was diagnosed at the age of 21 and multiple sclerosis at the age of 26. In addition to having a complex medical history, she gave birth to two male infants subsequently identified as having BZS. MHSF066-03 and MHSF066-04, currently 9 and 6 years old respectively, were both born with macrocephaly (>95th centile) with normal ventricular size. During their early childhood years, they showed signs of developmental delay, hypotonia, and lentiginos of the penis, all characteristic of BZS.

The affected and unaffected members of family MHSF066 were analysed for germline PTEN mutations. Direct sequencing analysis of the PCR product flanking exon 8 showed a transition of C to T at nucleotide 1003, resulting in a change from arginine to a stop codon (R335X). This nonsense mutation was identified in all four affected subjects with CS and BZS in this family.

The mutation was subsequently confirmed by allele specific oligonucleotide (ASO) analysis (fig 1), which showed both the wild type and the mutant allele from each of the affected subject's genomic DNA. By contrast, ASO of 30 alleles from unaffected, unrelated subjects failed to identify the mutant allele.

Table 2 Summary of BZS mutations in PTEN and the coexistence of identical mutations in families with CS and BZS

	Mutation	Phenotype	Reference
1	S170R	BZS	20
2	520del25	BZS	20
3	1390delC	BZS	32
4	Y178X	BZS	32
5	Q214X	BZS	32
6	E256X	BZS	32
7	Y68H	BZS	20
	Y68H	CS	28
8	R233X	BZS	20
	R233X	CS	30
9	R335X	CS, BZS	Present case
	R335X	CS	30
	R335X	CS	30
	R335X	CS	20

Discussion

PTEN has been identified as the susceptibility gene for two hamartoma syndromes, CS and BZS.²⁰ Although distinct phenotypically, these two disorders display partial clinical overlap.²¹ We have identified a germline mutation, R335X, in the PTEN coding sequence, in a family with two members with the classical phenotypic findings of CS and two members with the classical phenotypic findings of BZS. To our knowledge, this is the first report that contains subjects with the CS and the BZS phenotype in a single family resulting from the same PTEN mutation. Since patients with CS usually develop characteristic skin findings in the second decade, it will be crucial to follow the two affected male children with BZS in this family to evaluate whether the features of CS develop. The severe tumour phenotype of proband MHSF 066-01 also deserves comment. In addition to developing malignant tumours at a young age, including osteosarcoma, follicular thyroid carcinoma with metastasis to the lung, and breast carcinoma, she also shows an unknown association of CS, that is, multiple sclerosis.

To date, nine families with BZS have been screened for PTEN mutations, of which five were found to exhibit mutations in this gene.^{20 28 30 32} These are summarised in table 2. Of interest, two of the mutations identified in BZS families, R233X and Y68H, were also independently reported in unrelated families with CS.^{20 28 30} R335X represents another example of a particular germline PTEN mutation being present in both syndromes.^{20 30} Although the mutation reported herein, R335X, has not been previously reported in BZS, it has been observed in three unrelated families with CS. Moreover, we have recently identified R335X in an unrelated female proband with BZS (J Tok *et al*, unpublished data), suggesting that this truncating PTEN mutation is common in both hamartoma syndromes. Additionally, we have tested a frameshift mutation, 915del13, resulting in a premature stop at codon 312 in exon 8, and identified almost a complete loss of the PTEN phosphatase activity (unpublished data). Similar functional changes are predicted to occur with the truncating PTEN mutation R335X.

These data, together with our own, clearly indicate that an identical mutation, found in a single germline, in the PTEN gene can confer susceptibility to two distinct phenotypes, CS and BZS. These observations suggest that increased susceptibility to breast and thyroid cancer may be found in members of BZS families associated with germline PTEN mutations. Moreover, it also suggests that women with CS may give birth to offspring with the findings of BZS as well as CS. While the notion that these two diseases may be within the spectrum of the same primary disorder awaits further study, we cannot exclude the presence of epigenetic factors, such as sex hormones or other modifying genes playing a role in the pathogenesis of the phenotypic findings of both syndromes.

The authors are grateful to this family for their participation in the study. This work was supported by grants from the National Cancer Institute (RO-1 CA-66693 and RO-1 CA-70519 to MP), the National Institute on Aging (K-04 AG-00694 to MP), and the National Institute of Arthritis and Musculoskeletal and Skin Diseases, Skin Disease Research Center (PO-30 AR44535 to David R Bickers).

- Lloyd KM, Dennis M. Cowden's syndrome. A possible new syndrome complex with multiple system involvement. *Ann Intern Med* 1963;58:136-42.
- Weary PE, Gorlin RJ, Gentry WC, Comer JE, Greer K. Multiple hamartoma syndrome (Cowden's syndrome). *Arch Dermatol* 1972;106:682-90.
- Salem OS, Steck WD. Cowden's syndrome (multiple hamartoma syndrome and neoplasia syndrome). *J Am Acad Dermatol* 1983;8:686-96.
- Brownstein MH, Mehregan AH, Bikowski JB. Trichilemmomas in Cowden's syndrome. *JAMA* 1977;238:26.
- Brownstein MH, Wolf M, Bikowski JB. Cowden's syndrome: a cutaneous marker of breast cancer. *Cancer* 1978;41:2393-8.
- Schrager CA, Schneider D, Gruener AC, Tsou HC, Peacocke M. Clinical and pathological features of breast disease in Cowden's syndrome: an underrecognized syndrome with an increased risk of breast cancer. *Hum Pathol* 1998;29:47-53.
- Tsou HC, Teng DH, Ping Li X, *et al*. The role of *MMAC1* mutations in early-onset breast cancer: causative in association with Cowden syndrome and excluded in *BRCA1*-negative cases. *Am J Hum Genet* 1997;61:1036-43.
- Albrecht S, Haber RM, Goodman JC, Duvic M. Cowden syndrome and Lhermitte-Duclos syndrome. *Cancer* 1992;70:869-85.
- Eng C, Murday V, Seal S, Mohammad S, *et al*. Cowden syndrome and Lhermitte-Duclos disease in a family: a single genetic syndrome with pleiotropy? *J Med Genet* 1994;31:458-61.
- Riley HD, Smith WR. Macrocephaly, pseudopapilledema and multiple hemangiomas. A previously undescribed hereditary familial syndrome. *Pediatrics* 1960;26:293-300.
- Bannayan GA. Lipomatosis, angiomas, and macrencephaly. A previously undescribed congenital syndrome. *Arch Pathol* 1971;92:1-5.
- Zonana J, Rimoin DL, Davis DC. Macrocephaly with multiple lipomas and hemangiomas. *J Pediatr* 1976;89:600-2.
- Ruvalcaba RHA, Myhre S, Smith DW. Sotos syndrome with intestinal polyposis and pigmentary changes of the genitalia. *Clin Genet* 1980;18:413-16.
- Higginbottom MC, Schultz P. The Bannayan syndrome: an autosomal dominant disorder consisting of macrocephaly, lipomas, hemangiomas, and risk for intracranial tumors. *Pediatrics* 1982;69:632-4.
- DiLiberti JH, Weleber RG, Budden S. Ruvalcaba-Myhre-Smith syndrome: a case with probable autosomal dominant inheritance and additional manifestations. *Am J Med Genet* 1983;15:491-5.
- Miles JH, Zonana J, McFarlane J, Aleck KA, Bawle E. Macrocephaly with hamartomas: Bannayan-Zonana syndrome. *Am J Med Genet* 1984;19:225-34.
- Cohen MM. Bannayan-Riley-Ruvalcaba syndrome: renaming three formerly recognized syndromes as one etiologic entity. *Am J Med Genet* 1990;35:291.
- Halal F. Male to male transmission of cerebral gigantism. *Am J Med Genet* 1982;12:411-19.
- Gorlin RJ, Cohen MM, Condon LM, Burke BA. Bannayan-Riley-Ruvalcaba syndrome. *Am J Med Genet* 1992;44:307-14.
- Marsh DJ, Coulon V, Lunetta KL, *et al*. Mutation spectrum and genotype-phenotype analyses in Cowden disease and Bannayan-Zonana syndrome, two hamartoma syndromes with germline *PTEN* mutation. *Hum Mol Genet* 1998;7:507-15.

- 21 Fargnoli MC, Orlow SJ, Semel-Concepcion J, Bologna JL. Clinicopathologic findings in the Bannayan-Riley-Ruvalcaba syndrome. *Arch Dermatol* 1996;**132**:1214-18.
- 22 Nelen MRP, Peeters EAJ, Lin AY, et al. Localization of the gene for Cowden disease to chromosome 10q22-23. *Nat Genet* 1996;**13**:114-16.
- 23 Li J, Yen C, Liaw D, et al. *PTEN*, a putative protein tyrosine phosphatase gene mutated in human brain, breast, and prostate cancer. *Science* 1997;**275**:1943-7.
- 24 Steck PA, Perhouse MA, Jasser SA, et al. Identification of a candidate tumor suppressor gene, *MMAC1*, at chromosome 10q23.3 that is mutated in multiple advanced cancers. *Nat Genet* 1997;**15**:356-62.
- 25 Li DM, Sun H. *TEP1*, encoded by a candidate tumor suppressor locus, is a novel tyrosine phosphatase regulated by transforming growth factor β . *Cancer Res* 1997;**57**:2124-9.
- 26 Liaw D, Marsh DJ, Dahia PLM, et al. Germline mutations of the *PTEN* gene in Cowden disease, an inherited breast and thyroid cancer syndrome. *Nat Genet* 1997;**16**:64-7.
- 27 Nelen MR, van Staveren WC, Peeters EA, et al. Germline mutations in the *PTEN/MMAC1* gene in patients with Cowden disease. *Hum Mol Genet* 1997;**6**:1383-7.
- 28 Tsou HC, Ping XL, Xie XX, et al. The genetic basis of Cowden's syndrome: three novel mutations in *PTEN/MMAC1/TEP1*. *Hum Genet* 1998;**102**:467-73.
- 29 Marsh DJ, Dahia PLM, Zheng Z, Parsons R, Gorlin RJ, Eng C. Germline mutations in the Cowden disease gene, *PTEN*, are present in Bannayan-Zonana syndrome. *Nat Genet* 1997;**16**:333-4.
- 30 Lynch ED, Ostermeyer EA, Lee MK, et al. Inherited mutations in *PTEN* that are associated with breast cancer, Cowden disease, and juvenile polyposis. *Am J Hum Genet* 1997;**61**:1254-60.
- 31 Yen BC, Kahn H, Schiller AL, Klein MJ, Phelps RG, Lebwohl MG. Multiple hamartoma syndrome with osteosarcoma. *Arch Pathol Lab Med* 1993;**117**:1252-4.
- 32 Longy M, Coulon V, Duboue B, et al. Mutations of *PTEN* in patients with Bannayan-Riley-Ruvalcaba phenotype. *J Med Genet* 1998;**35**:886-9.