

Complex consanguinity associated with short rib-polydactyly syndrome III and congenital infection-like syndrome: a diagnostic problem in dysmorphic syndromes

L I Al-Gazali, L Sztriha, A Dawodu, E Varady, M Bakir, A Khdir, J Johansen

Department of Paediatrics, Faculty of Medicine and Health Science, UAE University, PO Box 17666, Al Ain, UAE
 L I Al-Gazali
 L Sztriha
 A Dawodu

Department of Paediatrics, Tawam Hospital, Al Ain, UAE
 E Varady

Department of Paediatrics, Al Ain Hospital, Al Ain, UAE
 M Bakir
 A Khdir

Department of Radiology, Faculty of Medicine and Health Sciences, UAE University, Al Ain, UAE
 J Johansen

Correspondence to: Dr Al-Gazali.

Received 23 June 1998
 Revised version accepted for publication 5 November 1998

Abstract
 Short rib-polydactyly syndromes (SRPS) are a heterogeneous group of recessively inherited lethal skeletal dysplasias. Four types have been recognised. However, overlap in the clinical and radiological features of the four types has led to difficulties in distinguishing between them.

The congenital infection-like syndrome is an autosomal recessive syndrome characterised by mental retardation, microcephaly, seizures, and intracranial calcifications.

We report a complex consanguineous family of Baluchi origin in whom short rib-polydactyly type III and congenital infection-like syndrome are segregating. Four children inherited SRPS III, one inherited congenital infection-like syndrome, and one inherited both. Although the radiological features in all the children with SRPS in this report were typical of type III, there was overlap in the clinical features with the other types of SRP syndromes. Furthermore, the child who inherited both SRPS III and congenital infection-like syndrome had CNS malformations in addition to periventricular cal-

cification. CNS malformations have been described in SRPS types II and IV but not type III.

This report further highlights the overlap between the different types of SRP syndrome. Moreover, it draws attention to the importance of considering the possibility of two recessive syndromes in the same child in complex consanguineous families when features overlap two syndromes.

(J Med Genet 1999;36:461-466)

Keywords: complex consanguinity; short rib-polydactyly syndrome III; congenital infection-like syndrome

Short rib-polydactyly syndromes (SRPS) are a group of autosomal recessive, perinatally lethal skeletal dysplasias characterised by extremely short ribs, specific changes in the long bones and pelvis, and a variable degree of polydactyly.¹ Four types have been recognised.¹ However, there is overlap in the clinical and radiological features of the four types and it is difficult to distinguish between them.¹⁻⁵

Congenital infection-like syndrome is an autosomal recessive syndrome characterised by microcephaly, intracranial calcification, seizures, and mental retardation with various other features found in congenital infection.^{6,7}

We report a complex consanguineous family in which short rib-polydactyly syndrome type III and congenital infection-like syndrome are segregating. Four children inherited SRPS III, one inherited congenital infection-like syndrome, and another one inherited both syndromes. This last child had the typical clinical and radiological features of SRPS III. In addition, she had multiple frenulae and omphalocele, hydrocephalus, periventricular calcification, a small vermis, bilateral cataracts, and gross hepatomegaly. Some of these features have been reported in SRPS II and SRPS IV but not in SRPS III.^{4,5,8-10} This report further highlights the overlap between the different types of SRP syndrome. Moreover, it draws attention to the importance of recognising the possibility of two recessive syndromes in the same child in a complex consanguineous family when features overlap two syndromes.

Case reports

This Baluchi family shows complex consanguinity (fig 1). The mother is 24 years old and the father is aged 27 years. There was a history

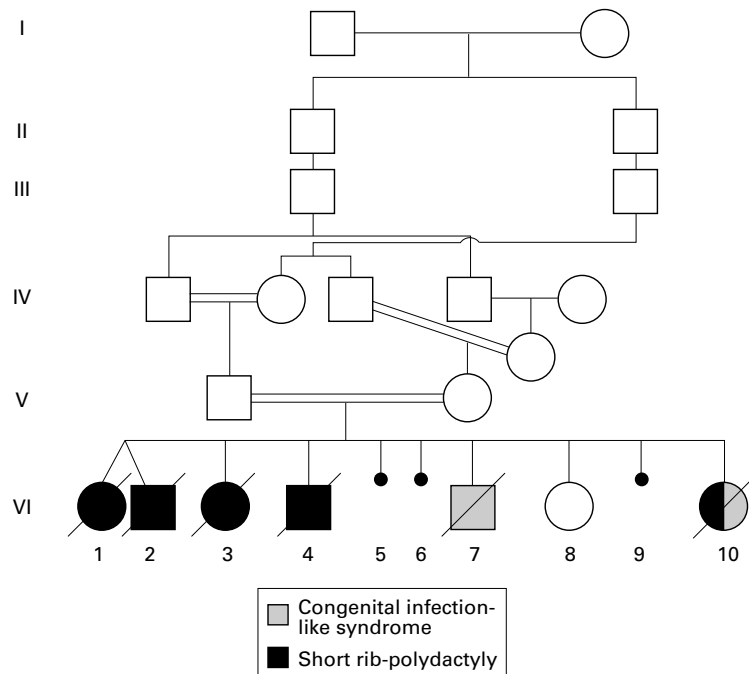


Figure 1 Family pedigree.

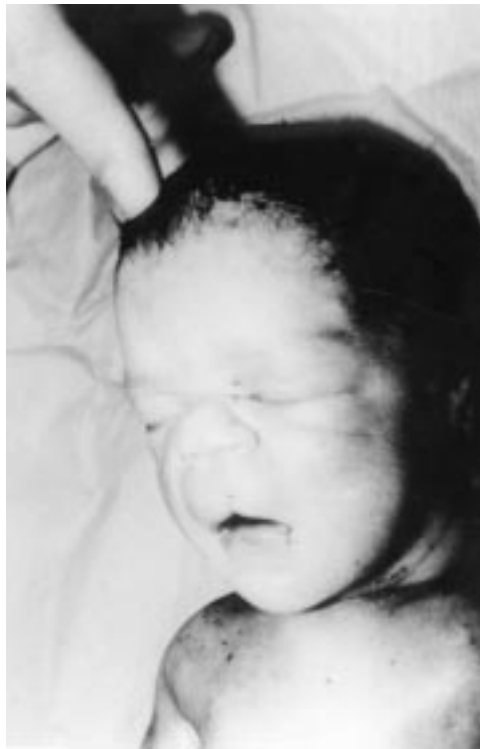

Figure 2 Case 1: facial appearance. Note short, upturned nose, long philtrum, and thin and notched upper lip.

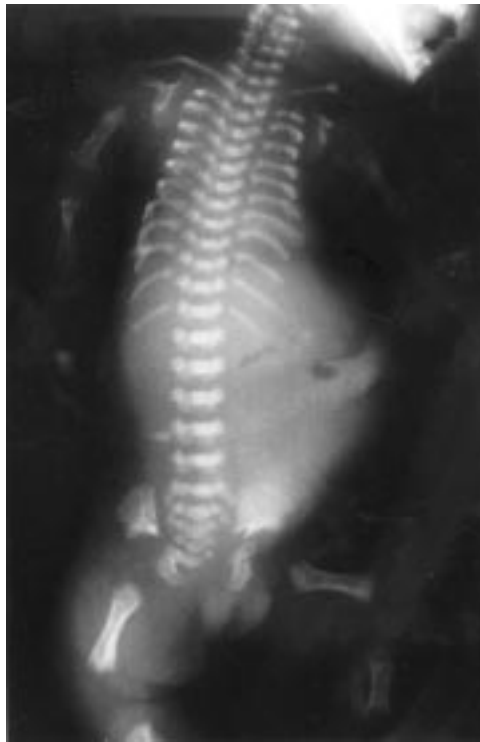


Figure 3 Case 1. Skeletal x ray showing a disproportionately small thorax with short, horizontal ribs, distinct corticomedullary demarcation of bones, lateral spurs at the end of the long tubular bones, a square pelvis with small sacroiliac notch, and triradiate acetabulum.

of three miscarriages all at 2 months of gestation. The first pregnancy resulted in the birth at 34 weeks of a twin male and female. Both died immediately after birth and both had

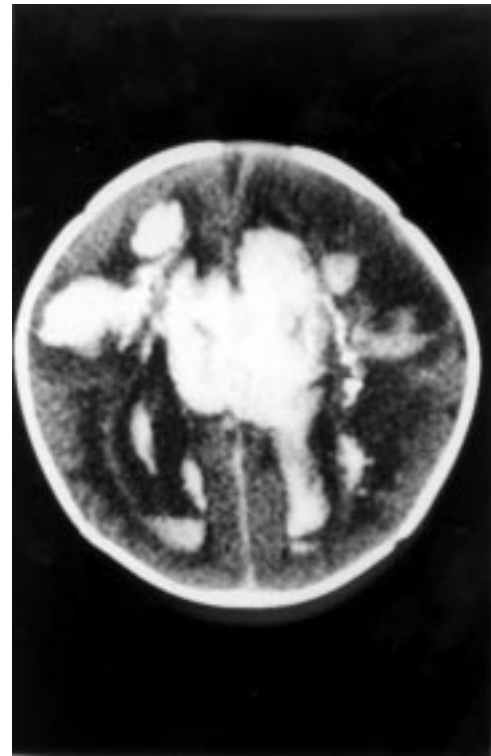


Figure 4 Brain CT scan of case 3 shows a large haemorrhage with extension into the basal ganglia, cortical parenchyma, and ventricles. Note the calcification in the periventricular white matter which can be distinguished from the bleeding, mainly on the left side (viewer's right).

polydactyly, short limbs, and narrow chest. No further information was available.

CASE 1: VI.3

The second pregnancy resulted in the birth of a female infant at 35 weeks' gestation by normal vaginal delivery. She lived for only 30 minutes. Birth weight was 1900 g (10th centile), length 40 cm (<10th centile), and head circumference 34 cm (>90th centile). She had a large head with a broad, high forehead, short, broad nose, a long, smooth philtrum, and a thin upper lip which was notched (fig 2). There was postaxial polydactyly of both hands and feet. The chest appeared narrow and the limbs were short.

Skeletal x rays showed a disproportionately small thorax with short, horizontal ribs, good bone mineralisation with distinct corticomedullary demarcation of long bones, and lateral spurs at the end of the tubular bones. The tibiae were longer than the fibulae and the pelvis looked square with a small sacroiliac notch and triradiate acetabular roof (fig 3). The vertebrae appeared small and flat and the anterior and posterior notches were clearly visible.

CASE 2: VI.4

The fourth child was born at term by normal vaginal delivery and died immediately after birth. He had short limbs, cleft lip and palate, exomphalos, and ambiguous genitalia. No measurements or radiological evaluation were available.

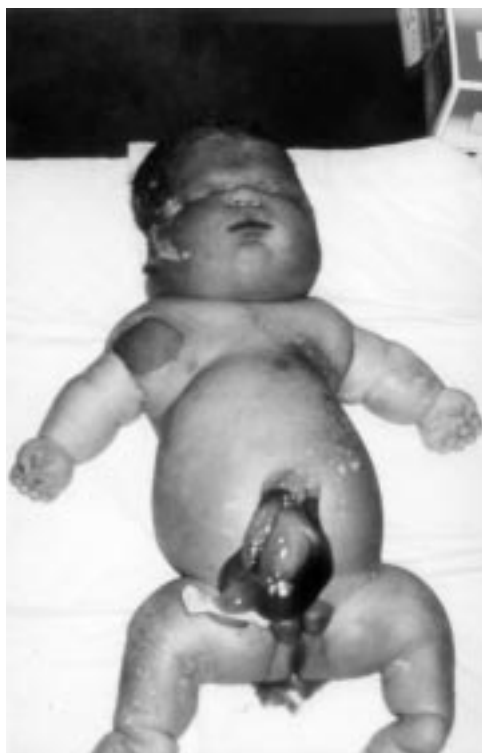

Figure 5 Case 4: general appearance. Note short limbs, postaxial polydactyly of the left hand, narrow thorax, distended abdomen, omphalocele, and oedematous genitalia.

CASE 3: VI.7

This male infant, the product of a normal pregnancy, was born at term by breech delivery. His birth weight was 2605 g (<10th centile), length 50 cm (>10th centile), and head circumference 35 cm (50th centile). The cord was around the neck and the baby required resuscitation at birth. He was noted to be pale, his Hb was 12.4 g, and haematocrit 36. He was given packed cell transfusion. After birth he was noted to be hypotonic with a bulging anterior fontanelle and distended

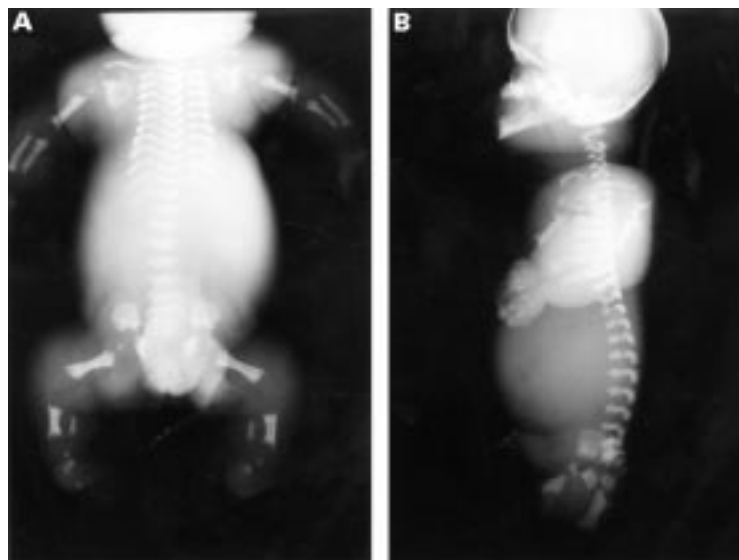


Figure 6 Case 4. (A) Skeletal x rays showing disproportionately small thorax with short horizontal ribs, lateral spurs at the end of the long bones, and square pelvis with triradiate acetabulum. Note premature ossification of the upper femoral and humeral epiphyses. (B) Lateral x rays of the spine showing small and flat vertebrae.

abdomen. There were no dysmorphic features. The liver was 5 cm below the costal margin. There was a pansystolic murmur grade III at the left sternal edge. Detailed eye examination showed bilateral cataracts. Brain ultrasound showed focal echogenic areas in the thalamic region with mildly dilated ventricles. Ultrasound of the kidney was normal. By the second day the head circumference had increased to 36 cm and the fontanelle became more tense and bulging. CT scan showed a large haemorrhage in the middle of the brain which had destroyed the basal ganglia and showed extension into the ventricles. The ventricles were enlarged and the brain mantle was thin. Intraparenchymal haemorrhage was seen in the frontal lobes as well. There was calcification in the periventricular white matter (fig 4). Echocardiography showed a patent ductus arteriosus and a ventricular septal defect. Other investigations, including blood picture, platelet count, and liver function tests, were normal. TORCH screening (serological examination for CMV, toxoplasmosis, and rubella, plus urine examination for CMV virus particles), serum and urine amino acid chromatography, urine organic acid, and chromosome analysis were normal. The baby was scheduled for ventricular drainage but deteriorated and died on the ninth day of life. A diagnosis of possible congenital infection was made.

CASE 4: VI.10

This female infant was the product of a pregnancy complicated by polyhydramnios. Prenatal ultrasound at 32 weeks showed a hydropic fetus with a small thorax and hypoplastic lungs. There was an abdominal wall defect and dysplastic kidneys. There was evidence of abnormal cerebral brain tissue and asymmetrical cerebral hemispheres. The delivery at term was normal. Birth weight was 2300 g (<10th centile), length 45 cm (<10th centile), and head circumference 34 cm (>10th centile). She lived for only a few minutes.

On physical examination, she had multiple abnormalities. These included short limbs, a very narrow chest, bilateral cataracts, a short, upturned nose, long smooth philtrum, thin lips, notched upper lip, multiple frenula, abnormal, small ears with very small auditory canals, a short neck with a pad of fat on the back of it, postaxial polydactyly of the left hand, and bilateral hallux valgus with talipes equinovarus deformities (fig 5). There was exomphalos and bilateral kidney masses. The liver was firm and enlarged 6 cm below the costal margin. The genitalia were normal. Skeletal survey showed a disproportionately small thorax with horizontal ribs, short tubular bones with good mineralisation, and distinct corticomedullary demarcation of the long bones and lateral spurs at the end of the tubular bones. The pelvis looked square with a small sacroiliac notch and a triradiate acetabular roof (fig 6). The tibiae appeared longer than the fibulae. The vertebral bodies were small and flat (fig 6). There was premature ossification of the upper femoral and upper humeral epiphyses. Chromosome analysis and TORCH

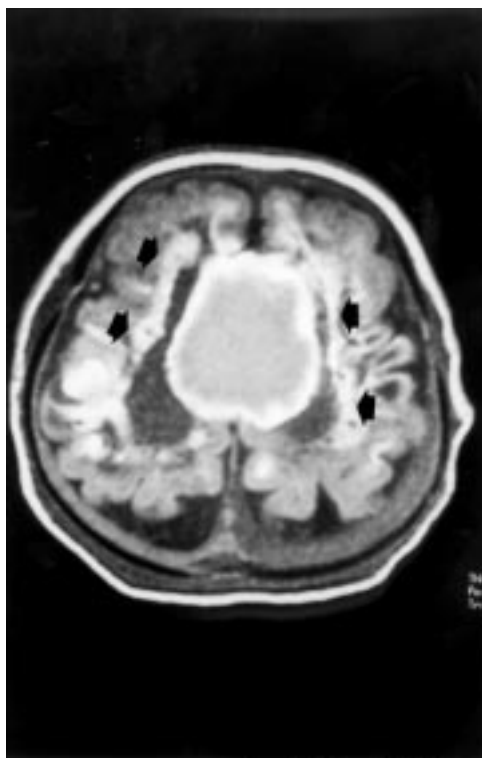


Figure 7 Case 4. Transaxial T1 weighted (672/14, TR/TE) MR image shows a simplified gyral pattern with shallow sulci and variation in the size of the gyri. A large haemorrhage destroyed the basal ganglia. Calcification bilaterally in the periventricular white matter is well illustrated (arrows).

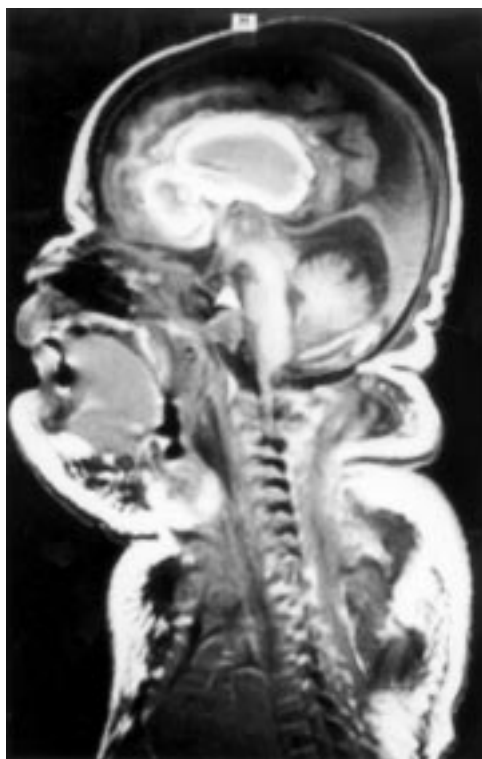

Figure 8 Case 4. Sagittal T1 weighted (672/14, TR/TE) MR image shows the large midline bleeding with extension into the frontal lobe. The cerebellum is small, the brainstem deformed. The foramen magnum and cervical spinal canal are stenotic.

tests were normal. CT scan of the kidneys showed bilateral cystic dysplastic kidneys.

Postmortem CT scan showed enlarged ventricles, a thin brain mantle, and simplified gyral pattern. There was a large haemorrhage in the middle of the brain, so the basal ganglia and third ventricle were not visible. Several small parenchymal haemorrhages were seen in the posterior frontal and parietal areas. There was widespread calcification in the periventricular white matter.

Postmortem MRI showed a simplified gyral pattern with a thin cortex. Most of the sulci were shallow and there was variation in the size of the gyri. The white matter was very thin in the periventricular area and showed abnormally low signal intensity on T1 weighted images. The lateral ventricles were dilated. A large haemorrhage with high signal intensity was seen in the middle of the brain, above the thalami with extension into the ventricles. The basal ganglia were not recognisable because of the haemorrhage which showed intraparenchymal extension including the medial parts of the frontal lobes. The corpus callosum was absent. There was widespread calcification in the periventricular white matter (fig 7). The cerebellar vermis was small, the brainstem was deformed, and the foramen magnum and cervical spinal canal were stenotic (fig 8).

Discussion

The perinatally lethal short rib-polydactyly syndromes (SRPS) are a heterogeneous group of newborn skeletal dysplasias, with autosomal recessive inheritance of extremely short ribs, specific changes in the long bones, pelvic abnormalities, a variable degree of polydactyly, and a high frequency of major congenital malformations.¹ Two groups have been identified: the Majewski group (SRPS II) and non-Majewski group. The non-Majewski group comprises three types: type I SRPS (Saldino-Noonan), type III SRPS (Verma-Namauf), and type IV SRPS (Beemer-Langer).¹¹

Overlap between the three types of non-Majewski SRPS has been reported and several authors have argued that the three non-Majewski types of SRPS represent variable expression of the same gene locus.²⁻³ There are also reports of cases with Majewski type SRPS with features overlapping one or more of the non-Majewski types.⁴⁻⁵ This has led to difficulties in distinguishing the different types of SRP syndromes. Currently there is controversy as to whether all these types represent a continuous spectrum of the same disorder.⁴⁻⁵

The clinical and radiological features in our cases (cases 1, 2, and 4) are compatible with the diagnosis of SRPS III. However, there are also some overlapping features with the other types of SRPS. Clinically these children had short limbs, a narrow chest, postaxial polydactyly, a short, broad nose, a long philtrum, a median notch of the upper lip in two of them, and a median cleft lip and palate in one. Multiple oral frenula were present in one case (case 4). Median cleft lip and palate are features of Majewski type SRPS II and Beemer-Langer

Table 1 CNS abnormalities described in Majewski and Beemer-Langer SRPS compared to case 4

Type of malformation	Majewski	Beemer-Langer	Case 4 in this report
Abnormal gyri	+	+	+
Agenesis/hypoplasia of corpus callosum	+	+	+
Dilated lateral ventricles	+	+	+
White matter calcification	-	-	+
Absence of olfactory bulbs	+	-	-
Vermis hypoplasia	+	+	+
Holoprosencephaly	-	+	-
Encephalocele	-	+	-
Arachnoid cyst	+	+	-
Anencephaly	+	-	-
Diencephalic hamartoma	+	-	-
Malformed circle of Willis	-	+	-
Deformed brain stem	-	-	+
Stenotic foramen magnum and cervical spinal canal	-	-	+
Brain haemorrhage	-	-	+

type IV.^{4-5,9} Similarly oral frenula have been reported in type IV only. Two of our cases had omphalocele (cases 2 and 4). This abnormality has been reported in type IV only.⁴⁻⁵ Radiological data were available in cases 1 and 4. Both showed typical changes of type III SRPS. These include a disproportionately small thorax, good corticomedullary demarcation of the long bones with lateral spurs at the end of the long bones, triradiate acetabular roof, the tibia appears longer than the fibula, and small and flat vertebral bodies. Case 4 also had in addition to the above features bilateral cystic dysplastic kidneys, gross hepatomegaly, bilateral cataracts, and central nervous system malformations. Cystic dysplastic kidneys have been reported in all types of SRPS including type III.⁴⁻⁵

However, CNS malformations have been described only in type II (Majewski)^{5,9,12,13} and type IV (Beemer-Langer) SRPS¹⁴⁻¹⁸ and not in type III (table 1). The CNS abnormalities in case 4 of this report comprised the following: a thin brain mantle with simplified gyri, absent corpus callosum, dilated ventricles, a small cerebellar vermis with deformed brain stem, and stenotic foramen magnum and cervical spinal canal. In addition, there was a large haemorrhage in the middle of the brain with extension into the ventricles and widespread calcifications in the periventricular white matter.

Intraventricular haemorrhage is uncommon in term infants, but it can occur because of residual germinal matrix, vascular malformation, tumour, extension of a haemorrhagic cerebral infarction, or coagulopathy.^{19,20} Malformation of the circle of Willis has been reported in one case of Beemer-Langer SRPS.¹⁸ In addition, there is a report of a case with Majewski SRPS who had unusually tortuous and congested veins over the cerebral hemispheres. Periventricular calcification has not been reported in any of the SRPS types. In addition to the calcification, our case had gross hepatomegaly and bilateral cataracts. Hepatomegaly and liver fibrosis have been reported in both Majewski and Beemer-Langer SRPS^{17,18} and cataracts in Majewski type.¹⁰ However, case 3 in this report, who appeared normal externally with no dysmorphic features, shortening of limbs, or chest narrowing, had some of the

CNS abnormalities found in case 4, including periventricular calcification, intraventricular haemorrhage, and thin brain mantle. In addition, there was hepatomegaly, bilateral cataracts, and congenital heart defect. Calcification, mainly in the basal ganglia, can be associated with hypoxic ischaemic encephalopathy, hypoparathyroidism, metabolic and hereditodegenerative disorders (Aicardi-Goutieres syndrome), in addition to intrauterine infection.^{21,22} All these conditions were excluded in our cases on clinical grounds or laboratory tests. Although the structure of the basal ganglia was not seen in our cases 3 and 4 because of haemorrhage, severe calcification of the periventricular white matter was recognisable. This type of calcification can be found in intrauterine infection and in the autosomal recessive congenital infection-like syndrome.^{6,7} Although a clinical diagnosis of intrauterine infection was entertained, investigation for a possible congenital infection was negative in case 3. Therefore, in view of the complex consanguinity in this family, the lack of laboratory evidence for congenital infection, and the presence of the same type of calcification and haemorrhage in case 4 together with hepatomegaly and cataracts, we think that the autosomal recessive infection-like syndrome is the most likely diagnosis in both cases 3 and 4. This means that two recessive genes (one determining SRPS and the other congenital infection-like syndrome) are segregating in this family and case 4 is homozygous for both genes.

Reardon *et al*⁷ reported 10 patients with congenital infection-like syndrome from five families. They suggested two possible categories in this group. Those with CNS manifestation with haematological problems and hepatosplenomegaly and those without. Of the 18 patients reported with this syndrome,^{6,7,23-26} four did not have microcephaly at birth but developed it during the first few months of life.⁷ Therefore, absence of microcephaly at birth in our cases does not rule out this diagnosis. Bilateral cataract has also been reported in one previous case.²⁵ Bleeding tendency is known to occur in some patients with this syndrome. It is very likely that our patients had bleeding tendency which resulted in haemorrhage in the periventricular areas with destruction of the basal ganglia and involvement of the ventricles and parenchyma. The presence of cerebral dysplasia and residual germinal matrix in addition to a possible bleeding tendency might have contributed to the development of haemorrhage in both cases.

The family in this report highlights further the overlap between the established types of SRPS as has been suggested repeatedly.^{4,5,23,27} Several hypotheses have been put forward to explain this overlap and the wide spectrum of anomalies observed in these patients. The debate is whether the different types of this lethal chondrodysplasia are the result of several mutations at different genes or are the consequence of heterogeneity, different mutant alleles, and secondary intrauterine modification of the phenotype³ or all of the types are a

single genetic disorder with widely variable clinical expression.^{2-4 14} In view of the generalised abnormalities of all organ system, it has been suggested that a defect in the regulation of cellular differentiation exists in these syndromes. The basic genetic defect could also be modified by epigenetic influences thus leading to a variable phenotype.³ Urioste *et al*²⁸ proposed a tentative location on 4p16 for the gene or cluster of closely linked genes that are responsible for SRPS. This was based on the observation of a pericentric inversion at p16 and q13.2 in a patient with characteristic skeletal and extraskeletal manifestations of SRPS.²⁹ It is interesting to note that the fibroblast growth factor receptor 3 gene (FGFR3) is located in this region. Mutations in this gene were found to be responsible for the phenotype of achondroplastic hypochondroplasia and thanatophoric dysplasia I and II.^{31 32} This gene is expressed mainly in the skeleton and central nervous system.^{33 34} Since the CNS is affected in addition to skeletal involvement in most cases of SRPS, the FGFR3 gene could be regarded as a good candidate gene for the SRPS.

This report also draws attention to the fact that two syndromes could exist in the same child, particularly in the presence of complex consanguinity in the family. This might lead to confusion and difficulty in establishing a diagnosis. The task of providing a diagnosis in a dysmorphic child is usually a difficult one. This is particularly so in view of the existing variability and heterogeneity in many of the recognised syndromes. The presence of two syndromes in the same child makes this task even more difficult. It would have been extremely difficult, for example, to diagnose two separate syndromes in case 4 in this report if this child had been the first born in the family. In such instances, new features may be added to a syndrome or even a new syndrome may be diagnosed. Complex consanguinity is common in the United Arab Emirates and the frequency of recessive disorders, particularly dysmorphic syndromes, is high.³⁵ It is important, therefore, when dealing with this population and similar populations, to consider the possibility of two recessive syndromes existing in the same child when features overlap more than one syndrome.

- 1 Sillence D, Kozlowski K, Bar-Ziv J, Furhmann-Rieger A, Fuhrmann W, Pascu F. Perinatally lethal short rib-polydactyly syndromes. I Variability in known syndromes. *Pediatr Radiol* 1987;17:474-80.
- 2 Sillence D. Non-Majewski short rib-polydactyly syndrome. *Am J Med Genet*, 1980;7:223-9.
- 3 Bernstein R, Isdale J, Pinto M, DuToit Zaaijman J, Jenkins T. Short rib-polydactyly: a single or heterogeneous entity? A re-evaluation prompted by four new cases. *J Med Genet* 1985;22:46-53.
- 4 Martinez-Frias ML, Bermejo E, Urioste M, Egúés J, López Soler JA. Short rib-polydactyly syndrome with anencephaly and other central nervous system anomalies: a new type of SRPS or a more severe expression of a known SRPS entity? *Am J Med Genet* 1993;47:782-7.
- 5 Martinez-Frias ML, Bermejo E, Urioste M, Huertas H, Arroyo I. Lethal short rib-polydactyly syndromes: further

- evidence for their overlapping in a continuous spectrum. *J Med Genet* 1993;30:937-41.
- 6 Baraitser M, Brett EM, Piesowicz AT. Microcephaly and intracranial calcification in two brothers. *J Med Genet* 1983;20:210-12.
- 7 Reardon W, Hockey A, Silberstien P, *et al*. Autosomal recessive congenital intrauterine infection like syndrome of microcephaly, intracranial calcification and CNS disease. *Am J Med Genet* 1994;52:58-65.
- 8 Sharma AK, Phadke SR, Agarwal SS. Short rib-polydactyly syndrome type IV: Beemer-Langer syndrome. *Am J Med Genet* 1993;46:345.
- 9 Prudlo J, Stoltenburg-Didinger G, Jimenez E, Ceros-Navarro J. Central nervous alterations in a case of short-rib-polydactyly syndrome, Majewski type. *Dev Med Child Neurol* 1993;35:158-76.
- 10 Chess J. Ocular pathology of the Majewski syndrome. *Br J Ophthalmol* 1982;66:736-41.
- 11 Spranger J. International classification of osteochondrodysplasias. *Am J Med Genet* 1992;44:223-9.
- 12 Chen H, Yang SS, Gonzalez E, Fowler M, Al Saadi A. Short rib-polydactyly syndrome Majewski type. *Am J Med Genet* 1980;7:215-22.
- 13 Walley VM, Coates CF, Gilbert JJ, Valentine GH, Davies EM. Short rib-polydactyly syndrome, Majewski type. *Am J Med Genet* 1983;14:445-52.
- 14 Yang SS, Roth JA, Langer LO. Short rib-syndrome Beemer-Langer type with polydactyly: a multiple congenital anomalies syndrome. *Am J Med Genet* 1991;39:243-6.
- 15 Tsai YC, Chang JM, Changchien CC, *et al*. Unusual short rib-polydactyly syndrome. *Am J Med Genet* 1992;44:31-6.
- 16 Lin AE, Doshi N, Flom L, Tenenholz B, Filkins KL. Beemer-Langer syndrome with manifestations of an oro-facio-digital syndrome. *Am J Med Genet* 1991;39:247-51.
- 17 Hennekam RCM. Short rib syndrome - Beemer type in sibs. *Am J Med Genet* 1991;40:230-3.
- 18 Cideciyan D, Rodriguez MM, Haun RL, Abdenour GE, Bruce JH. New findings in short rib syndrome. *Am J Med Genet* 1993;46:255-9.
- 19 Volpe JJ. *Neurology of the newborn*. 3rd ed. Philadelphia: Saunders, 1995:389-91.
- 20 Barkovich AJ. *Pediatric neuroimaging*. 2nd ed. New York: Raven Press, 1995:138.
- 21 Aicardi J. *Diseases of the nervous system in childhood*. New York: Cambridge University Press, 1992:544-5.
- 22 Aicardi J, Goutieres F. A progressive familial encephalopathy in infancy with calcifications of the basal ganglia and chronic cerebrospinal fluid lymphocytosis. *Ann Neurol* 1984;15:49-54.
- 23 Burn J, Wickramasinghe HT, Harding B, Baraitser M. A syndrome with intracranial calcification and microcephaly in two sibs resembling intrauterine infection. *Clin Genet* 1986;30:112-16.
- 24 Ishitsu T, Chikazawa S, Matsuda I. Two siblings with microcephaly associated with calcification of cerebral white matter. *Jpn J Hum Genet* 1985;30:213-17.
- 25 Wiczorek D, Gillessen-Kaesbach G, Passarge E. A nine month old boy with microcephaly, cataracts, intracerebral calcification and dysmorphic signs: an additional observation of an unusual autosomal recessive congenital infection-like syndrome. *Genet Couns* 1995;6:297-302.
- 26 Al-Dabbous R, Sabry MA, Farah S, Al-Awadi SA, Simeonor S, Farag TI. The autosomal recessive congenital infection-like syndrome of microcephaly intracranial calcification and CNS disease: report of another Bedouin family. *Clin Dysmorphol* 1998;17:127-30.
- 27 Cherstvoy ED, Lurie IW, Shved IA, Lazjuk GI, Ostrowskaya TI, Usojev SS. Difficulties in classification of the short rib-polydactyly syndromes. *Eur J Pediatr* 1980;133:57-61.
- 28 Urioste M, Martinez-Frias ML, Bermejo E, *et al*. Chromosome 4p16 and osteochondroplasias. *Nat Genet* 1994;6:334.
- 29 Urioste M, Martinez-Frias ML, Bermejo E, *et al*. Short rib polydactyly syndrome and pericentric inversion of chromosome 4. *Am J Med Genet* 1994;49:94-7.
- 30 Shiang R, Thompson LM, Zhu YZ, *et al*. Mutation in the transmembrane domain of FGFR, cause the most common genetic form of dwarfism, achondroplasia. *Cell* 1994;78:94-7.
- 31 Tavormina PT, Shiang R, Thompson LM, *et al*. Thanatophoric dysplasia (types I and II) caused by distinct mutations in fibroblast growth factor receptor 3. *Nat Genet* 1995;9:321-8.
- 32 Bellus GA, McIntosh I, Smith EA, *et al*. A recurrent mutation in tyrosine kinase domain of FGFR, causes hypochondroplasia. *Nat Genet* 1995;10:357-9.
- 33 Peters K, Ornitz D, Werner S, Williams L. Unique expression pattern of the FGF receptor 3 gene during mouse organogenesis. *Dev Biol* 1993;155:423-30.
- 34 Partanen I, Mäkelä TP, Eerola E, *et al*. FGFR-4 a novel fibroblast growth factor receptor with a distinct expression pattern. *EMBO J* 1991;10:1347-54.
- 35 Al-Gazali LL, Dawodu A, Sabrinathan, Varghese M. The profile of congenital abnormalities in the United Arab Emirates. *J Med Genet* 1995;32:7-13.