

Review article

**University
Department of
Medical Genetics and
Regional Genetic
Service, St Mary's
Hospital, Hathersage
Road, Manchester
M13 0JH, UK**
A Slavotinek

**Baylor College of
Medicine, Department
of Molecular and
Human Genetics,
Houston, TX 77030,
USA**
L G Shaffer
S K Shapira

**Baylor College of
Medicine, Department
of Pediatrics, Houston,
TX 77030, USA**
S K Shapira

Correspondence to:
Dr Slavotinek, National
Human Genome Research
Institute, National Institutes
of Health, Bldg 49, Room
4B75, 49 Convent Drive,
MSC 4472, Bethesda, MD
20892, USA.

Monosomy 1p36

Anne Slavotinek, Lisa G Shaffer, Stuart K Shapira

Abstract

We have reviewed published reports on patients with segmental aneusomy for chromosome 1p36 to help geneticists and other health professionals in the recognition of this emerging chromosomal syndrome. Terminal deletions of the short arm of chromosome 1 are associated with hypotonia and developmental delay (usually severe), growth abnormalities (growth retardation, microcephaly, obesity), and craniofacial dysmorphism with a large anterior fontanelle, prominent forehead, deep set eyes, flat nasal bridge and midface hypoplasia, ear asymmetry, a pointed chin, and orofacial clefting. Minor cardiac malformations, cardiomyopathy,

seizures, and ventricular dilatation are the more common additional findings. Sensorineural hearing loss and variable ophthalmological anomalies have also been frequently observed.

Although the deletions can be detected by high resolution cytogenetic studies, confirmation by fluorescence in situ hybridisation is required in most cases. The majority of deletions are maternally derived. Molecular characterisation of 1p36 deletions has been undertaken in several cases, and it is likely that this condition is a contiguous gene deletion syndrome.

(J Med Genet 1999;36:657-663)

Keywords: monosomy 1p36; contiguous gene deletion syndrome

Table 1 Reported cases with monosomy for chromosome band 1p36

Reference	Case	Age*	Age†	Presenting feature(s)	Karyotype	Survival
Magenis <i>et al</i> ¹	1	Newborn		Multiple congenital anomalies	del(1)(p36.13)	
Wargowski <i>et al</i> ²	1-4				del(1)(p36)	
Wexler <i>et al</i> ³	1	3 y 7 mth		Dysmorphism; seizures; microcephaly	46,XX,del(1)(p36.3)	Alive
	2	10 mth		Hypotonia; nystagmus; shawl scrotum	46,XY,del(1)(p36.31)	Alive
Kepler-Noreuil <i>et al</i> ⁴	1	3 wk	2 y	Congestive cardiac failure	46,XX,del(1)(p36.22)	Alive
	2	Newborn	8 mth	IUGR; dysmorphism	46,XX,del(1)(p36.22)	Alive
	3	12 mth	20 mth	Neonatal seizures; developmental delay	46,XX,del(1)(p36.22)	Alive
Reish <i>et al</i> ⁵	3	47 y		Developmental delay; seizures	46,XX,del(1)(p36.32)	Alive
Sandlin <i>et al</i> ⁶	1				del(1)(p36.2)	
	2				del(1)(p36.3)	
	3				del(1)(p36.3)	
Giraudeau <i>et al</i> ⁸	1	16 y		Dysmorphism; seizures; scoliosis; MR	46,XY,del(1)(p36.3)	Alive
Shapira <i>et al</i> ⁷	1	11 y 3 mth	15 y 4 mth	Developmental delay; dysmorphism	46,XY,del(1)(p36.22)	Alive
	2	10 y 9 mth	13 y 6 mth	Developmental delay; dysmorphism	46,XX,del(1)(p36.2)	Alive
	3	4 y 10 mth	12 y 11 mth	Developmental delay; dysmorphism	46,XY,del(1)(p36.2)	Alive
	4	5 y 11 mth	9 y 4 mth	Possible Prader-Willi syndrome	46,XX,del(1)(p36.31)	Alive
	5	2 y 9 mth	6 y 2 mth	Seizures; developmental delay	46,XY,del(1)(p36.23)	Alive
	6	2 y 9 mth	4 y 8 mth	Developmental delay; growth delay	46,XX,del(1)(p36.2)	Alive
	7	2 y 2 mth	4 y 1 mth	Developmental delay	46,XY,del(1)(p36.2)	Alive
	8	Prenatal (21 wk)	1 y 5 mth	Abnormal maternal serum AFP	46,XX,del(1)(p36.22)	Alive
	9	2 wk	1 y 3 mth	Seizures	46,XX,del(1)(p36.2)	Alive
	10	4 d	1 y 2 mth	Dysmorphism	46,XY,del(1)(p36.2)	Alive
	11	10 y 1 mth	11 y 1 mth	Developmental delay; dysmorphism	46,XX,del(1)(p36.22)	Alive
	12	4 d	11 mth	Multiple congenital anomalies	46,XY,del(1)(p36.2)	Alive
	14	6 mth	1 y 5 mth	Multiple congenital anomalies	46,XX,del(1)(p36.2)	Alive
Slavotinek <i>et al</i> ¹⁰	1	Newborn	6 y	Dysmorphism; congenital anomalies	46,XX,del(1)(p36.2)	Alive
Riegel <i>et al</i> ¹¹	1	Newborn	4 y	Hypotonia; developmental delay	46,XX,del(1)(p36.3)	Alive
Faivre <i>et al</i> ¹²	1	Prenatal (24 wk)	Prenatal (28 wk)	Abnormal antenatal scan	46,XY,del(1)(p36)	D prenatal (28 wk)
Eugster <i>et al</i> ¹³	1	4.5 y		Hyperphagia; obesity	mos46,XX,del(1)(p36.33)	Alive
Howard and Porteous ¹⁴	1	Newborn	2 mth	Dysmorphism; congenital heart disease	46,XY,del(1)(p34.1p36.1)	D 2 mth
Biegel <i>et al</i> ¹⁵	1	Newborn	5 mth	Developmental delay; dysmorphism	46,XX,del(1)(p36.1-p36.2)	Alive
Hain <i>et al</i> ¹⁶	1	Newborn	Newborn	Dysmorphism	45,XX,-1,-15,+der(1)(1;15)(p36;q11)	D 6 d
	2	Newborn	Newborn	Dysmorphism	45,XY,-1,-15,+der(1)(1;15)(p36;q11)	D 2 d
Yunis <i>et al</i> ¹⁷	1	4 y	4 y	Developmental delay	45,XX,ter rea (1;21)(p36;q13)	Alive
Barbi <i>et al</i> ¹⁸	1	Newborn	15 mth	Hypotonia; minor anomalies	46,XX,-1,+der(1)t(1;15)(p36;p11.2)	Alive
Blennow <i>et al</i> ¹⁹	1	10 mth	3.5 y	Seizures	46,XX,-1,+der(1)t(1;15)(p36.31-33;p11.2-12)	Alive

Age* = age at diagnosis.

Age† = age at time of reporting.

IUGR = intrauterine growth retardation; MR = mental retardation; AFP = alphafetoprotein; D = dead.

Two of the most important aims behind the characterisation of a “chromosomal syndrome” are to aid recognition of the phenotype and to document developmental progress. Until recently, there were few published reports of patients with “pure” monosomy for terminal chromosome 1p36. We provide a review of the published cases with 1p36 deletions and with interstitial deletions involving 1p36, in order to assist geneticists and other health professionals with the identification of patients and counselling of families with this chromosome abnormality.

Reported cases

Published cases of 39 patients with pure 1p36 monosomy are listed in table 1 together with karyotype, age at presentation, and reason for presentation.¹⁻¹⁹ One case with mosaicism for monosomy 1p36 has been included.¹³ Five patients with monosomy 1p36.31-33 arising from unbalanced segregants have also been included in table 1, as the phenotypic effects from the derivative chromosome 1 can be attributed mainly to 1p monosomy.¹⁶⁻¹⁹ The dysmorphic features and malformations associated with pure 1p36 monosomy are summarised in table 2 and discussed in the text. The incidence of dysmorphic features and malformations has not been given as a percentage because of differences in the completeness of the case reports. The deletion size of 17

additional patients has been reported, but because their clinical features were not listed, they are not included in this review.²⁰ Photographs of a collection of typical patients with 1p36 monosomy are shown in fig 1. Cases with terminal 1p36 monosomy reported only in abstracts,^{1-3 5 7} two patients with interstitial deletions,^{14 15} and six patients with 1p monosomy resulting from the segregation of translocations,^{9 16-19} who have possible additional chromosome imbalance, have been excluded from table 2.

Aetiology and genetics

The incidence of de novo monosomy for 1p36 has been estimated at 1/10 000 newborns.⁹ Underascertainment in the past has been attributed to difficulty in the detection of deletions involving the pale staining end of the chromosome with G banding.

The sex of the “deleted” patient was published in 35 cases; 13 males and 22 females have been reported (table 1). Several cases have been found at amniocentesis.^{12 21} Interestingly, in a retrospective analysis of 30 patients, five out of eight mothers who underwent prenatal serum screening during pregnancy had raised levels of maternal serum alpha-fetoprotein.²¹ The age at diagnosis in the remaining patients has ranged from the newborn period to 47 years of age. Thirteen patients presented in the newborn period or first month of life and all

Table 2 Clinical features of reported cases with monosomy for chromosome 1p36

	Reish et al ⁶ (case 3)	Keppeler-Noreuil et al ¹ (cases 1-3)	Giraudeau et al ⁸	Shapira et al ⁹ (cases 1-12, 14)	Riegel et al ¹¹
Birth					
Gestation		41 wk; 35 wk; 39 wk	Term		41 wk
Birthweight		<10th; 10th; 30th	2490 g (10th)		2650 g (<3rd)
OFC at birth		90th (3rd case)	33 cm (25th)		
Age at assessment	47 y	2 y; 18 mth; 20 mth	16 y		3 y 9 mth
Growth					
Height		<5th; <5th; 75th			98 cm (10th)
Weight	36.2 kg (<5th)	<5th; <5th; 75th			15 kg (10-25th)
OFC	51.3 cm (-2 SD)	10th; 10th-25th; 5th	49.5 cm (<<3rd)		47 cm (-2.1 SD)
Facies					
Brachycephaly		+ (1/3)		+ (5/13)	
Large anterior fontanelle		+ (3/3)	+	+ (8/8)	
Frontal bossing		+ (1/3)			
Broad/long forehead	+		+		+
Facial/ear asymmetry		+ (1/3)	+	+ (7/13)	+
Eyes					
Deep set eyes	+			+ (6/13)	
Almond shaped eyes					
Hypertelorism		+ (1/3)		+ (2/13)	
Epicanthic folds		+ (1/3)			+
Small/short fissures		+ (2/3)		+ (3/13)	
Slanting fissures	+	+ (1/3)		+ (6/13); (4/13)	+
Nose					
Flat nasal bridge		+ (1/3)		+ (9/13)	
Flat/hypoplastic midface	+	+ (1/3)	+		
Ears					
Dysplastic helices	+		+	+ (3/13)*	
Small ears	+	+ (1/3)		+ (4/13)	
Low set ears	+	+ (3/3)		+ (6/13)	
Auricular pit		+ (1/3)			
Mouth and chin					
Down turned mouth	+				+
Small mouth		+ (2/3)	+		+
Prominent/pointed chin	+			+ (10/13)†	
Digits					
Brachydactyly	+		+		+
Tapering fingers		+ (1/3)			
Fifth finger clinodactyly		+ (1/3)		+ (8/13)	
Syndactyly			+		
Small hands and feet	+			+ (1/13)	+

*Thick helices were noted in 7/13.⁹

†Prognathism was noted in 3/8.⁹

but five patients were younger than 10 years of age at diagnosis. The most common reasons for chromosome analysis were developmental delay, dysmorphism, seizures, and the investigation of multiple congenital anomalies, although one child was karyotyped because of congestive cardiac failure in the newborn period⁴ and two others were referred with possible Prader-Willi syndrome.^{9, 13} Survival to adult life has been described⁶ and all but four children were alive at the time of reporting (table 1).

The breakpoints of the deletions have ranged from 1p36.13 to 1p36.33 with the majority occurring in band 1p36.2 (table 1). Successful detection has been accomplished by high resolution G banding.^{13, 14} One study detected two deletions by analysis at the 850-1000 band level³ and another used a 600-800 band level.⁹ In most cases the deletions were confirmed with FISH using probe D1Z2^{1, 6, 7, 10, 11, 13, 18, 19, 23} or using both probe D1Z2 and probe p58.^{9, 20} Both FISH probes should be used to confirm the diagnosis, since some patients have been described who have been deleted for only one of these two probes.^{9, 20} Three deletions were ascertained during screening studies for submicroscopic chromosome deletions on panels of children with idiopathic mental retardation.^{8, 10, 11} These findings lend support to the high estimated occurrence of this deletion syndrome.⁹

Table 2 Continued

<i>Slavotinek et al</i> ¹⁰	<i>Eugster et al</i> ³	<i>Favore et al</i> ¹²
38 wk 1900 g (<3rd) 31.5 cm (<3rd) 6 y	38 wk 2780 g	Termination 28 wk
94.5 cm (<<3rd) 9.6 kg (<<3rd) 45 cm (<<3rd)	102 cm 25 kg	Prenatal
+		+
+		
+	+	
+	+	
+		
+	+	+
+	+	+
+	+	
+	+	
+	+	
+	+	
+	+	

In the largest study of “pure” monosomy 1p36, 21 out of 27 de novo deletions were maternally derived.²⁰ The deletions ranged in size from the “minimal” deletion interval (includes marker D1S243 and probe p58) to the largest deletion, with a proximal breakpoint near marker D1S2736.²⁰ Three other cases have also been characterised molecularly and have shown breakpoints within this range.^{8, 10, 11} Thus the breakpoints are highly variable within 1p36. Molecular characterisation of deletions, along with phenotypic correlations, have yielded regions in which to search for genes for specific features of the syndrome which has resulted in the conclusion that the 1p36 deletion syndrome is likely to be a contiguous gene deletion syndrome.^{20, 22}

Clinical features

DEVELOPMENT

Developmental delay is almost invariable, although the small number of older children and adults with pure 1p36 monosomy reported has prevented a comprehensive assessment of adult potential. Four out of six children in whom IQ could be assessed scored <60 with speech more severely affected than motor development.⁹ One patient with an IQ <20 was unable to walk unassisted in her forties.⁶ Development was also described as severely delayed in five out of six patients in one study,⁷ in a 12 month old girl,¹⁸ in a 4 year old girl,¹⁷ and in a 16 year old boy.⁸ One girl was unable to sit independently at the age of 6 years¹⁰ and two others had no language acquisition at over 4 years of age.^{11, 13} In contrast, three patients with the smallest documented deletions had complex speech abilities and mild mental retardation.^{20, 24} However, it seems reasonable to conclude that intellect is severely compromised in the majority of patients.

GROWTH

Postnatal growth retardation was found in eight out of eight patients and microcephaly in four out of nine children in one patient group.⁹ In these patients, measurements at birth were normal, but reduced growth was detected during or after the first year of life.⁹ Pre- and postnatal growth retardation, with or without microcephaly, has also been noted in a number of other cases.^{1-4, 6, 8, 10, 11, 15-17, 19} Growth retardation in 1p monosomy can be severe¹⁰ and it is interesting that several patients with ring 1 chromosomes have also had extremely short stature.²⁵⁻²⁸

Paradoxically, children with obesity and hyperphagia resembling Prader-Willi syndrome have also been reported with terminal 1p deletions.^{2, 4, 7, 9, 13} This observation led to the characterisation of two separate phenotypes for 1p36 monosomy.^{2, 4, 7} However, it has since been recognised that the division of patients with 1p36 deletions into two groups on the basis of growth parameters is unhelpful in predicting other clinical features.⁹ The differences in growth were previously suggested to arise from variations in deletion size or imprinting,⁴ but no evidence of a correlation between

growth parameters and deletion size or parental origin of the deletion has subsequently been found.⁹

Early puberty has been described in two female children, although their ultimate adult heights are predicted to be short.⁹ Conversely, one boy with microcephaly had small genitalia and no signs of puberty at 16 years of age⁶ and the only reported adult female patient had growth retardation, small breasts, and sparse axillary and pubic hair.⁶

DYSMORPHISM

The most common dysmorphic features included a large anterior fontanelle,^{2 4 8-10 19} prominent forehead (also described as bossed or broad/long),^{4 6 10 11 18 19} deep set eyes,^{6 9 13 17 19} and short, narrow, or slanting palpebral fissures.^{1 2 4 6 9-11} A flat nasal bridge^{2 4 9 15 17} and midface hypoplasia^{6 8 13} were also frequent. Other facial features were dysplastic ears or small, low set ears,^{1 2 4 6 9 10 12 13 16-19} a small mouth,^{4 8 11 13 19} or a mouth with downturned

corners,^{6 11 13 19} and a pointed or prominent chin.^{6 9 10} Several children have had a long philtrum.^{10 11} Minor digital anomalies such as short fifth fingers or fifth finger clinodactyly,^{2 4 9 17} camptodactyly,^{11 17} and small hands and feet^{9 11 13} were noted in some patients. Facial asymmetry^{4 8 10 11} and asymmetrical ears^{9 11} were common.

Orofacial clefting has been described in 10-40% of patients with 1p36 monosomy.^{2 4 9} In addition to reports of cleft lip/palate^{2 4 7 9 10 17 18} there are reports of one patient with a submucous cleft,³ five patients with a high arched palate,^{6 12-15} one boy with a flat, ridged palate,⁸ and a girl with prominent lateral palatine ridges.¹¹ Examples of the facial appearance of a child with 1p monosomy, cleft lip, and cleft palate are shown in fig 2.

CARDIOVASCULAR SYSTEM

Four children have had infantile dilated cardiomyopathy and one of the four, who also had a patent ductus, had a degree of left ventricular failure greater than expected from the cardiac malformation.^{4 9} In two of these cases, the cardiomyopathies resolved by 9 months and 2 years of age,⁴ and the cardiomyopathy was improving in the other two patients who have been on treatment with digoxin. Another child with a moderate sized atrial septal defect, tricuspid incompetence, and a small patent ductus arteriosus had left ventricular failure requiring medication for the first six months of life.¹⁰ Cardiac abnormalities were found in nine other patients and included tetralogy of Fallot,¹ a small ventricular septal defect,¹⁵ infundibular stenosis of the right ventricle,¹⁷ a patent ductus arteriosus,^{9 16} mild left pulmonary artery branch stenosis,⁹ and Ebstein anomaly with a patent ductus arteriosus.^{11 12} One case with an interstitial deletion of 1p36 had pulmonary atresia and a ventricular septal defect.¹⁴

CENTRAL NERVOUS SYSTEM

Hypotonia has been consistently documented, and in most cases was noted at birth.^{2-4 7 9-11 13 15 17-19} Epilepsy has also been found in the majority of children^{2-4 6 8-11 19} and myoclonic seizures,^{4 9} generalised tonic-clonic seizures,^{11 19} right sided focal fits,⁸ simple and complex partial seizures,⁹ and infantile spasms⁹ have been described. In some children, seizures started in infancy and ceased in the first few years of life,^{3 9} whereas others have had persistent convulsions requiring long term medication.^{3 6 8-11 19} EEG abnormalities may be absent in children with transient seizures.⁹ A hemispherectomy was performed in one child for management of seizures.³

Cranial imaging has documented cerebral atrophy, ventricular asymmetry, and ventricular enlargement.^{9-12 16 17} Hydrocephalus has occurred in two children.^{4 18} One report found hyperreflexia to be a common finding.² Disturbed behaviour has been described in some cases, including temper outbursts, banging or throwing objects, striking people, screaming episodes, and self-injurious behaviour (wrist bit-

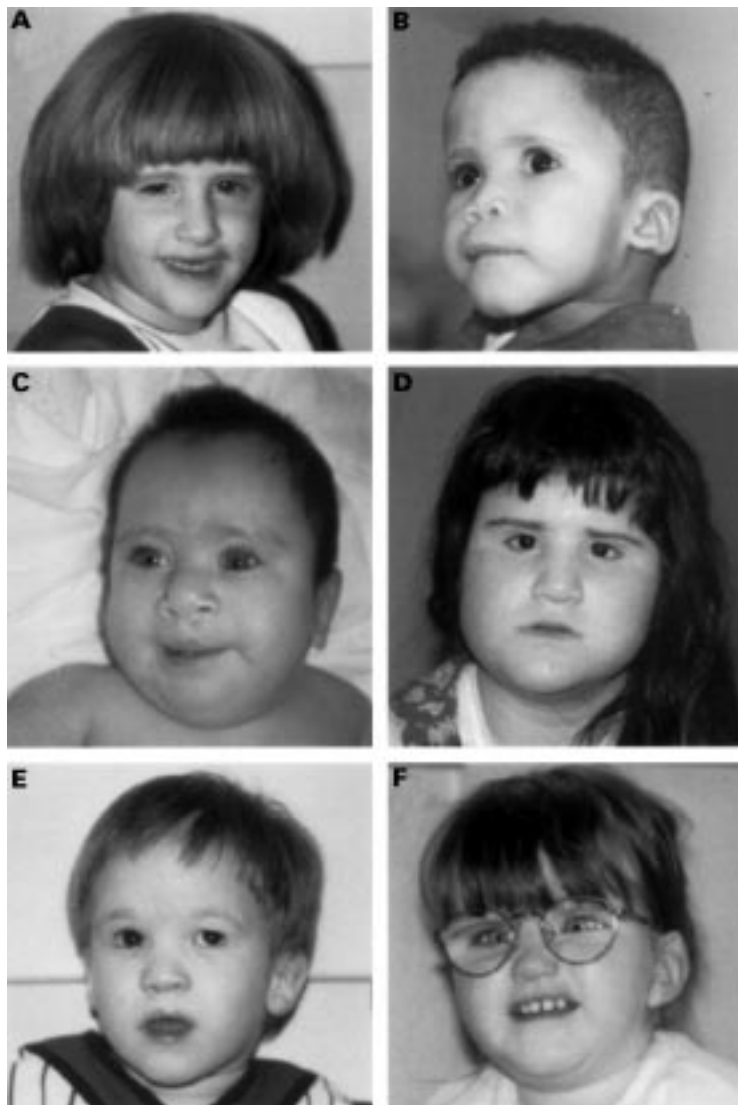

Figure 1 Six children with 1p36 deletions, whose deletion sizes have been characterised.²⁰ The patient numbers correspond to patient assignments reported in Wu et al.²⁰ (A) Patient 6 at 5 years of age. (B) Patient 10 at 19 months of age. (C) Patient 12 at 13 months of age. (D) Patient 15 at 9 years of age. (E) Patient 23 at 31 months of age. (F) Patient 28 at 24 months of age. (All photographs reproduced with permission.)

ing, head striking).^{6,9,13} Autistic behaviour has also been noted.^{3,9,19}

OPHTHALMOLOGICAL AND AUDITORY SYSTEMS

In one study, visual abnormalities were found in six out of eight patients and consisted of strabismus, sixth nerve palsy, amblyopia, refractive errors, anomalous optic discs, and lacrimal defects.⁹ Bilateral cataracts,⁶ iris colobomas,⁴ and moderate bilateral optic atrophy or pale optic discs^{8,18} have also been

described. Rotatory nystagmus was found in three children^{3,8,18} and several others have had strabismus.^{4,10,13,18} Reduced visual acuity or refractive errors have been confirmed in other patients.^{10,15,19}

Sensorineural or conductive hearing loss have been reported to be quite frequent. In the largest study,²⁹ 8/18 patients had bilateral high frequency sensorineural hearing loss (HFS-NHL), 2/18 patients had severe conductive hearing loss, and 1/18 had mild HFSNHL, but

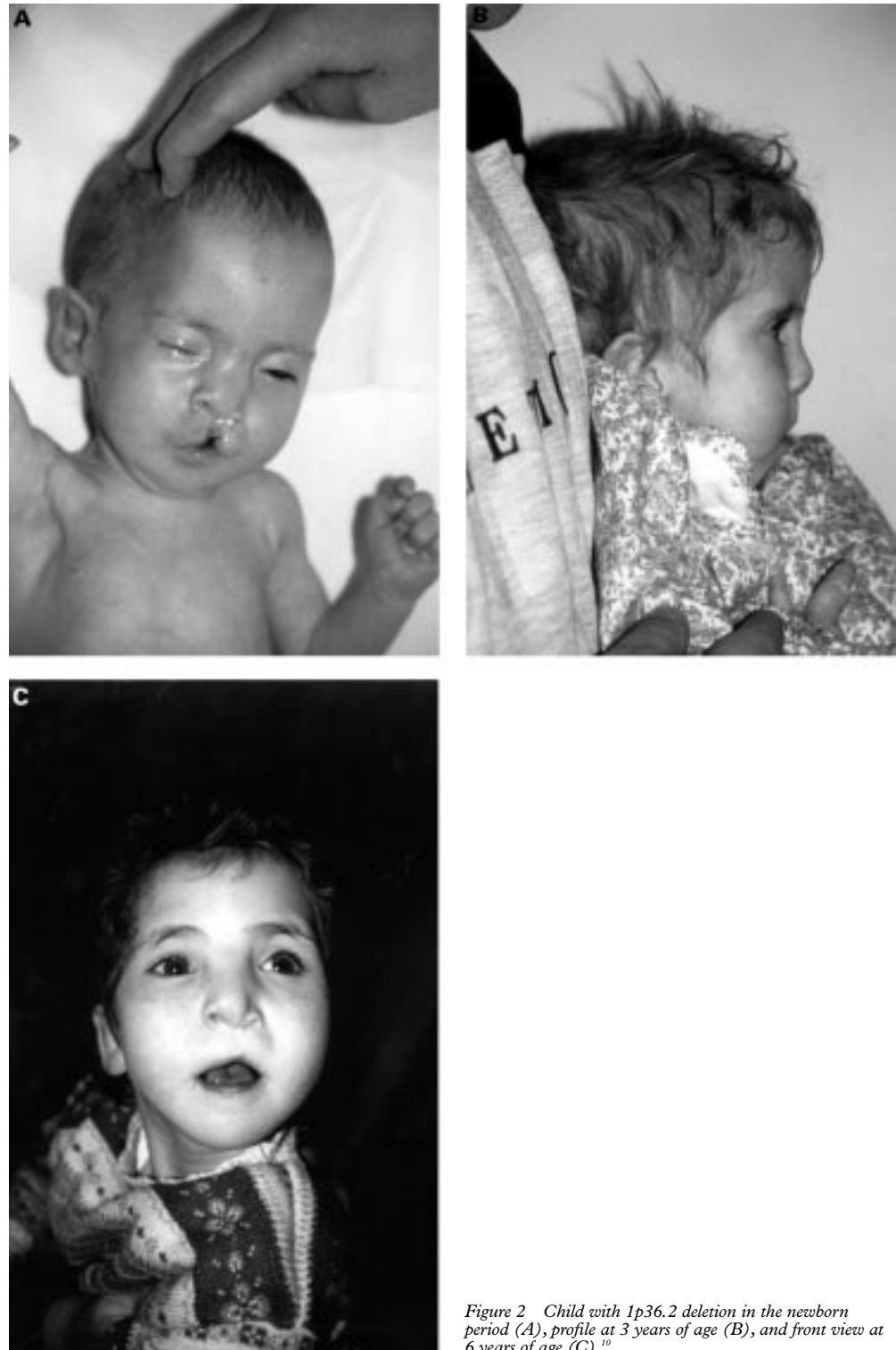


Figure 2 Child with 1p36.2 deletion in the newborn period (A), profile at 3 years of age (B), and front view at 6 years of age (C).¹⁰

had PE tubes in place at the time of the study. Other cases of hearing impairment have also been reported.^{6 10 13 18 19}

MUSCULOSKELETAL SYSTEM

Kyphoscoliosis has been described in two cases and surgery was necessary in one child.^{6 8} A thoracic kyphosis secondary to muscular hypotonia and mild scoliosis has been mentioned in other reports.^{10 11 16} Contractures of the fingers and hips,¹ dysplasia of the hip joints,¹⁸ metatarsus adductus,² and two patients with 11 pairs of ribs^{10 12} and a bifid rib¹⁰ have also been noted. Mild hemihypertrophy was found in one child.⁴

GENITOURINARY SYSTEM

Cryptorchidism has been found in two patients^{9 15} and shawl scrotum,³ small genitalia,⁸ scrotal hypoplasia,⁹ and dilatation of the renal collecting systems¹⁰ have each been described in individual cases. No structural renal anomalies have been noted.

OTHER FEATURES

Anomalous findings reported in only one case were imperforate anus with rectovaginal fistula,¹ abnormal pulmonary lobulation,¹⁹ congenital spinal stenosis,⁶ polydactyly,⁴ and Sturge-Weber syndrome.³ One child with an interstitial deletion had a hairy skin patch¹⁴ and another had a telangiectatic skin lesion on her mid forehead and hyperpigmented macules.⁴

Monosomy 1p with additional chromosome imbalance

There are at least 10 reports of monosomy 1p and additional chromosome material arising from either unbalanced segregation of a chromosome translocation or as a de novo sporadic event.^{6 9 30-37} Because the additional chromosomal imbalance may be subtle, chromosome or FISH analyses should be performed on the parents of all 1p36 deletion syndrome patients. In the largest review,²⁰ 1 in 30 patients arose from unbalanced segregation of a parental balanced translocation. These reports of the clinical features in cases with double segment imbalance strengthen the association of malformations with 1p36 monosomy, although a contributory role from the additional chromosome imbalance cannot be excluded.

Cardiomegaly was observed in a patient with monosomy for 1p36-1pter and trisomy for 9p12-9pter.³⁰ An infant with monosomy for 1p36.2-1pter had atrial and ventricular septal defects, seizures, and cerebral ventriculomegaly, although this child also had a duplication of 4q31.2-4qter.³⁴ An infant and a 20 week old fetus with monosomy 1p36 and trisomy for the distal long arm of chromosome 20 were described with congenital heart disease (tetralogy of Fallot, truncus arteriosus, and ventricular septal defect), ophthalmological abnormalities (microphthalmia, optic nerve colobomas, foveal hypoplasia), and hydrocephalus.³⁵

Two patients with monosomy for 1p36.31-1pter and trisomy for 19q13.42-19qter had seizures and one had optic atrophy, deafness, and strabismus.⁶ A man with seizures and a marked scoliosis had a translocation of Y chro-

mosome material to chromosome 1 resulting in monosomy for 1p36.³³ Megacystis with early urethral obstruction was found in a 15 week fetus with monosomy for 1p36-1pter and a duplication of terminal 10p.³⁶

Terminal deletions involving 1p36 and extending proximally to 1p35,³⁸ 1p34,³⁹ or 1p33⁴⁰ have not been included in this review because of the difficulty in attributing clinical features specifically to band 1p36. However, it is interesting that one 9 year old child with a deletion of 1p35 was karyotyped for suspected Prader-Willi syndrome.³⁸

Monosomy 1p and tumours of neural crest origin

There is strong evidence that one or more tumour suppressor genes map to 1p36.1-1p36.3 and are involved in the development of neuroblastoma and other tumours of neural crest origin.⁴¹⁻⁴⁴ Loss of heterozygosity studies and microsatellite markers have been used to map the critical region for a neuroblastoma tumour suppressor gene to between D1S244 and D1S214.^{45 46} One child with an interstitial deletion of 1p36 was diagnosed with neuroblastoma at the age of 5 months¹⁵ and two other children who had balanced translocations with breakpoints at 1p36 have also developed neuroblastomas.^{47 48} In the largest study reported, no child with 1p36 monosomy (ages 6 months to 17 years) has as yet developed this type of tumour.²⁰ It is possible that imprinting may be important in neuroblastoma formation⁴⁹ since one study showed that 16/17 allelic losses in this type of tumour were maternal in origin.⁵⁰ In a study of 1p36 deletions, the three cases with the largest deletions in which parental origin could be determined had segmental aneusomy caused by a paternal deletion.²⁰ If the tumour suppressor locus was proximally located within the deleted region of these patients, then the absence of neuroblastomas may be explained by the loss of the paternal, rather than the maternal allele.²⁰ However, if the gene maps more distally in 1p36, then the finding of both maternally and paternally derived deletions in the patients fails to support a role for imprinting in neuroblastomas.²⁰

Conclusion

We have reviewed 39 patients with "pure" 1p monosomy from medical publications in order to characterise the phenotype associated with this chromosomal syndrome. Terminal 1p deletions result in developmental delay (usually severe), abnormalities of growth (including growth retardation, microcephaly, or obesity similar to Prader-Willi syndrome), and dysmorphism with a large anterior fontanelle, prominent forehead, deep set eyes, flat nasal bridge and midface hypoplasia, ear asymmetry in shape or positioning, a pointed chin, and fifth finger clinodactyly/shortening. Minor cardiac malformations/cardiomyopathy, minor cerebral abnormalities, hypotonia, seizures, sensorineural hearing loss, and ophthalmological anomalies have been among the most frequently observed additional findings.

The variable nature of features that occur in patients with monosomy 1p36 necessitates monitoring for all the major complications. Medical management should include an echocardiogram, a hearing evaluation by brain-stem evoked response testing, an ophthalmological evaluation, as well as the involvement of neurologists, cardiologists, nutritionists, otolaryngologists, cleft lip/palate specialists, speech pathologists, and physical and occupational therapists, to deal with the more common manifestations of this syndrome. A determination of the extent of the deletion at the molecular level can also yield important prognostic information. Prognosis and management decisions will also be augmented by future identification of candidate genes that, when deleted, result in the various phenotypic aspects of the syndrome.

We are most grateful to Professor Schinzel for kindly supplying details of his patient and to Dr Jill Clayton-Smith for reading the manuscript.

- 1 Magenis RE, Sheehy R, Lacey D, Brown MG, Litt M. Small terminal deletion of chromosome 1 short arm in an infant with multiple anomalies: confirmation by in situ hybridization of probe p1-79. *Am J Hum Genet Suppl* 1987;41:A130.
- 2 Wargowski D, Sekhon G, Laxova R, Thompson K, Kent C. Terminal deletions of band 1p36: emergence of two overlapping phenotypes. *Am J Hum Genet Suppl* 1991;49:278.
- 3 Wexler P, Gilfillan T, McGavran L, Sujansky E. Deletions (1)(p36.3) and the potential role of high resolution chromosome analysis. *Am J Hum Genet Suppl* 1991;49:278.
- 4 Keppeler-Noreuil KM, Carroll AJ, Finley WH, Rutledge SL. Chromosome 1p terminal deletion: report of new findings and confirmation of two characteristic phenotypes. *J Med Genet* 1995;32:619-22.
- 5 Reish O, Berry SA, King RA, Hirsch B. Partial monosomy of chromosome 1p36.3: a distinctive phenotype. *Am J Hum Genet Suppl* 1994;55:A116.
- 6 Reish O, Berry SA, Hirsch B. Partial monosomy of chromosome 1p36.3: characterization of the critical region and delineation of a syndrome. *Am J Med Genet* 1995;59:467-75.
- 7 Sandlin CJ, Dodd BS, Dumars KW, et al. Phenotypes associated with terminal deletion of the short arm of chromosome 1. *Am J Hum Genet Suppl* 1995;57:A125.
- 8 Giraudeau F, Aubert D, Young I, et al. Molecular-cytogenetic detection of a deletion of 1p36.3. *J Med Genet* 1997;34:314-17.
- 9 Shapira SK, McCaskill C, Northrup H, et al. Chromosome 1p36 deletions: the clinical phenotype and molecular characterization of a common newly delineated syndrome. *Am J Hum Genet* 1997;61:642-50.
- 10 Slavotinek A, Rosenberg M, Knight S, et al. Screening for submicroscopic chromosome rearrangements in children with idiopathic mental retardation using microsatellite markers for the chromosome telomeres. *J Med Genet* 1999;36:405-11.
- 11 Riegel M, Castellani C, Balmer D, Brecevic L, Schinzel A. Terminal deletion, del(1)(p36.3), detected through screening for terminal deletions in patients with unclassified malformation syndromes. *Am J Med Genet* 1999;82:249-53.
- 12 Faivre L, Morichon-Delvallez N, Viot G, et al. Prenatal detection of a 1p36 deletion in a fetus with multiple malformations and a review of the literature. *Prenat Diagn* 1999;19:49-53.
- 13 Eugster EA, Berry SA, Hirsch B. Mosaicism for deletion 1p36.33 in a patient with obesity and hyperphagia. *Am J Med Genet* 1997;70:409-12.
- 14 Howard PJ, Porteus M. Deletion of chromosome 1p: a short review. *Clin Genet* 1990;37:127-31.
- 15 Biegel JA, White PS, Marshall HN, et al. Constitutional 1p36 deletion in a child with neuroblastoma. *Am J Hum Genet* 1993;52:176-82.
- 16 Hain D, Leversha M, Campbell N, et al. The ascertainment and implications of an unbalanced translocation in the neonate. Familial 1:15 translocation. *Aust Paediatr J* 1980;16:196-200.
- 17 Yunis E, Quintero L, Leibovici M. Monosomy 1pter. *Hum Genet* 1981;56:279-82.
- 18 Barbi G, Kennerknecht I, Klett C. Reciprocal translocation t(1;15)(p36.2;p11.2): confirmation of a suggestive cytogenetic diagnosis by in situ hybridization and clinical case report on resulting monosomy (1p). *Am J Med Genet* 1992;43:722-5.
- 19 Blennow E, Bui TH, Wallin A, Kogner P. Monosomy 1p36.31-33→pter due to a paternal reciprocal translocation: prognostic significance of FISH analysis. *Am J Med Genet* 1996;65:60-7.
- 20 Wu YQ, Heilstedt HA, Bedell JA, et al. Molecular refinement of the 1p36 deletion syndrome reveals size diversity and a preponderance of maternally derived deletions. *Hum Mol Genet* 1999;8:313-21.
- 21 Enciso VB, Robbins-Furman P, Agan NR, et al. Chromosome deletions of 1p36 associated with prenatal elevations of maternal serum AFP. *Am J Hum Genet Suppl* 1998;63:A162.
- 22 Shapira SK, Wu YQ, Heilstedt HA, et al. Chromosome 1p36 deletion syndrome: new clinical findings and phenotype-genotype correlations. *Am J Hum Genet Suppl* 1998;63:A33.
- 23 Buroker N, Bestwick R, Haight G, Magenis RE, Litt M. A hypervariable repeated sequence on human chromosome 1p36. *Hum Genet* 1987;77:175-81.
- 24 McPherson JD, Bedell JA, Wu YQ, et al. Contig assembly and candidate gene identification in the complex expressive language and cognitive processing critical region on 1p36. *Am J Hum Genet Suppl* 1998;63:A254.
- 25 Gordon RR, Cooke P. Ring-1 chromosome and microcephalic dwarfism. *Lancet* 1964;ii:1212-13.
- 26 Wolf CB, Petersen JA, LoGrippe GA, Weiss L. Ring 1 chromosome and dwarfism - a possible syndrome. *J Pediatr* 1967;71:719-22.
- 27 Bobrow M, Emerson PM, Spriggs AI, Ellis HL. Ring-1 chromosome, microcephalic dwarfism, and acute myeloid leukemia. *Am J Dis Child* 1973;126:257-60.
- 28 Kjessler B, Gustavson KH, Wigertz A. Apparently non-deleted ring-1 chromosome and extreme growth failure in a mentally retarded girl. *Clin Genet* 1978;14:8-15.
- 29 Heilstedt HA, Wu YQ, May K, et al. Bilateral high frequency hearing loss is commonly found in patients with the 1p36 deletion syndrome. *Am J Hum Genet Suppl* 1998;63:A106.
- 30 Desangles F, Mourrieras P, Papouin-Rauzy M, Saliou P. Monosomie 1pter par translocation familiale (1p;9p). *Ann Genet* 1983;26:53-5.
- 31 Steele MW, Wenger SL, Geweke LO, Golden WL. The level of 6-phosphogluconate dehydrogenase (6-PGD) activity in a patient with a terminal 1p deletion suggests that the gene locus is not distal to sub-band p36.3 on chromosome 1. *Clin Genet* 1984;25:59-62.
- 32 Lamb J, Wilkie AO, Harris PC, et al. Detection of breakpoints in submicroscopic chromosomal translocation, illustrating an important mechanism for genetic disease. *Lancet* 1989;ii:819-24.
- 33 Abbas N, Novelli G, Stella NC, et al. A 45,X male with molecular evidence of a translocation of Y euchromatin onto chromosome 1. *Hum Genet* 1990;86:94-8.
- 34 Legare JM, Sekhon GS, Laxova R. De novo translocation involving chromosomes 1 and 4 resulting in partial duplication of 4q and partial deletion of 1p. *Am J Med Genet* 1994;53:216-21.
- 35 Howard-Peebles PN, Black SH. FISH identification of deletion 1p36 from a half-cryptic maternal translocation. *Am J Med Genet* 1993;52:381.
- 36 Fryns JP, Vandenberghe K, Deschrijver D. Early urethral obstruction sequence and unbalanced translocation with terminal 10p duplication/1p deficiency. *Genet Couns* 1997;8:349-50.
- 37 Chen Z, Grebe TA, Guan XY, et al. Maternal balanced translocation leading to partial duplication of 4q and partial deletion of 1p in a son: cytogenetic and FISH studies using band-specific painting probes generated by chromosome microdissection. *Am J Med Genet* 1997;71:160-6.
- 38 Wenger SL, Steele MW, Becker DJ. Clinical consequences of deletion 1p35. *J Med Genet* 1988;25:263.
- 39 Pálóvá A, Halasová E, Kamenická E, Kádasi L. De novo deletion 1p(34→pter). *Hum Genet* 1985;69:94.
- 40 Gencik A, Gencikova A. Partial 1p monosomy in a physically and mentally retarded boy. *J Genet Hum* 1987;35:309-15.
- 41 Martinsson T, Sjöberg RM, Hallstenson K, et al. Delineation of a critical tumour suppressor region at distal 1p in neuroblastoma tumours. *Eur J Cancer* 1997;33:1997-2001.
- 42 Vargas MP, Zhuang Z, Wang C, et al. Loss of heterozygosity on the short arm of chromosomes 1 and 3 in sporadic pheochromocytoma and extra-adrenal paraganglioma. *Hum Pathol* 1997;28:411-15.
- 43 White PS, Maris JM, Sulman EP, et al. Molecular analysis of the region of distal 1p commonly deleted in neuroblastoma. *Eur J Cancer* 1997;33:1957-61.
- 44 Vortmeyer AO, Merino MJ, Boni R, et al. Genetic changes associated with primary Merkel cell carcinoma. *Am J Clin Pathol* 1998;109:565-70.
- 45 Martinsson T, Sjöberg RM, Hedborg F, Kogner P. Deletion of chromosome 1p loci and microsatellite instability in neuroblastomas analyzed with short-tandem repeat polymorphisms. *Cancer Res* 1995;55:5681-6.
- 46 Cheng NC, Van Roy N, Chan A, et al. Deletion mapping in neuroblastoma cell lines suggests two distinct tumor suppressor genes in the 1p35-36 region, only one of which is associated with N-myc amplification. *Oncogene* 1995;10:291-7.
- 47 Laureys G, Speleman F, Opendakker G, Benoit Y, Leroy J. Constitutional translocation t(1;17)(p36;q12-21) in a patient with neuroblastoma. *Genes Chrom Cancer* 1990;2:252-4.
- 48 Van der Drift P, Chan A, Laureys G, et al. A constitutional balanced 1;17 neuroblastoma translocation. *Eur J Cancer* 1997;33:2136.
- 49 Barlow DP. Gametic imprinting in mammals. *Science* 1995;270:1610-13.
- 50 Caron H, Peter M, van Sluis P, et al. Evidence for two tumour suppressor loci on chromosomal bands 1p35-36 involved in neuroblastoma: one probably imprinted, another associated with N-myc amplification. *Hum Mol Genet* 1995;4:535-9.