

Electronic letter

A family with hereditary port wine stain

EDITOR—Port wine stains (PWS) are common capillary vascular malformations of the dermis, which are present at birth and grow with the person. PWS most commonly affect the head, face, and upper body.¹ Although usually considered to be sporadic lesions, a survey of patients attending for laser treatment of PWS has shown a higher than expected prevalence of lesions in relatives, suggesting a hereditary predisposition to these malformations.²

Families have previously been reported with autosomal dominant inheritance of capillary vascular malformations. In these families, the lesions can be atypical in distribution, with affected subjects having multiple lesions on the trunk and limbs, as well as on the face³⁻⁵ (J Clayton-Smith, 1998, personal communication). In other families, the common median telangiectatic naevus or “stork mark” has been shown to segregate as an autosomal dominant trait.⁶

In this report, we present a family with four subjects affected with classical single PWS. The family pedigree is shown in fig 1, with clinical photographs of the affected subjects in fig 2. I.1 and I.2 were not available to be examined, but neither was reported to have a port wine stain.

II.2 and II.4 are sisters, both daughters of I.1 and I.2. On examination, neither II.2 and II.4 have PWS. Both have mild 5th finger clinodactyly. The husband of II.2 was also examined and does not have a PWS.

III.3 is the son of II.4. He presented with a left facial port wine stain at birth. He had surgical correction of a tracheo-oesophageal fistula as a neonate. He also required an orchidopexy for an undescended left testis. Subsequently his growth and neurodevelopment were normal. On examination he has an extensive PWS affecting the left side of his face, mainly affecting skin over the maxilla and cheek. He also has 5th finger clinodactyly. His PWS failed to respond to argon laser and tunable dye laser therapy. His brother, III.4, was noted to have a large PWS affecting the upper left hand quadrant of his body at birth. This lesion affects the anterior and posterior aspect of the chest as well as the arm and hand, but sparing his face. He also has 5th finger clinodactyly. Tunable dye laser treatment resulted in reduction of

J Med Genet 2000;37 (<http://jmedgenet.com/cgi/content/full/37/8/e12>)

intensity of the PWS. III.5 is the younger sister of these two brothers and has no evidence of PWS on examination.

III.1 is the daughter of II.1 and II.2. She is therefore the first cousin of the two affected brothers. She had a PWS affecting her left cheek, present at birth. This lesion responded to repeated courses of pulsed tunable dye laser therapy. The only other finding on examination was 5th finger clinodactyly. After this family presented to the South-East Scotland Regional Genetics Service, her brother, III.2, was born with a PWS affecting his nose and upper lip.

In this family, the vascular lesions are classical port wine stains affecting one area of the body, clinically indistinguishable from sporadic lesions. The affected subjects are all offspring of two unaffected sisters. This is in contrast to previously reported families with autosomal dominant inheritance, where the lesions are frequently multiple and with atypical distribution. Tracheo-oesophageal fistula and 5th finger clinodactyly have not previously been reported in PWS families.

Several other clinical entities manifest with cutaneous port wine stain. In this family it is impossible to exclude Sturge-Weber syndrome with facial port wine stain and meningeal angiomas with calcification (MIM 185300). This has been reported to occur in a father and son,⁷ although it is usually a sporadic occurrence. None of the affected subjects in our family suffered from seizures or developmental delay. Klippel-Trenaunay-Weber syndrome (MIM 149000) requires the presence of hemihypertrophy and other vascular lesions in association with the port wine stain. These features were not present in our family.

The presence of port wine stain in four members of this family suggests that PWS is being inherited as a monogenic disorder. The pattern of inheritance is consistent with an autosomal dominant trait with reduced penetrance, X linked inheritance, or mitochondrial inheritance. From our pedigree, we cannot exclude X linked inheritance, although one of the affected children is female. Mitochondrial inheritance seems unlikely, as the port wine stains are isolated congenital lesions.

Reduced penetrance may be a random event. Alternatively, there may be imprinting, with a requirement for maternal transmission of a mutation before there is expression of the port wine stain or there may be anticipation. There is preliminary evidence for anticipation in familial cerebral cavernous angioma.⁸ Cerebral cavernous angioma is an autosomal dominant disorder of the cerebral vasculature. A gene for this disorder, *KRIT1*, has recently been identified on chromosome 7. The mutations identified in this gene include premature terminations and frameshift mutations.^{9,10} In our family, a further explanation of the inheritance pattern is that hormonal factors may make expression of a port wine stain more likely in male mutation carriers than females.

The mechanism by which a mutation in a single gene would cause the abnormal capillary plexus of a PWS is uncertain. A second somatic mutation in capillary endothelial cell precursors may be required, in a situation analogous to that of retinoblastoma.¹¹ The mutated endothelial cells derived from this line would then form a dysplastic capillary network. This “two hit” mechanism provides an explanation for a genetic basis to sporadic PWS, but in our family it fails to explain why only the children and not the parents are affected, or why the lesions are single and localised to the upper body.

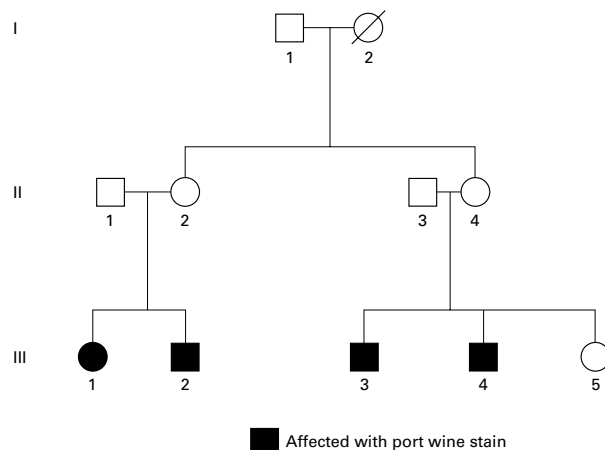


Figure 1 Family pedigree.

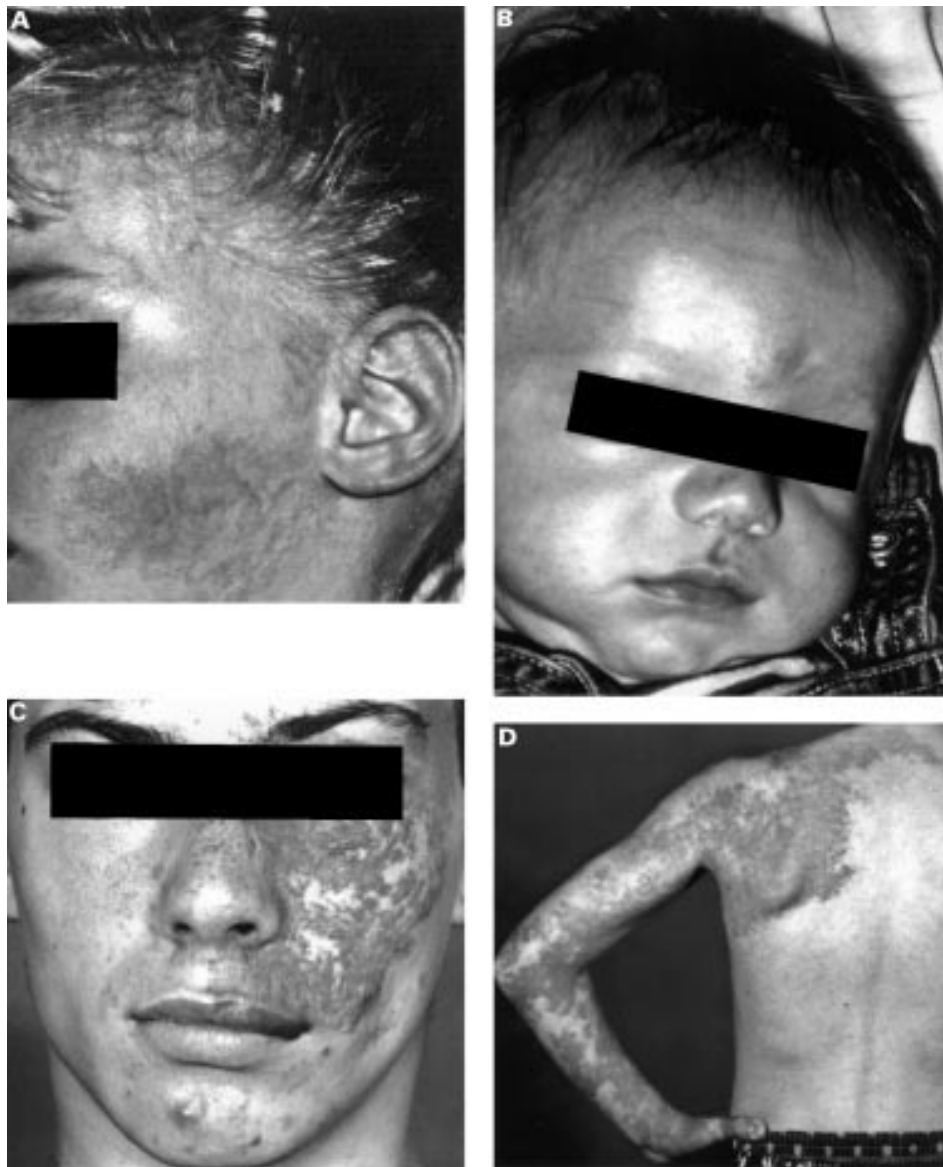

Figure 2 (A) III.1: left facial port wine stain following laser treatment. (B) III.2 with faint port wine stain affecting nose and upper lip. (C) III.3: port wine stain affecting left side of face. (D) III.4: port wine stain affecting upper left quadrant of body.

An alternative explanation would be that the reduced gene product in endothelial cells renders the capillary plexus more susceptible to the environmental influences which may cause sporadic PWS.

The inheritance of PWS in this family provides further evidence for a genetic predisposition to classical port wine stains. Investigation of the genetic factors involved in this common and disfiguring condition may be useful in identifying new approaches to treatment, as well as providing insight into the genetic control of development of the microvasculature.

JONATHAN N BERG*
A A QUABA†
A GEORGANTOPOULOU†
MARY E M PORTEOUS*

*South-East Scotland Regional Genetics Service, Western General Hospital, Edinburgh EH4 2XU, UK

†Department of Plastic Surgery, St John's Hospital, Livingston, UK

Correspondence to: Dr Berg, jberg@hgmp.mrc.ac.uk

1 Fishman SJ, Mulliken JB. Hemangiomas and vascular malformations of infancy and childhood. *Pediatr Clin North Am* 1993;40:1177-200.

- 2 Mills CM, Lanigan SW, Hughes J, Anstey AV. Demographic study of port wine stain patients attending a laser clinic: family history, prevalence of naevus anaemicus and results of prior treatment. *Clin Exp Dermatol* 1997; 22:166-8.
- 3 Redondo P, Vazquez-Doval FJ. Familial "multiple nevi flammei." *J Am Acad Dermatol* 1996;35:769-70.
- 4 Schmid M, Boltshauser E. Familial multiple naevi flammei. *Helv Paediatr Acta* 1989;43:491-2.
- 5 Pasyk KA. Familial multiple lateral telangiectatic nevi (port-wine stains or nevi flammei). *Clin Genet* 1992;41:197-20.
- 6 Pasyk KA, Włodarczyk SR, Jakóbczak MM, Kurek M, Aughton DJ. Familial medial telangiectatic nevus: variant of nevus flammeus - port-wine stain. *Plast Reconstr Surg* 1993;91:1032-41.
- 7 Debicka A, Adamczak P. Przypadek dziedzicznego zespołu Sturge'a-Webera. *Klin Oczna* 1979;81:541-2.
- 8 Siegel AM, Andermann F, Badhwar A, Rouleau GA, Dam M, Hopf HC, Dichgans J, Sturzenegger M, Hopf NJ, Yasui N, Stepper F, Killer M, Van-neste JA, Acciarri N, Drigo P, Christensen J, Braun V, Konu D, Andermann E. Anticipation in familial cavernous angioma: ascertainment bias or genetic cause. *Acta Neurol Scand* 1998;98:372-6.
- 9 Laberge-le Couteulx S, Jung HH, Labauge P, Houtteville JP, Lescoat C, Cecillon M, Marechal E, Joutel A, Bach JF, Tournier-Lasserre E. Truncating mutations in CCM1, encoding KRIT1, cause hereditary cavernous angiomas. *Nat Genet* 1999;23:189-93.
- 10 Sahoo T, Johnson EW, Thomas JW, Kuehl PM, Jones TL, Dokken CG, Touchman JW, Gallione CJ, Lee-Lin SQ, Kosofsky B, Kurth JH, Louis DN, Mettler G, Morrison L, Gil-Nagel A, Rich SS, Zabramski JM, Boguski MS, Green ED, Marchuk DA. Mutations in the gene encoding KRIT1, a Krev-1/rap1a binding protein, cause cerebral cavernous malformations (CCM1). *Hum Mol Genet* 1999;8:2325-33.
- 11 Hansen MF, Cavenee WK. Retinoblastoma and the progression of tumour genetics. *Trends Genet* 1998;4:125-8.