

- 23 Walowsky C, Fitzhugh DJ, Castano IB, Ju JY, Levin NA, Christman MF. The topoisomerase-related function gene TRF4 affects cellular sensitivity to the antitumor agent camptothecin. *J Biol Chem* 1999;274:7302-8.
- 24 Wang Z, Castano IB, De Las Penas A, Adams C, Christman MF. Pol kappa: a DNA polymerase required for sister chromatid cohesion. *Science* 2000;289:774-9.
- 25 Callan DF, Eyre H, Yip MY, Freemantle J, Haan ES. Molecular cytogenetic and clinical studies of 42 patients with marker chromosomes. *Am J Med Genet* 1992;43:709-15.
- 26 Crolla JA, Dennies NR, Earnshaw WC. A non-isotopic in situ hybridization study of the chromosomal origin of 15 supernumerary marker chromosomes in man. *J Med Genet* 1992;29:699-703.
- 27 Depinet TW, Zackowski JL, Earnshaw WC, Kaffe S, Sekhon GS, Stallard R, Sullivan BA, Vance GH, van Dyke DL, Willard HF, Zinn AB, Schwartz S. Characterization of neocentromeres in marker chromosomes lacking detectable alpha satellite DNA. *Hum Mol Genet* 1997;8:1195-204.
- 28 Gravholt CH, Friedrich U. Molecular cytogenetic study of supernumerary marker chromosomes in an unselected group of children. *Am J Med Genet* 1995;56:106-11.
- 29 Barbi G, Kennerknecht I, Wöhr G, Avramopoulos D, Karadima G, Petersen MB. Mirror-symmetric duplicated chromosome 21q with minor proximal deletion, and with neocentromere in a child without the classical Down syndrome phenotype. *Am J Med Genet* 2000;91:116-22.
- 30 Voullaire L, Saffery R, Davies J, Earle E, Kalitsis P, Slater H, Irvine DV, Choo KHA. Trisomy 20p resulting from inverted duplication and neocentromere formation. *Am J Med Genet* 1999;85:403-8.
- 31 Maggert KA, Karpen GH. Acquisition and metastability of centromere identity and function: sequence analysis of a human centromere. *Genome Res* 2000;10:725-8.
- 32 Gimelli G, Zuffardi O, Giglio S, Zeng C, He D. CENP-G in neocentromeres and inactive centromeres. *Chromosoma* 2000;109:328-33.
- 33 Slater HR, Nouri S, E Earle, Lo AWI, Hale LG, Choo KHA. Neocentromere formation in a stable ring 1p32-p36.1 chromosome. *J Med Genet* 1999;36:914-18.
- 34 Barry A, Bateman M, Howman EV, Cancilla MR, Tainton KM, Irvine DV, Saffery R, Choo KHA. The 10q25 neocentromere and its inactive progenitor have identical primary nucleotide sequence: further evidence for epigenetic modification. *Genome Res* 2000;10:832-8.
- 35 Koch J. Neocentromere and alpha satellite: a proposed structural code for functional human centromere. *Hum Mol Genet* 2000;9:149-54.

A case of Roberts syndrome described in 1737

A W Bates

EDITOR—In 1735 Johanna Sophia Schmied, from the village of Taucha near Leipzig, gave birth to a stillborn child with multiple abnormalities, described at the time as a “very rare” monster. The case was reported by a local physician, Gottlieb Friderici, in a tract, *Monstrum humanum rarissimum*, published in Leipzig two years later.¹ Friderici performed a necropsy and published his findings along with a case history of the pregnancy and two detailed plates engraved by a local draughtsman “from life”. The mother was aged 28 years, of short stature and slender, with a “choleric-melancholic” temperament. She had been married to a “hunchback” for 10 years, and they had three other children, all “free of imperfections”; the fourth child is that described by Friderici. “Halfway” though the pregnancy, the fetal movements were felt very faintly and the uterus was not thereafter seen to increase in size, whereas her husband recalled that in the previous pregnancies her belly had grown normally. The baby was stillborn after a labour of seven hours.

A large anterior encephalocele was present. Friderici remarked that, although the appearance resembled hydrocephalus, the protuberance contained cerebral matter. The frontal bone was very abnormal to the bridge of the nose. The nose was “vestigial”, but the nostrils were patent, and a probe inserted into the oral cavity passed through a fissure in the palatal bone. The mouth was “lipless”, the eyes protruded, and the orbits were shallow. A tiny external auditory meatus was found, but the pinnae were absent. The legs, like the forearms, were “simple”, composed of only one bone. There were pterygia in the popliteum (M in fig 1), the groin, and running from the mouth to the upper thorax. The digits of the feet were distorted but all digits were present. The fingernails “resembled those of an animal”.

All ribs were present. In the engraving the thorax appears deformed, though this may be because the illustration was made from the reconstructed body after necropsy. The pleural cavities and pericardium contained “thin fluid”. The liver appeared unusually large and the kidneys were unequal in size. Two small intra-abdominal testes were located. No external genitalia were identified. Quantities of meconium were passed via the anus.

The specimen was brought to Friderici and examined within a few hours of delivery. Fig 1 was printed life sized and was hand coloured. The crown-rump length of the figure is 20 cm and the foot length 4.5 cm; these dimensions correspond to a gestational age of some 24 weeks, compatible with the history, and suggesting that it was drawn in the correct proportions. The head appears microcephalic, though this may be because of the encephalocele. The upper limbs show marked shortening, and were likened by Friderici to the wing of a chicken without the feathers. The combination of anterior encephalocele, microcephaly, shallow orbits, cleft palate, marked micrognathia, hypomelia of the upper limbs, single forearm and leg bones (most probably absence of the radius and fibula, though fusion is possible), and flexion contractures is consistent with a severe lethal form of Roberts-SC phocomelia syndrome (MIM 268300). The inheritance of this condition is autosomal recessive with great variability of expression; the largest review has shown that it is more often sporadic than hereditary.² Consanguinity is not discussed in the account but the physical descriptions of the parents as of short stature and a “hunchback” do not rule out their having had minor dysmorphic features. It is too early in gestation to assess cryptorchidism, and growth retardation cannot be assessed owing to probable intrauterine death

J Med Genet
2001;38:565-567

Department of
Histopathology and
Morbid Anatomy,
Institute of Pathology,
The Royal London
Hospital, London
E1 1BB, UK
A W Bates

Correspondence to:
Dr Bates, awbates@
conwithhouse.fsnet.co.uk

and microcephaly. Encephalocele is an uncommon feature, seen only in severe forms of Roberts syndrome, but the frontal location is typical.³⁻⁵ The presence of pleural and pericardial effusions raises the possibility of a cardiovascular or renal anomaly but there is no description of the anatomy of the heart or kidneys. The gall bladder and spleen were not described.

The differential diagnosis includes Bartsocas-Papas syndrome and acrofacial dysostosis, particularly Nager type. Some features, such as popliteal and other pterygia and absent penis and pinnae, are suggestive of Bartsocas-Papas syndrome, but the encephalocele, absent limb bones, the absence of syndactyly, and the well formed digits (a second plate in the original

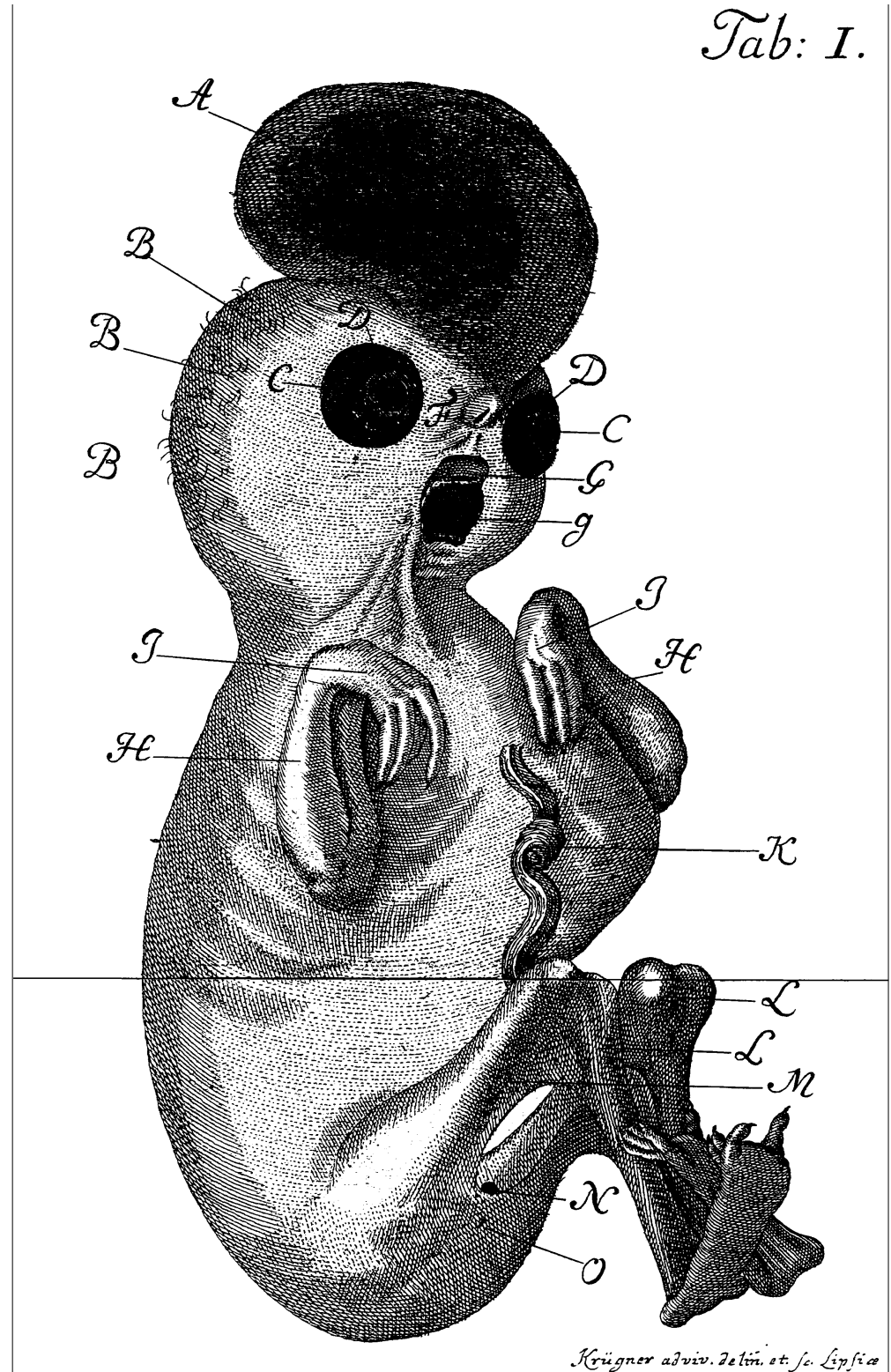


Figure 1 Engraving of the external features of the fetus, from Friderici, 1737 (courtesy of Leipzig Universitätsbibliothek).

description shows well formed nails on both hands and feet) are not features that would be expected in this syndrome.⁶ Severe Nager acrofacial dysostosis can present with similar features,⁷ but encephalocele and pterygia would not be expected. The most probable diagnosis is that of Roberts syndrome, though there are some unusual features, such as the prominent pterygia and absent external genitalia.

Roberts and SC phocomelia syndrome are generally regarded as the same nosological entity though the absence of cleft palate in the SC syndrome may be a difference.⁸ Roberts syndrome has been interpreted as a human mitotic mutation syndrome that leads to a wide spectrum of secondary developmental defects. The phenotype is highly variable.² The eponymous description of the syndrome was in 1919,⁹ though Mayer's case of 1829 was recognised as Roberts syndrome by Van den Berg and Francke,² and a fetus described by Virchow in 1898 has recently been interpreted as Roberts syndrome after re-examination of the specimen.¹⁰ A case has also been identified among the specimens in the teratological collection of the Museum Vrolik in Amsterdam,¹¹ and the diagnosis is also likely in an infant exhibited in Leiden in 1671.¹² Friderici's account therefore represents one of the earliest published descriptions of Roberts syndrome.

The author thanks the Director of the Convit Institute for the use of computer and library facilities, and the staff of Leipzig

Universitätsbibliothek and the library of the Royal Society of Medicine for their assistance.

- 1 Friderici, G. *Monstrum Homanum Rarissimum recens in locum editum in tabula exhibet simulque observationibus pathologicis aliisque illuc pertinentibus breviter illustrat*. Lipsiae: Christiani Langenhemii, 1737.
- 2 Van den Berg DJ, Francke U. Roberts syndrome: a review of 100 cases and a new rating system for severity. *Am J Med Genet* 1993;47:1104-123.
- 3 Freeman MV, Williams DW, Schimke RN, Temtamy SA, Vachier E, German J. The Roberts syndrome. *Clin Genet* 1974;5:1-16.
- 4 Maserati E, Pasquali F, Zuffardi O, Buttitta P, Cuoco C, Defant G, Gimelli G, Fraccaro M. Roberts syndrome: phenotypic variation, cytogenetic definition and heterozygote detection. *Ann Genet* 1991;34:239-46.
- 5 Mann NP, Fitzsimmons J, Fitzsimmons E, Cooke P. Roberts syndrome: clinical and cytogenetic aspects. *J Med Genet* 1982;19:116-19.
- 6 Hennekam RC, Huber J, Variend D. Bartsocas-Papas syndrome with internal anomalies: evidence for a more generalized epithelial defect or new syndrome? *Am J Med Genet* 1994;53:102-7.
- 7 McDonald MT, Gorski JL. Nager acrofacial dysostosis. *J Med Genet* 1993;30:779-82.
- 8 Qazi QH, Kassner EG, Masakawa A, Madahar C, Choi SJ. The SC phocomelia syndrome: report of two cases with cytogenetic abnormality. *Am J Med Genet* 1979;4:231-8.
- 9 Roberts JB. A child with double cleft lip and palate, protrusion of the intermaxillary portion of the upper jaw and imperfect development of the bones of the four extremities. *Ann Surg* 1919;70:252-3.
- 10 Urban M, Rogalla P, Tinschert S, Krietsch P. Tetrachomelia and bilateral cleft lip in a historical case of Roberts syndrome (Virchow, 1898). *Am J Med Genet* 1997;72:307-14.
- 11 Oostra RJ, Baljet B, Dijkstra PF, Hennekam CM. Congenital anomalies in the teratological collection of Museum Vrolik in Amsterdam, The Netherlands. I. Syndromes with multiple congenital abnormalities. *Am J Med Genet* 1998;77:100-15.
- 12 Bouchardi F. Infante monstroso Lugduni in viam publicam die V. Martii A. MDCLXXI. exposito. *Miscellanea Curiosa* 1672;3:14-16.

1st Asia Pacific Forum on Quality Improvement in Health Care

Three day conference

Wednesday 19 to Friday 21 September 2001

Sydney, Australia

We are delighted to announce this forthcoming conference in Sydney. Authors are invited to submit papers (call for papers closes on Friday 6 April), and delegate enquiries are welcome.

The themes of the Forum are:

- Improving patient safety
- Leadership for improvement
- Consumers driving change
- Building capacity for change: measurement, education and human resources
- The context: incentives and barriers for change
- Improving health systems
- The evidence and scientific basis for quality improvement.

Presented to you by the BMJ Publishing Group (London, UK) and Institute for Healthcare Improvement (Boston, USA), with the support of the the Commonwealth Department of Health and Aged Care (Australia), Safety and Quality Council (Australia), NSW Health (Australia), and Ministry of Health (New Zealand).

For more information contact: quality@bma.org.uk or fax +44 (0)20 7383 6869