

affects both ocular and skeletal development, with delayed intramembranous ossification and abnormal postaxial endochondral bone formation. The observed male to male transmission strongly suggests autosomal dominant inheritance. While there is some overlap of these features with previously reported genetic conditions, none exhibits delay in intramembranous ossification and most involve other organ systems unaffected in this family. This constellation of clinical findings represents a unique condition and suggests a distinctive autosomal dominantly inherited syndrome. Identification of other similarly affected subjects may eventually shed light on underlying causative mechanisms and broaden our understanding of ocular and skeletal development.

We thank the family for their cooperation in this study. Jane Schuette assisted in clinical evaluation and preparing photographs. DMM is a Fellow in the Medical Genetics Residency Program. JLG is supported by grants from the March of Dimes-Birth Defects Foundation (6-FY99-425) and the National Institutes of Health (HD34446).

- Warburg M. An update on microphthalmos and coloboma. A brief survey of genetic disorders with microphthalmos and coloboma. *Ophthalmic Paediatr Genet* 1991;12:57-63.
- Dolk H, Busby A, Armstrong BG, Walls PH. Geographical variation in anophthalmia and microphthalmia in England, 1988-94. *BMJ* 1998;317:905-10.
- Kallen B, Robert E, Harris J. The descriptive epidemiology of anophthalmia and microphthalmia. *Int J Epidemiol* 1996;25:1009-16.
- Warburg M. Classification of microphthalmos and coloboma. *J Med Genet* 1993;30:664-9.
- Schneider A, Bardakjian T, Aronson A, Dwyer M. Are specific eye findings a useful predictor of the presence of associated major anomalies in anophthalmia/microphthalmia? *Am J Hum Genet* 2000;67:717A.
- Castilla EE, Lugarinho R, da Graca Dutra M, Salgado LJ. Associated anomalies in individuals with polydactyly. *Am J Med Genet* 1998;80:459-65.
- Halal F, Homsy M, Perreault G. Acro-renal-ocular syndrome: autosomal dominant thumb hypoplasia, renal ectopia, and eye defect. *Am J Med Genet* 1984;17:753-62.
- Aalfs CM, van Schooneveld MJ, van Keulen EM, Hennekam RC. Further delineation of the acro-renal-ocular syndrome. *Am J Med Genet* 1996;62:276-81.
- Thompson EM, Baraitser M. Sorsby syndrome: a report on further generations of the original family. *J Med Genet* 1988;25:313-21.
- Smith RD, Fineman RM, Sillence DO, Lester PD, Nixon GW, Rimoin DL, Lachman RS. Congenital macular colobomas and short-limb skeletal dysplasia. *Am J Med Genet* 1980;5:365-71.
- Judisch GF, Martin-Casals A, Hanson JW, Olin WH. Oculodentodigital dysplasia. Four new reports and a literature review. *Arch Ophthalmol* 1979;97:878-84.
- Gladwin A, Donnai D, Metcalfe K, Schrandt-Stumpel C, Brueton L, Verloes A, Aylsworth A, Toriello H, Winter R, Dixon M. Localization of a gene for oculodentodigital syndrome to human chromosome 6q22-q24. *Hum Mol Genet* 1997;6:123-7.
- Biesecker LG, Abbott M, Allen J, Clericuzio C, Feuillan P, Graham JM Jr, Hall J, Kang S, Olney AH, Lefton D, Neri G, Peters K, Verloes A. Report from the workshop on Pallister-Hall syndrome and related phenotypes. *J Med Genet* 1996;65:76-81.
- Kang S, Allen J, Graham JM Jr, Grebe T, Clericuzio C, Patronas N, Ondrey F, Green E, Schäffer A, Abbott M, Biesecker LG. Linkage mapping and phenotypic analysis of autosomal dominant Pallister-Hall syndrome. *J Med Genet* 1997;34:441-6.
- Franceschini P, Testa A, Bogetti G, Girardo E, Guala A, Lopez-Bell G, Buzio G, Ferrario E, Piccato E. Kenny-Caffey syndrome in two sibs born to consanguineous parents: evidence for an autosomal recessive variant. *Am J Med Genet* 1992;42:112-16.
- Fanconi S, Fischer JA, Wieland P, Amares M, Fanconi A, Giedion A, Prader A. Kenny syndrome: evidence for idiopathic hypoparathyroidism in two patients and for abnormal parathyroid hormone in one. *J Pediatr* 1986;109:469-75.
- McDonald MT, Gorski JL. Nager acrofacial dysostosis. *J Med Genet* 1993;30:779-82.
- Cargile CB, McIntosh I, Clough MV, Rutberg J, Yaghami R, Goodman BK, Chen XN, Korenburg JR, Thomas GH, Geraghty MT. Delayed membranous ossification of the cranium associated with familial translocation (2;3)(p15;q12). *Am J Med Genet* 2000;92:328-35.
- Gonzalez-del Angel A, Carnevale A, Takenaga R. Delayed membranous cranial ossification in a mother and child. *Am J Med Genet* 1992;44:786-9.
- Zhou G, Chen Y, Zhou L, Thirunavukkarasu K, Hecht J, Chitayat D, Gelb BD, Pirinen S, Berry SA, Greenberg CR, Karsenty G, Lee B. CBFA1 mutation analysis and functional correlation with phenotypic variability in cleidocranial dysplasia. *Hum Mol Genet* 1999;8:2311-16.

J Med Genet
2001;38:551-556

**Department of
Pedodontics and
Orthodontics, Institute
of Dentistry, Helsinki
University Central
Hospital, PO Box 41,
FIN-00014 University
of Helsinki, Helsinki,
Finland**
S Pirinen
A Kentala
S Arte

**Institute of
Biotechnology, Univer-
sity of Helsinki,
Finland**
P Nieminen
I Thesleff

**Department of Human
Molecular Genetics,
National Public Health
Institute, Helsinki,
Finland**
T Varilo

Correspondence to:
Professor Pirinen,
sinikka.pirinen@helsinki.fi

Recessively inherited lower incisor hypodontia

Sinikka Pirinen, Anu Kentala, Pekka Nieminen, Teppo Varilo, Irma Thesleff, Sirpa Arte

EDITOR—Hypodontia, congenitally missing teeth, is common in modern man. The teeth most often missing in populations of European origin are the upper lateral incisors and second premolars. The condition is known to have a strong genetic component. At present two mutated genes in humans, *MSX1*¹ and *PAX9*² are known to cause missing permanent teeth. Mutations in *MSX1* can also cause orofacial clefting.³ Several experimental and clinical studies indicate that other genetic components are also involved.⁴⁻⁸ Hypodontia is also often seen in syndromes, particularly in those which present with other ectodermal anomalies,⁹ and in non-syndromic patients with cleft lip/alveolus with or without cleft palate.

The population prevalence of the common incisor-premolar hypodontia (IPH, MIM 106600) is 8-10% in healthy European children. Some or all third molar teeth are missing in one-fifth of the population,¹⁰ and missing

third molars are seen in varying combinations in IPH patients and/or family members.¹¹ Family studies also indicate that peg shaped upper lateral incisors, impacted canines, rotated bicuspid, and short root anomaly (SRA) are caused by the same genetic components that cause missing incisors and premolars.¹²⁻¹⁵ The condition is inherited as an autosomal dominant trait¹⁶ with reduced penetrance and is mostly restricted to the permanent dentition. When a large number of teeth (>6) are congenitally missing, the term used is oligodontia (MIM 6044625). The prevalence of oligodontia in European populations is estimated at 0.08%,¹⁷ but this figure also includes syndromic patients.

We describe 37 Finnish patients from 34 families with several lower incisors and upper lateral permanent incisors congenitally missing. In half of the patients, the corresponding deciduous teeth had either been missing or peg




Figure 1 The 34 families with RIH. The patients are the middle column, parents with minor dental anomalies are on the left, and the healthy and affected sibs with minor dental anomalies are on the right. In three families, two affected children were seen. The four single child families were excluded as uninformative in calculations of the proportion of affected sibs.

shaped. An atopic condition had been diagnosed in two thirds of the patients. Occurrence of the trait within the families followed an autosomal recessive mode of inheritance. We have called the condition Recessive Incisor Hypodontia (RIH) and suggest that it belongs to the Finnish Disease Heritage, the enrichment of some 40 rare disorders.

Table 1 Dental and health characteristics of 37 patients with recessive lower incisor hypodontia (RIH)

Clinical characteristics	Girls		Boys	
	+/N	(%)	+/N	(%)
Four missing lower incisors				
Permanent	1/18	6	8/19	42
Deciduous	2/19	10	—	—
Three missing lower incisors				
Permanent	2/14	14	2/19	11
Deciduous	1/14	7	—	—
Peg shaped incisor(s)				
Permanent	7/18	39	5/18	28
Deciduous	7/12	58	6/10	60
Missing permanent canine(s)	1/12	8	4/16	25
Missing premolar(s)	8/17	47	7/16	43
Missing first or second molars				
Permanent	1/16	6	6/16	38
Deciduous	1/10	10	—	—
Taurodontism in permanent molars	5/10	50	11/16	69
Dental age >2 SD	4/12	33	5/16	31
Asthma, diagnosed by a doctor	7/18	39	9/19	47
Atopic skin, diagnosed by a doctor	11/17	62	9/17	53

Methods

Ten patients with missing lower and upper lateral incisors were first seen at the Hypodontia Unit of the Department of Pedodontics and Orthodontics, University of Helsinki over the past five years. Their parents did not display similar hypodontia, but sometimes had one congenitally missing permanent tooth. In two families, the condition was seen in sibs. In order to discover the prevalence of this condition in Finland, a questionnaire was sent to all active orthodontists and municipal health centres in the country (362 letters). We received radiographs of 220 patients and 65 patients selected from these were further studied after giving their consent.

Inclusion criteria were three or four congenitally missing lower incisors, at least two congenitally missing or peg shaped lower permanent incisors together with missing upper lateral incisors, preceded by agenesis of at least one lower deciduous incisor, and a pedigree consistent with an autosomal recessive mode of inheritance. Exclusion of obvious dominant oligodontia, anhidrotic ectodermal dysplasia (EDA, also carriers), and incontinentia pigmenti (IP) was attempted by careful clinical examination, anamnestic information, and pedigree analysis. The final sample consisted of 37 patients from 34 families. Three pairs of sibs were included (fig 1).

The patients, parents, some grandparents, and sibs were examined radiographically and interviewed, and facial and oral photographs were taken. Alginate impressions were made of all cooperative patients. Dental age was calculated from radiographs by the age medians for tooth formation¹⁸ and standard deviations (SD) for dental ages.¹⁹

Parents and sibs showing dental anomalies such as hypodontia of one or two teeth, peg shaped teeth, retained cuspids or taurodontic teeth are shown in fig 1. The ancestors were traced back to 1850 from local church registries using the names, dates, and birth places of parents. Microfilm copies in The National Archives of Finland were used for earlier periods. To analyse the mode of inheritance, the ratio of affected to healthy sibs was corrected for the absence of healthy sibships born to two heterozygous parents.²⁰ For DNA analysis, samples of venous blood were taken from patients, grandparents, parents, and sibs. The study was approved by the Ethics Committee of the Institute of Dentistry, University of Helsinki.

Results

All 37 patients were under 22. Their clinical characteristics are presented in table 1 with typical panoramic radiographs in fig 2. Nine of the patients had no permanent lower incisors, two of them had also lacked the corresponding deciduous teeth. In seven, the upper permanent lateral incisors were also missing and in five the deciduous upper lateral incisors as well. In one, the upper central incisors were peg shaped with an anomalous structure (fig 2B). In four patients, three missing lower permanent incisors were evident. Of these 13 severely

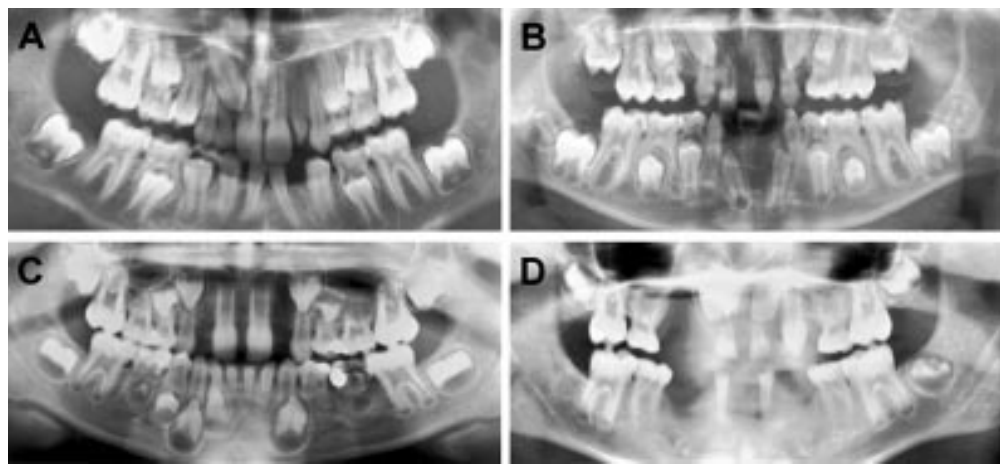

Figure 2 Radiographs of four patients with RIIH. In addition to missing lower and upper lateral incisors, missing permanent bicuspid are visible in all the patients and also missing cuspid and second molars in the most severely affected boy of the series (D). In patient B, the upper central incisors are conical with dens in dente. Later, his upper canines failed to erupt. Taurodontic upper first molars can be seen in all four.

affected patients, 10 were boys. The remaining 24 had a varying combination of missing or peg shaped lower and upper permanent and deciduous incisors. A deciduous tooth/teeth was missing in 19/36 (53%). In addition to incisors, other permanent teeth were also missing (fig 3). Mean dental age based on tooth formation was slightly delayed (SDS 0.8). Taurodontism was noted in the molar teeth of 16/26 patients (62%).

Photographs of the younger patients are shown in fig 4. Hair, nails, eyelashes, eyebrows, and perspiration were normal. Heights and

weights were also normal for age. A large proportion of the patients reported allergies (62%), such as atopic skin (52%) and asthma (43%), diagnosed by a doctor.

The male/female ratio of the patients was 19/18 (1.05). The proportion of affected sibs was calculated from 30 sibships with 76 children. The apparent proportion of affected sibs was 0.43. After mathematical correction for the absence of healthy sibships born of two heterozygous parents, using the a priori correction of truncate complete ascertainment, the proportion was 0.22. Pedigrees of 31 families were traced back at least to the fifth generation, and, when possible, to the late 17th century (10 generations). In two families, the parents of the proband had a common ancestor six and seven generations back (fig 5), but no other family linkages between the families were found. A map of Finland, where the birth places of the great grandparents of the patients are marked, is shown in fig 6. In the case of 23/31 index cases, the maternal and paternal ancestors originated from the same rural area.

Minor dental anomalies in the form of a missing upper lateral incisor or a missing third molar/molars was seen in 41% of the parents and in 27% of the healthy sibs (fig 1). Both parents and sibs reported allergies (46% and 40% respectively) and skin problems (46% and 35% respectively). Ten of the 29 examined mothers (34%), eleven of the 22 fathers (50%), six of the 22 healthy sisters (27%), and six of the 20 healthy brothers (30%) are shown in the pedigrees on the basis of their minor dental anomaly (fig 1).

Discussion

Our attempt at a nationwide ascertainment resulted in a response to more than half of our questionnaires, but because the oldest patient was only 22, it is likely that we only found a proportion of the total number of RIIH patients in Finland. By using strict criteria in an effort not to overdiagnose, some of the cases reported to us and some of the mildly affected sibs were perhaps misclassified.

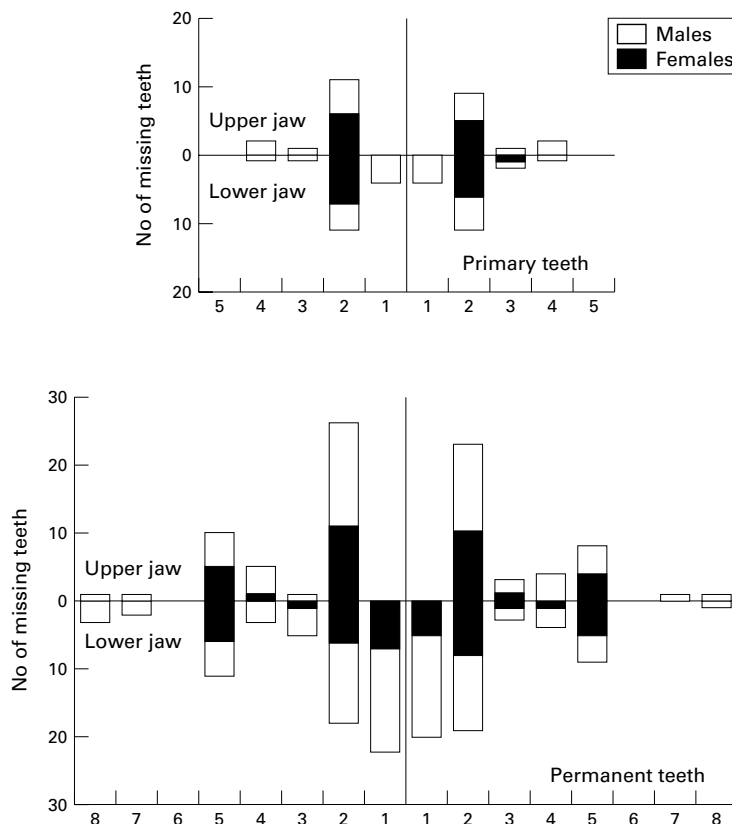


Figure 3 Distribution and number of missing deciduous and permanent teeth in 33 patients with RIIH.




Figure 4 Photographs of four unrelated patients. A similarity in facial features (broad nasal bridge, deep mentolabial sulcus, reduced anterior facial height) can be seen. Hair, eyelashes, and eyebrows appeared normal.

There are many published reports of conditions with missing lower incisors. In Japan the prevalence of tooth agenesis is of the same order as in Europeans, but the lower lateral incisor is the most commonly missing tooth.²¹ Witkop syndrome is an autosomal dominant condition with missing lower incisors and dysmorphic nails.²² In a patient from Minnesota,²³ dentition and a face very similar to that of our patients can be seen. First cousins of Egyptian origin, born of consanguineous marriages, with absent or conical lower deciduous incisors and thin hair and finger nails, with cleft palate in one and a branchial cyst in the other, were described by Fried,²⁴ who suggested autosomal recessive inheritance. A similar patient from Turkey, a child of first cousins, has also been described.²⁵ The Norwegian sibs reported²⁶ could also well have the autosomal recessive condition described here. A brother and sister from Lebanon with only a few permanent teeth and thin nails were recently reported²⁷ with the suggestion that they may have the condition described by Fried.²⁴ The pattern of missing

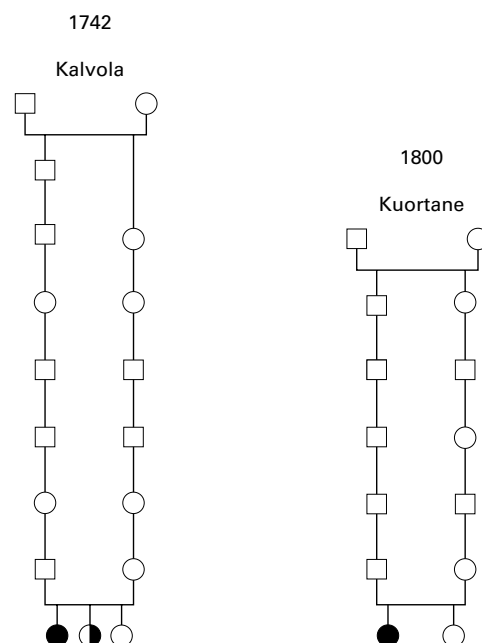


Figure 5 Pedigrees of the two probands whose parents were found to have a common ancestor originating from Kalvola in the middle of the 1700s (on the left) and Kuortane in 1800 (on the right).

teeth, including deciduous teeth, can also be similar in incontinentia pigmenti²⁸ and in Kabuki syndrome.²⁹

Congenitally missing deciduous teeth, as seen in 53% of the present patients, is not common in IPH. The prevalence figures are commonly close to 0.5%³⁰⁻³² and, interestingly, are higher (0.9%) in Finland.³³ All these figures may also include children with syndromic hypodontia or oligodontia. The genetics of hypodontia in the deciduous dentition has not been systematically studied, but has been assumed to be a symptom of IPH, as the corresponding permanent tooth is also usually missing. Detailed descriptions of the distribution of missing teeth in hypodontia patients are rare. However, in two Scandinavian studies, the pattern of missing lower and upper lateral incisors typical of RIH is evident.^{16 34} This also suggests that the condition also exists in other populations but has perhaps been overlooked because of overlapping symptoms with IPH. Retarded dental development and short rooted (taurodontic) molar tooth form are characteristic of hypodontia and oligodontia and were clearly seen in the condition described here.

The number of cases of atopic diseases, commonly seen in our patients and also reported by the family members, exceeds the reported population prevalences³⁵ and is an interesting finding in the present context. Of the similar published conditions, only the Norwegian report mentions asthma as a symptom of the patient. Recently, a distinct anhidrotic ectodermal syndrome with missing teeth and immunological abnormalities, EDA-ID, has been described. The condition seems to be caused by impaired NF-kB signalling.³⁶

In recessively inherited conditions heterozygous manifestations may occur. Here, minor dental anomalies were noted in less than half of

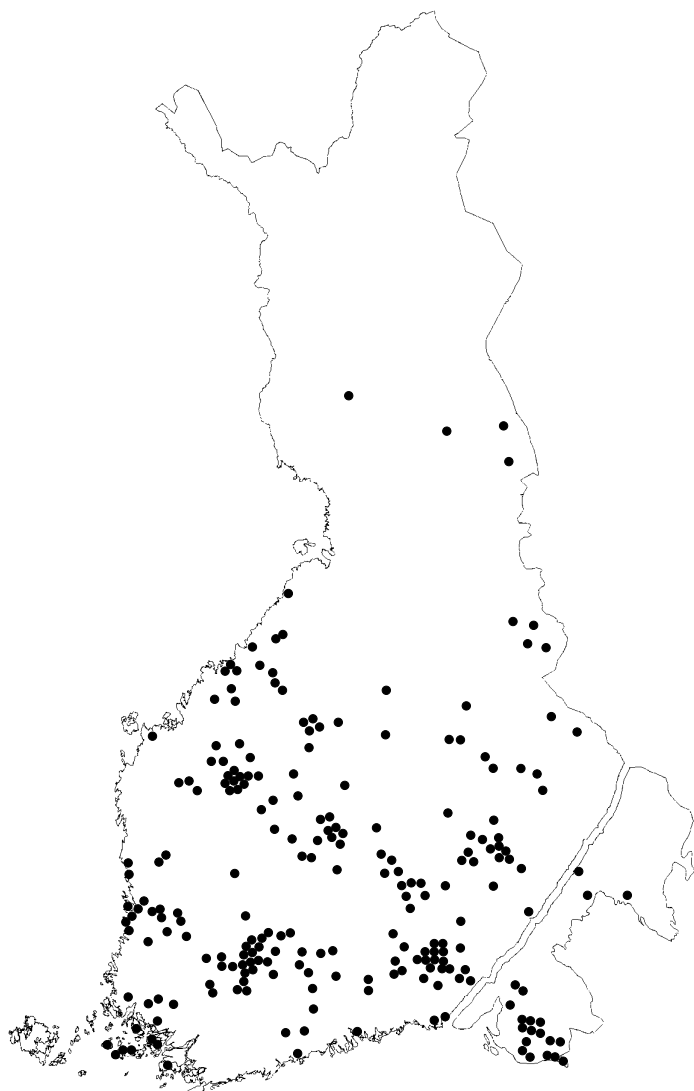


Figure 6 Birth places of patients' great grandparents, the pattern of the regional distribution of the ancestors coinciding with early settlement in Finland, and the population migration from north east to west and north. In 23 out of 31 cases the maternal and paternal grandparents originated from the same area.

the parents (41%), regarded as carriers of one mutated gene. Theoretically, two thirds of the healthy sibs are also heterozygous. In the sibs, minor dental anomalies were seen in 27%. As dental anomalies are quite common in the population, it is difficult to know whether these minor aberrations reflect the normal variation or represent heterozygous manifestations.

Several rare genetic conditions, mostly autosomal recessive, have been found in the Finnish population and this "Finnish Disease Heritage" has been explained by national and regional isolation of small population groups. Recent findings confirming that mostly one major mutation is seen in 70 to 100% of affected subjects³⁷ has shown this assumption to be correct. The results of our genealogical studies indicate that RIH is a new disease of the Finnish Disease Heritage, although it obviously is also seen in other populations.

In conclusion, we have diagnosed in Finland (population 5.2 million) 37 patients with a specific type of hypodontia with an autosomal

recessive mode of inheritance, characterised by missing deciduous and permanent incisors, and an increased inclination to eczema and asthma. We have named the condition Recessive Incisor Hypodontia (RIH). The patients resemble reported patients from consanguineous marriages from various parts of the world. Attempts to clarify the molecular pathology of this condition are at present being carried out and the results will be of interest in developmental studies and in the study of molecular mechanics of atopic diseases.

We warmly thank our patients and the numerous families for making this study possible. We thank dentists throughout Finland, in particular Professor Satu Alaluusua for informing us about patients with missing lower incisors. We thank Professors Reijo Norio and Leena Palotie-Peltonen for valuable advice and support. The study was supported by the Foundation of Paediatric Research, the Ulla Hjelt Fund, and the Academy of Finland.

- Vastardis H, Karimbux N, Guthua SW, Seidman JG, Seidman CE. A human MSX1 homeodomain missense mutation causes selective tooth agenesis. *Nat Genet* 1996;13:417-21.
- Stockton DW, Das P, Goldenberg M, D'Souza R, Patel PI. Mutation of Pax9 is associated with oligodontia. *Nat Genet* 2000;24:18-19.
- Van den Boogaard MJ, Dorland M, Beemer FA, van Amstel HK. MSX1 mutation is associated with orofacial clefting and tooth agenesis in humans. *Nat Genet* 2000;24:342-3.
- van Genderen C, Okamura RM, Farinas I, Quo RG, Parslow TG, Bruhn L, Grosschedl R. Development of several organs that require inductive epithelial-mesenchymal interactions is impaired in LEF-1-deficient mice. *Genes Dev* 1994;22:2691-703.
- Nieminen P, Arte S, Pirinen S, Peltonen L, Thesleff I. Gene defect in hypodontia: exclusion of MSX1 and MSX2 as candidate genes. *Hum Genet* 1995;96:305-8.
- Arte S, Nieminen P, Pirinen S, Peltonen L, Thesleff I. Gene defect in hypodontia: exclusion of EGF, EGFR and FGF-3 as candidate genes. *J Dent Res* 1996;75:1346-52.
- Ahmad W, Brancolini V, ul Faiyaz MF, Lam H, ul Haque S, Haider M, Maimon A, Aita VM, Owen J, Brown D, Zegarelli DJ, Ahmad M, Ott J, Christiano AM. A locus for autosomal recessive hypodontia with associated dental anomalies maps to chromosome 16q12.1. *Am J Hum Genet* 1998;62:987-91.
- Scarel RM, Trevilatto PC, Di Hipolito O, Camargo LEA, Line SRP. Absence of mutations in the homeodomain of the MSX1 gene in patients with hypodontia. *Am J Med Genet* 2000;92:346-9.
- Pinheiro M, Freire-Maia N. Ectodermal dysplasias: a clinical classification and a causal review. *Am J Med Genet* 1994;53:153-62.
- Haavikko K. Hypodontia of permanent teeth. An orthopantomographic study. *Suom Hammaslaak Toim* 1971;67:219-25.
- Baccetti T. A controlled study of associated dental anomalies. *Angle Orthod* 1998;68:267-74.
- Alvesalo L, Portin P. The inheritance pattern of missing, peg-shaped, and strongly mesio-distally reduced upper lateral incisors. *Acta Odontol Scand* 1969;27:563-75.
- Svinhufvud E, Myllärniemi S, Norio R. Dominant inheritance of tooth malpositions and their association to hypodontia. *Clin Genet* 1988;34:373-81.
- Pirinen S, Arte S, Apajalahti S. Palatal displacement of canine is genetic and related to congenital absence of teeth. *J Dent Res* 1996;75:1742-6.
- Apajalahti S, Arte S, Pirinen S. Short root anomaly in families and its association with other dental anomalies. *Eur J Oral Sci* 1999;107:97-101.
- Grahnén H. Hypodontia in the permanent dentition. A clinical and general investigation. *Odont Revy* 1956;7(suppl 3):1-100.
- Schalk van der Weide Y. *Oligodontia: a clinical, radiographic and genetic evaluation*. PhD thesis, University of Utrecht, Utrecht, 1992.
- Haavikko K. The formation and the alveolar and clinical eruption of the permanent teeth. An orthopantomographic study. *Suom Hammaslaak Toim* 1970;66:103-70.
- Nystöm M, Aine L, Peck L, Haavikko K, Kataja M. Dental maturity in Finns and the problem of missing teeth. *Acta Odontol Scand* 2000;58:49-56.
- Li CC. *Human genetics. Principles and methods*. New York: McGraw-Hill, 1961:58-78.
- Niswander JD, Sujaku C. Congenital anomalies of teeth in Japanese children. *J Phys Anthropol* 1963;21:569-74.
- Witkop CJ. Genetic diseases of the oral cavity. In: Tietze RW, ed. *Oral pathology*. New York: McGraw-Hill 1965:812-13.
- Moller KT, Gorlin RJ, Wedge B. Oligodontia, taurodontia and sparse hair growth - a syndrome? *J Speech Hear Disord* 1973;38:268-71.
- Fried K. Autosomal recessive hidrotic ectodermal dysplasia. *J Med Genet* 1977;14:137-9.

- 25 Akyuz S, Atasu A. Tooth and nail syndrome: genetic, clinical and dermatoglyphic findings: case report. *J Clin Pediatr Dent* 1993;17:105-8.
- 26 Lyngstadaas SP, Nordbo H, Gedde-Dahl T Jr, Tharne PS. On the genetics of hypodontia and microdontia: synergism or allelism of major genes in a family with six affected members. *J Med Genet* 1996;33:137-42.
- 27 Megarbane A, Noujeim Z, Fabre M, Der Kalustian VM. New form of hidrotic ectodermal dysplasia in a Lebanese family. *Am J Med Genet* 1998;75:196-9.
- 28 Gorlin RJ, Anderson JA. The characteristic dentition of incontinentia pigmenti. *J Pediatr* 1960;57:78-85.
- 29 Mhanni A, Cross H, Chudley A. Kabuki syndrome: description of dental findings in 8 patients. *Clin Genet* 1999;56:154-7.
- 30 Ravn JJ. Aplasia, supernumerary teeth and fused teeth in the primary dentition. An epidemiologic study. *Scand J Dent Res* 1971;79:1-6.
- 31 Magnusson TE. Hypodontia, hyperodontia and double formation of primary teeth in Iceland. An epidemiological study. *Acta Odontol Scand* 1984;42:137-9.
- 32 Gellin ME. The distribution of anomalies of the primary anterior teeth and their effect on the permanent successors. *Dent Clin North Am* 1984;28:69-80.
- 33 Järvinen S, Lehtinen L. Supernumerary and congenitally missing primary teeth in Finnish children. An epidemiological study. *Acta Odontol Scand* 1981;39:83-6.
- 34 Daugaard-Jensen J, Nodal M, Skovgaard LT, Kjaer I. Comparison of the pattern of agenesis in the primary and permanent dentitions in a population characterized by agenesis in the primary dentition. *Int J Pediatr Dent* 1997;7:143-8.
- 35 Anonymous. Worldwide variation in prevalence of symptoms of asthma, allergic rhinoconjunctivitis, and atopic eczema: ISAAC. The International Study of Asthma and Allergies in Childhood. (ISAAC) Steering Committee. *Lancet* 1998;351:1225-32.
- 36 Döffinger R, Smahi A, Bessia C, Geissmann F, Feinberg J, Durandy A, Bodemer C, Kenwrick S, Dupuis-Girod S, Blanche S, Wood P, Rabia SH, Headon DJ, Overbeek PA, Le Deist F, Holland SM, Belani K, Kumararatne DS, Fischer A, Shapiro R, Conley ME, Reimund E, Kalhoff H, Abinun M, Munnich A, Israëli A, Courtis G, Casanova JL. X-linked anhidrotic ectodermal dysplasia with immunodeficiency is caused by impaired NF- κ B signaling. *Nat Genet* 2001;27:278-85.
- 37 Peltonen L, Jalanko A, Varilo T. Molecular genetics of the Finnish disease heritage. *Hum Mol Genet* 1999;8:1913-23.

Congenital diaphragmatic hernia and interstitial deletion of chromosome 3

P Brennan, G D Croaker, M Heath

J Med Genet
2001;38:556-558

Clinical Genetics Service, City Hospital, Nottingham NG5 1PB, UK

P Brennan

Department of Paediatric Surgery, Queen's Medical Centre, Nottingham NG7 2UH, UK
G D Croaker

Cytogenetics Services, City Hospital, Nottingham NG5 1PB, UK
M Heath

Correspondence to:
Dr Brennan,
paul_brennan6@hotmail.com

EDITOR—Congenital diaphragmatic hernia (CDH) is seen in 1/2000 to 1/5000 fetuses and liveborn infants.^{1,2} Around 60% of fetuses diagnosed by antenatal ultrasound scanning at 20 weeks' gestation die in utero and the mortality rate in those surviving to term remains 30-50%. Coexistent major structural malformations are seen in a large proportion of cases, the commonest in liveborn infants being cardiac anomalies and neural tube defects.³

The genetic contribution to the aetiology of CDH is poorly understood. Although no large scale, population based, offspring recurrence study exists, familial clustering of CDH has been attributed to polygenic inheritance, which predicts an offspring recurrence risk of 1-2%. Familial congenital diaphragmatic hernia is, however, well described with autosomal dominant inheritance in most reported families,

although no linkage studies have been performed. Candidate genes may therefore be localised by studying the large proportion of patients with CDH and an underlying chromosome abnormality. Autosomal trisomies, typically of chromosomes 13, 18, and 21, account for many of these cases. More complex structural rearrangements have also been reported in some series, although many of these cases have additional organ malformations.⁴⁻⁶ However, a number of de novo structural anomalies associated with CDH have been documented, defining candidate loci for future study; these are summarised in table 1.

Case report

We report a male infant with CDH associated with a proximal deletion of the long arm of chromosome 3 in mosaic form. Clinical genetic evaluation was sought during the third pregnancy of a 29 year old female and a 32 year old male. She had previously had two healthy children and there was no history of pregnancy loss. Fetal ultrasound examination at 22 weeks' gestation showed a large, left sided diaphragmatic hernia with mediastinal shift but no hydrops. No other structural abnormality was seen. A placental biopsy was taken for cytogenetic analysis. Both direct and long term preparations showed an abnormal mosaic male karyotype with an additional, unidentified small chromosome in approximately 50% of cells examined. Analysis of cultured amniocytes confirmed the marker chromosome in 50% of cells. Fluorescence in situ hybridisation (FISH) studies indicated that the marker was derived from the centromeric region of chromosome 3 (fig 1A) and contained euchromatic material. The karyotype was assigned as

Table 1 Candidate loci for congenital diaphragmatic hernia

Locus	Reported anomaly	Other phenotypic features	Reference
1q	Del(1)(q32q42)de novo	Low set ears Neck webbing Hypospadias Undescended testes Bilateral equinovarus Camptodactyly	17
3q	Mosaic del(3)(q11.1q13.2)de novo	No	This case
	Del(3)(q21q23)de novo	BPES	16
4p	Del(4)(p16)de novo	Wolf-Hirschhorn syndrome	6
	del(4)(p16)de novo	Dandy-Walker malformation	6
8p	del(8)(p23.1)de novo	AVSD	18
	del(8)(p23.1)de novo	Facial dysmorphism Dolichocephaly Tricuspid stenosis	6
8q	t(8;13)(q22.3;q22)mat	No	7
	t(8;15)(q22.3;q15)de novo	No	7
12p	Mosaic tetrasomy 12p	Pallister-Killian syndrome	19, 20
15q	t(5;15)(p15.3;q24)mat ?unbalanced	No	21
	t(15;17)(q24.3;q23.3)pat unbalanced	No	6
	del(15)(q24qter)	No	22
	t(1;15)(q41;q21.2)de novo	Falot's tetralogy Severe microphthalmia	23