

"Molecular rulers" for calibrating phenotypic effects of telomere imbalance

C L Martin, D J Waggoner, A Wong, S Uhrig, J A Roseberry, J F Hedrick, S D Pack, K Russell, E Zackai, W B Dobyns, D H Ledbetter

J Med Genet 2002;**39**:734–740

See end of article for authors' affiliations

Correspondence to:
Dr D H Ledbetter,
Department of Human
Genetics, The University of
Chicago, 920 E 58th
Street, Chicago, IL 60637,
USA;
dhl@genetics.uchicago.edu

Revised version received
5 June 2002
Accepted for publication
18 June 2002

As a result of the increasing use of genome wide telomere screening, it has become evident that a significant proportion of people with idiopathic mental retardation have subtle abnormalities involving the telomeres of human chromosomes. However, during the course of these studies, there have also been telomeric imbalances identified in normal people that are not associated with any apparent phenotype. We have begun to scrutinise cases from both of these groups by determining the extent of the duplication or deletion associated with the imbalance. Five cases were examined where the telomere rearrangement resulted in trisomy for the 16p telomere. The size of the trisomic segment ranged from ~4.7 Mb and the phenotype included mental and growth retardation, brain malformations, heart defects, cleft palate, pancreatic insufficiency, genitourinary abnormalities, and dysmorphic features. Three cases with telomeric deletions without apparent phenotypic effects were also examined, one from 10q and two from 17p. All three deletions were inherited from a phenotypically normal parent carrying the same deletion, thus without apparent phenotypic effect. The largest deletion among these cases was ~600 kb on 17p. Similar studies are necessary for all telomeric regions to differentiate between those telomeric rearrangements that are pathogenic and those that are benign variants. Towards this goal, we are developing "molecular rulers" that incorporate multiple clones at each telomere that span the most distal 5 Mb region. While telomere screening has enabled the identification of telomere rearrangements, the use of molecular rulers will allow better phenotype prediction and prognosis related to these findings.

Unbalanced submicroscopic telomere rearrangements are a significant cause of idiopathic mental retardation with or without congenital malformations, accounting for approximately 5% of these cases.^{1–7} With the development of a second generation set of telomere specific clones,⁸ telomere screening is now readily available in many laboratories and is being used extensively in the evaluation of children with mental retardation and congenital anomalies. The results of these investigations are not only providing explanations for previously unexplained cases of mental retardation, but are also further defining the frequency of telomeric rearrangements in various clinical populations and clarifying the phenotype associated with these rearrangements. Furthermore, during the course of these studies, telomeric imbalances have also been identified in normal subjects without any apparent phenotype.^{3, 5, 6, 9} These observations suggest that not all telomere imbalances result in a phenotype and that the lack of phenotypic effect may be related to the size of the rearrangement or the involvement of regions of the genome that are tolerant to dosage imbalances.

Despite these advances, there is a paucity of information regarding the genotype/phenotype correlations of many of the telomere imbalances discovered, complicating the diagnostic and prognostic implications. Therefore, further studies are needed for all telomeric regions to define how much monosomy or trisomy can be tolerated without phenotypic effect and, conversely, how much monosomy or trisomy will have a phenotypic effect. These studies will aid in the differentiation between telomere rearrangements that are pathogenic versus those that are benign variants.

The current format for routine telomere screening does not give any information as to the size of the imbalance, making interpretation of the significance of the finding and comparison to other reported cases difficult. In addition, many telomere rearrangements are the result of unbalanced segregation of a

balanced translocation resulting in both monosomy and trisomy for a telomeric segment and the relative contribution of these rearrangements to the phenotype is difficult to decipher.

There are several reported polymorphisms involving the telomeric regions of human chromosomes, including 2q,¹⁰ 16p,¹¹ and the pseudoautosomal region of the short arm of the X and Y chromosomes.³ In addition, there have been multiple benign familial variants identified and the number of these suspected imbalances continues to increase.^{5, 6, 12} The phenotypic consequences of such findings will depend on the size of the imbalance and the gene content of the region.

To define telomeric rearrangements as pathogenic or benign variants, we are developing "molecular rulers" to measure the size of imbalances identified in telomeric regions. Multiple clones throughout the telomere region are being used in a fluorescence in situ hybridisation (FISH) assay to delineate the size of any imbalances identified. The use of a panel of genomic probes for each telomere will be beneficial in defining the size of the trisomy or monosomy, which would allow a more substantial comparison of similar cases. The collection of data from all telomere regions will be beneficial in clarifying and defining genotype/phenotype correlations and will assist investigators in narrowing the search for genes causing specific phenotypic effects. Here, we report the use of molecular rulers in defining genotype/phenotype correlations for telomere imbalances involving 10q, 16p, and 17p. Clinical findings in five cases of trisomy 16p are reported, all of which were sized using the molecular ruler strategy. In addition, three cases of monosomy, one from 10q and two from 17p, all without apparent phenotypic effect, are described.

SUBJECTS AND METHODS

Case 1

Patient 1 was born after a pregnancy complicated by polyhydramnios and intrauterine growth retardation. Her

Table 1 Clinical features of patients with partial trisomy 16p

Features	Case 1	Case 2	Case 3	Case 4	Case 5
Mental retardation	+	+	+	+	+
Seizures	+	-	+	-	-
Hearing loss	+	U	+	+	+
Delayed growth	+	-	+	+	+
Microcephaly	+	-	+	+	-
Cleft palate	-	+	+	+	+
Pancreatic insufficiency	+	U	U	+	U
Brain anomalies	+	+	U	+	U
Pachygyria	-	+		-	
Abnormal corpus callosum	+	-		+	
Optic nerve hypoplasia	+	+	U	U	U
Heart defect	-	-	+	+	+
Vascular ring				-	+
Atrial septal defect			+	+	-
Genitourinary abnormalities	-	+	-	+	+
Vesicoureteral reflux		+		+	+
Cystic kidney		-		-	+
Hydronephrosis		+		+	+
Dysmorphic features	+	+	+	+	+
Ear abnormalities	+	+	N	+	+
Thin, fragile hair	+	N	N	+	+
Cutis aplasia	+	N	N	-	-
Small palpebral fissures	N	N	+	+	+
Downward slanting palpebral fissures	N	N	N	-	+
Upward slanting palpebral fissures	N	N	+	-	-
Prosis	N	N	N	+	+
Hypertelorism	N	N	+	+	+
Broad nasal root	+	N	+	-	+
Bifid nasal tip	N	N	N	+	-
Short philtrum	N	N	+	-	-
High arched palate	N	N	+	-	-
Micrognathia	+	+	N	-	-
Anteriorly placed anus	+	N	N	-	-
Hypoplastic distal phalanges	N	N	+	-	-
2-3 toe syndactyly	N	+	N	+	+

+, present; -, absent; U, unknown; N, not reported in clinical description.

birth weight was 1930 g (<5th centile) and head circumference was 32 cm (2nd centile). The medical history was significant for feeding problems with severe gastro-oesophageal reflux, which required gastrostomy tube placement, pancreatic insufficiency with fatty replacement of the pancreas, bilateral optic nerve and foveal hypoplasia with nystagmus, sensorineural hearing loss, seizures, vesicoureteral reflux with hydronephrosis, and recurrent pneumonias. Cranial MRI at 4 months showed severe classical lissencephaly with mild hypogenesis of the rostrum and splenium of the corpus callosum, moderate enlargement of the lateral ventricles, and cavum septi pellucidi.

Physical examination at 8 months of age showed her weight was 3960 g (<5th centile), length was 57.1 cm (<5th centile), and OFC was 40.25 cm (<5th centile). Dysmorphic features are listed in table 1 and include prominent forehead, bitemporal narrowing, short nose with upturned nares, right epicanthic fold, syndactyly of the left third and fourth fingers, transverse palmar crease, and bilateral clinodactyly of the fifth digits. Neurological examination showed weak cry, poorly coordinated suck, truncal hypotonia, bilateral hand fistling with adducted thumbs, and hypoactive tendon reflexes. She died at 17 months of age from complications of infection.

The family history was positive for two maternal relatives with isolated preaxial polydactyly. Cytogenetic analysis of the proband and her mother were normal.

Case 2

The prenatal history was complicated by ultrasound findings of shortened long bones and hydronephrosis. She was born at 38 weeks' gestation with a birth weight of 2970 g (10th centile), length of 51 cm (50th centile), and OFC of 34 cm (50th centile). Findings in the newborn period included

pachygyria, mild optic atrophy, cleft of the soft palate, eventration of the left diaphragm, and bilateral vesicoureteral reflux with hydronephrosis. Dysmorphic features are listed in table 1. Neurological examination showed a weak cry and diffuse hypotonia. The family history indicated that a paternal aunt had mental retardation and many similar features to the proband. A karyotype on peripheral blood lymphocytes was reported as normal. In addition, FISH deletion studies for DiGeorge and Miller-Dieker syndromes, chromosomal breakage studies, and 7-dehydrocholesterol levels were all normal.

Case 3

The prenatal history was positive for non-immune hydrops and a cystic hygroma. She was born at 36 weeks of gestation and was noted to be small for gestational age. Her medical complications and dysmorphic features are shown in table 1. Her development at the age of 6 years indicated global developmental delays. She walked at 3 years and requires extensive help with feeding and dressing herself. She does not talk or follow commands and has behavioural problems with head banging, self-injurious behaviour, and tantrums. Physical examination at the age of 6 showed her weight was 16 kg (<5th centile), height was 97 cm (<5th centile), and OFC was 49 cm (10th centile).

The family history was positive for multiple maternal relatives with similar medical problems to the proband. A maternal half uncle had two children, a son who died and was reported to have hypertelorism, small phallus, cryptorchidism, multicystic kidneys, seizures, and hydrops and a 21 year old daughter with severe mental retardation, cleft palate, hypertelorism, ventricular septal defect, seizures, and a limb anomaly. In addition, a maternal great aunt and a maternal second cousin had similar birth defects and medical complications.

Routine cytogenetic analysis and FISH for a 22q11.2 deletion were reported as normal.

Case 4

Prenatal history was complicated by oligohydramnios, and she was born at 37 weeks' gestation with a birth weight of 2750 g (25th centile). Her medical complications are listed in table 1 and included sagittal craniosynostosis. In addition, she had feeding intolerance requiring gastrostomy tube placement, growth failure, multiple episodes of pneumonia, pancreatic insufficiency treated with enzyme supplementation, skin abnormalities, mild to moderate bilateral sensorineural hearing loss requiring hearing aids, and decreased vision. Her neurological history was notable for a hypoplastic corpus callosum and arachnoid cyst, seizure disorder, developmental delays with mental retardation, and a behaviour disorder with head banging.

Laboratory data included a positive sweat chloride test, although molecular testing for 70 cystic fibrosis mutations was negative. She carried a diagnosis of cystic fibrosis, but her skin condition made it difficult to confirm the positive sweat chloride test. Her development at the age of 6 was markedly delayed. She could pull to a stand, cruise, and sit alone but could not crawl or walk and was not toilet trained. She had a normal pincer grasp but did not transfer and could make sounds and noises but did not talk.

Her physical examination at the age of 6 showed her weight was 12.6 kg (<5th centile), length was 96 cm (<5th centile), and head circumference was 47 cm (<5th centile). Her head was microcephalic with thin, sparse hair and mild scaling of the scalp. Dysmorphic features included bilateral ptosis, short palpebral fissures, upturned, bifid nasal tip, bilateral cupped ears, clubbing of all nails, and thin tapered fingers with bilateral fifth finger clinodactyly. Her neurological examination showed increased tone in the upper and lower extremities with normal reflexes and proximal hypotonia. Her skin examination was remarkable for keratotic follicular papules with underlying erythema.

The family history showed four maternal miscarriages, one with a different partner, and one healthy full sib. The maternal grandmother had one miscarriage and a maternal aunt had a history of three miscarriages. The paternal grandmother had one miscarriage and a paternal aunt had two miscarriages. Routine cytogenetic analysis on lymphocytes was normal.

Case 5

Prenatal history was remarkable for exposure to Serzone until approximately three months and then Paxil throughout the pregnancy. Neither of these medications has a proven teratogenic effect. A prenatal ultrasound at 18 weeks identified a cystic right kidney. He was born at 40 weeks with a birth weight of 2802 g (20th centile). The medical history, listed in table 1, was significant for ptosis, blocked tear ducts, a vascular ring with an aberrant right subclavian artery, patent ductus arteriosus, hypospadias, and bilateral inguinal hernias and undescended testes. In addition, he had gastro-oesophageal reflux and poor weight gain which required gastrostomy tube placement, a mild conductive hearing loss, reactive airway disease, and a cystic kidney with grade IV reflux. Development at the age of 15 months was delayed. He could not walk, pull to stand, or crawl. He sat without support at 1 year, and began rolling front to back at 11 months. His language skills tested at 7 months for receptive skills and 4-5 months for expressive language. Physical examination at the age of 15 months showed his weight was 9.34 kg (10th centile), length was 73.5 cm (<50th centile), and head circumference was 48.5 cm (50th centile). His head had an occipital bulge with mild posterior flattening. Dysmorphic features are listed in table 1 and include sparse eyebrows, ptosis, hypertelorism (IPD 5.6 cm, >97th centile), low set, asymmetrical, simple ears, a depressed nasal bridge, a long, thin

philtrum, cleft of the upper gum, downturned corners of the mouth, a hypoplastic scrotum, and brachydactyly of the fifth finger with clinodactyly bilaterally. Neurological examination was significant for hypotonia.

The family history was remarkable for a maternal grandmother with a single kidney and two maternal cousins with genitourinary reflux. Routine cytogenetic analysis, FISH analysis for deletions of 22q11.2 and 4p16.3, 7-dehydrocholesterol levels, and *MID1* sequence analysis were reported as normal.

Case 6

Paternal chromosome analysis was done secondary to a history of recurrent miscarriages and showed satellites on the short arm of one chromosome 17, referred to as a satellited 17p chromosome. The father was phenotypically normal. Amniocentesis on a subsequent pregnancy showed a similar satellited 17p chromosome in the fetus.¹³

Case 7

Parental chromosomes were studied secondary to the finding of a satellited 17p chromosome in their fetus who died in utero. The normal father was found to carry the same satellited 17p chromosome.

Case 8

This 22 month old child had a neurological history of seizures, pachygyria, large ventricles, cerebellar hypoplasia, and an absent corpus callosum. His medical history was also significant for ichthyosis, mild arthrogryposis, and developmental delay. Dysmorphic features included sparse scalp hair, absent eyebrows, and short upper limbs.

The family history was significant for four maternal miscarriages and a single miscarriage in the maternal grandmother and two maternal aunts. All investigations as to an underlying aetiology, including metabolic studies, were negative.

Genomic clone selection

The BAC and PAC clones included in the molecular ruler assay were selected based on published physical maps¹⁴ and publicly available genome resources, such as the University of California Santa Cruz Human Genome Browser (<http://genome.ucsc.edu>) and the integrated STS/radiation hybrid maps (Whitehead Institute, http://www-genome.wi.mit.edu/cgi-bin/contig/phys_map and NCBI Map Viewer, <http://www.ncbi.nlm.nih.gov>). Genomic clones were selected at ~500 kb intervals to cover the most distal 5 Mb of each chromosome of interest. For the most distal 1 Mb, a complete contig of overlapping clones covering the region was developed to analyse any smaller imbalances. The clones used in this study to examine the imbalances identified in the telomeric region of 10q are cosmid 2136c3¹⁵ and BAC 261B16.⁸ For 16p, the telomere clone BAC 191K2⁸ was used with the following RPCI-11 BAC clones: 243K18, 522P1, 270H24, 361I19, 95J11, 295D4, 545E8, 445I19, and 65J21. A panel of cosmids was used for 17p including 2111a5, 144D6, C106B5, c1027, ABR, and 43c4¹⁶ (unpublished data). The estimated genomic distances of these clones to the Miller-Dieker/lissencephaly region, shown in fig 1, are from physical mapping studies of the 17p telomere region (C Cardoso, manuscript in preparation).

Before inclusion in the molecular ruler, all clones were PCR-verified using STS primers. In addition, FISH was used to verify each clone's cytogenetic position and unique localisation (that is, no cross hybridisation signals to other chromosomes). For the chromosome ends that showed a conflicting order by physical mapping data, interphase or metaphase FISH was used to determine the order of the genomic clones.

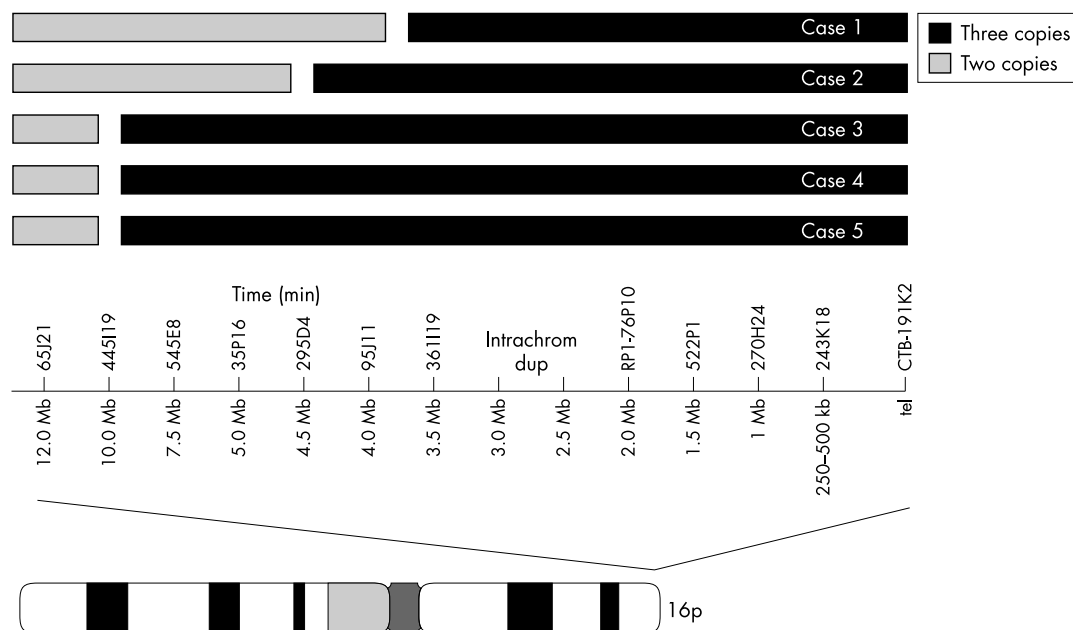


Figure 1 Results from FISH analysis using a molecular ruler for the telomeric region of the short arm of chromosome 16 on metaphase cells from five patients. The trisomic region for each case is shown at the top of the figure by the black bar; the grey bar is proximal to the breakpoint and represents a region of normal copy number. Unique genomic clones spaced at ~500 kb intervals are depicted above the ideogram for chromosome 16. For the region spanning ~2.5-3 Mb from the telomere, a unique clone could not be identified; this region contains an intrachromosomal duplication. Case 1 had the smallest region of trisomy. The largest trisomic region identified was observed in cases 3, 4, and 5, whose breakpoints were all contained within BAC clone 445I19.

FISH analysis

All of the trisomy 16p cases and the 10q deletion case were previously reported to have normal routine chromosome analysis, completed elsewhere, before telomere analysis was pursued. Genome wide telomere screening was carried out on peripheral blood samples using the ToTelVysion™ assay (Vysis Inc, Downers Grove, IL), which consists of 41 telomere probes,⁸ combined in 15 mixtures of two to four probes each. The manufacturer's instructions were followed and five metaphase cells were analysed for each hybridisation area. The rearrangements in the two remaining cases, which were both 17p satellited chromosome cases, were half-cryptic rearrangements identified by cytogenetic analysis. Targeted telomere analyses, with probes specific to the 17p telomere region,^{8,15} were used to uncover the underlying genomic imbalance.

After a telomere imbalance was identified, further FISH analysis was pursued using the molecular ruler assay. DNA was isolated using an automated DNA isolation system (AutoGen 740, Integrated Separation Systems, Natick, MA) and directly labelled with either Spectrum Orange-dUTP (Vysis Inc), Spectrum Green-dUTP (Vysis Inc), or Diethylaminocoumarin-5-dUTP (DEAC/aqua, PerkinElmer Life Sciences Inc, Boston, MA) using a standard nick translation reaction. Slide preparation, probe preparation, and hybridisation were completed using previously described methods.¹⁶ Slides were washed in $0.4 \times \text{SSC}/0.3\% \text{NP-40}$ for two minutes at 73°C then transferred into $2 \times \text{SSC}/0.1\% \text{NP-40}$ at room temperature for two minutes. Slides were briefly rinsed in $4 \times \text{SSC}/0.1\% \text{Tween-20}$ at room temperature and then mounted in antifade solution (Vector) containing DAPI. At least 10 cells were analysed using direct microscopic visualisation and digital imaging analysis (ViewPoint software, Vysis, Inc). Chromosome identification was achieved by inverted DAPI staining.

RESULTS

Trisomy 16p cases

A deletion of the telomeric region of 17p was identified in case 1 as a result of FISH analysis with cosmid probes from distal

17p13 (c71, L132, and 8-1)¹⁸ (unpublished data). Subsequent FISH analysis of the proband's mother showed that she is a carrier of an apparently balanced reciprocal translocation between the short arms of chromosomes 16 and 17. Further FISH analysis on the proband, with cosmid cPKDCO5 (D16S2505), which lies near the PKD gene on chromosome 16p, showed trisomy for the 16p telomere region. Therefore, the proband inherited the derivative 17, but not the derivative 16, from her mother resulting in monosomy for 17p and trisomy for 16p.

The remaining four 16p trisomy cases were identified during the course of genome wide telomere screening of patients with unexplained mental retardation and normal karyotypes. Case 2 involved an unbalanced translocation between the telomeres of chromosome 7p and 16p, cases 3 and 4 had unbalanced translocations involving the 10q and 16p telomeres and case 5 had an unbalanced translocation involving the short arm of chromosome 14. In all four cases, only 16p trisomy was observed. In cases 2, 3, and 4 the breakpoint on the second chromosome occurred distal to the chromosome specific telomere probe and did not result in any detectable corresponding monosomy. The monosomy in case 5 corresponded to the short arm of an acrocentric chromosome, any deletion of which is not expected to be associated with a phenotype. Overall, three cases were shown to be inherited from a parent carrying the balanced form of the translocation; cases 1 and 3 were maternally inherited while case 2 was paternally inherited. The family history for case 4 suggested possible maternal inheritance of the balanced form of the translocation; however, the family chose not to pursue further testing. Case 5 was a de novo rearrangement.

To measure the extent of trisomy for 16p in these cases, a molecular ruler was used, using the set of clones shown in fig 1 as FISH probes. Additional clones had to be identified for 16p since some of the cases showed trisomy for all clones tested in the initial probe set. Results of the molecular ruler analysis are shown in fig 1. Case 1 had the smallest trisomic region (~3.5-4 Mb) while cases 3, 4, and 5 had the largest trisomic regions (~10 Mb); the breakpoint for these three

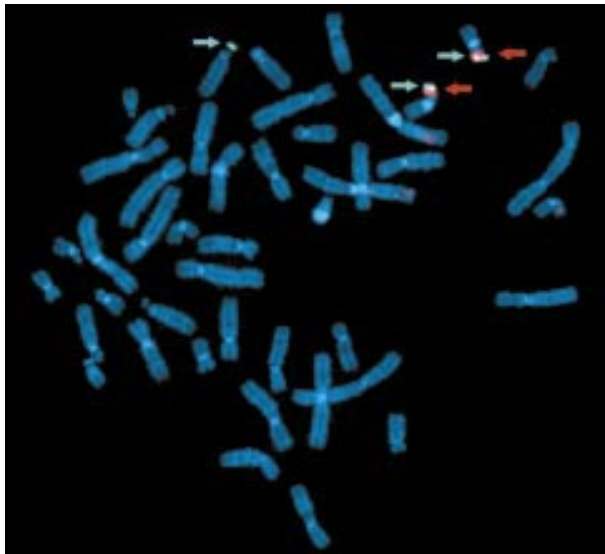


Figure 2 Representative image of FISH analysis on case 5 with an unbalanced rearrangement involving the telomeric regions of the short arm of chromosome 14 and the short arm of chromosome 16. BAC clone 545E8, labelled in Diethylaminocoumarin (abbreviated DEAC and shown in aqua), is distal to the breakpoint and shows three signals marked with the aqua arrows. BAC 65J21, labelled in Spectrum Orange, lies proximal to the breakpoint and shows two signals, as indicated by the red arrows. The two normal chromosomes 16 contain hybridisation signals for both probes. The derivative chromosome 14 only has a hybridisation signal for 545E8, indicating trisomy for this region.

rearrangements resided within the same clone, BAC 445I19. Fig 2 shows a representative FISH image from case 5 with two clones, one on each side of the breakpoint.

The fact that the largest rearrangements involve approximately 10 Mb implies that they should have been visible by routine cytogenetic analysis. However, all were reported as normal. Upon re-examination, the two rearrangements involving 10q were visible by G banding. Initial failure to detect these imbalances underlines the fact that many telomeric rearrangements are subtle because of the G negative staining pattern of these regions.

17p deletion cases

Two unrelated couples were referred for cytogenetic studies because of recurrent fetal losses; G banding analysis showed 17p satellited chromosomes in both phenotypically normal males. Using FISH with a unique 17p telomere probe, cosmid 211a5, deletions of the 17p telomere region were identified for both 17p satellited chromosomes. To calibrate the size of the deletion, proximal cosmid clones were used as FISH probes. Unique DNA sequences were deleted in both cases; the larger deletion of approximately 600 kb includes the *ABR* gene and as many as 13 other more distal genes (C Cardoso, manuscript in preparation). Fig 2 depicts the extent of monosomy associated with each 17p satellited chromosome case.

10q deletion case

By genome wide telomere screening, a deletion of the 10q telomere was identified in case 8 using cosmid 2136c3, derived from a half YAC clone from the 10q telomere, yRM2136.¹⁵ Parental analysis with the same 10q telomere probe showed that the phenotypically normal mother carries the same telomere deletion. BAC clone 261B16,⁸ which was identified using an STS derived from yRM2136 and extends proximal from it, was subsequently tested on the proband and his mother. Two signals were observed in both subjects; however, the signal intensity was noted to be consistently weaker on

one chromosome 10 homologue than the other, suggesting that the breakpoint for the deletion is contained in this clone.

DISCUSSION

Genome wide telomere screening has provided great strides in determining the aetiology of unexplained mental retardation with or without congenital abnormalities. These advances, however, have shown the need for more detailed studies of telomere imbalances to define correlations between genotype and phenotype further. Telomere imbalances that are pathogenic need to be differentiated from those that are benign familial variants or polymorphisms. To accomplish this goal, it is necessary to organise coordinated efforts to study multiple cases involving the same telomere imbalance. In this study, we used "molecular rulers" for the telomeric regions of 10q, 16p, and 17p to define the extent of imbalance in subjects with telomere rearrangements. By carrying out FISH with probes extending proximal from each telomere probe, the size of the imbalance was delineated, adding to the description of such telomere phenotypes.

Complete trisomy 16 is the most frequent autosomal anomaly resulting in spontaneous miscarriage.¹⁷ Partial trisomy 16p is rare, but can result in a live born child. More than 30 cases of partial trisomy 16p have now been described and the pattern of malformations and anomalies in the patients is strikingly similar.¹⁸⁻²¹ This syndrome is associated with developmental delay, recurrent respiratory infections, seizures, congenital heart defects, renal and genitourinary anomalies, and cleft palate. Characteristic facial features include scant hair, micrognathia, hypertelorism, upward slanting palpebral fissures, low set ears, a long philtrum and thin upper lip, overlapping fingers, and an abnormally placed thumb. The majority of cases are secondary to a familial balanced translocation.¹⁸ However, inverted and direct duplications and insertional translocations have also been described.²¹⁻²³

Based on previous cytogenetic findings, the critical region appears to be within 16p13.1-p13.3. Interestingly, the severity of clinical findings is irrespective of the amount of 16p trisomy present with several cases of trisomy for the entire short arm being described. In several cases, the identification of the 16p trisomic segment was only possible after the recognition of the parental balanced translocation or with further molecular cytogenetic studies.²⁴

The cases reported here have similar clinical features to the previously reported cases. In table 1, the cases are shown in order from the smallest trisomic region (case 1) to the largest (cases 3, 4, and 5), with case 2 having the smallest pure trisomy. Based on the size of the trisomy, there is no specific phenotypic pattern distinguishing these cases. When compared to the described trisomy 16 phenotype, case 2 is notable for a lack of hearing loss and heart defects. However, most of the clinical information that was available for this subject was from the newborn period, which may explain the lack of noted hearing loss and heart defects are only present in approximately 55% of all trisomy 16p cases. Thus, it is difficult to interpret whether the lack of these features in case 2 is the result of the smaller trisomic segment. Of interest is the lack of cleft palate in case 1, which has the smallest amount of trisomy 16. Cleft palate is described in 80-90% of reported trisomy 16 cases and is not a common feature of monosomy 17p. This observation suggests that a region causative for cleft palate may be more proximal on chromosome 16p than the trisomic segment in this patient. Overall, there are no specific patterns or specific features that differentiate the cases reported here from those published; however, the smaller size of the trisomic region involved in these five patients further narrows the critical region for this disorder.

Case 1 has an additional finding of monosomy for chromosome 17p explaining the overlapping features with the Miller-Dieker syndrome. Additional clinical features in case 1 include

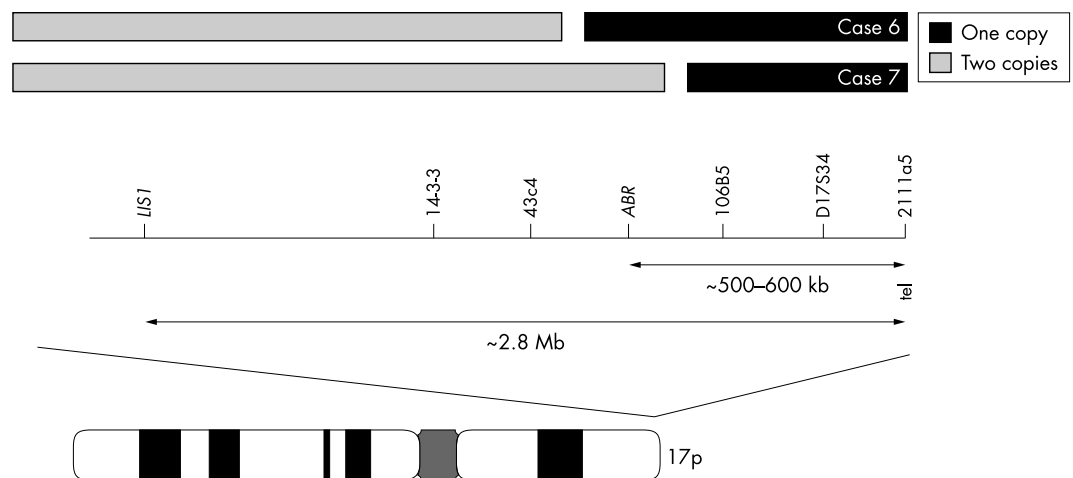


Figure 3 Results from FISH analysis on two unrelated cases with satellited 17p chromosomes. The deleted region for each case is shown by the black bar; the normal region of the chromosome is shown by the grey bar. The clones used to size the deletions are listed above the ideogram of chromosome 17. The largest deletion without phenotype, spanning ~600 kb, was observed in case 6.

cutis aplasia and pancreatic insufficiency and, therefore, a diagnosis of Johanson-Blizzard syndrome was previously considered. However, after defining the unbalanced chromosome rearrangement in this patient, most of the patient's phenotype is consistent with the features of monosomy 17p and trisomy 16p, making the diagnosis of Johanson-Blizzard syndrome seem less likely. Pedigree analysis suggests that Johanson-Blizzard syndrome is autosomal recessive, but its gene has not been mapped and the pathogenesis remains unknown. However, since the features of this patient overlap with those of Johanson-Blizzard syndrome, telomere analysis to rule out trisomy 16p should be considered in any patient with this diagnosis.

Case 4 also has pancreatic insufficiency and carries a diagnosis of cystic fibrosis. However, molecular testing did not confirm the diagnosis and the sweat test results remain questionable because of her underlying skin condition. When compared with the trisomy 16p phenotype, all of her features are consistent with partial trisomy 16p. Pancreatic insufficiency has not been previously reported in cases of trisomy 16p, although many of these patients die at an early age and this feature may not have developed or been recognised. The findings of pancreatic insufficiency in two of the patients reported here may represent a new feature of the trisomy 16p phenotype.

The five cases reported here not only contribute to the growing phenotypic description of partial trisomy 16p, but the molecular ruler data also help to narrow the critical region and to dissect the genotype/phenotype correlation. There is a surprising lack of differences between the cases reported here and published cases. One possible difference is survival, as many of the previously reported cases were lethal at an early age. Four out of five of the cases reported here are alive and doing relatively well; the one case who is dead had monosomy 17p and lissencephaly as a complicating factor. Telomere analysis will allow the identification of cryptic rearrangements like those reported here and may show that abnormalities like partial 16p trisomy are not as rare as once thought, but may have been unrecognised because of the lower resolution of previous testing methodologies.

Another interesting result shown by using the molecular ruler strategy to examine these five 16p trisomy cases is that the breakpoint of three of these rearrangements appears to lie within the same clone, BAC 445119. This finding suggests that there may be a common mechanism for some rearrangements involving 16p. It will be interesting to determine if shared subtelomeric sequence homologies mediate these and other telomeric rearrangements.

The two 17p deletion cases reported here show compelling evidence for a lack of phenotypic effect from this rearrangement since a normal father carries the rearrangement in both cases. Unique DNA sequences were deleted in both cases; the larger deletion was greater than 600 kb and includes *ABR* and as many as 13 other more distal genes (C Cardoso, manuscript in preparation), highlighting the fact that large deletions are not necessarily associated with a phenotype.

The deletion involving the 10q telomere was identified in both the proband and his phenotypically normal mother making it unlikely that the deletion was associated with the clinical features in the child. Terminal deletions of 10q are rare, but have been reported with typical breakpoints at 10q25 or 10q26. The typical features associated with these deletions include a prominent, beaked nose, malformed ears, mental retardation, cardiac defects, and anogenital malformations.²⁵ The features of the patient reported here do not overlap with this reported phenotype, giving more credence to the likelihood that his deletion is not related to his phenotype.

Several of the benign variants reported so far, including the three reported here, are deletions leading to monosomy for a telomeric segment. The most likely explanation for the lack of phenotypic effect is that decreased dosage of these genes does not have an effect on normal development or function. This phenomenon has been shown for chromosome 16p where small telomere deletions lead only to α thalassaemia without other significant effects despite the deletion of many highly conserved genes.¹² Larger deletions of these same chromosomes, however, would have a more significant impact on the phenotype. For example, as shown in fig 3 for the cases of 17p monosomy, if the deletion extended proximally ~1-2 Mb, there would be dramatically different results, including Miller-Dieker syndrome and lissencephaly. The use of a "molecular ruler" to define the critical breakpoint of these regions will be critically important in delineating benign variants from pathogenic deletions.

Telomere screening has enabled the identification of telomere rearrangements and shown that these rearrangements are a significant cause of mental retardation. Use of molecular rulers will now allow more accurate phenotype prediction and genetic counselling, as well as assist in mapping genes for specific clinical features.

As a part of the human genome project, BAC clones are being identified throughout the genome at approximately a 1 Mb resolution.²⁶ These clones have been used in a comparative genomic hybridisation (CGH) array format to assess genome wide copy number.²⁷ CGH arrays targeting specific genomic regions are also being developed. Veltman *et al*²⁸ recently

described the successful use of a CGH array, containing clones corresponding to each human telomere region, in high throughput screening for telomeric imbalances. In clinically important regions, such as telomeres, having a higher resolution on such an array would allow increased detection of more frequent chromosomal rearrangements. Molecular rulers for each telomere that span the most distal 5 Mb of every chromosome with one clone every 500 kb would be a valuable addition to genome wide copy number measurements. In addition, to identify those telomeric rearrangements less than 1 Mb in size, a contig of the most distal telomere region could be developed and implemented in the same assay. The use of this expanded CGH array format would allow not only for the identification of telomere rearrangements, but also for the delineation of their size in a single hybridisation, thus providing a more efficient and comprehensive mechanism for testing for telomeric imbalances.

ACKNOWLEDGEMENTS

Data access. UCSC Human Genome Browser, <http://genome.ucsc.edu>. NCBI Map Viewer, <http://www.ncbi.nlm.nih.gov>. Whitehead Institute, http://www-genome.wi.mit.edu/cgi-bin/contig/phys_map.

The first two authors contributed equally to this work. This work was supported in part by grants from the National Institutes of Health (1 RO1 HD36715-03 to DHL) and the March of Dimes (6-FY00-404 to DHL and CLM). The authors would like to thank Drs Betsy Hirsch, Lillian Killos, Marcia Willing, and Eric Wulfsberg for providing patient samples and clinical information and Dr Carlos Cardoso for useful discussions and mapping information for chromosome 17p. We would also like to acknowledge Dr Daniel L Kastner who kindly provided the 16p cosmid probe, cPKDCOS5.

Authors' affiliations

C L Martin, D H Waggoner, A Wong, S Uhrig, J A Roseberry, J F Hedrick, W B Dobyns, D H Ledbetter, Department of Human Genetics, University of Chicago, Chicago, IL, USA

S D Pack, National Institute of Neurological Disorders and Stroke, National Institutes of Health, Bethesda, MD, USA

K Russell, E Zackai, Children's Hospital of Philadelphia, Division of Human Genetics and Molecular Biology, Philadelphia, PA, USA

REFERENCES

- 1 **Flint J**, Wilkie AOM, Buckle VJ, Winter RM, Holland AJ, McDermid HE. The detection of subtelomeric chromosomal rearrangements in idiopathic mental retardation. *Nat Genet* 1995;**9**:132-40.
- 2 **Knight SJL**, Regan R, Nicod A, Horsley SW, Kearney L, Homfray T, Winter RM, Bolton P, Flint J. Subtle chromosomal rearrangements in children with unexplained mental retardation. *Lancet* 1999;**354**:1676-81.
- 3 **Knight SJL**, Flint J. Perfect endings: a review of subtelomeric probes and their use in clinical diagnosis. *J Med Genet* 2000;**37**:401-9.
- 4 **De Vries BBA**, White SM, Knight SJL, Regan R, Homfray T, Young ID, Super M, McKeown C, Splitt M, Quarrell OWJ, Trainer AH, Niermeijer MF, Malcolm S, Flint J, Hurst A, Winter RM. Clinical studies on submicroscopic subtelomeric rearrangements: a checklist. *J Med Genet* 2001;**38**:145-50.
- 5 **Joyce CA**, Dennis NR, Cooper S, Browne CE. Subtelomeric rearrangements: results from a study of selected and unselected probands with idiopathic mental retardation and control individuals by using high-resolution G-banding and FISH. *Hum Genet* 2001;**109**:440-51.
- 6 **Riegel M**, Baumer A, Jamar M, Delbecque K, Herens C, Verloes A, Schinzel A. Submicroscopic terminal deletions and duplications in retarded patients with unclassified malformation syndromes. *Hum Genet* 2001;**109**:286-94.
- 7 **Rossi E**, Piccini F, Zollino M, Neri G, Caselli D, Tenconi R, Castellan C, Carozzo R, Danesino C, Zuffardi O, Ragusa A, Castiglia L, Galesi O, Greco D, Romano C, Pierluigi M, Perfume C, Di Rocco M, Faravelli F, Bricarelli FD, Bonaglia MC, Bedeschi MF, Borgatti R. Cryptic telomeric rearrangements in subjects with mental retardation associated with dysmorphism and congenital malformations. *J Med Genet* 2001;**38**:417-20.
- 8 **Knight SJL**, Lese CM, Precht K, Kuc J, Ning Y, Lucas S, Regan R, Brenan M, Nicod A, Martin Lawrie N, Cardy DLN, Nguyen H, Hudson TJ, Riethman H, Ledbetter DH, Flint J. An optimized set of human telomere clones for studying telomere integrity and architecture. *Am J Hum Genet* 2000;**67**:320-32.
- 9 **Baliff BC**, Kashork CD, Shaffer LG. The promise and pitfalls of telomere region-specific probes. *Am J Hum Genet* 2000;**67**:1356-9.
- 10 **Macina RA**, Negorev DG, Spais C, Ruthig LA, Hu XL, Riethman HC. Sequence organization of the human chromosome 2q telomere. *Hum Mol Genet* 1994;**3**:1847-53.
- 11 **Wilkie AO**, Higgs DR, Rack KA, Buckle VJ, Spurr NK. Stable length polymorphism of up to 260 kb at the tip of the short arm of human chromosome 16. *Cell* 1991;**64**:595-606.
- 12 **Horsley SW**, Daniels RJ, Anguita E, Raynham HA, Peden JF, Villegas A, Vickers MA, Green S, Wayne JS, Chui DH, Ayyub H, MacCarthy AB, Buckle VJ, Gibbons RJ, Kearney L, Higgs DR. Monosomy for the most telomeric, gene-rich region of the short arm of human chromosome 16 causes minimal phenotypic effects. *Eur J Hum Genet* 2001;**9**:217-25.
- 13 **Killos LD**, Lese CM, Mills PL, Precht KS, Stanley WS, Ledbetter DH. A satellited 17p with telomere deleted and no apparent clinical consequences. *Am J Hum Genet* 1997;**61**:736.
- 14 **Daniels RJ**, Peden JF, Lloyd C, Horsley SW, Clark K, Tufarelli C, Kearney L, Buckle VJ, Doggett NA, Flint J, Higgs DR. Sequence, structure and pathology of the fully annotated terminal 2 Mb of the short arm of human chromosome 16. *Hum Mol Genet* 2001;**10**:339-52.
- 15 **National Institutes of Health**, Institute of Molecular Medicine Collaboration. A complete set of human telomeric probes and their clinical application. *Nat Genet* 1996;**14**:86-9.
- 16 **Chong SS**, Pack SD, Roschke AV, Tanigami A, Carozzo R, Smith AC, Dobyns WB, Ledbetter DH. A revision of the lissencephaly and Miller-Dieker syndrome critical regions in chromosome 17p13.3. *Hum Mol Genet* 1997;**6**:147-55.
- 17 **Hassold TJ**, Pettay D, Freeman SB, Grantham M, Takaesu N. Molecular studies of non-disjunction in trisomy 16. *J Med Genet* 1991;**28**:159-62.
- 18 **Leonard C**, Huret JL, Imbert MC, Lebouc Y, Selva J, Bouley AM. Trisomy 16p in a liveborn offspring due to maternal translocation t(16;21)(q11;p11) and review of the literature. *Am J Med Genet* 1992;**43**:621-5.
- 19 **O'Connor TA**, Higgins RR. Trisomy 16p in a liveborn infant and review of trisomy 16p. *Am J Med Genet* 1992;**42**:316-19.
- 20 **Schinzel A**, Kotzot D, Brecevic L, Robinson WP, Dutly F, Dauwerse H, Binkert F, Baumer A, Ausserer B. Trisomy first, translocation second, uniparental disomy and partial trisomy third: a new mechanism for complex chromosomal aneuploidy. *Eur J Hum Genet* 1997;**5**:308-14.
- 21 **Kokalj-Vokac N**, Medica I, Zagorac A, Zagradisnik B, Erjavec A, Gregoric A. A case of insertional translocation resulting in partial trisomy 16p. *Ann Genet* 2000;**43**:131-5.
- 22 **Juan JLC**, Cigudosa JC, Gomez AO, Almeida MTA, Miranda JLG. De novo trisomy 16p. *Am J Med Genet* 1997;**68**:219-21.
- 23 **Movahhedian HR**, Kashani DS, Bull D, Jones KL, Rothman A. Pulmonary hypertension and trisomy 16. *Pediatr Cardiol* 1998;**19**:187-9.
- 24 **Brandt CA**, Lyngbye TL, Pederson S, Bolund L, Friedrich U. Value of chromosome painting in determining the chromosomal outcome in offspring of a 12;16 translocation carrier. *J Med Genet* 1994;**31**:234-7.
- 25 **Waggoner DJ**, Chow CK, Dowton SB, Watson MS. Partial monosomy of distal 10q: three new cases and a review. *Am J Med Genet* 1999;**86**:1-5.
- 26 **The BAC Resource Consortium**. Integration of cytogenetic landmarks into the draft sequence of the human genome. *Nature* 2001;**409**:953-8.
- 27 **Snijders AM**, Nowak N, Segaves R, Blackwood S, Brown N, Conroy J, Hamilton G, Hindle AK, Huey B, Kimura K, Law S, Myambo K, Palmer J, Ylstra B, Yue JP, Gray JW, Jain AN, Pinkel D, Albertson DG. Assembly of microarrays for genome-wide measurement of DNA copy number. *Nat Genet* 2001;**29**:263-4.
- 28 **Veltman JA**, Schoenmakers EF, Eussen BH, Janssen I, Merx G, van Cleef B, van Ravenswaaij CM, Brunner HG, Smeets D, van Kessel AG. High-throughput analysis of subtelomeric chromosome rearrangements by use of array-based comparative genomic hybridization. *Am J Hum Genet* 2002;**70**:1269-76.