

REVIEW ARTICLE

Leber hereditary optic neuropathy

P Y W Man, D M Turnbull, P F Chinnery

J Med Genet 2002;**39**:162–169

Leber hereditary optic neuropathy (LHON) is a mitochondrial genetic disease that preferentially causes blindness in young adult males, affecting about 1 in 25 000 of the British population. It is characterised by bilateral subacute loss of central vision owing to focal degeneration of the retinal ganglion cell layer and optic nerve. Over 95% of LHON cases are primarily the result of one of three mitochondrial DNA (mtDNA) point mutations, G3460A, G11778A, and T14484C, which all involve genes encoding complex I subunits of the respiratory chain. An intriguing feature of LHON is that only ~50% of males and ~10% of females who harbour a pathogenic mtDNA mutation actually develop the optic neuropathy. This marked incomplete penetrance and gender bias imply that additional mitochondrial and/or nuclear genetic factors must be modulating the phenotypic expression of LHON. It is also likely that environmental factors contribute to the onset of visual failure. However, these secondary precipitating factors remain poorly defined at present. In this review, we describe the natural history of this optic nerve disorder and highlight issues relating to clinical diagnosis, management, and genetic counselling. We also discuss the findings of recently published studies and the light they shed on the complex aetiology and pathophysiology of LHON.

HISTORY

Leber hereditary optic neuropathy (LHON, OMIM 535000) was first described as a distinctive clinical entity in 1871 by the German ophthalmologist Theodore Leber (1840-1917).¹ He described a characteristic pattern of visual loss among members of four families and his observations were subsequently confirmed in pedigrees from different populations.²⁻⁶ These early studies highlighted several of the salient features of LHON including the maternal transmission of the disease, the predilection of males to lose vision, and the almost exclusive involvement of the optic nerve. The non-mendelian pattern of inheritance was to remain a mystery until more became known about the mitochondrial genome. The hypothesis that a mitochondrial DNA (mtDNA) mutation was the causative factor in LHON then became firmly established.

PATHOGENIC MUTATIONS

In one retrospective study, over 95% of LHON pedigrees harboured one of three mtDNA point mutations, G3460A, G11778A, and T14484C, which all involve genes encoding complex I subunits of the mitochondrial respiratory chain.⁷ These primary LHON mutations have so far not been found in a large sample of normal controls, without a family history of visual failure (>1000). However, the relative frequency of each of these pathogenic mutations varies considerably world wide. A meta-analysis involving 159 pedigrees from northern Europe and Australia showed that G11778A was the most prevalent LHON mutation (table 1). The predominance of G11778A is even more marked in the Far East where it accounts for ~90% of total LHON cases.⁸ Although T14484C is relatively rare in most countries,^{8,9} it is the most common mutation found among French Canadians (87%). This has recently been convincingly ascribed to a founder event.^{10,11}

Primary mutations have not been identified in a small minority of diagnosed LHON cases, the most likely explanation being that rare pathogenic mtDNA variants are segregating in these pedigrees. Some of these have recently been identified and most seem to cluster in the gene encoding the ND6 subunit. It has been suggested by some investigators that the latter represents a mutational hot spot for LHON and should be investigated in pedigrees where none of the three primary mutations is present.¹²

EPIDEMIOLOGY

LHON is by far the most common of the mitochondrial genetic diseases, with an estimated prevalence of ~1 in 25,000 in the north east of England.²³ No prevalence data are currently available for other populations, although 2% of people on the blind register in Australia are reported to suffer from LHON.²⁴ The reported median age of onset in LHON varies somewhat between various case series, but 95% of those who lose their vision do so by their early 50s (table 2). However, visual deterioration can occur any time during the first to the seventh decade of life. Except for one report which found a slight increase in the age of onset in females carrying the G11778A mutation,⁹ it is generally accepted that neither gender nor mutational status significantly influences the timing and severity of the

See end of article for authors' affiliations

Correspondence to:
Dr P F Chinnery,
Department of Neurology,
School of Neurosciences
and Psychiatry, The
Medical School, University
of Newcastle Upon Tyne,
Newcastle upon Tyne, UK;
P.F.Chinnery@ncl.ac.uk

Abbreviations: LHON, Leber hereditary optic neuropathy; mtDNA, mitochondrial DNA; MS, multiple sclerosis; MHC, major histocompatibility complex; VEPs, visual evoked potentials; ADOA, autosomal dominant optic atrophy

Table 1 Reported pathogenic primary mtDNA mutations in LHON

	Mutation	Protein	Prevalence ⁷	Reference
Common	G3460A	ND1	>95%	14, 15
	G11778A	ND4	13%	13
	T14484C	ND6	69%	16, 17
			14%	
Rare	G13730A	ND5	<5%	18
	G14459A	ND6		19
	C14482G	ND6		20
	A14495G	ND6		12
	C14498T	ND6		21
	C14568T	ND6		21
	T14596A	ND6		22

initial visual loss.^{10 25-27} LHON is also characterised by a marked gender bias, with males more likely to become affected than females. Finally, up to 60% of LHON probands will give a reliable history of other maternal relatives being affected. The remainder most likely represent cases where family history is difficult to trace back, given that de novo mutation is rare in LHON.²⁸

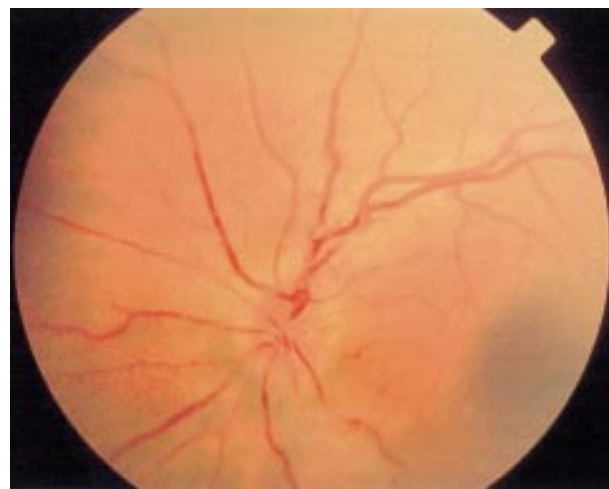
CLINICAL FEATURES

Acute phase

LHON carriers remain asymptomatic until they experience blurring or clouding of vision in one eye. In the vast majority of cases, visual dysfunction is bilateral, the fellow eye becoming affected either simultaneously (25%) or sequentially (75%), with a median inter-eye delay of eight weeks.⁹ Visual acuity usually reaches a nadir four to six weeks after the first start of symptoms and is severely reduced to 6/60 or less. The characteristic field defect in LHON is a centrocaecal scotoma. Other clinical features include the early impairment of colour perception but, more importantly, pupillary reflexes are preserved and patients usually report no pain on eye movement. Fundoscopy provides other diagnostic clues and in classical cases the following abnormalities can be observed: vascular tortuosity of the central retinal vessels, a circumpapillary telangiectatic microangiopathy, and swelling of the retinal nerve fibre layer (fig 1). However, it must be stressed that in ~20% of LHON cases, the optic disc looks entirely normal in the acute phase.²⁹

Chronic phase

The retinal nerve fibre layer gradually degenerates and after six months optic atrophy is a universal feature of LHON.³⁰ If a patient is only seen at this stage, it can be difficult to exclude other possible causes of optic atrophy, especially if there is no clear maternal family history. In these cases, molecular genetic testing is warranted. The extent of final visual recovery

**Figure 1** Acute fundal appearance in LHON.

depends greatly on the patient's mutational status, with G11778A carrying the worst overall prognosis (table 2). There is also some evidence that patients with the T14484C mutation are more likely to show improvement if visual loss occurs before the age of 20.^{27 31} However, LHON is a devastating disorder with the majority of patients showing no functional improvement and remaining within the legal requirement for blind registration.

Associated features

A significant minority of white LHON carriers, especially females with the G11778A mutation, develop clinical and neuroimaging features indistinguishable from multiple sclerosis (MS), including unmatched oligoclonal bands in the cerebrospinal fluid.³²⁻³⁶ The prevalence of this MS-like illness in LHON is higher than expected because of chance only and some investigators have argued for a potential role of autoimmunity in the pathophysiology of this mitochondrial disorder.^{32 37} It is of note that higher levels of antibodies to the optic nerve protein tubulin have been found among LHON carriers compared to controls.³⁸ However, other reports have failed to detect any significant association between LHON and either class I or class II major histocompatibility complex (MHC) genotypes.^{39 40} Overall, the "autoimmunity" hypothesis has not yet been convincingly substantiated. Other clinical abnormalities have also been reported to be more common in LHON compared to controls. These include postural tremor, peripheral neuropathy, non-specific myopathy, movement disorders, and cardiac arrhythmias.^{31 41-46} The jury is still out as to whether these represent real or spurious associations.

However, it is now well recognised that a group of LHON pedigrees does exist characterised by optic neuropathy and additional severe neurological deficits (spastic dystonia, ataxia, and juvenile onset encephalopathy). These "LHON+"

Table 2 Summary of major reported case series in LHON

	No of pedigrees	Median onset (y)	Male:female ratio	Visual recovery	Reference
G3460A	9	29	2.3 : 1	22%	26
	8	20	4.3 : 1	25%	9
G11778A	49	28	4.5 : 1	4%	25
	66	24	3.7 : 1	25%	9
T14484C	17	27	2.1 : 1	37%	27
	23	19	7.7 : 1	58%	10

Table 3 Respiratory chain dysfunction in LHON

	In vitro ⁶⁰⁻⁷⁴		In vivo ⁷⁵⁻⁷⁷
	Complex I activity*	Respiratory rate*	MRS*
G3460A	60–80%	30–35%	0%
G11778A	0–50%	30–50%	75%
T14484C	0–65%	10–20%	50%

*% decrease relative to controls.

syndromes have been linked to various mtDNA mutations in isolated pedigrees from Holland, Australia, and North America: A11696G and/or T14596A,²² T4160C,⁴⁷ and G14459A,¹⁹ respectively. So far, none of the three primary LHON mutations have been linked to such severe phenotypes.

Diagnosis

A tentative diagnosis of LHON can usually be made based solely on the patient's clinical history. A series of baseline investigations are usually carried out. These include a formal assessment of visual fields with static or kinetic perimetry and fluorescein angiography which in LHON shows no leakage, implying that the microvasculature is not compromised. Electrophysiological studies, including electroretinograms and visual evoked potentials (VEPs), can be carried out to exclude retinal pathology and confirm optic nerve dysfunction. A more in depth review of the electrophysiological features in LHON is provided by Sherman and Kleiner.⁴⁸ CT and MRI scans are usually normal in LHON, although there are some case reports of non-enhancing high signals within the optic nerve and sheath distension.⁴⁹⁻⁵⁴ The latter is thought to represent slight oedema or gliosis in the atrophic phase. Cranial imaging is sometimes required in those situations where other inflammatory or structural causes of acute optic neuropathy need to be excluded. In singleton cases with atypical clinical features and no clear maternal history of blindness, molecular genetic testing for the three primary LHON mutations will usually clarify matters.

NEUROPATHOLOGY

To date, there are no pathological data on the acute phase of LHON. Post mortem studies have been carried out mostly on elderly patients who had experienced visual loss several decades earlier.⁵⁵⁻⁵⁶ In some of the early reports, the mutational status of the patient is also unknown although the clinical history was highly suggestive of LHON.⁴⁹⁻⁵⁰⁻⁵⁷⁻⁵⁸ These limitations notwithstanding, the neuropathology in LHON seems to be limited to the retinal ganglion cell layer with sparing of the retinal pigment epithelium and photoreceptor layer. There is marked cell body and axonal degeneration, with associated demyelination and atrophy observed from the optic nerves to the lateral geniculate bodies. Apoptosis is thought to be involved although this has yet to be formally proven.⁵⁹

BIOCHEMICAL FEATURES

Since all three primary LHON mutations involve complex I subunits, one would expect respiratory chain function to be compromised, leading to deficient ATP production and subsequent degeneration of retinal ganglion cells as a consequence of energy failure. However, both in vitro and in vivo biochemical studies have produced conflicting results regarding the extent of respiratory chain dysfunction in LHON (table 3). These variations could be partly because of the different protocols used. For example, a wide range of cell types was assayed in these experiments, including platelets, leucocytes, fibroblasts, and skeletal muscle, to name just a few. For obvious technical reasons, it is not possible to investigate retinal ganglion cells directly. A striking feature of these studies is

that none found any significant difference between affected and unaffected LHON carriers. Balancing the current weight of evidence, it seems that LHON is associated with a rather more subtle respiratory chain defect when compared to other pathogenic mtDNA mutations (such as the A3243G in the syndrome of mitochondrial myopathy, encephalopathy, lactic acidosis, and stroke-like episodes (MELAS)).

PATHOPHYSIOLOGY

These functional studies also raise important issues regarding the pathophysiology of LHON (fig 2). The most obvious one relates to the focal degeneration of the optic nerve. One could argue that only retinal ganglion cells are affected because they require a sustained level of ATP for normal function. This is supported by a recent study that found a high level of mitochondrial enzyme activity in retinal ganglion cells and the nerve fibre layer.⁷⁸ However, two points militate against this assertion. Firstly, it has been shown quite conclusively that photoreceptors have a much higher oxidative demand than retinal ganglion cells.⁷⁹⁻⁸⁰ Secondly, it is difficult to reconcile why other mitochondrial disorders characterised by more severe complex I defects do not universally cause optic atrophy (J Smeitink, personal communication). Although purely speculative, it is possible that retinal ganglion cells are preferentially involved because they are somehow exquisitely sensitive to subtle imbalances in cellular redox state or increased level of free radicals.⁸¹

The clinical picture of LHON shows some overlap with that of autosomal dominant optic atrophy (ADOA), and in both disorders optic nerve dysfunction results from the selective degeneration of the retinal ganglion cell layer.⁸² Therefore, it is of great interest that the causative gene in ADOA has recently been identified as being a dynamin related GTPase, located on chromosome 3q28-29.⁸³⁻⁸⁴ This protein has a highly basic amino-terminal domain that targets it to the mitochondria and preliminary studies in yeast indicate important roles in vesicular transport and outer membrane integrity.⁸⁵⁻⁸⁷ These findings add further weight to the long held view that the maintenance of retinal ganglion cells is heavily dependent upon normal mitochondrial function. The development of faithful animal models will hopefully provide us with a better insight into the still obscure pathophysiology of LHON.

INCOMPLETE PENETRANCE

An intriguing feature of LHON is that only ~50% of males and ~10% of females who harbour one of the three primary mutations actually develop the optic neuropathy.⁵⁻⁸⁸⁻⁹⁰ This incomplete penetrance and predilection for males to lose vision imply that additional genetic and/or environmental factors must modulate the phenotypic expression of LHON. Alternatively, the gender bias could also result from a combination of subtle anatomical, hormonal, and/or physiological variations between males and females.²⁵⁻⁵⁶⁻⁹¹

MITOCHONDRIAL GENETIC FACTORS

Heteroplasmy

In most LHON pedigrees, the primary mutation is homoplasmic (every mtDNA molecule harbours the mutant allele). By contrast, 10-15% of LHON carriers are thought to be heteroplasmic, with one mtDNA subpopulation carrying the wild type allele.⁹⁻⁹² It has been suggested that heteroplasmy might influence the expression and inheritance pattern of LHON but there have been no rigorous prospective studies to address this possibility.⁹³⁻⁹⁷ Preliminary data suggest that heteroplasmy might contribute to incomplete penetrance, with the risk of blindness being minimal if the mutational load is less than 60%.⁹⁸

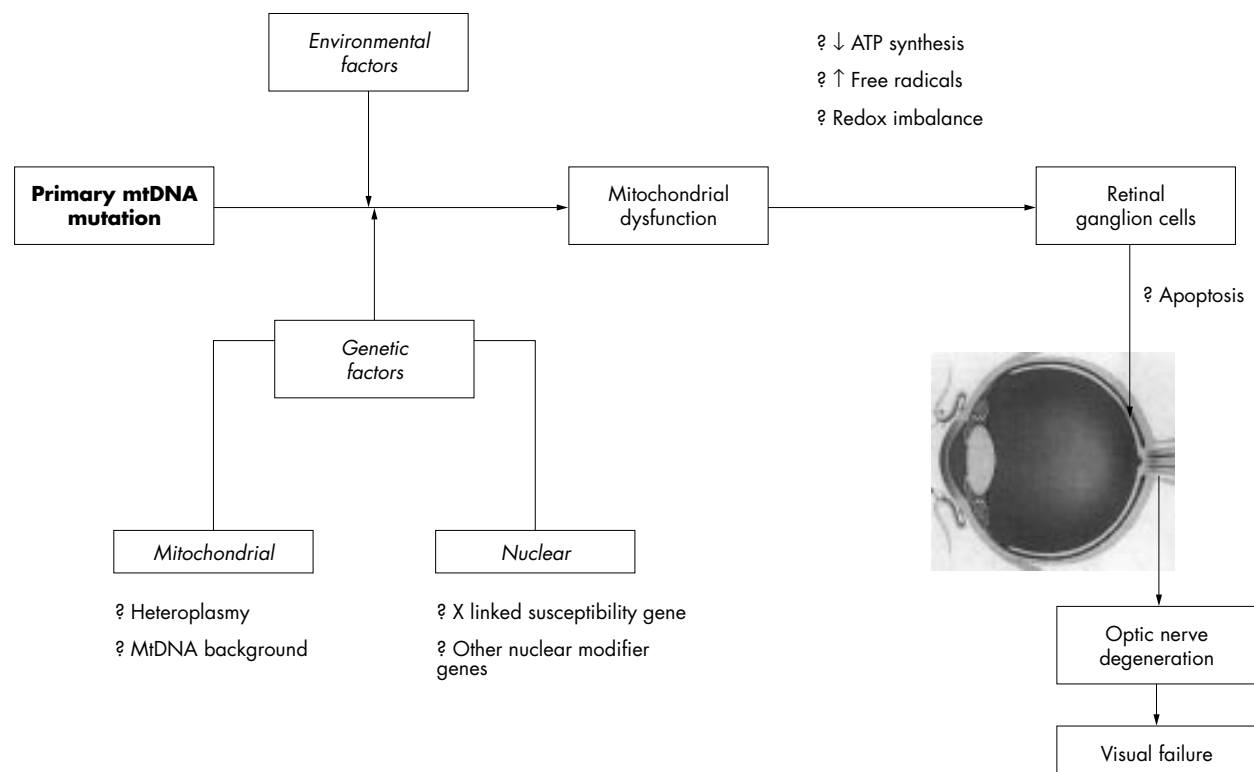


Figure 2 Schematic representation of the pathways leading to optic nerve degeneration in LHON.

MtDNA haplogroups

There still exists some controversy surrounding the pathogenic role of so-called “secondary” mtDNA mutations in LHON: T4216C, A4917G, G9804A, G9438A, G13708A, G15257A, and G15812A.⁹⁹⁻¹⁰¹ These nucleotide substitutions are found at a higher frequency in LHON patients relative to controls and some investigators argue that they act in synergy with the primary mutations, increasing the risk of disease expression. Based on phylogenetic analysis, it has been shown that T4216C, G13708A, G15257A, and G15812A all cluster on a specific mtDNA background, haplogroup J.¹⁰² Several studies have subsequently found that LHON pedigrees, T14484C and to a lesser extent G11778A, are not randomly distributed along the phylogenetic tree but show a strong preferential association with haplogroup J.¹⁰³⁻¹⁰⁵ This could be because of an early founder effect whereby the G11778A and T14484C mutations arose early in the evolution of haplogroup J, leading to its over-representation on that mitochondrial lineage.¹⁰⁶ However, this explanation is unlikely given that it has been shown convincingly that all three primary LHON mutations have arisen multiple times on different mitochondrial backgrounds.¹⁰⁴ Moreover, up to now, none of these mtDNA mutations have been found in normal controls belonging to haplogroup J.

The most compelling explanation is that the risk of visual loss in patients harbouring a primary LHON mutation is increased by haplogroup J and by extension one or more of the polymorphisms that defines it.¹⁰⁷ If this specific mtDNA background does have a deleterious effect, one would expect haplogroup J to result in a more pronounced respiratory chain defect. Cybrid cell lines carrying the G11778A mutation and haplogroup J were shown to have a lower oxygen consumption and a longer doubling time compared to cell lines with the G11778A mutation alone.⁶⁷ However, a recently published study using *in vivo* MRS failed to detect any deleterious effect in brain and skeletal muscle, with haplogroup J not further impairing mitochondrial oxidative metabolism in patients harbouring the G11778A mutation.¹⁰⁸ The influence of haplo-

group J on the biochemical features of the T14484C mutation has not yet been determined. This would be interesting to clarify given the much stronger association of haplogroup J with T14484C compared to G11778A. However, as already mentioned, these biochemical studies are not without their own limitations and require cautious interpretation.

Haplogroup J is one of nine European specific haplogroups and therefore one would expect LHON to be more common in populations of European extraction. However, this hypothesis is difficult to assess given the current paucity of data regarding the prevalence of this mitochondrial disorder in different ethnic groups. Haplogroup J is not thought to influence age of onset or final visual outcome in LHON but this requires further confirmation in a larger LHON cohort.^{30 109} The question also remains as to why G3460A pedigrees do not show a skewed haplogroup distribution. The hypothesis that haplogroup J increases penetrance for the G11778A and T14484C mutations is not widely accepted and further studies are required to clarify matters.

NUCLEAR GENETIC FACTORS

Segregation analysis

The predominance of affected males in LHON cannot be explained by mitochondrial inheritance. Segregation analysis of a large number of pedigrees from diverse ethnic groups suggests the existence of a recessive X linked susceptibility gene acting in synergy with the mtDNA mutation.^{9 110 111} In the Bu and Rotter model,¹¹⁰ development of blindness in males is consistent with the simultaneous inheritance of an X linked visual loss susceptibility allele and the LHON mutation. Females are affected either if they are homozygous at the susceptibility locus (40%) or heterozygous with skewed X chromosome inactivation (60%). The gene frequency for the susceptibility locus was proposed to be 0.08 and the estimated penetrance in a heterozygous female 0.11.

Linkage analysis

Attempts to identify this X linked susceptibility locus by standard linkage analysis have so far been unsuccessful.^{112-114 116} According to the Bu and Rotter model,¹¹⁰ a proportion of heterozygous females will be affected as a result of unfortunate Lyonisation of the "normal" X chromosome. Mathematical modelling suggests that visual loss in women will only occur if at least 60-83% of retinal ganglion cells harbour the visual loss susceptibility allele.¹¹⁷ However, a number of studies have failed to show skewed X chromosome inactivation in the leucocyte fraction of affected female carriers.^{115 118-120} Despite these negative results, it would be premature to conclude that there are no additional nuclear genetic factors modulating the expression of the primary LHON mtDNA mutations. The situation may be highly complex, with the existence of genetic heterogeneity and the epistatic interaction of multiple nuclear susceptibility loci.

ENVIRONMENTAL FACTORS

Five pairs of monozygotic twins harbouring a primary LHON mutation have been reported.^{9 25 28 123-125} In two cases, the twins remained discordant, although there is always the possibility that the unaffected sib will lose vision later on in life. The existence of discordant monozygotic twins does not exclude the possibility of nuclear genetic factors in LHON but strongly suggests that environmental factors also contribute to penetrance. Anecdotal evidence suggests that smoking, alcohol, nutritional deprivation, psychological stress, or acute illness can precipitate the onset of blindness in LHON.^{41 126-131} However, a recently published case-control study failed to confirm the association between heavy smoking or alcohol intake and an increased risk of visual loss.¹³²

Potential environmental triggers have not been extensively investigated because of the logistical problems inherent in the proper conduct of case-control studies for a rare disease. The most obvious limitation of these types of retrospective studies is the possibility of recall bias given that most patients are interviewed several years after they lost vision. This makes it very difficult to obtain reliable data regarding not only possible exposure to environmental triggers but also to quantify their duration and intensity. A possible solution to this problem will be to set up a longitudinal study involving the long term and regular follow up of a large cohort of unaffected LHON carriers. Although an attractive option, this will almost certainly require a multicentre collaborative effort in order to collect a sufficient number of subjects.

CLINICAL MANAGEMENT

Prevention

No generally accepted measures have been shown either to prevent or delay the onset of blindness in LHON. In spite of this, for general health reasons, it would be wise to advise unaffected LHON carriers to moderate their alcohol intake and stop smoking. There is therefore no need for long term follow up of asymptomatic carriers in the clinic.

Treatment

There is currently no treatment available that improves the final visual outcome in LHON. One small, non-randomised trial claimed that oral administration of a quinone analogue (idebedone) and vitamin supplementation (B12 and C) can speed up visual recovery.¹³³ However, more rigorous studies are required before such a regimen can be advocated during the acute phase. The long term management of visually impaired patients is mainly supportive.

GENETIC COUNSELLING

Once a primary LHON mutation has been identified in a proband, other family members can be offered molecular genetic testing to exclude the possibility of a de novo

Table 4 Recurrence risks for relatives of LHON probands

	Risk of visual loss (%)	
	G11778A ⁹	T14484C ¹⁰
Sibs		
Brother	25	28
Sister	8	5
Sister's children		
Nephew	41	30
Niece	17	3
Maternal first cousins		
Male	30	19
Female	7	4

mutation. The latter is exceedingly rare and has only been previously reported for the T14484C mutation.²⁸ We recently confirmed the occurrence of a de novo G3460A mutation in a pedigree from the north east of England (P Y W Man, unpublished data). Since LHON shows strict maternal inheritance, males can be reassured that none of their children will inherit the mtDNA mutation. On the other hand, females will transmit the pathogenic mutation to all of their offspring. Since most mothers are homoplasmic, their children will only harbour the mutant allele and their lifetime risk of losing vision can be derived from established gender and age dependent penetrance figures, as detailed below. The situation is rather more complicated for a heteroplasmic mother given the theoretical possibility that she could transmit only a low level of mutant mtDNA to a particular offspring. However, genetic counselling is not straightforward for unaffected carriers who are found to be heteroplasmic for a primary LHON mutation. Although, there is a suggestion that a mutational threshold of ~60% is necessary for disease expression, it must be stressed these are only preliminary findings and require further confirmation.⁹⁸

Some indication of recurrence risks can be provided to maternal relatives of a LHON proband (table 4). However, robust estimates for the G3460A mutation have not yet been determined in a large number of pedigrees and, although these are unlikely to differ significantly from the G11778A and T14484C mutations, any extrapolation should be done with caution. It is important for LHON carriers to be made aware that it is currently not possible to predict accurately whether or when they will become affected. Despite these caveats, the two main predictive factors for visual failure remain age and gender. Males have a 50% lifetime risk of blindness compared to only 10% for females, but these approximate figures can be further refined based upon the patient's age. From published age dependent penetrance data, we know that most patients experience visual loss in their late teens or early 20s and the probability of becoming affected is minimal once past the age of 50.^{10 31 89}

CONCLUSIONS

LHON is a mitochondrial genetic disease characterised by bilateral subacute loss of central vision owing to focal degeneration of the optic nerve. The vast majority of cases are the result of one of three mtDNA point mutations, G3460A, G11778A, and T14484C, which all involve genes encoding complex I subunits of the respiratory chain. With molecular genetic testing now routinely available, this has greatly facilitated clinical diagnosis, especially in atypical cases. However, many aspects of the complex aetiology of LHON remain poorly defined at present. The incomplete penetrance and sex bias clearly indicate that, although necessary, the mtDNA mutation

is insufficient on its own for disease manifestation. The identification of the secondary factors modulating the phenotypic expression of LHON is currently an area of intense research. Better characterisation of the relationship between mtDNA mutations, mitochondrial biogenesis, and optic nerve dysfunction is also needed to clarify the still unclear pathophysiology of LHON. Progress in all of these areas is a prerequisite for both improved genetic counselling and the development of future therapeutic strategies.

ACKNOWLEDGEMENTS

This work was supported by the Wellcome Trust (PFC, DMT), the Medical Research Council (DMT), and the PPP Healthcare Trust (PYWM). Figure 1 was kindly provided by Mr P G Griffiths.

Authors' affiliations

P Y W Man, D M Turnbull, P F Chinnery, Department of Neurology, School of Neurosciences and Psychiatry, The Medical School, University of Newcastle Upon Tyne, UK

REFERENCES

- Leber T. Ueber hereditäre und congenital angelegte sehnervenleiden. *Graefes Arch Clin Exp Ophthalmol* 1871;17:249-91.
- Bell J. Hereditary optic atrophy (Leber's disease). In: Pearson K, ed. *The treasury of human inheritance*. Cambridge: Cambridge University Press, 1931:345-423.
- Imai Y, Moriwaki D. A probable case of cytoplasmic inheritance in man: a critique of Leber's disease. *J Genet* 1936;33:163-7.
- Lundsgaard R. A genealogic, genetic and clinical study of 101 cases of retrobulbar optic neuritis in 20 Danish families. *Acta Ophthalmol* 1944;21:1-306.
- Van Senus AHC. Leber's disease in the Netherlands. *Doc Ophthalmol* 1963;17:1-162.
- Seedorff T. Leber's disease. *Acta Ophthalmol* 1968;46:4-25.
- Mackey DA, Oostra RJ, Rosenberg T, Nikoskelainen E, Bronte-Stewart J, Poulton J, Harding AE, Govan G, Bolhuis PA, Norby S. Primary pathogenic mtDNA mutations in multigeneration pedigrees with Leber hereditary optic neuropathy. *Am J Hum Genet* 1996;59:481-5.
- Mashima Y, Yamada K, Wakakura M, Kigasawa K, Kudoh J, Shimizu N, Oguchi Y. Spectrum of pathogenic mitochondrial DNA mutations and clinical features in Japanese families with Leber's hereditary optic neuropathy. *Curr Eye Res* 1998;17:403-8.
- Harding AE, Sweeney MG, Govan GG, Riordan-Eva P. Pedigree analysis in Leber hereditary optic neuropathy families with a pathogenic mtDNA mutation. *Am J Hum Genet* 1995;57:77-86.
- Macmillan C, Kirkham T, Fu K, Allison V, Andermann E, Chitayat D, Fortier D, Gans M, Hare H, Quercia N, Zackon D, Shoubridge EA. Pedigree analysis of French Canadian families with T14484C Leber's hereditary optic neuropathy. *Neurology* 1998;50:417-22.
- Macmillan C, Johns TA, Fu K, Shoubridge EA. Predominance of the T14484C mutation in French-Canadian families with Leber hereditary optic neuropathy is due to a founder effect. *Am J Hum Genet* 2000;66:332-5.
- Chinnery PF, Brown DT, Andrews RM, Singh-Kler R, Riordan-Eva P, Lindley J, Applegarth DA, Turnbull DM, Howell N. The mitochondrial ND6 gene is a hot spot for mutations that cause Leber's hereditary optic neuropathy. *Brain* 2001;124:209-18.
- Wallace DC, Singh G, Loit MT, Hodge JA, Schurr TG, Lezza AM, Elsas LJ, Nikoskelainen EK. Mitochondrial DNA mutation associated with Leber's hereditary optic neuropathy. *Science* 1988;242:1427-30.
- Huoponen K, Vilkki J, Aula P, Nikoskelainen EK, Savontaus ML. A new mtDNA mutation associated with Leber hereditary optic neuroretinopathy. *Am J Hum Genet* 1991;48:1147-53.
- Howell N, Bindoff LA, McCullough DA, Kubacka I, Poulton J, Mackey D, Taylor L, Turnbull DM. Leber hereditary optic neuropathy: identification of the same mitochondrial ND1 mutation in six pedigrees. *Am J Hum Genet* 1991;49:939-50.
- Mackey D, Howell N. A variant of Leber hereditary optic neuropathy characterized by recovery of vision and by an unusual mitochondrial genetic etiology. *Am J Hum Genet* 1992;51:1218-28.
- Johns DR, Neufeld MJ, Park RD. An ND-6 mitochondrial DNA mutation associated with Leber hereditary optic neuropathy. *Biochem Biophys Res Commun* 1992;187:1551-7.
- Howell N, Halvorson S, Burns J, McCullough DA, Poulton J. When does bilateral optic atrophy become Leber hereditary optic neuropathy? *Am J Hum Genet* 1993;53:959-63.
- Jun AS, Brown MD, Wallace DC. A mitochondrial DNA mutation at nucleotide pair 14459 of the NADH dehydrogenase subunit 6 gene associated with maternally inherited Leber hereditary optic neuropathy and dystonia. *Proc Natl Acad Sci USA* 1994;91:6206-10.
- Howell N, Bogolin C, Jamieson R, Marena DR, Mackey DA. mtDNA mutations that cause optic neuropathy: how do we know? *Am J Hum Genet* 1998;62:196-202.
- Wissinger B, Besch D, Baumann B, Fauser S, Christ-Adler M, Jurkies B, Zrenner E, Leo-Kotler B. Mutation analysis of the ND6 gene in patients with Lebers hereditary optic neuropathy. *Biochem Biophys Res Commun* 1997;234:511-15.
- De Vries DD, Went LN, Bruyn GW, Scholte HR, Hofstra RM, Bolhuis PA, van Oost BA. Genetic and biochemical impairment of mitochondrial complex I activity in a family with Leber hereditary optic neuropathy and hereditary spastic dystonia. *Am J Hum Genet* 1996;58:703-11.
- Chinnery PF, Johnson MA, Wardell TM, Singh-Kler R, Hayes C, Brown DT, Taylor RW, Bindoff LA, Turnbull DM. The epidemiology of pathogenic mitochondrial DNA mutations. *Ann Neurol* 2000;48:188-93.
- Mackey DA, Buttery RG. Leber hereditary optic neuropathy in Australia. *Aust NZ J Ophthalmol* 1992;20:177-84.
- Newman NJ, Loit MT, Wallace DC. The clinical characteristics of pedigrees of Leber's hereditary optic neuropathy with the 11778 mutation. *Am J Ophthalmol* 1991;111:750-62.
- Johns DR, Smith KH, Miller NR. Leber's hereditary optic neuropathy. Clinical manifestations of the 3460 mutation. *Arch Ophthalmol* 1992;110:1577-81.
- Johns DR, Heher KL, Miller NR, Smith KH. Leber's hereditary optic neuropathy. Clinical manifestations of the 14484 mutation. *Arch Ophthalmol* 1993;111:495-8.
- Biousse V, Brown MD, Newman NJ, Allen JC, Rosenfeld J, Meola G, Wallace DC. De novo 14484 mitochondrial DNA mutation in monozygotic twins discordant for Leber's hereditary optic neuropathy. *Neurology* 1997;49:1136-8.
- Riordan-Eva P, Harding AE. Leber's hereditary optic neuropathy: the clinical relevance of different mitochondrial DNA mutations. *J Med Genet* 1995;32:81-7.
- Nikoskelainen EK, Huoponen K, Juvonen V, Lamminen T, Nummelin K, Savontaus ML. Ophthalmologic findings in Leber hereditary optic neuropathy, with special reference to mtDNA mutations (published erratum appears in *Ophthalmology* 1996;103:998). *Ophthalmology* 1996;103:504-14.
- Riordan-Eva P, Sanders MD, Govan GG, Sweeney MG, Da Costa J, Harding AE. The clinical features of Leber's hereditary optic neuropathy defined by the presence of a pathogenic mitochondrial DNA mutation. *Brain* 1995;118:319-37.
- Harding AE, Sweeney MG, Miller DH, Mumford CJ, Kellar-Wood H, Menard D, McDonald WI, Compston DA. Occurrence of a multiple sclerosis-like illness in women who have a Leber's hereditary optic neuropathy mitochondrial DNA mutation. *Brain* 1992;115:979-89.
- Jansen PH, van der Knaap MS, de Coe IF. Leber's hereditary optic neuropathy with the 11778 mtDNA mutation and white matter disease resembling multiple sclerosis: clinical, MRI and MRS findings. *J Neurol Sci* 1996;135:176-80.
- Kellar-Wood H, Robertson N, Govan GG, Compston DA, Harding AE. Leber's hereditary optic neuropathy mitochondrial DNA mutations in multiple sclerosis. *Ann Neurol* 1994;36:109-12.
- Mojon DS, Fujihara K, Hirano M, Miller C, Lincoff NS, Jacobs LD, Greenberg SJ. Leber's hereditary optic neuropathy mitochondrial DNA mutations in familial multiple sclerosis. *Graefes Arch Clin Exp Ophthalmol* 1999;237:348-50.
- Olsen NK, Hansen AW, Norby S, Edal AL, Jorgensen JR, Rosenberg T. Leber's hereditary optic neuropathy associated with a disorder indistinguishable from multiple sclerosis in a male harbouring the mitochondrial DNA 11778 mutation. *Acta Neurol Scand* 1995;91:326-9.
- Vanopdenbosch L, Dubois B, D'Hooghe MB, Meire F, Carton H. Mitochondrial mutations of Leber's hereditary optic neuropathy: a risk factor for multiple sclerosis. *J Neurol* 2000;247:535-43.
- Smith PR, Cooper JM, Govan GG, Riordan-Eva P, Harding AE, Schapira AH. Antibodies to human optic nerve in Leber's hereditary optic neuropathy. *J Neurol Sci* 1995;130:134-8.
- Chalmers RM, Govan GG, Schapira AH, Harding AE. HLA class I genotypes in Leber's hereditary optic neuropathy. *J Neurol Sci* 1996;135:173-5.
- Govan GG, Smith PR, Kellar-Wood H, Schapira AH, Harding AE. HLA class II genotypes in Leber's hereditary optic neuropathy. *J Neurol Sci* 1994;126:193-6.
- Chalmers RM, Harding AE. A case-control study of Leber's hereditary optic neuropathy. *Brain* 1996;119:1481-6.
- Meire FM, Van Coster R, Cochaux P, Obermaier-Kusser B, Candaele C, Martin JJ. Neurological disorders in members of families with Leber's hereditary optic neuropathy (LHON) caused by different mitochondrial mutations. *Ophthalm Genet* 1995;16:119-26.
- Nikoskelainen EK, Marttila RJ, Huoponen K, Juvonen V, Lamminen T, Sonninen P, Savontaus ML. Leber's "plus": neurological abnormalities in patients with Leber's hereditary optic neuropathy. *J Neurol Neurosurg Psychiatry* 1995;59:160-4.
- Bower SP, Hawley I, Mackey DA. Cardiac arrhythmia and Leber's hereditary optic neuropathy. *Lancet* 1992;339:1427-8.
- Mashima Y, Kigasawa K, Hasegawa H, Tani M, Oguchi Y. High incidence of pre-excitation syndrome in Japanese families with Leber's hereditary optic neuropathy. *Clin Genet* 1996;50:535-7.
- Nikoskelainen EK, Savontaus ML, Huoponen K, Antila K, Hartiala J. Pre-excitation syndrome in Leber's hereditary optic neuropathy. *Lancet* 1994;344:857-8.
- Howell N, Kubacka I, Xu M, McCullough DA. Leber hereditary optic neuropathy: involvement of the mitochondrial ND1 gene and evidence for an intragenic suppressor mutation. *Am J Hum Genet* 1991;48:935-42.

- 48 **Sherman J**, Kleiner L. Visual-system dysfunction in Lebers hereditary optic neuropathy. *Clin Neurosci* 1994;**2**:121-9.
- 49 **Smith JL**, Tse DT, Byrne SF, Johns DR, Stone EM. Optic nerve sheath distention in Leber's optic neuropathy and the significance of the "Wallace mutation". *J Clin Neuroophthalmol* 1990;**10**:231-8.
- 50 **de Gottrau P**, Buchi ER, Daicker B. Distended optic nerve sheaths in Leber's hereditary optic neuropathy. *J Clin Neuroophthalmol* 1992;**12**:89-93.
- 51 **Doti MT**, Caputo N, Signorini E, Federico A. Magnetic resonance imaging findings in Leber's hereditary optic neuropathy. *Eur Neurol* 1992;**32**:17-19.
- 52 **Mashima Y**, Oshitari K, Imamura Y, Momoshima S, Shiga H, Oguchi Y. Orbital high resolution magnetic resonance imaging with fast spin echo in the acute stage of Leber's hereditary optic neuropathy. *J Neurol Neurosurg Psychiatry* 1998;**64**:124-7.
- 53 **Vaphiades MS**, Newman J. Optic nerve enhancement on orbital magnetic resonance imaging in Leber's hereditary optic neuropathy. *J Neuroophthalmol* 1999;**19**:238-9.
- 54 **Inglese M**, Rovaris M, Bianchi S, Mancardi GL, Ghezzi A, Salvi F, Cortelli P, Filippi M. MRI, MTI, and DWI study of the optic nerve, brain, and cervical cord from patients with Leber hereditary optic neuropathy. *Neurology* 2000;**54**:A320.
- 55 **Saadati HG**, Hsu HY, Heller KB, Sadun AA. A histopathologic and morphometric differentiation of nerves in optic nerve hypoplasia and Leber hereditary optic neuropathy. *Arch Ophthalmol* 1998;**116**:911-16.
- 56 **Sadun AA**, Dao J. Annual review in neuro-ophthalmology. The anterior visual pathways. *J Neuroophthalmol* 1994;**14**:141-54.
- 57 **Kwitken J**, Barest HD. The neuropathology of hereditary optic atrophy (Leber's disease): the first complete anatomic study. *Am J Ophthalmol* 1958;**34**:185-207.
- 58 **Adams JH**, Blackwood W, Wilson J. Further clinical and pathological observations on Leber's optic atrophy. *Brain* 1966;**89**:15-26.
- 59 **Howell N**. Leber hereditary optic neuropathy: mitochondrial mutations and degeneration of the optic nerve. *Vision Res* 1997;**37**:3495-507.
- 60 **Parker WD Jr**, Oley CA, Parks JK. A defect in mitochondrial electron-transport activity (NADH-coenzyme Q oxidoreductase) in Leber's hereditary optic neuropathy. *N Engl J Med* 1989;**320**:1331-3.
- 61 **Majander A**, Huoponen K, Savontaus ML, Nikoskelainen E, Wikstrom M. Electron transfer properties of NADH:ubiquinone reductase in the ND1/3460 and the ND4/11778 mutations of the Leber hereditary optic neuropathy (LHON). *FEBS Lett* 1991;**292**:289-92.
- 62 **Larsson NG**, Andersen O, Holme E, Oldfors A, Wahlstrom J. Leber's hereditary optic neuropathy and complex I deficiency in muscle. *Ann Neurol* 1991;**30**:701-8.
- 63 **Smith PR**, Cooper JM, Govan GG, Harding AE, Schapira AH. Platelet mitochondrial function in Leber's hereditary optic neuropathy. *J Neurol Sci* 1994;**122**:80-3.
- 64 **Degli Esposti M**, Carelli V, Ghelli A, Ratta M, Crimi M, Sangiorgi S, Montagna P, Lenaz G, Liguori E, Cortelli P. Functional alterations of the mitochondrially encoded ND4 subunit associated with Leber's hereditary optic neuropathy. *FEBS Lett* 1994;**352**:375-9.
- 65 **Cock HR**, Cooper JM, Schapira AH. The 14484 ND6 mtDNA mutation in Leber hereditary optic neuropathy does not affect fibroblast complex I activity. *Am J Hum Genet* 1995;**57**:1501-2.
- 66 **Oostra RJ**, Van Galen MJ, Bolhuis PA, Bleeker-Wagemakers EM, Van den Bogert C. The mitochondrial DNA mutation ND6*14,484C associated with Leber hereditary optic neuropathy, leads to deficiency of complex I of the respiratory chain. *Biochem Biophys Res Commun* 1995;**215**:1001-5.
- 67 **Vergani L**, Martinuzzi A, Carelli V, Cortelli P, Montagna P, Schievano G, Carozzo R, Angelini C, Liguori E. MtDNA mutations associated with Leber's hereditary optic neuropathy: studies on cytoplasmic hybrid (cybrid) cells. *Biochem Biophys Res Commun* 1995;**210**:880-8.
- 68 **Montagna P**, Plazzi G, Cortelli P, Carelli V, Liguori E, Barboni P, Focci M. Abnormal lactate after effort in healthy carriers of Leber's hereditary optic neuropathy. *J Neurol Neurosurg Psychiatry* 1995;**58**:640-1.
- 69 **Majander A**, Finel M, Savontaus ML, Nikoskelainen E, Wikstrom M. Catalytic activity of complex I in cell lines that possess replacement mutations in the ND genes in Leber's hereditary optic neuropathy. *Eur J Biochem* 1996;**239**:201-7.
- 70 **Hofhaus G**, Johns DR, Hurko O, Attardi G, Chomyn A. Respiration and growth defects in trans-mitochondrial cell lines carrying the 11778 mutation associated with Leber's hereditary optic neuropathy. *J Biol Chem* 1996;**271**:13155-61.
- 71 **Carelli V**, Ghelli A, Ratta M, Bacchilega E, Sangiorgi S, Mancini R, Leuzzi V, Cortelli P, Montagna P, Liguori E, Degli Esposti M. Leber's hereditary optic neuropathy: biochemical effect of 11778/ND4 and 3460/ND1 mutations and correlation with the mitochondrial genotype. *Neurology* 1997;**48**:1623-32.
- 72 **Cock HR**, Tabrizi SJ, Cooper JM, Schapira AH. The influence of nuclear background on the biochemical expression of 3460 Leber's hereditary optic neuropathy. *Ann Neurol* 1998;**44**:187-93.
- 73 **Cock HR**, Cooper JM, Schapira AH. Functional consequences of the 3460-bp mitochondrial DNA mutation associated with Leber's hereditary optic neuropathy. *J Neurol Sci* 1999;**165**:10-17.
- 74 **Brown MD**, Trounce IA, Jun AS, Allen JC, Wallace DC. Functional analysis of lymphoblast and cybrid mitochondria containing the 3460, 11778, or 14484 Leber's hereditary optic neuropathy mitochondrial DNA mutation. *J Biol Chem* 2000;**275**:39831-6.
- 75 **Cortelli P**, Montagna P, Avoni P, Sangiorgi S, Bresolin N, Maggio M, Zaniol P, Mantovani V, Barboni P, Barbiroli B, Liguori E. Leber's hereditary optic neuropathy: genetic, biochemical, and phosphorus magnetic resonance spectroscopy study in an Italian family. *Neurology* 1991;**41**:1211-15.
- 76 **Barbiroli B**, Montagna P, Cortelli P, Iotti S, Lodi R, Barboni P, Monari L, Liguori E, Frassinetti C, Zaniol P. Defective brain and muscle energy metabolism shown by in vivo 31P magnetic resonance spectroscopy in nonaffected carriers of 11778 mtDNA mutation. *Neurology* 1995;**45**:1364-9.
- 77 **Lodi R**, Taylor DJ, Tabrizi SJ, Kumar S, Sweeney M, Wood NW, Styles P, Radda GK, Schapira AH. In vivo skeletal muscle mitochondrial function in Leber's hereditary optic neuropathy assessed by P-31 magnetic resonance spectroscopy. *Ann Neurol* 1997;**42**:573-9.
- 78 **Andrews RM**, Griffiths PG, Johnson MA, Turnbull DM. Histochemical localisation of mitochondrial enzyme activity in human optic nerve and retina. *Br J Ophthalmol* 1999;**83**:231-5.
- 79 **Lowry O**, Roberts NR, Lewis C. The quantitative histochemistry of the retina. *J Biol Chem* 1956;**220**:879-92.
- 80 **Kageyama GH**, Wong-Riley MT. The histochemical localization of cytochrome oxidase in the retina and lateral geniculate nucleus of the ferret, cat, and monkey, with particular reference to retinal mosaics and ON/OFF-center visual channels. *J Neurosci* 1984;**4**:2445-59.
- 81 **Klivenyi P**, Karg E, Rozsa C, Horvath R, Komoly S, Nemeth I, Turi S, Vecsei L. Alpha-tocopherol/lipid ratio in blood is decreased in patients with Leber's hereditary optic neuropathy and asymptomatic carriers of the 11778 mtDNA mutation. *J Neurol Neurosurg Psychiatry* 2001;**70**:359-62.
- 82 **Kjer B**, Eiberg H, Kjer P, Rosenberg T. Dominant optic atrophy mapped to chromosome 3q region. II. Clinical and epidemiological aspects. *Acta Orthop Scand* 1996;**74**:3-7.
- 83 **Delettre C**, Lenaers G, Griffioen JM, Gigarel N, Lorenzo C, Belenguer P, Pelloquin L, Grosgeorge J, Turc-Carel C, Perret E, Astarie-Dequeker C, Lasquellèc L, Arnaud B, Ducommun B, Kaplan J, Hamel CP. Nuclear gene OPA1, encoding a mitochondrial dynamin-related protein, is mutated in dominant optic atrophy. *Nat Genet* 2000;**26**:207-10.
- 84 **Alexander C**, Votruba M, Pesch UE, Thiselton DL, Mayer S, Moore A, Rodriguez M, Kellner U, Leo-Kottler B, Auburger G, Bhattacharya SS, Wissinger B. OPA1, encoding a dynamin-related GTPase, is mutated in autosomal dominant optic atrophy linked to chromosome 3q28. *Nat Genet* 2000;**26**:211-15.
- 85 **Pelloquin L**, Belenguer P, Menon Y, Ducommun B. Identification of a fission yeast dynamin-related protein involved in mitochondrial DNA maintenance. *Biochem Biophys Res Commun* 1998;**251**:720-6.
- 86 **van der Bliek AM**. Functional diversity in the dynamin family. *Trends Cell Biol* 1999;**9**:96-102.
- 87 **Labrousse AM**, Zappaterra MD, Rube DA, van der Bliek AM. C elegans dynamin-related protein DRP-1 controls severing of the mitochondrial outer membrane. *Mol Cell* 1999;**4**:815-26.
- 88 **Seedorff T**. The inheritance of Leber's disease. A genealogical follow-up study. *Acta Ophthalmol* 1985;**63**:135-45.
- 89 **Nikoskelainen EK**. Clinical picture of LHON. *Clin Neurosci* 1994;**2**:115-20.
- 90 **Brown MD**, Wallace DC. Spectrum of mitochondrial-DNA mutations in Lebers hereditary optic neuropathy. *Clin Neurosci* 1994;**2**:138-45.
- 91 **Hollander H**, Makarov F, Stefani FH, Stone J. Evidence of constriction of optic nerve axons at the lamina cribrosa in the normotensive eye in humans and other mammals. *Ophthalmol Res* 1995;**27**:296-309.
- 92 **Smith KH**, Johns DR, Heher KL, Miller NR. Heteroplasmy in Leber's hereditary optic neuropathy. *Arch Ophthalmol* 1993;**111**:1486-90.
- 93 **Zhu DP**, Economou EP, Antonarakis SE, Maumenee IH. Mitochondrial DNA mutation and heteroplasmy in type I Leber hereditary optic neuropathy. *Am J Med Genet* 1992;**42**:173-9.
- 94 **Yen MY**, Yen TC, Pang CY, Liu JH, Wei YH. Mitochondrial DNA mutation in Leber's hereditary optic neuropathy. *Invest Ophthalmol Vis Sci* 1992;**33**:2561-6.
- 95 **Barboni P**, Mantovani V, Montagna P, Braglini M, Cortelli P, Liguori E, Puddu P, Caramazza R. Mitochondrial DNA analysis in Leber's hereditary optic neuropathy. *Ophthalmol Pediatr Genet* 1992;**13**:219-26.
- 96 **Black GC**, Morten K, Laborde A, Poulton J. Leber's hereditary optic neuropathy: heteroplasmy is likely to be significant in the expression of LHON in families with the 3460 ND1 mutation. *Br J Ophthalmol* 1996;**80**:915-17.
- 97 **Tanaka A**, Kiyosawa M, Mashima Y, Tokoro T. A family with Leber's hereditary optic neuropathy with mitochondrial DNA heteroplasmy related to disease expression. *J Neuroophthalmol* 1998;**18**:81-3.
- 98 **Chinnery PF**, Andrews RM, Turnbull DM, Howell N. Leber hereditary optic neuropathy: does heteroplasmy influence the inheritance and expression of the G11778A mitochondrial DNA mutation? *Am J Med Genet* (in press).
- 99 **Johns DR**, Berman J. Alternative, simultaneous complex I mitochondrial DNA mutations in Leber's hereditary optic neuropathy. *Biochem Biophys Res Commun* 1991;**174**:1324-30.
- 100 **Johns DR**, Neufeld MJ. Cytochrome b mutations in Leber hereditary optic neuropathy. *Biochem Biophys Res Commun* 1991;**181**:1358-64.
- 101 **Johns DR**, Neufeld MJ. Cytochrome c oxidase mutations in Leber hereditary optic neuropathy. *Biochem Biophys Res Commun* 1993;**196**:810-15.
- 102 **Torroni A**, Wallace DC. Mitochondrial DNA variation in human populations and implications for detection of mitochondrial DNA mutations of pathological significance. *J Bioenerg Biomembr* 1994;**26**:261-71.
- 103 **Brown MD**, Torroni A, Reckord CL, Wallace DC. Phylogenetic analysis of Leber's hereditary optic neuropathy mitochondrial DNA's indicates

- multiple independent occurrences of the common mutations. *Hum Mutat* 1995;**6**:311-25.
- 104 **Torroni A**, Petrozzi M, D'Urbano L, Sellitto D, Zeviani M, Carrara F, Carducci C, Leuzzi V, Carelli V, Barboni P, De Negri A, Scozzari R. Haplotype and phylogenetic analyses suggest that one European-specific mtDNA background plays a role in the expression of Leber hereditary optic neuropathy by increasing the penetrance of the primary mutations 11778 and 14484. *Am J Hum Genet* 1997;**60**:1107-21.
- 105 **Brown MD**, Sun F, Wallace DC. Clustering of Caucasian Leber hereditary optic neuropathy patients containing the 11778 or 14484 mutations on an mtDNA lineage. *Am J Hum Genet* 1997;**60**:381-7.
- 106 **Howell N**, Kubacka I, Halvorson S, Howell B, McCullough DA, Mackey D. Phylogenetic analysis of the mitochondrial genomes from Leber hereditary optic neuropathy pedigrees. *Genetics* 1995;**140**:285-302.
- 107 **Finnila S**, Majamaa K. Phylogenetic analysis of mtDNA haplogroup T1 in a Finnish population. *J Hum Genet* 2001;**46**:64-9.
- 108 **Lodi R**, Montagna P, Cortelli P, Iotti S, Cevoli S, Carelli V, Barbiroli B. 'Secondary' 4216/ND1 and 13708/ND5 Leber's hereditary optic neuropathy mitochondrial DNA mutations do not further impair in vivo mitochondrial oxidative metabolism when associated with the 11778/ND4 mitochondrial DNA mutation. *Brain* 2000;**123**:1896-902.
- 109 **Oostra RJ**, Bolhuis PA, Zorn-Ende I, de Kok-Nazark MM, Bleeker-Wagemakers EM. Leber's hereditary optic neuropathy: no significant evidence for primary or secondary pathogenicity of the 15257 mutation. *Hum Genet* 1994;**94**:265-70.
- 110 **Bu XD**, Rotter JL. X chromosome-linked and mitochondrial gene control of Leber hereditary optic neuropathy: evidence from segregation analysis for dependence on X chromosome inactivation. *Proc Natl Acad Sci USA* 1991;**88**:8198-202.
- 111 **Nakamura M**, Fujiwara Y, Yamamoto M. The two locus control of Leber hereditary optic neuropathy and a high penetrance in Japanese pedigrees. *Hum Genet* 1993;**91**:339-41.
- 112 **Chen JD**, Cox I, Denton MJ. Preliminary exclusion of an X-linked gene in Leber optic atrophy by linkage analysis. *Hum Genet* 1989;**82**:203-7.
- 113 **Carvalho MR**, Muller B, Rotzer E, Berninger T, Kommerell G, Blankenagel A, Savontaus ML, Meitinger T, Lorenz B. Leber's hereditary optic neuroretinopathy and the X-chromosomal susceptibility factor: no linkage to DXs7. *Hum Hered* 1992;**42**:316-20.
- 114 **Sweeney MG**, Davis MB, Lashwood A, Brockington M, Toscano A, Harding AE. Evidence against an X-linked locus close to DXS7 determining visual loss susceptibility in British and Italian families with Leber hereditary optic neuropathy. *Am J Hum Genet* 1992;**51**:741-8.
- 115 **Chalmers RM**, Davis MB, Sweeney MG, Wood NW, Harding AE. Evidence against an X-linked visual loss susceptibility locus in Leber hereditary optic neuropathy. *Am J Hum Genet* 1996;**59**:103-8.
- 116 **Handoko HY**, Wirapati PJ, Sudoyo HA, Sitepu M, Marzuki S. Meiotic breakpoint mapping of a proposed X linked visual loss susceptibility locus in Leber's hereditary optic neuropathy. *J Med Genet* 1998;**35**:668-71.
- 117 **Bu X**, Rotter JL. Leber hereditary optic neuropathy: estimation of number of embryonic precursor cells and disease threshold in heterozygous affected females at the X-linked locus. *Clin Genet* 1992;**42**:143-8.
- 118 **Pegoraro E**, Schimke RN, Garcia C, Stern H, Cadaldini M, Angelini C, Barbosa E, Carroll J, Marks WA, Neville HE. Genetic and biochemical normalization in female carriers of Duchenne muscular dystrophy: evidence for failure of dystrophin production in dystrophin-competent myonuclei. *Neurology* 1995;**45**:677-90.
- 119 **Pegoraro E**, Carelli V, Zeviani M, Cortelli P, Montagna P, Barboni P, Angelini C, Hoffman EP. X-inactivation patterns in female Leber's hereditary optic neuropathy patients do not support a strong X-linked determinant. *Am J Med Genet* 1996;**61**:356-62.
- 120 **Oostra RJ**, Kemp S, Bolhuis PA, Bleeker-Wagemakers EM. No evidence for 'skewed' inactivation of the X-chromosome as cause of Leber's hereditary optic neuropathy in female carriers. *Hum Genet* 1996;**97**:500-5.
- 121 **Gale RE**, Wheadon H, Boulos P, Linch DC. Tissue specificity of X-chromosome inactivation patterns. *Blood* 1994;**83**:2899-905.
- 122 **Sharp A**, Robinson D, Jacobs P. Age- and tissue-specific variation of X chromosome inactivation ratios in normal women. *Hum Genet* 2000;**107**:343-9.
- 123 **Nikoskelainen EK**, Savontaus ML, Wanne OP, Katila MJ, Nummelin KU. Leber's hereditary optic neuroretinopathy, a maternally inherited disease. A genealogic study in four pedigrees. *Arch Ophthalmol* 1987;**105**:665-71.
- 124 **Johns DR**, Smith KH, Miller NR, Sulewski ME, Bias WB. Identical twins who are discordant for Leber's hereditary optic neuropathy. *Arch Ophthalmol* 1993;**111**:1491-4.
- 125 **Lam BL**. Identical twins no longer discordant for Leber's hereditary optic neuropathy. *Arch Ophthalmol* 1998;**116**:956-7.
- 126 **Hwang JM**, Park HW. Carbon monoxide poisoning as an epigenetic factor for Leber's hereditary optic neuropathy. *Korean J Ophthalmol* 1996;**10**:122-3.
- 127 **Tsao K**, Aitken PA, Johns DR. Smoking as an aetiological factor in a pedigree with Leber's hereditary optic neuropathy. *Br J Ophthalmol* 1999;**83**:577-81.
- 128 **DuBois LG**, Feldon SE. Evidence for a metabolic trigger for Leber's hereditary optic neuropathy. A case report. *J Clin Neuroophthalmol* 1992;**12**:15-16.
- 129 **Cullom ME**, Heher KL, Miller NR, Savino PJ, Johns DR. Leber's hereditary optic neuropathy masquerading as tobacco-alcohol amblyopia. *Arch Ophthalmol* 1993;**111**:1482-5.
- 130 **Golnik KC**, Schaible ER. Folate-responsive optic neuropathy. *J Neuroophthalmol* 1994;**14**:163-9.
- 131 **Shaikh S**, Ta C, Basham AA, Mansour S. Leber hereditary optic neuropathy associated with antiretroviral therapy for human immunodeficiency virus infection. *Am J Ophthalmol* 2001;**131**:143-5.
- 132 **Kerrison JB**, Miller NR, Hsu F, Beaty TH, Maumenee IH, Smith KH, Savino PJ, Stone EM, Newman NJ. A case-control study of tobacco and alcohol consumption in Leber hereditary optic neuropathy. *Am J Ophthalmol* 2000;**130**:803-12.
- 133 **Mashima Y**, Kigasawa K, Wakakura M, Oguchi Y. Do idebenone and vitamin therapy shorten the time to achieve visual recovery in Leber hereditary optic neuropathy? *J Neuroophthalmol* 2000;**20**:166-70.