

## SHORT REPORT

# Novel autosomal dominant mandibulofacial dysostosis with ptosis: clinical description and exclusion of *TCOF1*

P Hedera, H V Toriello, E M Petty

*J Med Genet* 2002;**39**:484–488

**Background:** Treacher Collins syndrome (TCS), the most common type of mandibulofacial dysostosis (MFD), is genetically homogeneous. Other types of MFD are less common and, of these, only the Bauru type of MFD has an autosomal dominant (AD) mode of inheritance established. Here we report clinical features of a kindred with a unique AD MFD with the exclusion of linkage to the TCS locus (*TCOF1*) on chromosome 5q31-q32.

**Methods:** Six affected family members underwent a complete medical genetics physical examination and two affected subjects had skeletal survey. All available medical records were reviewed. Linkage analysis using the markers spanning the *TCOF1* locus was performed. One typically affected family member had a high resolution karyotype.

**Results:** Affected subjects had significant craniofacial abnormalities without any significant acral changes and thus had a phenotype consistent with a MFD variant. Distinctive features included hypoplasia of the zygomatic complex, micrognathia with malocclusion, auricular abnormalities with conductive hearing loss, and ptosis. Significantly negative two point lod scores were obtained for markers spanning the *TCOF1* locus, excluding the possibility that the disease in our kindred is allelic with TCS. High resolution karyotype was normal.

**Conclusions:** We report a kindred with a novel type of MFD that is not linked to the *TCOF1* locus and is also clinically distinct from other types of AD MFD. Identification of additional families will facilitate identification of the gene causing this type of AD MFD and further characterisation of the clinical phenotype.

Mandibulofacial dysostosis (MFD) is a genetically heterogeneous group of disorders with abnormal craniofacial development that is not associated with any limb anomalies. Treacher Collins syndrome (TCS), caused by mutations in the *treacle* gene mapped to 5q31-32, is the most common type of MFD.<sup>1</sup> It is characterised by hypoplasia of the mandible and zygomatic bones, downward slanting palpebral fissures with lower lid colobomas, abnormalities of the pinna, and conductive hearing loss; these changes are typically bilateral and symmetrical.<sup>2</sup> Genetic analysis of TCS kindreds suggested genetic homogeneity of this entity.<sup>3-5</sup> However, several case reports described patients with various chromosomal abnormalities suggesting additional loci for MFD on chromosomes 3p23-24.12, 4p15.32-14, and 5q11.<sup>6-8</sup> Additional types of MFD have been reported; however, only the Bauru type of MFD is clearly established to have autosomal dominant (AD) inheritance.<sup>9</sup>

Here we report a kindred with AD mode of inheritance where affected subjects manifest MFD with various degrees of hypoplasia of the zygomatic complex, micrognathia with malocclusion, auricular abnormalities with conductive hearing loss, and ptosis. To determine if this phenotype represents

an atypical allelic variant of TCS type of MFD, we performed linkage analysis using markers linked to the TCS locus (*TCOF1*) on chromosome 5q31-q32 and excluded linkage to this locus. We propose that this is a novel type of AD MFD, further supporting genetic heterogeneity of this condition.

## METHODS

### Patients

This study was approved and informed consent obtained as specified by the Institutional Review Board at the University of Michigan Medical Center. Six affected family members (IV.1, IV.5, V.1, V.3, V.4, and V.5, fig 1) underwent complete medical genetics physical examinations. All available medical records were reviewed. We also analysed the photographs of these patients that were taken before surgical procedures, photographs of a subject who had died, II.9 (affected), and living subjects III.2 (affected), IV.3 (unaffected), and V.2 (unaffected), who were not available for examination. In addition, V.3 and V.4 had skeletal surveys and a high resolution karyotype was obtained from subject V.5.

### Genetic analysis

We examined genetic linkage to the locus *TCOF1* to exclude an atypical form of TCS. Eight markers (SPARC.PCR, D5S402, D5S210, D5S519, D5S412, D5S434, D5S378, and D5S403) that were previously shown to be linked in families with TCS were genotyped.<sup>5, 10</sup> We included six affected subjects (IV.1, IV.5, V.1, V.3, V.4, and V.5, fig 1) and a married in spouse, IV.6, in the genetic analysis. DNA was extracted from peripheral blood leucocytes. Microsatellite DNA polymorphisms were amplified by the polymerase chain reaction according to standard procedures. Amplifications were performed in 25 µl volumes in 96 well trays using MJ Research thermocyclers for 35 cycles. One primer was labelled with 32-dATP using T4 polynucleotide kinase. Amplified DNA was electrophoresed on 7% polyacrylamide/6 mol/l urea-formamide gels and alleles were scored from autoradiographs.

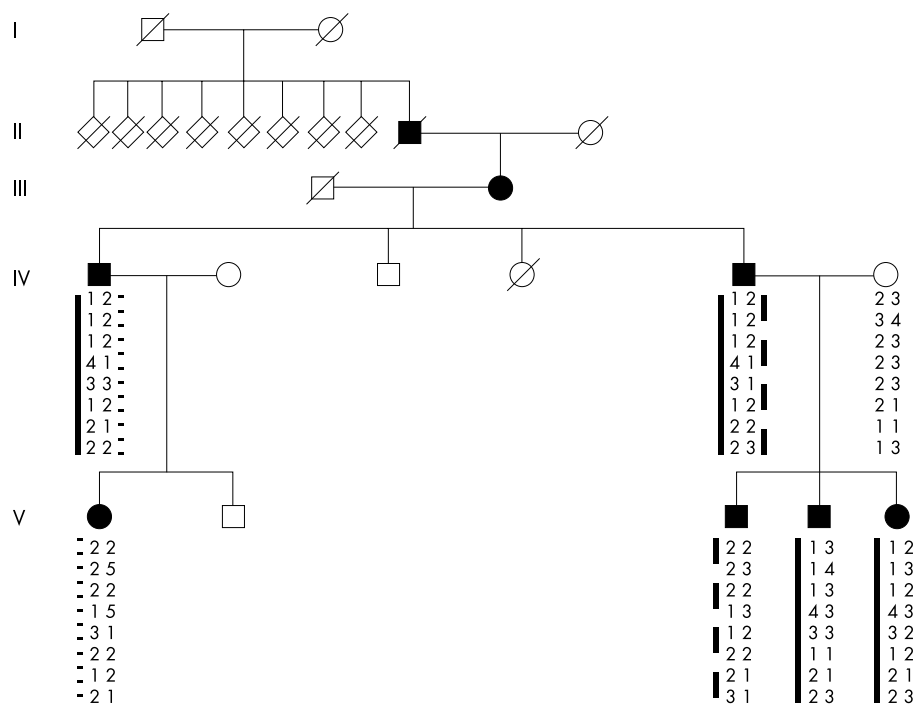
Two point linkage analyses were performed with the MLINK subroutine of the LINKAGE program using an autosomal dominant model of disease inheritance and disease allele frequency of 0.001.<sup>11</sup> We assigned genetic penetrance 0.90 for lod score calculations. Marker allele frequencies were not calculated from this family (since only one unrelated spouse was available) but instead were assumed to be equal.

## RESULTS

### Pedigree analysis

Pedigree analysis (fig 1) is consistent with transmission of a single gene, highly penetrant, autosomal dominant disorder. There are no significant differences between clinical severity

**Abbreviations:** TCS, Treacher Collins syndrome; MFD, mandibulofacial dysostosis; AD, autosomal dominant; EAC, external auricular canal



**Figure 1** Pedigree of the family with a novel type of mandibulofacial dysostosis. Haplotype analysis of six markers linked to the *TCOF1* locus (SPARC.PCR, D5S402, D5S210, D5S519, D5S412, D5S434, D5S378, and D5S403) identified three chromosomes, symbolised by full, dotted, and dashed lines that were inherited by affected subjects IV.1 and IV.5; their phase could not be determined because DNA from subjects III.1 and III.2 was not available. Affected offspring V.1, V.2, V.3, and V.4 inherited all three chromosomes from their affected fathers, excluding linkage to chromosome 5q31-32.

in males and females and they are affected with similar frequency. Two instances of male to male transmission (IV.6 to V.3 and V.4) exclude X linked inheritance. Review of an old family photograph (not shown) of II.9 together with his seven sibs and parents showed severe, bilateral ptosis and a small jaw at approximately 30 years of age. The appearance of other family members was unremarkable. He was the youngest of nine children and paternal and maternal ages are unknown. Even though non-paternity cannot be excluded, this is suggestive of a new mutation event in this subject.

#### Phenotype analysis

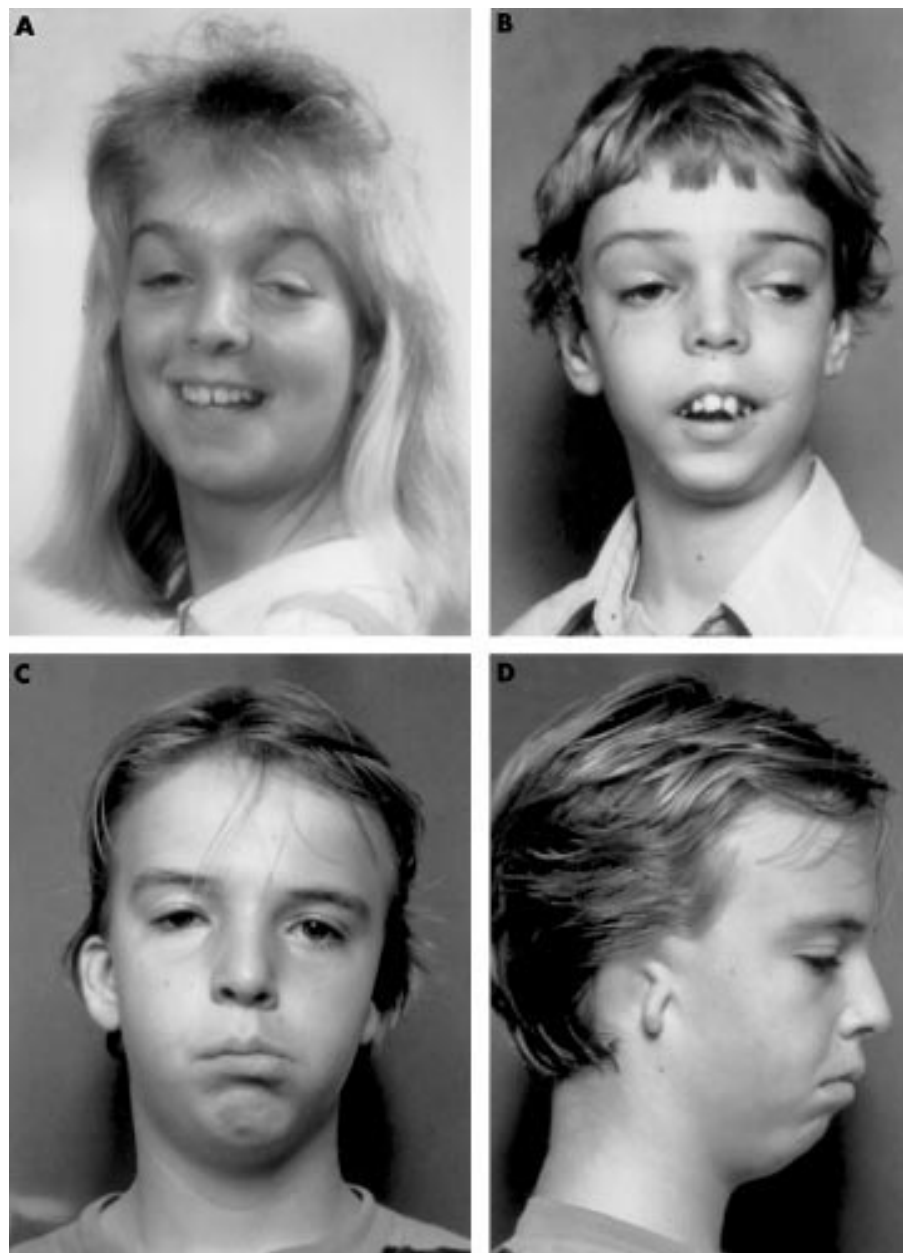Table 1 summarises the phenotypic features of six examined subjects. Every affected subject had downward slanting

palpebral fissures and bilateral congenital ptosis. Surgical correction was indicated in V.3, V.4, and V.5 (fig 2A-C). Downward slanting palpebral fissures and bilateral ptosis were also prominent in II.9 and III.2 based on review of photographs. Malar hypoplasia and micrognathia resulting in malocclusion was also a constant feature, even though its degree varied from mild to moderate among affected subjects (fig 2B, C). Surgery for micrognathia was necessary in four subjects and one required a long term tracheostomy (IV.1). Four affected subjects (IV.1, IV.5, V.1, and V.3) had unilateral anotia with only a rudimentary tag present and with complete atresia of the external auditory canal (EAC); no blind fistulas were detected (fig 2D). The contralateral ear in these subjects was unremarkable with the exception of IV.1 who had a small,

**Table 1** Phenotypic features of affected subjects

|                                      | IV.1  | IV.5   | V.1  | V.3  | V.4   | V.5  |
|--------------------------------------|---|--|--|--|---|--|
| Ptosis                               | +<br>Bilateral, mild  | +<br>Bilateral, moderate   | +<br>Bilateral, mild   | +<br>Bilateral, severe (surgery)   | +<br>Bilateral, severe (surgery)                    | +<br>Bilateral, severe (surgery)                     |
| Downward slanting palpebral fissures | +   | +  | +  | +  | +   | +  |
| Malar hypoplasia                     | +   | +  | +  | +  | +   | +  |
| Micrognathia                         | +   | +  | +  | +  | +   | +  |
| Malocclusion                         | Severe, required tracheostomy   | Mild, no surgery   | Mild, no surgery   | Moderate, required surgery   | Moderate, required surgery                          | Moderate, required surgery                           |
| Malformation of auricle              | +   | +  | +  | +  | +   | +  |
| Hearing loss                         | Right rudimentary tag and EAC atresia<br>Left ear small, cupped with EAC stenosis | Right rudimentary tag and EAC atresia<br>Left ear normal with EAC stenosis | Right rudimentary tag and EAC atresia<br>Left ear normal with EAC stenosis | Left rudimentary tag and EAC atresia<br>Right ear normal with EAC stenosis | Both ears unremarkable<br>Bilateral stenosis of EAC | Both ears unremarkable,<br>Bilateral stenosis of EAC |
|                                      | +   | +  | +  | +  | +   | +  |
|                                      | Bilateral conductive hearing loss   | Left conductive hearing loss   | Left ear normal hearing  | Right ear conductive hearing loss  | Bilateral conductive hearing loss                   | Bilateral conductive hearing loss                    |

EAC=external auditory canal.



**Figure 2** (A) Subject V.5 with prominent, bilateral ptosis and downward slanting palpebral fissures. (B) Subject V.4 with bilateral ptosis, malar hypoplasia, and malocclusion. (C) Subject V.3 with mild facial asymmetry on the left and malocclusion. (D) Subject V.3 with unilateral anotia with a rudimentary ear and micrognathia. Note the absence of the lateral propagation of hair onto the cheeks.

cupped ear. All four subjects with unilateral anotia had signs of contralateral EAC stenosis and conductive hearing loss. The other two subjects (V.4 and V.5) had unremarkable auricles; however, symmetrical bilateral EAC stenosis and conductive hearing loss were also present in both subjects without anotia. Small, cupped ears without unilateral anotia and severe hearing loss were reported for II.9 and III.2.

None of the affected subjects had microphthalmia, epibulbar lipodermoid, upper or lower lid colobomas, partial absence of the lower eyelashes, propagation of hair onto the cheeks, or macrostomia. We did not observe unilateral hypoplasia of the facial muscles in affected subjects with facial asymmetry.

Clinical examination of the skeletal system did not show any abnormalities in IV.1, IV.5, or V.1. No vertebral anomalies were present on *x* rays obtained in two affected subjects, V.3 and V.4, and the rest of their skeletal surveys were also normal. V.5 had nail hypoplasia on both fifth toes and mild scoliosis, to

the left, of the thoracic spine. Both of her brothers, V.3 and V.4, had mild camptodactyly of the fourth and fifth fingers on both hands and increased laxity of the distal interphalangeal joints of all fingers. All three also had mild soft tissue syndactyly of the fingers and a sandal gap between toes 1 and 2. There was hallux valgus of the big toe in all three and V.3 and V.4 also had a short distal phalanx of the big toe. V.3 also had mild pectus carinatum.

A review of the past medical history of affected family members did not show any associated medical problems that were present in every affected subject. All affected family members had normal psychomotor development and normal intelligence with the exception of subject V.4 who had delayed speech acquisition and started to talk at the age of 7 years. However, at the same age he was diagnosed with severe hearing loss that had not been suspected previously. He was also diagnosed with learning disabilities but graduated from high

school and enrolled in a community college. Subject III.2 developed difficulties in walking and at the age of 75 years she became wheelchair dependent. Her gait abnormalities were attributed to severe arthritis of the hip. Her grandson, subject V.3, also complained of hip pain but his gait was normal. The same subject had a history of gastric ulcer and sinus tachycardia; two dimensional echocardiogram was normal.

### Genetic analysis

High resolution, prometaphase karyotype with 550-750 band resolution performed on V.5 was normal and did not show microdeletions or rearrangements. Special attention was paid to chromosomes 3p23-24.12, 4p15.32-14, and 5q11.<sup>6-8</sup> All six analysed markers spanning the *TCOF1* locus yielded significantly negative two point lod scores ( $<-2$ ), thus excluding linkage to chromosome 5q31-q34 (fig 1).

### DISCUSSION

We report one kindred with six affected subjects who had bilateral ptosis, downward slanting palpebral fissures, various degrees of malar hypoplasia and micrognathia, conductive hearing loss, and unilateral anotia in four affected subjects. Three affected subjects had minimal limb abnormalities (nail hypoplasia on both fifth toes and mild camptodactyly of the fourth and fifth fingers bilaterally); however, these skeletal anomalies are trivial when compared with the clinical spectrum seen in the acrofacial dysostoses.<sup>12</sup> Moreover, three other examined affected subjects did not have signs of any limb abnormalities and we propose that the phenotype of this family is consistent with MFD.

Facial asymmetry with hemifacial microsomia and asymmetrical hypoplasia of the mandible and external ear, together with epibulbar dermoid, colobomas of the upper lid, and vertebral anomalies are cardinal features of oculoauriculovertebral dysplasia (Goldenhar syndrome, OMIM 164210).<sup>13</sup> The majority of cases are sporadic but several examples of vertical transmission support an AD mode of inheritance.<sup>14</sup> Even though some degree of asymmetrical involvement was a constant feature in affected patients from the present pedigree, we did not detect any asymmetry of the mouth or epibulbar dermoids. Moreover, two subjects had a radiographical examination of the spine and no hemivertebrae, vertebral hypoplasia, or block vertebral anomalies were present, thus excluding the diagnosis of oculoauriculovertebral dysplasia.

The mode of inheritance in this pedigree is consistent with an AD mode of inheritance. The most common type of AD MFD is TCS. Even though bilateral ptosis, absence of lower lid colobomas, and asymmetrical facial and auricular abnormalities did not suggest the diagnosis of TCS, we genotyped markers linked to the *TCOF1* locus to exclude conclusively the possibility of an atypical manifestation of a variant form of TCS in the family. We obtained significantly negative two point lod scores throughout the *TCOF1* locus, excluding *treacle* as a cause of MFD in our patients.

Interstitial deletion of chromosomes 3 and 4 ((del)(3)(p23p24.12) and (del)(4)(p15.32p14)) and an apparently balanced translocation t(5;13)(q11;p11) have been associated with facial features resembling a TCS phenotype.<sup>6-8</sup> None of these patients had severe ptosis as was seen in the present family. We performed high resolution karyotyping in one typically affected subject and no abnormalities were found. The existence of a similar phenotype in patients with detected chromosomal rearrangements supports the existence of genetic heterogeneity of MFD. However, these chromosomal regions may not be candidate regions for MFD. This is shown in an example of a family with MFD and an apparently balanced translocation t(6;16)(p21.31;p13.11); another child

with MFD had a normal karyotype and this translocation did not segregate with the disease.<sup>15</sup>

The Bauru type of MFD is another type of MFD with an AD mode of inheritance described in Brazilian patients.<sup>9</sup> Cleft lip with or without cleft palate and upward slanting palpebral fissures, which have been reported in patients with Bauru syndrome, enable us to distinguish this type of MFD from our kindred. None of the affected subjects from our kindred had signs of macroblepharon or macrostomia, two diagnostic features of a novel type of MFD described by Verloes and Lesenfants.<sup>16</sup> Other recognised types of MFD have either autosomal recessive or an X linked mode of inheritance.

In summary, we propose that this family represents a novel type of AD MFD whose main features include ptosis, hypoplasia of the zygomatic complex, micrognathia with malocclusion, and auricular abnormalities with conductive hearing loss. The limited number of available affected and unaffected subjects did not allow us to perform a robust genome wide search. Identification of additional families with the same phenotype will be necessary to find a locus for the gene causing this novel type of MFD.

### Authors' affiliations

**P Hedera\***, Department of Pediatrics, Division of Medical Genetics, University of Michigan, MI, USA

**H V Toriello**, DeVos Children's Hospital, Genetics Service, Grand Rapids, MI, USA

**E M Petty**, Department of Medicine, Division of Medical Genetics, 1150 W Medical Center Drive, 4301 MSRB 3, Ann Arbor, MI 48109, USA

Correspondence to: Dr E M Petty, Department of Medicine, Division of Medical Genetics, 1150 W Medical Center Drive, 4301 MSRB 3, Ann Arbor, MI 48109, USA; epetty@umich.edu

\*Present address: Department of Neurology, University of Michigan, MI, USA

Revised version received 21 March 2002  
Accepted for publication 22 March 2002

### REFERENCES

- 1 **Treacher Collins Syndrome Collaborative Group**. Positional cloning of a gene involved in the pathogenesis of Treacher Collins syndrome. *Nat Genet* 1996;**12**:130-6.
- 2 **Dixon MJ**. Treacher Collins syndrome. *J Med Genet* 1995;**32**:806-8.
- 3 **Dixon MJ**, Read AP, Donnai D, Colley A, Dixon J, Williamson R. The gene for Treacher Collins syndrome maps to the long arm of chromosome 5. *Am J Hum Genet* 1991;**49**:17-22.
- 4 **Jabs EW**, Li X, Coss CA, Taylor EW, Meyers DA, Weber JL. Mapping the Treacher Collins syndrome locus to 5q31.3-q33.3. *Genomics* 1991;**11**:193-8.
- 5 **Edery P**, Manach Y, Le Merrer M, Till M, Vignal A, Lyonnet S, Munnich A. Apparent genetic homogeneity of the Treacher Collins-Franceschetti syndrome. *Am J Med Genet* 1994;**52**:174-7.
- 6 **Arn PH**, Mankinen C, Jabs EW. Mild mandibulofacial dysostosis in a child with a deletion of 3p. *Am J Med Genet* 1993;**46**:534-6.
- 7 **Jabs EW**, Coss CA, Hayflick SJ, Whitmore TE, Pauli RM, Kirkpatrick SJ, Meyers DA, Goldberg R, Day DW, Rosenbaum KN. Chromosomal deletion 4p15.32-p14 in a Treacher Collins syndrome patient: exclusion of the disease locus from and mapping of anonymous DNA sequences to this region. *Genomics* 1991;**11**:188-92.
- 8 **Balestrazzi P**, Baeteman MA, Mattei MG, Mattei JF. Franceschetti syndrome in a child with a de novo balanced translocation (5;13)(q11;p11) and significant decrease of hexosaminidase B. *Hum Genet* 1983;**64**:305-8.
- 9 **Marciano**, ACB, Richieri-Costa A. A newly recognized autosomal dominant mandibulofacial dysostosis (Bauru type): report on a Brazilian family. *Brazil J Dysmorphol Speech Hearing Disord* 1998;**1**:37-41.
- 10 **Dixon MJ**, Dixon J, Houseal T, Bhatt M, Ward DC, Klinger K, Landes GM. Narrowing the position of the Treacher Collins syndrome locus to a small interval between three new microsatellite markers at 5q32-33.1. *Am J Hum Genet* 1993;**52**:907-14.
- 11 **Lathrop GM**, Lalouel JM, Julier C, Ott J. Multipoint linkage analysis in humans: detection of linkage and estimation of recombination. *Am J Hum Genet* 1985;**37**:482-98.

- 12 **Opitz JM**, Mollica F, Sorge G, Milana G, Cimino G, Caltabiano M. Acrofacial dysostoses: review and a report of previously undescribed condition: the autosomal or X-linked dominant Catania form of acrofacial dysostosis. *Am J Med Genet* 1993;**47**:660-78.
- 13 **Rollnick BR**, Kaye CI, Nagatoshi K, Hauck W, Martin AO. Oculoauriculovertebral dysplasia and variants: phenotypic characteristics of 294 patients. *Am J Med Genet* 1987;**26**:361-75.
- 14 **Regenbogen L**, Godel V, Goya V, Goodman RM. Further evidence for an autosomal dominant form of oculoauriculovertebral dysplasia. *Clin Genet* 1982;**21**:161-7.
- 15 **Dixon MJ**, Haan E, Baker E, David D, McKenzie N, Williamson R, Mulley J, Farrall M, Callen D. Association of Treacher Collins syndrome and translocation 6p21.31/16p13.11: exclusion of the locus from these candidate regions. *Am J Hum Genet* 1991;**48**:274-80.
- 16 **Verloes A**, Lesenfants S. A new form of mandibulofacial dysostosis with macroblepharon and macrostomia. *Clin Dysmorphol* 1997;**6**:21-4.

If you have a burning desire to respond to a paper published in *Journal of Medical Genetics*, why not make use of our "rapid response" option?

Log on to our website ([www.jmedgenet.com](http://www.jmedgenet.com)), find the paper that interests you, and send your response via email by clicking on the "eLetters" option in the box at the top right hand corner.

Providing it isn't libellous or obscene, it will be posted within seven days. You can retrieve it by clicking on "read eLetters" on our homepage.

The editors will decide as before whether to publish it in a future paper issue as well.

## ECHO

### From errant enzymes to colon cancers



Please visit the Journal of Medical Genetics website [[www.jmedgenet.com](http://www.jmedgenet.com)] for link to this full article.

The suggestion that some colorectal cancers (CRCs) develop by a methylation pathway has been given support by a genetic study of 500 patients in Australia. The findings support the view that key enzymes in the metabolism of folate and methyl groups, which affect DNA methylation, influence predisposition to CRCs, particularly sporadic (non-familial) cancers with microsatellite instability (MSI).

The researchers hypothesised that genetic polymorphisms in enzymes of folate metabolism—methylentetrahydrofolate reductase (MTHFR) and cystathionine beta-synthase (CBS)—would respectively predispose to or protect against MSI+ CRCs, owing to their effects on enzyme activity.

Comparison of the frequency of polymorphic genotypes in patients with MSI+ and MSI- CRCs and in controls confirmed the hypothesis. The *MTHFR* TT genotype—which results in a 30% drop in enzyme activity—was significantly associated with CRC, but in patients aged  $\geq 70$  years, compared with age matched controls (12% v 7%). It also correlated with increased age at diagnosis of proximal tumours (median age 74 v 67 years) and was found almost twice as commonly in MSI+ as in MSI- tumours (16% v 9%). The *CBS844ins68* genotype—which increases activity in reducing plasma homocysteine—was less common in proximal tumours than in controls (4% v 10%).

The study was performed in 500 patients with CRC: 75 cancers were MSI+ cancers of the proximal colon and 426 were MSI- cancers of the proximal (203) or distal (233) colon. The controls were 1207 healthy subjects from the Western Australian population. A subgroup of 155 of the controls was typed for the CBS polymorphism.

▲ *Gut* 2002;**50**:520–524.