

## LETTER TO JMG

## Mandibuloacral dysplasia caused by homozygosity for the R527H mutation in lamin A/C

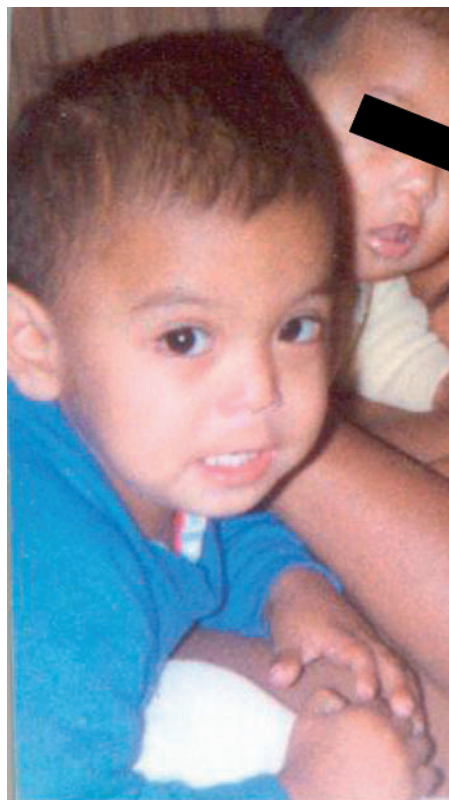
J J Shen, C A Brown, J R Lupski, L Potocki

*J Med Genet* 2003;40:854–857

Lamins are intermediate filament proteins comprising a major structural component of the nuclear lamina, which underlies the inner membrane of the nuclear envelope in most somatic cells. In humans, seven alternatively spliced forms derive from three genes—*LMNA*, *LMNB1*, and *LMNB2*. Although their nuclear functions are currently being elucidated, it has been hypothesised that they are involved in membrane support, pore arrangement, envelope assembly, and chromatin organisation. Through these associations, the lamins may have more expanded roles at the cellular level and control diverse functions such as DNA synthesis, gene expression, and apoptosis.<sup>1–6</sup>

Disorders caused by defects in the nuclear lamina associated proteins are referred to as the laminopathies. Thus far among the lamins, these have been described only for *LMNA*, which maps to chromosome 1q21.2 and encodes lamin A and lamin C through alternative splicing. A disparate group of seemingly unrelated diseases with different affected organ systems has been attributed to lamin A/C mutations. These include Charcot-Marie-Tooth disease type 2B,<sup>7</sup> forms of dilated cardiomyopathy,<sup>8</sup> both autosomal dominant and autosomal recessive forms of Emery-Dreifuss muscular dystrophy,<sup>9</sup> limb girdle muscular dystrophy type 1B,<sup>11</sup> Dunnigan-type familial partial lipodystrophy,<sup>12–14</sup> and Hutchinson-Gilford progeria.<sup>15–16</sup> Recently, Novelli *et al* categorised mandibuloacral dysplasia as a laminopathy resulting from lamin A/C mutation.<sup>17</sup>

Mandibuloacral dysplasia (MAD; MIM 248370) is a rare autosomal recessive disorder. Affected individuals have a normal appearance at birth, then progressively develop



**Figure 1** Photograph of the patient at approximately two years of age. Note normal overall appearance except for subtle distal phalangeal swelling.

## Key points

- Mandibuloacral dysplasia (MAD) is a rare disorder combining a characteristic facial appearance with acro-osteolysis and lipodystrophy.
- Lamins are integral structural components of the nuclear lamina hypothesised to be involved in numerous cellular processes. Mutations in these genes result in diverse diseases collectively referred to as the laminopathies. Recently, MAD has been shown to be caused by a specific mutation (R527H) in *LMNA*, which encodes lamins A and C.
- A boy with this disorder is described who has a homozygous R527H substitution in *LMNA*. Thus far, all families with MAD in whom a mutation was discovered harbour the identical base alteration. These families show distinct haplotypes, which indicates that each mutation originated independently.
- There is a highly specific genotype–phenotype correlation between the *LMNA* R527H mutation and MAD.

lipodystrophy and dysmorphic craniofacial and skeletal features. Characteristic findings in MAD include mandibular hypoplasia, acro-osteolysis, prominent appearance of the eyes, dental overcrowding, beaked nose, delayed closure of the cranial sutures, clavicular dysplasia/osteolysis, joint contractures, and poikiloderma. Novelli *et al* analysed lamin A/C for mutations in five consanguineous Italian families with MAD.<sup>17</sup> Homozygosity for a single mutation (R527H) was found in all nine affected individuals, who also shared a common disease haplotype.

In this report, we describe the physical and radiographic features of a Mexican American boy with MAD. Mutational analysis of the lamin A/C gene revealed homozygosity for the identical R527H mutation as reported previously, but with a distinct haplotype.

## METHODS

## Clinical information

The patient was the full term product of a consanguineous union. The pregnancy history was unremarkable and he

appeared normal at birth. Subtle physical changes were first noted at approximately 18 months of age, when he developed persistently swollen fingertips (fig 1). Alterations in his skin and pattern of body fat distribution began when he was six years old; his mother described puffiness around his cheeks and neck region, as well as areas of dry and variably pigmented skin near his eyes, umbilicus, and axillae. Approximately two years later, he began to show dental crowding, micrognathia, and marked thickening of the nails on his fingers and toes. He continued to develop lipodystrophic changes and progressive joint contractures until our first encounter with him at 12 years of age. His past medical history was otherwise unremarkable, without major or chronic illnesses. He met his developmental milestones appropriately and he was enrolled at school in an age appropriate grade level. No other similarly affected individuals were reported in this family.

At age 12, many features of MAD were evident (fig 2). His weight, height, and fronto-occipital circumference were all within the 5th–10th centiles. He had a lipodystrophic body habitus with thin extremities and a central distribution of fat in his face, neck, and trunk. His face showed prominence of the eyes, a beaked nose, fullness of the cheeks, micrognathia, inability to open his mouth completely, and dental overcrowding. Acanthosis nigricans of the neck was present. He had markedly downward sloping shoulders. Examination of the lungs, heart, abdomen, and genitals was normal. Patchy

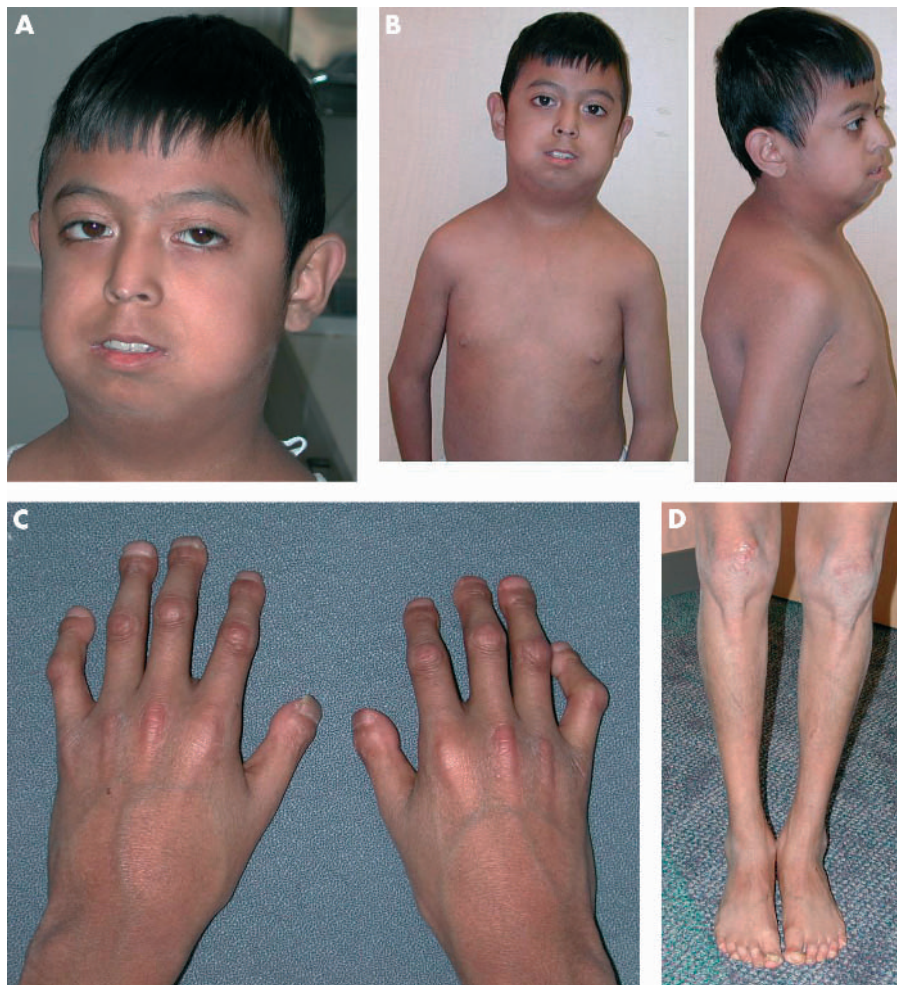areas of poikiloderma were present on his neck and lower abdomen and in the axillary and inguinal regions. Neurologically, his strength was intact without asymmetry, reflexes were bilaterally normal, and no sensory deficits were identified.

The most dramatic aspects on examination involved his musculoskeletal system and extremities. There was extreme paucity of subcutaneous fat in the extremities, and the overlying skin was taut and dry. He had mild contractures at his elbows and a restricted range of motion in his shoulder girdle and hips. His fingers and toes showed camptodactyly, short, broad and bulbous distal phalanges, and hypoplastic nail beds with varying degrees of nail hyperkeratosis.

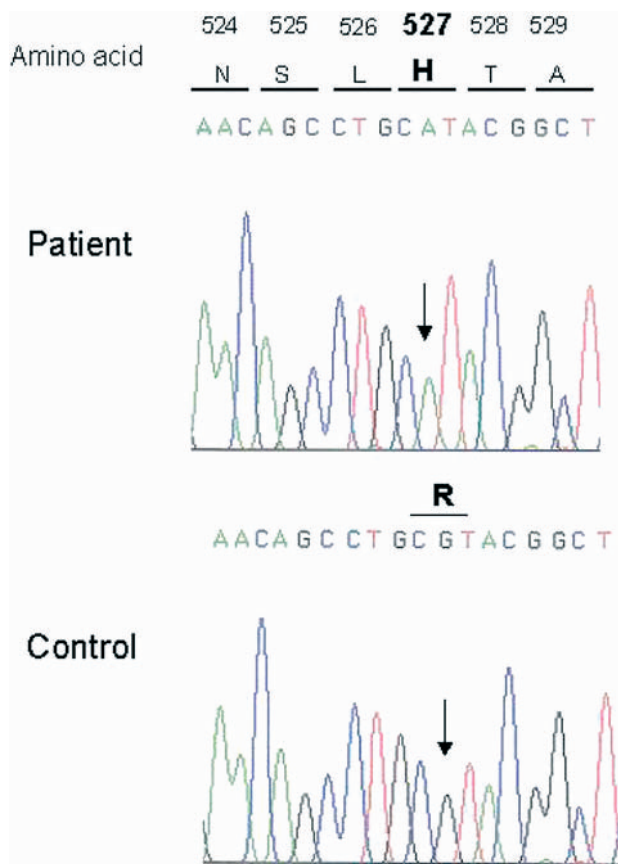
### Imaging and laboratory evaluation

A skeletal survey revealed generalised osteopenia, wormian bones with persistence of suture lines in his cranium, coxa valga, and distal phalangeal osteolysis. Clavicular abnormalities were not evident. On biochemical analysis there was hypercholesterolaemia and dyslipidaemia, but normal glycosylated haemoglobin and non-fasting serum glucose levels. Chromosome analysis revealed a normal 46,XY complement.

Sequencing of *LMNA* identified a homozygous G→A transition at nucleotide position 1580 (1580G>A) which, by conceptual translation, resulted in a missense arginine to histidine substitution at amino acid position 527 (R527H) (fig 3). The nucleotides at the *LMNA* exonic single nucleotide



**Figure 2** Current photographs showing characteristic craniofacial appearance (A), lipodystrophy (B), and distal extremity and phalangeal findings (C) (D).



**Figure 3** Sequence of LMNA showing the G→A transition and resulting arginine to histidine missense substitution at amino acid position 527.

polymorphisms (SNPs) previously reported<sup>17, 18</sup> were as follows: position 861, T; position 1338, T; position 1698, T.

## DISCUSSION

We describe here another individual with mandibuloacral dysplasia. Apart from an earlier age of onset (1.5 v 4.3 years), the findings in this patient typify the physical and radiographic features previously associated with this disorder.<sup>19</sup> Another consistently reported aspect of MAD is insulin resistance and impaired glucose tolerance, and on examination this patient has acanthosis nigricans. Novelli *et al* have identified a homozygous LMNA missense mutation (R527H) in nine patients with MAD from five consanguineous Italian families.<sup>17</sup> Consistent with a founder effect, all affected individuals shared a common disease haplotype: LMNA exonic SNPs at nucleotide positions 861, 1338, and 1698 were C, C, and C. More recently, Simha *et al* reported two separate families with MAD in which the R527H substitution was present as well<sup>20</sup>; however, the exonic SNPs were different (T, T, and C at the corresponding SNP nucleotide positions), and intronic SNPs indicated separate origins for this mutation in each family. The patient we describe here harbours the same homozygous R527H lamin A/C mutation as the previously reported patients; this also originated independently as evidenced by a different haplotype (T, T, and T).

An intriguing aspect of the laminopathies is the diversity of phenotypes, despite the fact that many are caused by mutations in the same lamin A/C gene. Examples of allelic affinity include the androgen receptor locus in spinal and bulbar muscular atrophy (MIM 313200) and testicular feminisation (MIM 300068); fibroblast growth factor receptor

mutations causing distinct craniosynostosis syndromes; and the ABCR locus and a range of retinal dystrophies and susceptibility to macular degeneration.<sup>21</sup> Diseases caused by LMNA mutations (MAD, Dunnigan-type familial partial lipodystrophy, forms of cardiomyopathy, limb girdle muscular dystrophy type 1B, autosomal dominant Emery-Dreifuss muscular dystrophy (AD-EDMD), Charcot-Marie-Tooth disease type 2B, and Hutchinson-Gilford progeria) provide a further and more dramatic example of this phenomenon as all manifest separate and distinctive phenotypic features including skeletal changes, skin findings, lipodystrophy, cardiomyopathy, muscular dystrophy, and neuropathy.<sup>7-11, 15, 16, 22-26</sup>

Although the wide ranging phenotypes of the laminopathies result from LMNA mutations that occur throughout the gene, a different scenario is emerging with MAD. The arginine at position 527 is located within the C-terminal immunoglobulin-like domain in the centre of a  $\beta$  sheet on the domain surface; mutations at this site are postulated to disturb intramolecular interactions and disrupt protein structure.<sup>27, 28</sup> Substituting a proline in this location (R527P) results in AD-EDMD with some but not all patients with lipodystrophy.<sup>9, 10, 29, 30</sup> However, substituting a histidine in this position (R527H) has now been shown in four separate instances to result in MAD. A founder effect was not suspected because of differing ethnic backgrounds, and haplotype analysis indeed supports the likelihood that each of the R527H mutations arose independently. This raises an intriguing possibility that there is a very specific genotype-phenotype correlation between this exact amino acid substitution and the characteristic constellation of lipodystrophy with skeletal and skin manifestations in this rare disease. Recently, Eriksson *et al* reported a similar result, as 19 of 20 de novo classical cases of Hutchinson-Gilford progeria harboured LMNA mutations, each predicted to result in the same internal 50 amino acid deletion.<sup>16</sup>

Among the approximately 40 patients with MAD reported so far, there is a certain degree of phenotypic variability. For example, the patient described in this report lacked clavicular hypoplasia. Other affected individuals have differed in the extent of acro-osteolysis or in whether hypogonadism is present.<sup>31-33</sup> Individuals with Hoepffner-Dreyer-Rudiger syndrome<sup>34</sup> lack acro-osteolysis but otherwise phenotypically resemble MAD. Simha and Garg<sup>19</sup> proposed two variant forms of MAD which are distinguished by the pattern of body fat distribution: type A, with preferential accumulation of subcutaneous fat centrally, and type B, with generalised loss of subcutaneous fat. They have recently confirmed that only type A MAD is caused by the R527H mutation in LMNA; no mutations were detected in four families with type B MAD.<sup>20</sup> Continued molecular analysis of patients with MAD will help determine the specificity of the LMNA R527H mutation to type A MAD, the variability of phenotypic expressivity for this mutation, and the molecular basis for additional forms of MAD.

Note added in proofs: Agarwal *et al* have described a patient with type B MAD and mutations in the ZMPSTE24 gene.<sup>35</sup>

## Authors' affiliations

J J Shen, J R Lupski, L Potocki, Department of Molecular and Human Genetics, Baylor College of Medicine, Texas Children's Hospital, Houston, Texas, USA

C A Brown, Molecular Diagnostics Laboratory, Fairview-University Medical Center, University of Minnesota, Minneapolis, Minnesota, USA

J R Lupski, Department of Pediatrics, Texas Children's Hospital, Houston, Texas, USA

Correspondence to: Dr L Potocki, Department of Molecular and Human Genetics, Baylor College of Medicine, Texas Children's Hospital, Clinical Care Center, 6621 Fannin, Suite 1560, Houston, Texas 77030, USA; lpotocki@bcm.tmc.edu

## REFERENCES

- 1 **Goldman RD**, Gruenbaum Y, Moir RD, Shumaker DK, Spann TP. Nuclear lamins: building blocks of nuclear architecture. *Genes Dev* 2002;**16**:533–47.
- 2 **Holaska JM**, Wilson KL, Mansharamani M. The nuclear envelope, lamins and nuclear assembly. *Curr Opin Cell Biol* 2002;**14**:357–64.
- 3 **Worman HJ**, Courvalin J-C. The nuclear lamina and inherited disease. *Trends Cell Biol* 2002;**12**:591–8.
- 4 **Burke B**, Stewart CL. Life at the edge: the nuclear envelope and human disease. *Nat Rev Mol Cell Biol* 2002;**3**:575–85.
- 5 **Hutchison CJ**. Lamins: building blocks or regulators of gene expression? *Nat Rev Mol Cell Biol* 2002;**3**:848–58.
- 6 **Mounkes L**, Kozlov S, Burke B, Stewart CL. The laminopathies: nuclear structure meets disease. *Curr Opin Genet Dev* 2003;**13**:223–30.
- 7 **De Sandre-Giovannoli A**, Chaouch M, Kozlov S, Vallat J-M, Tazir M, Kassouri N, Szepietowski P, Hammadouche T, Vandenberghe A, Stewart CL, Grid D, Levy N. Homozygous defects in LMNA, encoding lamin A/C nuclear-envelope proteins, cause autosomal recessive axonal neuropathy in human (Charcot-Marie-Tooth disorder type 2) and mouse. *Am J Hum Genet* 2002;**70**:726–36.
- 8 **Fatkin D**, MacRae C, Sasaki T, Wolff MR, Porcu M, Frenneaux M, Atherton J, Vidaillet HJ, Spudich S, De Girolami U, Seidman JG, Seidman CE, Muntoni F, Muehle G, Johnson W, McDonough B. Missense mutations in the rod domain of the lamin A/C gene as causes of dilated cardiomyopathy and conduction-system disease. *N Engl J Med* 1999;**341**:1715–24.
- 9 **Bonne G**, Raffaele Di Barletta M, Varnous S, Becane H-M, Hammouda E-H, Merlini L, Muntoni F, Greenberg CR, Gary F, Urtizberea J-A, Duboc D, Fardeau M, Toniolo D, Schwartz K. Mutations in the gene encoding lamin A/C cause autosomal dominant Emery-Dreifuss muscular dystrophy. *Nat Genet* 1999;**21**:285–8.
- 10 **Raffaele Di Barletta M**, Ricci E, Galluzzi G, Tonali P, Mora M, Morandi L, Romorini A, Voit T, Orstavik KH, Merlini L, Trevisan C, Biancalana V, Housmanowa-Petrusewicz I, Bione S, Ricotti R, Schwartz K, Bonne G, Toniolo D. Different mutations in the LMNA gene cause autosomal dominant and autosomal recessive Emery-Dreifuss muscular dystrophy. *Am J Hum Genet* 2000;**66**:1407–12.
- 11 **Muchir A**, Bonne G, van der Kooij AJ, van Meegen M, Baas F, Bolhuis PA, de Visser M, Schwartz K. Identification of mutations in the gene encoding lamins A/C in autosomal dominant limb girdle muscular dystrophy with atrioventricular conduction disturbances (LGMD1B). *Hum Mol Genet* 2000;**9**:1453–9.
- 12 **Cao H**, Hegele RA. Nuclear lamin A/C R482Q mutation in Canadian kindreds with Dunnigan-type familial partial lipodystrophy. *Hum Mol Genet* 2000;**9**:109–12.
- 13 **Shackleton S**, Lloyd DJ, Jackson SNJ, Evans R, Niermeijer MF, Singh BM, Schmidt H, Brabant G, Kumar S, Durrington PN, Gregory S, O'Rahilly S, Trembath RC. LMNA, encoding lamin A/C, is mutated in partial lipodystrophy. *Nat Genet* 2000;**24**:153–6.
- 14 **Speckman RA**, Garg A, Du F, Bennett L, Veile R, Arioglu E, Taylor SI, Lovett M, Bowcock AM. Mutational and haplotype analyses of families with familial partial lipodystrophy (Dunnigan variety) reveal recurrent missense mutations in the globular C-terminal domain of lamin A/C. *Am J Hum Genet* 2000;**66**:1192–8.
- 15 **De Sandre-Giovannoli A**, Bernard R, Cau P, Navarro C, Amiel J, Boccaccio I, Lyonnet S, Stewart CL, Munnich A, Le Merrer M, Levy N. Truncation in Hutchinson-Gilford Progeria. *Science* 2003;**300**:2055.
- 16 **Eriksson M**, Brown WT, Gordon LB, Glynn MW, Singer J, Scott L, Erdos MR, Robbins CM, Moses TY, Berglund P, Dutra A, Pak E, Durkin S, Csoka AB, Boehnke M, Glover TW, Collins FS. Recurrent de novo point mutations in lamin A cause Hutchinson-Gilford progeria syndrome. *Nature* 2003 (advance online publication): doi:10.1038/nature01629.
- 17 **Novelli G**, Muchir A, Sangiuolo F, Helbling-Leclerc A, Rosaria D'Apice M, Massaro C, Capon F, Sbraccia P, Federici M, Lauro R, Tudisco C, Pallotta R, Scarano G, Dallapiccola B, Merlini L, Bonne G. Mandibuloacral dysplasia is caused by a mutation in LMNA-encoding lamin A/C. *Am J Hum Genet* 2002;**71**:426–31.
- 18 **Vigouroux C**, Magre J, Vantyghem M-C, Bourut C, Lascols O, Shackleton S, Lloyd DJ, Guerci B, Padova G, Valensi P, Grimaldi A, Piquemal R, Touraine P, Trembath RC, Capeau J. Lamin A/C gene: sex-determined expression of mutations in Dunnigan-type familial partial lipodystrophy and absence of coding mutations in congenital and acquired generalized lipodystrophy. *Diabetes* 2000;**49**:1958–62.
- 19 **Simha V**, Garg A. Body fat distribution and metabolic derangements in patients with familial partial lipodystrophy associated with mandibuloacral dysplasia. *J Clin Endocrinol Metab* 2002;**87**:776–85.
- 20 **Simha V**, Agarwal AK, Oral EA, Fryns J-P, Garg A. Genetic and phenotypic heterogeneity in patients with mandibuloacral dysplasia-associated lipodystrophy. *J Clin Endocrinol Metab* 2003;**88**:2821–4.
- 21 **Shroyer N**, Lewis RA, Allikmets R, Singh N, Dean M, Leppert M, Lupski JR. The rod photoreceptor ATP-binding cassette transporter gene, ABCR, and retinal disease: from monogenic to multifactorial. *Vision Res* 1999;**39**:2537–44.
- 22 **Kobberling J**, Dunnigan MG. Familial partial lipodystrophy: two types of an X linked dominant syndrome, lethal in the hemizygous state. *J Med Genet* 1986;**23**:120–7.
- 23 **Garg A**, Speckman RA, Bowcock AM. Multisystem dystrophy syndrome due to novel missense mutations in the amino-terminal head and alpha-helical rod domains of the lamin A/C gene. *Am J Med* 2002;**112**:549–55.
- 24 **Becane H-M**, Bonne G, Varnous S, Muchir A, Ortega V, Hammouda E-H, Urtizberea J-A, Lavergne T, Fardeau M, Eymard B, Weber S, Schwartz K, Duboc D. High incidence of sudden death with conduction system and myocardial disease due to lamins A and C gene mutation. *PACE* 2000;**23**:1661–6.
- 25 **Brodsky GL**, Muntoni F, Miocic S, Sinagra G, Sewry C, Mestroni L. Lamin A/C gene mutation associated with dilated cardiomyopathy with variable skeletal muscle involvement. *Circulation* 2000;**101**:473–6.
- 26 **Chaouch M**, Allal Y, De Sandre-Giovannoli A, Vallat JM, Amer-el-Khedoud A, Kassouri N, Chaouch A, Sindou P, Hammadouche T, Tazir M, Levy N, Grid D. The phenotypic manifestations of autosomal recessive axonal Charcot-Marie-Tooth due to a mutation in Lamin A/C gene. *Neuromuscul Disord* 2003;**13**:60–7.
- 27 **Dhe-Paganon S**, Werner ED, Chi Y-I, Shoelson SE. Structure of the globular tail of nuclear lamin. *J Biol Chem* 2002;**277**:17381–4.
- 28 **Krimm I**, Ostlund C, Gilquin B, Couprie J, Hossenlopp P, Mornon J-P, Bonne G, Courvalin J-C, Worman HJ, Zinn-Justin S. The Ig-like structure of the C-terminal domain of lamin A/C, mutated in muscular dystrophies, cardiomyopathy, and partial lipodystrophy. *Structure* 2002;**10**:811–23.
- 29 **Bonne G**, Mercuri E, Muchir A, Urtizberea A, Becane HM, Recan D, Merlini L, Wehnert M, Boor R, Reuner U, Vorgerd M, Wicklein EM, Eymard B, Duboc D, Penisson-Besnier I, Cuisset JM, Ferrer X, Desguerre I, Lacombe D, Bushby K, Pollitt C, Toniolo D, Fardeau M, Schwartz K, Muntoni F. Clinical and molecular genetic spectrum of autosomal dominant Emery-Dreifuss muscular dystrophy due to mutations of the lamin A/C gene. *Ann Neurol* 2000;**48**:170–80.
- 30 **van der Kooij AJ**, Bonne G, Eymard B, Duboc D, Talim B, Van der Valk M, Leiss P, Richard P, Demay L, Merlini L, Schwartz K, Busch HFM, de Visser M. Lamin A/C mutations with lipodystrophy, cardiac abnormalities, and muscular dystrophy. *Neurology* 2002;**59**:620–3.
- 31 **Freidenberg GR**, Cutler DL, Jones MC, Hall B, Mier RJ, Culler F, Jones KL, Lozzio C, Kaufmann S. Severe insulin resistance and diabetes mellitus in mandibuloacral dysplasia. *Am J Dis Child* 1992;**146**:93–9.
- 32 **Prasad PVS**, Padmavathy L, Sethurajan S. Familial mandibuloacral dysplasia—a report of four cases. *Int J Dermatol* 1998;**37**:614–16.
- 33 **Ng D**, Stratakis CA. Premature adrenal cortical dysfunction in mandibuloacral dysplasia: a progeroid-like syndrome. *Am J Med Genet* 2000;**95**:293–5.
- 34 **Hoepffner H-J**, Dreyer M, Reimers U, Schmidt-Preuss U, Koepf H-P, Rudiger HW. A new familial syndrome with impaired function of three related peptide growth factors. *Hum Genet* 1989;**83**:209–16.
- 35 **Agarwal AK**, Fryns J-P, Gary A. Zinc metalloproteinase, ZMPSTE24, is mutated in mandibuloacral dysplasia. *Hum Mol Genet* 2003;**12**:1995–2001.