

## ONLINE MUTATION REPORT

# Large deletion causing the *TSC2-PKD1* contiguous gene syndrome without infantile polycystic disease

Y M Smulders, B H J Eussen, S Verhoef, C H Wouters

*J Med Genet* 2003;40:e17(<http://www.jmedgenet.com/cgi/content/full/40/2/e17>)

**T**uberous sclerosis complex (TSC) is a genetic disorder characterised by hamartomatous growth abnormalities in many organs. Epilepsy and mental retardation, typical skin manifestations, intracerebral hamartoma, renal angiomyolipoma, and pulmonary lymphangioleiomyomatosis are among the major diagnostic features of TSC.<sup>1</sup> TSC is thought to affect approximately 1 in every 6000 newborns. It has an autosomal dominant inheritance pattern, but an estimated 60% of all cases involve new mutations.

TSC exhibits locus heterogeneity with two identified genes, one on 9q34 (*TSC1*) and the other on 16p13 (*TSC2*).<sup>2</sup> The *TSC2* gene lies immediately adjacent to *PKD1*, the major gene causing autosomal dominant polycystic kidney disease (ADPKD). Both genes are in a tail to tail orientation only 60 bp apart. In 1994, a "contiguous gene syndrome" was described, involving large deletions disrupting both the *TSC2* gene and the *PKD1* gene.<sup>3</sup> Although, overall, 25% to 32% of patients with TSC show some degree of renal cyst formation,<sup>4,5</sup> the six cases described in the first report all presented during early childhood with markedly enlarged polycystic kidneys.<sup>3</sup> Later reports of the *PKD1-TSC2* contiguous gene syndrome further supported the notion that this disorder is typically associated with severe juvenile polycystic kidney disease.<sup>6-8</sup> A systematic mutational analysis of 27 unrelated patients with TSC and multiple bilateral renal cysts showed that 22 had contiguous deletions of *TSC2* and *PKD1*. In 17 patients with constitutional deletions, the median age of presentation was six months (range 1 month to 10 years), with 83% of patients presenting with abdominal masses or distension owing to large cysts. Renal cystic disease was comparatively mild in the patients without the contiguous gene syndrome.<sup>7</sup>

Here, we present a case of a patient with an exceptionally large, de novo, germline deletion involving the entire *TSC2* and *PKD1* region, who presented at the age of 13 years with a unilateral abdominal mass caused by large renal angiomyolipomas. She underwent nephrectomy at the age of 19 because of acute renal bleeding. Significant renal cystic disease in the contralateral kidney did not develop until several years later.

### CASE REPORT

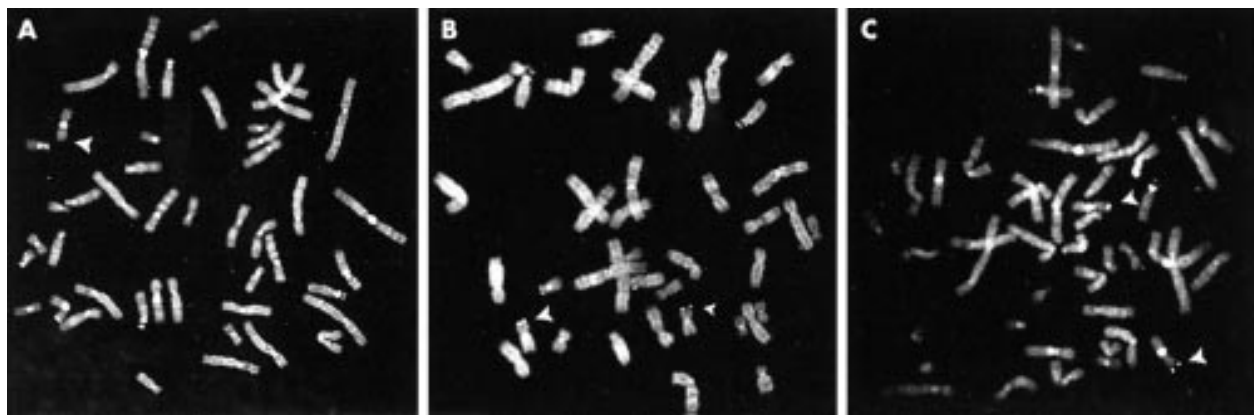
At the age of 13 years, a previously healthy female was evaluated elsewhere for abdominal right upper quadrant discomfort. Ultrasonography and abdominal CT scanning showed two large tumours in the right kidney, with diameters of 5 and 7 cm. A presumptive diagnosis of renal angiomyolipoma was made. Both kidneys showed a few small (<1.5 cm) renal cysts. Renal length (12 cm for both kidneys) was normal for her age and height. At this time, it was decided to monitor renal tumour growth closely and not to institute any form of treatment. Regular follow up with abdominal ultrasonography did not show growth of the renal tumours or cysts. At the age of 19, the patient presented with acute right sided intra- and perirenal haemorrhage, requiring emergency nephrectomy. Histopathological examination confirmed the diagnosis of renal angiomyolipomas, without significant polycystic disease

### Key points

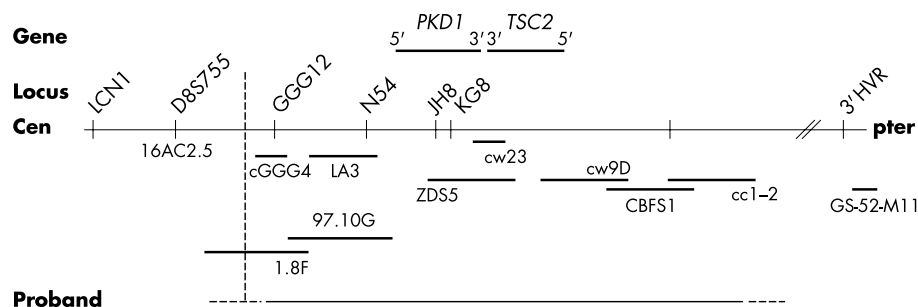
- The characteristic phenotype of patients with the *TSC2-PKD1* contiguous gene syndrome is dominated by severe juvenile polycystic disease, combined with variable phenotypic expression of tuberous sclerosis.
- We describe the case of a woman who presented with renal angiomyolipoma at the age of 13 years. Unilateral nephrectomy was performed at the age of 19 years. No significant polycystic disease was present at this time. At the age of 26 years, pulmonary lymphangioleiomyomatosis was diagnosed, which prompted a full evaluation of the tuberous sclerosis phenotype, resulting in confirmation of the clinical diagnosis. In this period, the remaining kidney showed only moderate polycystic disease.
- FISH analysis of the 16p13.3 region disclosed a deletion spanning the entire *TSC2* and *PKD1* region, larger than previously described deletions in the contiguous gene syndrome.
- This case illustrates the marked phenotypic heterogeneity of the *TSC2-PKD1* contiguous gene syndrome. Although the deletion was exceptionally large, significant polycystic disease did not develop until early adulthood. The contention that severe juvenile polycystic disease is a hallmark of the *TSC2-PKD1* contiguous gene syndrome appears to be incorrect.

(a few solitary cysts, all  $\leq 1$  cm) A year later, five angiomyolipomas of  $\leq 3.5$  cm were surgically removed from the left kidney with the purpose of preventing similar bleeding complications. At the age of 26, she had a spontaneous pneumothorax. A high resolution CT scan of the lungs was suggestive of lymphangioleiomyomatosis, a diagnosis later confirmed by open lung biopsy. After three recurrences of pneumothorax, she underwent bilateral pleurodesis. Because of progressive renal insufficiency of her remaining left kidney, she was referred to the nephrology clinic of our hospital.

Physical examination showed normal stature, habitus, and intellectual development. Because of the combination of renal angiomyolipoma and pulmonary lymphangioleiomyomatosis, evaluation for signs of TSC was performed. Dermatological inspection showed discrete abnormalities: a 4 mm angiofibroma (adenoma sebaceum) in the left nasolabial fold, a solitary shagreen patch on the back, and hypomelanotic macules ( $\leq 1$  mm) as well as small confetti-like skin lesions on the extremities. Dental examination showed a few, discrete enamel pits. Abdominal ultrasonography showed a slightly enlarged left kidney with a length of 13.5 cm, containing multiple cysts with a maximum diameter of 4.5 cm, and a solitary angiomyolipoma of 3.5 cm. Furthermore, the liver contained two cysts, both with a diameter of 1 cm. Magnetic resonance



**Figure 1** Representative FISH results showing (A) a deletion of the 16p13.3 region using the cw23 probe (7q11.23) and D7S427 control probe (7q36). Only one normal chromosome 16 shows signals at p13.3; no signals are visible on the deleted chromosome 16 (arrow). (B) A partial deletion (diminished signals) of the 16p13.3 region using the 1.8F probe (small arrow) and normal signals on the other chromosome 16 (large arrow). (C) On both chromosomes 16 the subtelomeric probe GS-52-M11 is still visible (arrows).



**Figure 2** The molecular map of the *TSC2* and *PKD1* region on chromosome 16p (not drawn to scale). The deletion detected in the proband is indicated by the solid bar.

imaging of the brain showed two small subependymal nodules. Fundoscopy was normal. Echocardiography showed a type II atrial septal defect, but no intracardiac hamartomas. Based on these clinical criteria, the likely diagnosis of TSC was confirmed.<sup>1</sup> At this time, the renal cysts were considered to be part of the TSC syndrome.

### Cytogenetics

Cytogenetic and FISH (fluorescence in situ hybridisation) studies were performed on metaphases derived from a culture of PHA stimulated peripheral blood lymphocytes. The cultures were synchronised by using an excess amount of thymidine for 16 hours. The block was released by change of medium six hours before harvesting. Standard karyotyping performed on GTG banded chromosomes showed a normal female karyotype (46,XX). To detect a possible submicroscopic deletion in the *TSC2* region, subsequent FISH analysis was performed according to the protocol of Pinkel *et al*<sup>9</sup> with minor modifications. The DNA probes cc1-2,<sup>10</sup> cw9d,<sup>11</sup> cw23,<sup>11</sup> (fig 1A), ZDS5,<sup>11</sup> 97.10G,<sup>12</sup> and cGGG4<sup>10</sup> hybridising to the 16p13.3 region showed a large deletion on one of the two chromosomes 16. The number of metaphases analysed with the different DNA probes were respectively 30, 30, 10, 10, 20, and 20. A subtelomeric probe GS-52-M11<sup>13</sup> located in the 16pter region was still present (fig 1C, a total of 10 metaphases was investigated), indicating that the deletion was interstitial. The DNA probe 1.8F<sup>12</sup> showed a partial deletion, clearly visible by a difference in intensity (fig 1B). This intensity difference was consistent across the 20 metaphases which were investigated, indicating absence of somatic mosaicism. The breakpoint of the deletion must for this reason be located in the proximal part of DNA probe 1.8F. The positions of the probes on chromosome 16p are schematically shown in fig 2. Following these findings,  $\alpha$  thalassaemia was ruled out by haemoglobin electrophoresis. In

addition, to determine whether the deletion was de novo or familial, the parents of the proband were investigated. Both parents had a normal phenotype, showed a normal karyotype, and FISH did not disclose any abnormalities in the 16p13.3 region.

### DISCUSSION

The case presented is remarkable in two ways. Firstly, as outlined in the introduction, it is very unusual for the *TSC2*-*PKD1* contiguous gene syndrome to present itself without severe congenital or juvenile polycystic disease with grossly enlarged kidneys.<sup>3-6-8</sup> Secondly, the deletion found in our patient is exceptionally large, at least 200 kb, which is the probe contig surrounding the *TSC2* and *PKD1* genes. It is, to our knowledge, the largest interstitial deletion reported in the *TSC*-*PKD* contiguous gene syndrome in an otherwise normal subject.

Previously, the  $\alpha$  globin gene cluster was mapped to chromosome band 16p13.3 distal to the *TSC2* locus. Patients with  $\alpha$  thalassaemia/mental retardation syndrome (ATR-16) have been reported to show terminal deletions, variable in extent.<sup>14-15</sup> The deletion present in the proband proved to be interstitial, since the subtelomeric probe GS-52-M11 located at the 16pter region was still present. This was expected considering the normal  $\alpha$  thalassaemia trait and absence of mental retardation in the proband. The proximal breakpoint was, on the other hand, similar to the one previously found in the patient described by Eussen *et al*.<sup>15</sup>

Why did significant polycystic disease develop later in life in our patient? The answer remains speculative. Somatic mosaicism, which occurs frequently in tuberous sclerosis complex,<sup>16</sup> and has also been reported in the *TSC2*-*PKD1* contiguous gene syndrome,<sup>7</sup> does not appear to play a role in our patient. Mosaicism at organ level, particularly in the kidney, cannot be

ruled out. In both ADPKD<sup>17,18</sup> and in TSC,<sup>2,19</sup> loss of heterozygosity has been suggested as the mechanism responsible for disease expression. Loss of heterozygosity implies that a “second hit” is required before disease develops. The nature of this “second hit” causing loss of heterozygosity is unknown. Whether it is usually the same for the adjacent genes *PKD1* and *TSC2* is also uncertain. Since *PKD1* and *TSC2* mutations are apparently both recessive at the cellular level, loss of heterozygosity is probably responsible for disease manifestations in the contiguous gene syndrome as well, although this remains to be proven. We speculate that, in our patient, either a single “second hit” caused loss of heterozygosity for both *PKD1* and *TSC2* at a later stage than is common in the contiguous gene syndrome, or two “second hits” were responsible for her disease, one of which, conceivably the one causing loss of heterozygosity for the *PKD* gene, occurred at a later stage in life.

In conclusion, this case illustrates that marked heterogeneity exists in the clinical presentation of the *TSC2-PKD1* contiguous gene syndrome. In contrast to what is commonly thought, severe juvenile polycystic disease is not an obligatory sign.

#### Authors' affiliations

**Y M Smulders**, Department of Nephrology, Academic Medical Centre, Amsterdam, The Netherlands

**B H J Eussen**, **C H Wouters**, Department of Clinical Genetics, Erasmus Medical Centre, Rotterdam, The Netherlands

**S Verhoef**, Department of Clinical Genetics, Academic Medical Centre, Amsterdam, The Netherlands

Correspondence to: Dr Y M Smulders, Free University Medical Centre, PO Box 7057, Amsterdam 1007 MB, The Netherlands; y.smulders@vumc.nl

#### REFERENCES

- 1 **Roach ES**, Gomez MR, Northrup H. Tuberous sclerosis complex consensus conference. Revised clinical diagnostic criteria. *J Child Neurol* 1998;**13**:624-28.
- 2 **Young J**, Povey S. The genetic basis of tuberous sclerosis. *Mol Med Today* 1998;**4**:313-19.
- 3 **Brook-Carter PT**, Peral B, Ward CJ, Thompson P, Hughes J, Maheshwar MM, Nellist M, Gamble V, Harris PC, Sampson JR. Deletion of the *TSC2* and *PKD1* genes associated with severe infantile polycystic kidney disease - a contiguous gene syndrome. *Nat Genet* 1994;**8**:328-32.
- 4 **Cook JA**, Mueller RF, Sampson J. A cross sectional study of renal involvement in tuberous sclerosis. *J Med Genet* 1996;**33**:480-4.
- 5 **Dabora SL**, Jozwiak S, Franz DN, Roberts PS, Nieto A, Chung J, Choy YS, Reeve MP, Thiele E, Egelhoff JC, Kasprzyk-Obara J, Domanska-Pakiela D, Kwiatkowski DJ. Mutation analysis in a cohort of 224 tuberous sclerosis patients indicates increased severity of *TSC2*, compared to *TSC1*, disease in multiple organs. *Am J Hum Genet* 2001;**68**:64-80.
- 6 **Longa L**, Scolari F, Brusco A, Carbonara C, Polidoro S, Valzorio B, Riegler P, Migone N, Maiorca R. A large *TSC2* and *PKD1* deletion is associated with renal and extrarenal signs of autosomal dominant polycystic kidney disease. *Nephrol Dial Transpl* 1997;**12**:1900-7.
- 7 **Sampson JR**, Maheshwar MM, Aspinwall R, Thompson P, Cheadle JP, Ravine D, Roy S, Haan R, Bernstein J, Harris PC. Renal cystic disease in tuberous sclerosis: role of the polycystic kidney disease 1 gene. *Am J Hum Genet* 1997;**61**:843-51.
- 8 **Torra R**, Badenas C, Darnell A, Camacho JA, Aspinwall R, Harris PC, Estivill X. Facilitated diagnosis of the contiguous gene syndrome: tuberous sclerosis and polycystic kidneys by means of haplotype studies. *Am J Kidney Dis* 1998;**31**:1038-43.
- 9 **Pinkel D**, Staume T, Gray JW. Cytogenetic analysis using quantitative, high-sensitivity, fluorescence hybridisation. *Proc Natl Acad Sci USA* 1986;**83**:2934-8.
- 10 **Germiño GG**, Weinstad-Saslow D, Himmelbauer H, Gillepsie GAJ, Somlo S, Wirth B, Barton N, Harris KL, Frischauf AM, Reeders ST. The gene for autosomal dominant polycystic kidney disease lies in a 750-kb CpG-rich region. *Genomics* 1992;**13**:144-51.
- 11 **The European Polycystic Kidney Disease Consortium**. The polycystic disease 1 gene encodes a 14 kb transcript and lies within a duplicated region on chromosome 16. *Cell* 1994;**77**:881-94.
- 12 **Burn TC**, Connors TD, Raay TJV, Dackowski WR, Millholland JM, Klinger KW, Landes GM. Generation of a transcriptional map for a 700 kb region surrounding the polycystic kidney disease type 1 (*PKD1*) and tuberous sclerosis type 2 (*TSC2*) disease genes on human chromosome 16p13.3. *Genome Res* 1996;**6**:525-37.
- 13 **Knight SJL**, Lese CM, Prechts KS, Kuc J, Ning Y, Lucas S, Regan R, Brenan M, Nicod A, Lawrie NM, Cardy DLN, Nguyen H, Hudson TJ, Riethman HC, Ledbetter DH, Flint J. An optimized set of human telomere clones for studying telomere integrity and architecture. *Am J Hum Genet* 2000;**67**:320-32.
- 14 **Wilkie AOM**, Buckle VJ, Harris PC, Lamb J, Barton NJ, Reeders ST, Lindenbaum RH, Nicholls RD, Barrow M, Bethlenfalvai NC, Hutz MH, Tolmie JL, Weatherall DJ, Higgs DR. Clinical features and molecular analysis of the alpha-thalassemia/mental retardation syndromes. Cases due to deletions involving chromosome band 16p13.3. *Am J Hum Genet* 1990;**46**:1112-26.
- 15 **Eussen BHJ**, Bartalini G, Bakker L, Balestri P, Di Lucca C, Van Hemel JO, Dauwense H, van den Ouweland AMW, Ris-Stalpers C, Verhoef S, Halley DJJ, Fois A. An unbalanced submicroscopic translocation t(8;16)(q24.3;p13.3)pat associated with tuberous sclerosis complex, adult polycystic kidney disease, and hypomelanosis of Ito. *J Med Genet* 2000;**37**:287-91.
- 16 **Verhoef S**, Bakker L, Tempelaars AMP, Hesselting-Jansen ALW, Mazurcak T, Jozwiak S, Fois A, Bartalini G, Zonnenberg BA, Eussen AJ, Lindhout D, Halley DJJ, Ouweland AMW. High rate of mosaicism in tuberous sclerosis complex. *Am J Hum Genet* 1999;**64**:1632-7.
- 17 **Germiño GG**. Autosomal dominant polycystic kidney disease: a two-hit model. *Hosp Pract* 1997;**32**:81-102.
- 18 **Brasier JL**, Henske EP. Loss of the polycystic kidney disease (*PKD1*) region of chromosome 16p13 in renal cyst cells supports a loss-of-function model for cyst pathogenesis. *J Clin Invest* 1997;**99**:194-9.
- 19 **Green A**, Smith M, Yates J. Loss of heterozygosity on chromosome 16p13.3 in hamartomas from tuberous sclerosis patients. *Nat Genet* 1994;**6**:193-6.