

SHORT REPORT

A phenocopy of CAII deficiency: a novel genetic explanation for inherited infantile osteopetrosis with distal renal tubular acidosis

K J Borthwick, N Kandemir, R Topaloglu, U Kornak, A Bakkaloglu, N Yordam, S Ozen, H Mocan, G N Shah, W S Sly, F E Karet

J Med Genet 2003;40:115-121

The rare bone thickening disease osteopetrosis occurs in various forms, one of which is accompanied by renal tubular acidosis (RTA), and is known as Guibaud-Vaincel syndrome or marble brain disease. Clinical manifestations of this autosomal recessive syndrome comprise increased bone density, growth failure, intracerebral calcification, facial dysmorphism, mental retardation, and conductive hearing impairment. The most common cause is carbonic anhydrase II (CAII) deficiency. Several different loss of function mutations in *CA2*, the gene encoding CAII, have been described. To date, there have been no exceptions to the finding of CAII deficiency in patients with coexistent osteopetrosis and RTA. Most often, the RTA is of mixed proximal and distal type, but kindreds are reported in which either distal or proximal RTA predominates.

We report the molecular genetic investigation of two consanguineous kindreds where osteopetrosis and distal RTA (dRTA) were both manifest. One kindred harbours a novel homozygous frameshift alteration in *CA2*. In the other, CAII levels were normal despite a similar clinical picture, and we excluded defects in *CA2*. In this kindred, two separate recessive disorders are penetrant, each affecting a different, tissue specific subunit of the vacuolar proton pump (H⁺-ATPase), providing a highly unusual, novel genetic explanation for the coexistence of osteopetrosis and dRTA. The osteopetrosis is the result of a homozygous deletion in *TCIRG1*, which encodes an osteoclast specific isoform of subunit a of the H⁺-ATPase, while the dRTA is associated with a homozygous mutation in *ATP6V1B1*, encoding the kidney specific B1 subunit of H⁺-ATPase.

This kindred is exceptional firstly because the coinheritance of two rare recessive disorders has created a phenocopy of CAII deficiency, and secondly because these disorders affect two different subunits of the H⁺-ATPase that have opposite effects on bone density, but which have only recently been determined to possess tissue specific isoforms.

The association of osteopetrosis and renal tubular acidosis (RTA) was first described in 1972, and it is also referred to as Guibaud-Vaincel syndrome or marble brain disease (MIM 259730, <http://www.ncbi.nlm.nih.gov/Omim/>).¹⁻³ Clinical manifestations of this autosomal recessive syndrome comprise increased bone density, intracerebral calcification, mental retardation, growth failure, and facial dysmorphism. In 1983, Sly *et al*⁴ showed that in patients with this syndrome, carbonic anhydrase II (CAII) activity in erythrocytes was absent, suggesting that this was the primary defect. Several different loss of function mutations in *CA2*, the gene encoding

this protein, have since been described. To date there have been no exceptions to the finding of CAII deficiency in patients with coexistent osteopetrosis and RTA. Most often, the RTA is of mixed proximal and distal type, consistent with the known expression pattern of *CA2* in both proximal convoluted tubule and collecting duct.⁵ However, kindreds are reported in which either distal or proximal RTA predominates.^{6,7} We report here two families where osteopetrosis and distal RTA (dRTA) were both manifest, but in one we could exclude defects in *CA2* as the cause and therefore sought an alternative genetic explanation.

METHODS

Participating families

Kindred 1

The index male, case A, was the first offspring of a central Turkish first cousin union (pedigree structure shown in fig 1). He was delivered spontaneously following a 40 week uncomplicated pregnancy, weighing 3080 g. At 10 days old and weighing 2960 g, he developed pneumonia, difficulty in feeding, and convulsions. Facial dysmorphism was prominent, with low set ears, hypertelorism, and a depressed nasal bridge.

Laboratory data on admission were as listed in table 1, showing hyperchloraemic metabolic acidosis. Urinary pH was 7 and remained higher than 5.5 during all episodes of spontaneous metabolic acidosis. There was transient trace proteinuria that resolved spontaneously; urine amino acids were normal. Following rehydration, renal function was otherwise normal. Alkaline phosphatase was raised and x rays showed generalised increased bone density, with a "bone within bone" appearance in the tubular bones (fig 2) characteristic of osteopetrosis.

Therapy was started with Shohl solution (citric acid and sodium citrate), vitamin D3, and temporary supplementation of calcium. He was readmitted at 2 months of age with fever, respiratory distress, and difficulty feeding. His weight had fallen further to 2750 g and length was 51 cm (<3rd centile). Physical examination disclosed pneumonia, pallor, and hepatosplenomegaly. He could fix his eyes to light and on his mother, and pupillary reactions were normal. He responded normally to sound, but compliance for auditory evoked responses could not be obtained. Laboratory data were as in table 1, showing persistence of the metabolic acidosis. Severe hypokalaemia subsequently developed, and distal renal tubular acidosis was diagnosed. The urinary Ca:Cr ratio was raised at 0.15-0.45 on several occasions during this admission. He had become markedly anaemic (Hb 7.2 g/dl). The total white cell count had risen to $32 \times 10^9/l$, and a peripheral blood smear showed a marked left shift.

Renal ultrasonography showed increased medullary echogenicity suggestive of nephrocalcinosis. Intracranial calcification was not observed on conventional radiography. The dose

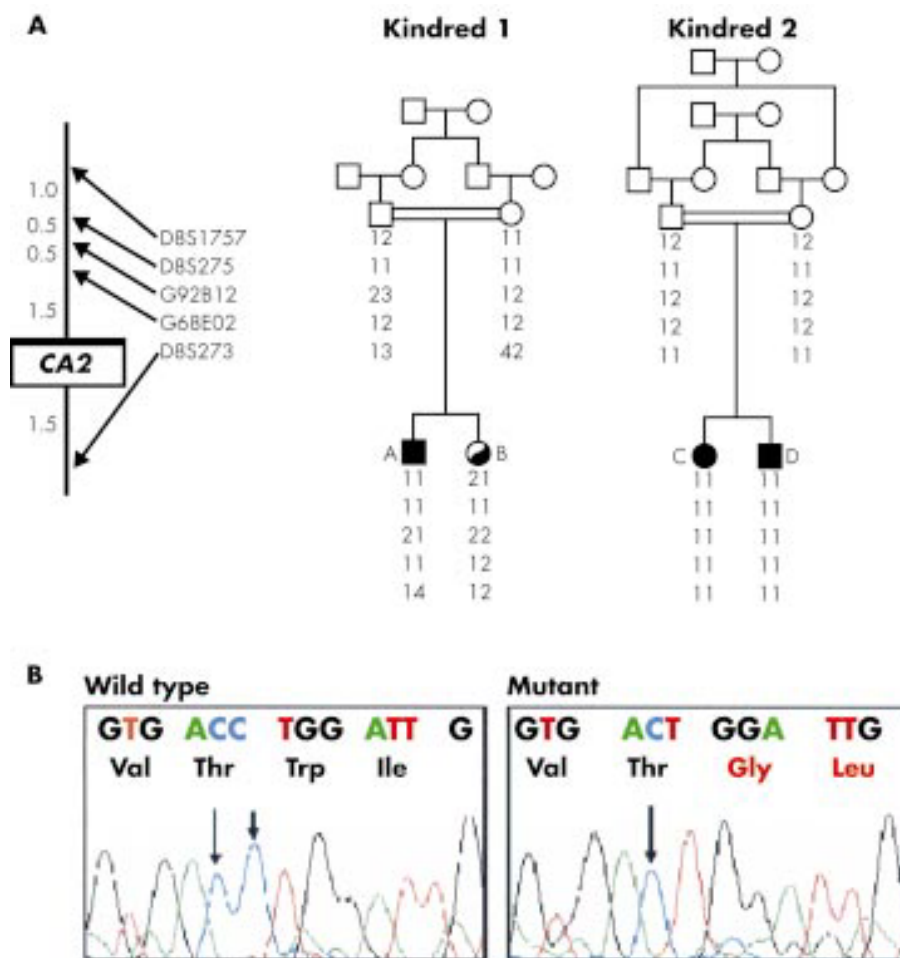


Figure 1 Genetic analysis of CA2. (A) The pedigree structures and genotypes at polymorphic loci tightly linked to CA2 are shown. On the left, marker order on chromosome 8 and the cM distances between them are indicated. Linkage is unlikely in kindred 1 by virtue of haplo-non-identity and heterozygosity (cases A and B), whereas there is homozygous identity by descent in both affected members of kindred 2 (C and D). (B) Direct sequencing of both affected members of kindred 2 showed a single nucleotide deletion in codon 207 (loss of the second arrowed cytosine). This results in 15 novel amino acids followed by a premature termination codon. Both unaffected parents were heterozygous for this mutation.

of Shohl solution was increased to 4-5 ml/kg and additional potassium supplementation was administered. However, he remained unwell with severe growth retardation and died at 12 months of age.

Case B, the sister of case A, presented at 3.5 months because of poor feeding and poor weight gain. She too was the product

of a normal, term pregnancy and delivery. She was also growth retarded (length 57 cm, 10th centile; weight 3500 g, <5th centile for age). Laboratory investigations (table 1) again showed hypokalaemic metabolic acidosis with inappropriately alkaline urine, consistent with dRTA. Mild hypercalciuria was present, and medullary nephrocalcinosis was found on renal

Table 1 Biochemical parameters of cases A and B (kindred 1), C and D (kindred 2)

Parameter	Case A, first admission	Case A, second admission	Case B	Case C	Case D
Plasma sodium (mEq/l)	138	141	135	139	138
Plasma potassium (mEq/l)	5.6	4.2 → 1.5 ^l	2.8 ^l	4.2	4.3
Plasma chloride (mEq/l)	120 ^h	118 ^h	111 ^h	123 ^h	109 ^h
Plasma bicarbonate (mEq/l)	10.9 ^l		13.1 ^l	10.7 ^l	13.5 ^l
Plasma creatinine (mg/dl)	0.7 ^h		0.4		
Plasma calcium (mg/dl)	5.5 ^l	9.2		8.6	9.3
Plasma phosphate (mg/dl)	5.2	3.9			
Plasma alkaline phosphatase (U/l)	1802 ^h	328			
Blood urea nitrogen (mg/dl)	23 ^h		21		
Arterial pH	7.18 ^l	7.05 ^h	7.28 ^l	7.28 ^l	7.35
Urine pH	7.0 ^h	7.0 ^h	7.0 ^h	8.0 ^h	7.0 ^h
Urine calcium	0.45 ^h mg/mg creatinine		0.18 ^h mg/mg creatinine	12.2 ^h mg/kg/day	
Hb (g/dl)	16.7 ^h	7.2 ^l			
White cells (10 ⁹ /l)	12.5 ^h	32 ^h			

^h = above the normal range for age; ^l = below the normal range for age.

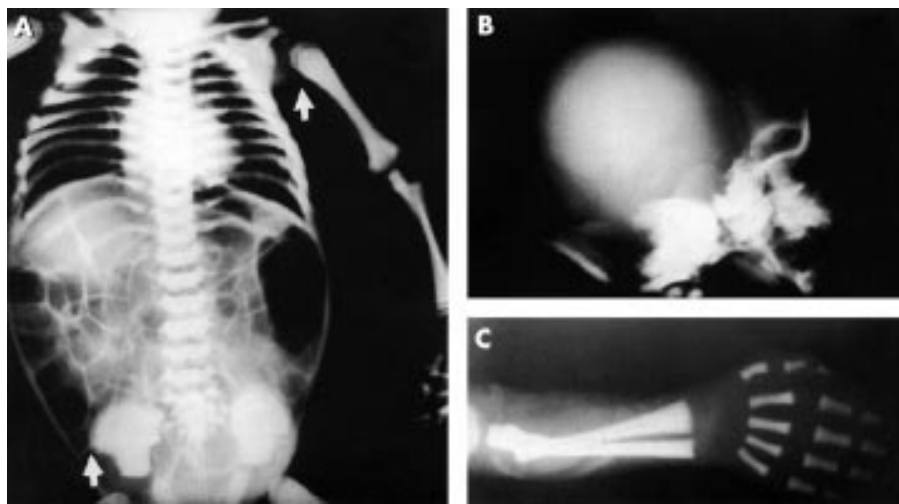


Figure 2 Radiographs of case A, at 10 days of age. There is a generalised increase in bone density. Typical features of osteopetrosis are the “bone in bone” appearance seen in the left humerus and iliac crests (A, arrows), and the severely sclerotic appearance of the skull base relative to the calvarium (B). Soft tissue calcification is evident in (C).

ultrasound. Neither amino aciduria nor glycosuria was detected. Unlike her brother, she showed no sign of osteopetrosis on skeletal x ray at initial or subsequent assessment.

Oral potassium and bicarbonate supplementation in the form of Shohl solution and potassium citrate were started. She had less severe growth failure than her brother, but still weighed only 6 kg with length 70 cm at 12 months old. Audiography performed at the age of 3 years showed bilateral sensorineural hearing loss, which first became clinically evident three months earlier.

Kindred 2

This kindred was from northern Turkey and the two affected children were the product of a double first cousin union (fig 1). The female index case (case C) presented at the age of 8 years for evaluation of blindness, which had first been noted when she was 2 years old, and which was accompanied by severe growth impairment (<3rd centile for age), global mental retardation, conductive hearing loss, and calcification of the basal ganglia. Initial biochemical investigations, shown in table 1, were consistent with distal renal tubular acidosis, as in kindred 1. In addition, the urine anion gap was positive at 33.1.⁸ Amino aciduria, glycosuria, or bicarbonaturia were not detected, suggesting preserved proximal tubular function. Nephrocalcinosis was detectable by ultrasound and she had marked hypercalcaemia. Based on similar radiological appearances to case A, the child was diagnosed as having osteopetrosis and was started, and has been maintained, on Shohl solution. Her brother (case D) came to medical attention at the same time, with almost identical problems and biochemical profile, at the age of 3 years. He also receives Shohl solution. These children are now 13 and 8 years old.

Linkage analysis

Ethical approval for genetic studies was granted by the Cambridge Local Ethical Research Committee (99/078). Polymorphic loci flanking *CA2*, *ATP6V1B1* (previously known as *ATP6B1*), and *TCIRG1* on chromosomes 8, 2, and 11 respectively were typed by PCR amplification of genomic DNA extracted from peripheral blood.⁹ Incorporation of [α -³²P]dCTP (Amersham Pharmacia Biotech, Little Chalfont, Buckinghamshire, UK) into the reaction mix was followed by electrophoresis under denaturing conditions and autoradiography, as previously described.¹⁰ SNPs located within *ATP6V1B1* that had been identified during previous mutation analysis¹¹ were typed by restriction digest and agarose gel

electrophoresis following PCR amplification using primers in flanking sequences.

Genomic sequencing

All coding exons and flanking intronic regions of *CA2*, *ATP6V1B1*, and *TCIRG1* were amplified and sequenced on an ABI-377 machine using the ABI Prism BigDye™ kit, according to the manufacturer's protocol (PE Applied Biosystems, Foster City, CA, USA). Identified mutations were confirmed by repeat PCR amplification and sequencing on the opposite strand. The missense alteration G78R in *ATP6V1B1* (see results) was typed in both parents and in 40 unrelated unaffected subjects by RFLP analysis using *Bsr*BI (New England Biolabs, Hitchin, UK). Exon 7 of *TCIRG1* was separately amplified by PCR in all members of kindred 1 and products resolved by agarose gel electrophoresis.

Measurement of carbonic anhydrase II

CAII activity for enzymatic diagnosis was assessed by the end point titration assay as previously described; CAI activities were calculated by subtraction from the totals.^{12,13}

RESULTS

The diagnosis of osteopetrosis with distal RTA was made in each kindred on the basis of clinical presentation, biochemical and haematological abnormalities, and radiographic features in the index cases. In kindred 2, the genetic cause of the syndrome was typical: a destructive mutation in *CA2*, as predicted by CAII activity which showed very low levels in both children and intermediate activity in both carrier parents (table 2), and by linkage analysis that showed homozygous identity by descent (fig 1A) at the *CA2* locus. Both children were homozygous for the deletion of a single cytosine in *CA2*, lost from codon 207 (fig 1B). The resulting novel 15 amino acids culminate in a premature termination codon.

While it was clear in kindred 1 that the index case had radiographic evidence of osteopetrosis, it was not apparent whether his sister (case B) had isolated dRTA or was simply failing to manifest radiographic changes of osteopetrosis because of the severity of her systemic acidosis, which is said to ameliorate the increase in bone density.⁶ With increasing age, osteopetrosis still remained absent in case B and it became more likely that two separate disorders were penetrant in this consanguineous family. The subsequent genetic investigations have confirmed this.

In contrast to kindred 2, activity of CAII was not reduced in any family member in this kindred (table 2). As shown in fig

Table 2 Carbonic anhydrase isoenzyme I and II activity in red blood cells

	Total CA (U/mg Hb)	CAII	CAI
Case A	30.0	16.2	13.8
Case B	12.5	6.2	6.3
Father	17.3	8.4	8.9
Mother	15.6	7.7	7.9
Case C	7.7	1.1	6.6
Case D	9.7	0.6	9.1
Father	11.8	4.1	7.6
Mother	11.7	4.5	7.2

Normal ranges (mean (SEM)): total CA 16.4 (3.0) U/mg Hb, CAII 8.1 (2.0) U/mg Hb.
CAI levels calculated following addition of NaI.^{12, 13}

1A, linkage to *CA2* could theoretically be excluded whether one or both children had osteopetrosis. The close consanguinity of the parents predicts homozygosity in an affected child across this segment of chromosome 8 by descent from one carrier great grandparent. The index case was heterozygous at this locus and, in addition, the two sibs were not haploidentical. Moreover, direct sequencing of all coding exons and exon-intron boundaries of *CA2* in both children did not show any sequence alterations.

In view of the presence of sensorineural rather than conductive hearing loss in conjunction with dRTA in the surviving sib, we examined linkage to *ATP6V1B1*. This gene,

which encodes the kidney specific B1 subunit of the apical H⁺-ATPase (proton pump) responsible for urine acidification in the collecting duct, has been previously found to cause the syndrome of dRTA with deafness (MIM 267300).¹¹ Linkage could not be excluded, as both children were homozygous by descent (fig 3A). We found that both children were homozygous for a missense mutation altering glycine at position 78 to arginine (fig 3B). This change resulted in loss of a *BsrBI* restriction site that was subsequently used to show that both parents were heterozygous (fig 3C), and that the alteration was absent from 80 control chromosomes.

We next assessed candidacy of *TCIRG1* as the causative gene to account for the osteopetrosis in case A. This gene has recently been identified as the cause of isolated recessive malignant osteopetrosis.^{14, 15} It encodes the osteoclast specific $\alpha 3$ isoform of the large accessory subunit in the H⁺-ATPase responsible for acidification at the osteoclast-bone interface. Linkage analysis showed that he was homozygous across this segment while his sister was not (fig 4A), and he was discovered to have a novel, homozygous 26 bp deletion starting in codon 216 (fig 4B), resulting in an almost immediate termination codon that would severely truncate the protein. His sister and both parents were heterozygotes, as shown by PCR amplification of this region of the gene (fig 4C).

DISCUSSION

The hereditary skeletal disorder osteopetrosis is primarily characterised by increased bone radiodensity. The neurological manifestations of blindness and deafness in osteopetrosis are usually attributed to nerve compression by the abnormal and

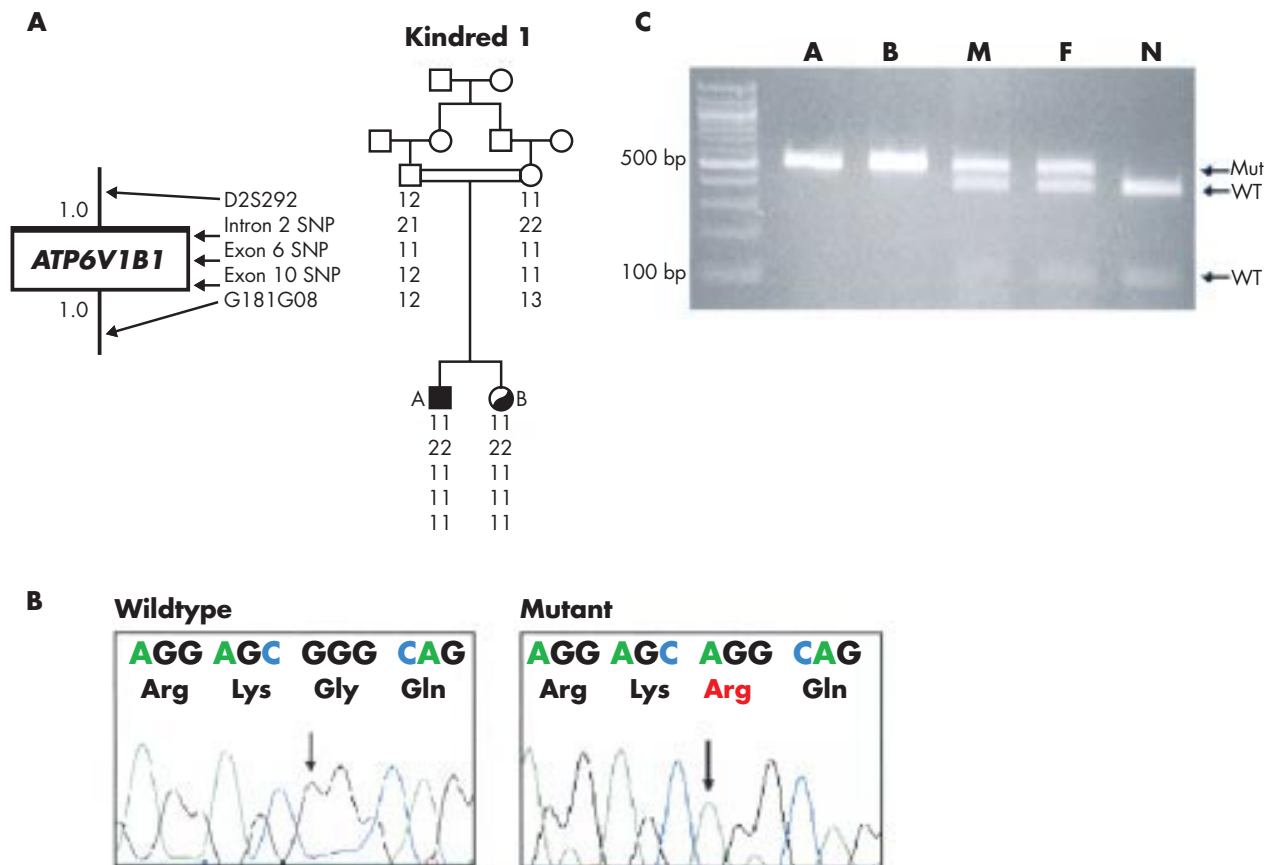


Figure 3 Genetic analysis of *ATP6V1B1* in kindred 1. (A) Linkage is possible by virtue of homozygosity in both affected offspring. Markers and distances on chromosome 2 are displayed as in fig 1. (B) Direct sequencing in both affected subjects showed a homozygous G to A nucleotide substitution in codon 78, altering glycine to arginine. (C) This mutation removes a *BsrBI* restriction site. PCR amplification of this exon followed by digestion showed that both unaffected parents (F, M) were heterozygous carriers. Mutant (mut) = 505 bp; wild type (WT) = 400 + 105 bp. N = WT control.

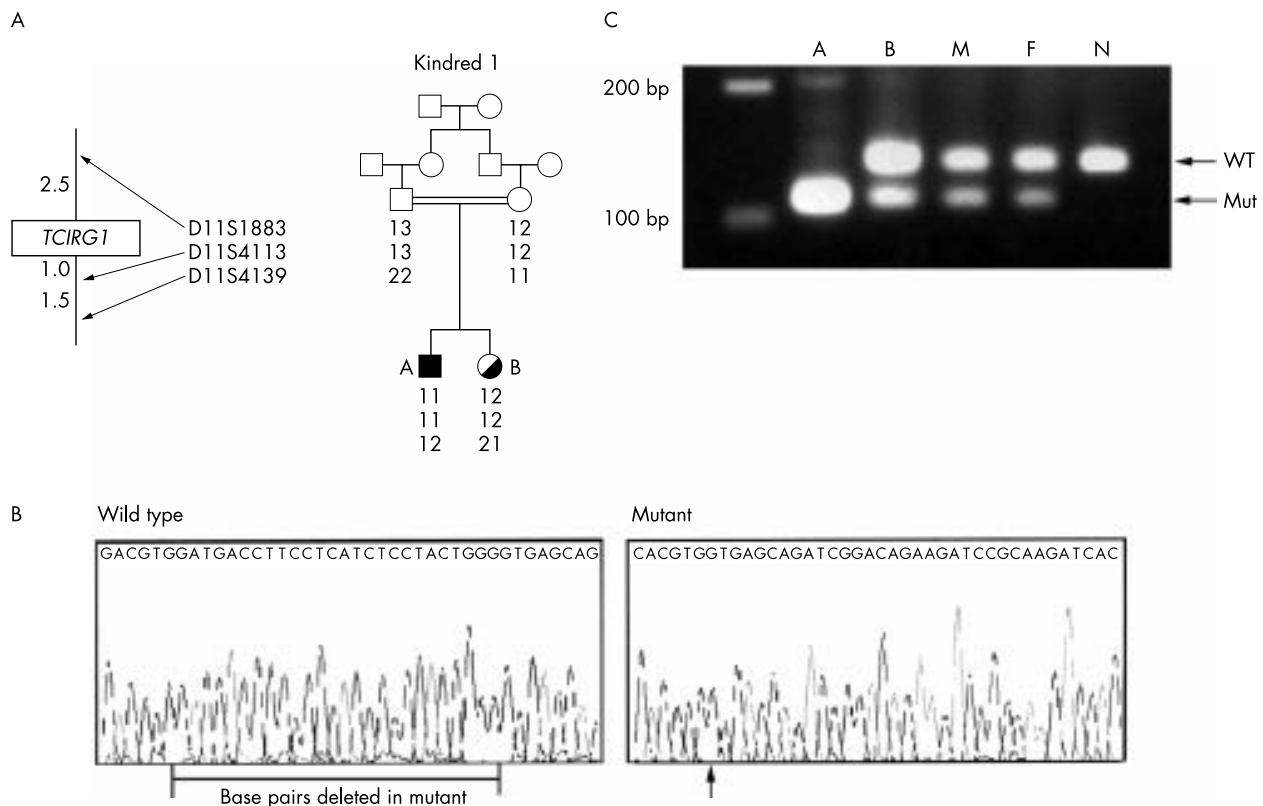


Figure 4 Genetic analysis of *TCIRG1* in kindred 1. (A) Only the index case is likely to harbour mutations in this gene. Markers and distances on chromosome 11 are displayed as in fig 1. (B) Direct sequencing in the index case showed a homozygous 26 bp deletion starting at W216 in exon 7. (C) This mutation permits resolution by product size difference following PCR amplification of this exon. Both unaffected parents and sib were heterozygous carriers. WT = 138 bp; mut = 112 bp.

deformed bone. It occurs in several forms; those arising as recessive traits are usually much more severe than the autosomal dominant type.^{16,17} In addition, the “infantile malignant” form caused by mutation in *TCIRG1* is generally even more severe than the commoner variety resulting from CAII deficiency. In contrast, bone mineral density is decreased by the acidosis of distal RTA, with overt rickets appearing in untreated cases, and the associated hearing impairment is sensorineural rather than conductive.

Until now, the association of osteopetrosis with RTA has always implied that *CA2* is the responsible gene. The novel destructive *CA2* mutation we found in the second kindred adds to the 16 different mutations previously reported in families with CAII deficiency syndrome.^{18,19} The commonest of these, colloquially known as the Arabic mutation, leads to loss of the donor splice junction of intron 2.²⁰ It accounts for almost all cases in North Africa and the Arabian peninsula, which comprise 75% of all those reported. An interesting study found that affected families were all descended from the same nomadic tribe (Helal) in the 10th century.²⁰ Despite the appearance of this tribe as far north as Greece, CAII deficiency has never been reported in Turkey until this year. In addition to the second kindred described here, with its novel *CA2* mutation, a recent report identified another Turkish kindred with this syndrome²¹; however, apart from excluding the Arabic mutation, no further genetic information was presented.

At first glance, kindred 1 might have fit the diagnostic mould of CAII deficiency, with case B escaping radiological detection of bone thickening because of demineralisation secondary to the systemic acidosis, as has previously been suggested.⁶ Strikingly, however, carbonic anhydrase II levels were not diminished in any member of this family, and our genetic studies showed that *CA2* could not be the responsible gene.

Kindred 1 is particularly unusual because we have found two separate genetic traits that affect bone density in opposite ways, since dRTA is associated with osteopenia. Recessive osteopetrosis was diagnosed in the first child of this family because of the typical symptoms in early infancy. Although detailed studies of auditory and optic nerves could not be performed, retinal examination showed peripapillary chorioretinal atrophy, which is also compatible with osteopetrosis.²² Despite appropriate attempts to correct the metabolic effects, case A failed to thrive and when he died still weighed only 3500 g, with length 53 cm. The severity of the metabolic derangement, very young age at presentation, and resistance to appropriate therapy would have been unusual for CAII deficiency, but is more in keeping with the infantile malignant form. The presence of the homozygous destructive mutation in *TCIRG1*, causing loss of the $\alpha 3$ subunit from osteoclast proton pumps, combined with primary recessive dRTA, suggests that his poor clinical progress despite treatment was probably inevitable. Bone marrow transplantation might have been considered had he survived, but while this is reported to rescue the bone disease of CAII deficiency, it cannot ameliorate the RTA.²³

The second child’s hearing impairment, in the absence of osteopetrosis, but in the context of distal renal tubular acidosis, led to the assessment of *ATP6V1B1* as a causative gene.¹¹ It became evident that both cases A and B have this recessive form of dRTA. The mutation we identified is novel and is unlikely to represent a neutral polymorphism. Firstly, it was absent in controls, secondly it replaces a neutral hydrophobic residue with a positively charged hydrophilic one, and thirdly it lies in a domain of the encoded protein whose β barrel conformation is particularly well conserved across species. Furthermore, other disease causing mutations have been identified in this same domain.¹¹

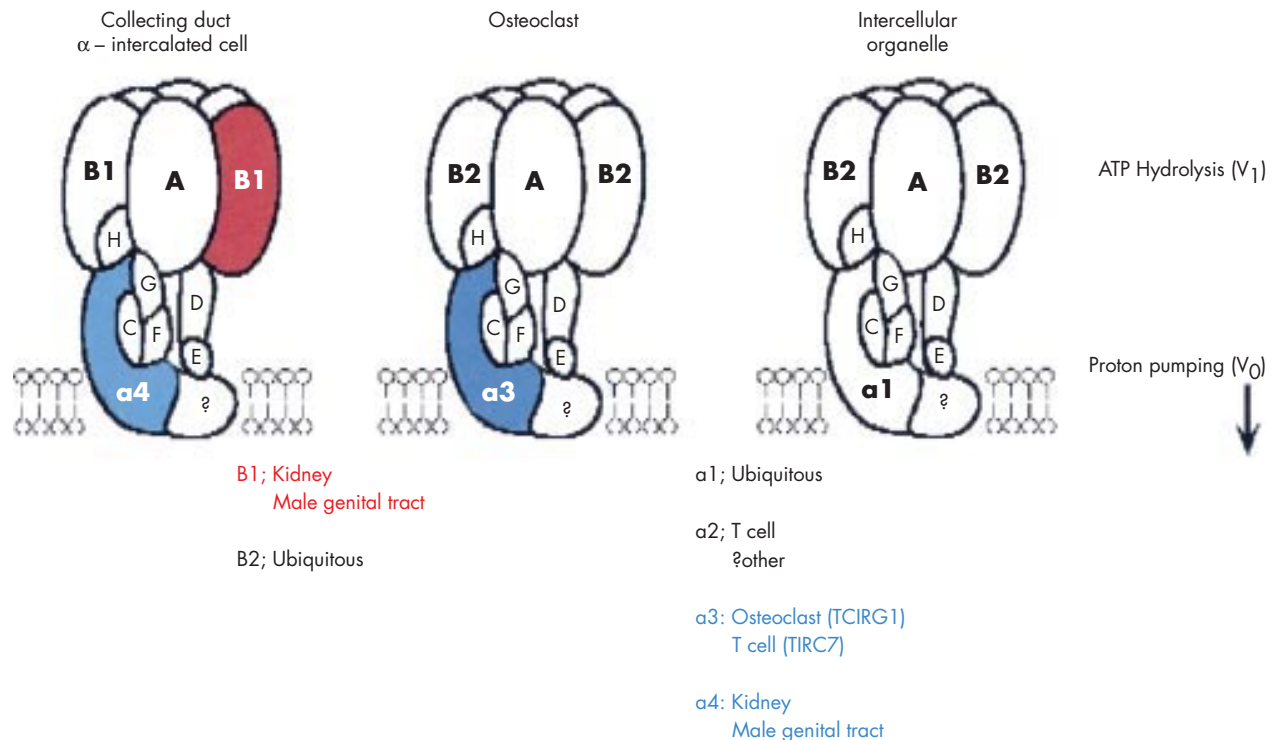


Figure 5 General structure of the vacuolar H⁺-ATPase. The multi-subunit proton pump is divided into V₁ and V₀ domains, subserving ATP hydrolytic and proton translocation functions respectively. The B subunit is necessary, but not on its own sufficient, for ATP hydrolysis by the V₁ domain. The contribution of the 116 kDa α subunit (also known as the large accessory subunit) to overall pump function is unknown. Composition of the ubiquitously expressed intracellular pump is depicted on the right. At specialised sites of acid transport, different subunits are substituted as shown. The α3 subunit has long and short transcripts, *TCIRG1* and *TIRC7*; the latter is of unknown function.

These two inherited disorders affect two different subunits of the vacuolar proton pump that have only in recent years been determined to possess tissue specific isoforms. The B and α subunits are known to be encoded by two and four different genes respectively, and this knowledge has in part been derived from the investigation of rare Mendelian kindreds. B1 is one of the subunit isoforms that makes the H⁺-ATPase on the luminal membrane of the kidney α intercalated cell unique, and α3 is the only known osteoclast specific subunit of the H⁺-ATPase (fig 5). Although their overall multi-subunit composition is probably the same, the ubiquitously expressed intracellular proton pumps that are responsible for organelle acidification contain the B2 and α1 subunits. Proper function of proton pumps containing the tissue specific gene products, present at high density at the cell surface, is essential for homeostasis in both kidney and bone. The B subunit, forming part of the V₁ catalytic domain responsible for ATP hydrolysis, is known to be necessary for this hydrolysis to proceed.²⁴ In contrast, the contribution of the α subunit to overall pump function has yet to be elucidated in mammals. Evidence from yeast studies suggests its involvement in transmembrane proton translocation and/or stabilisation of the pump complex.^{25 26}

TCIRG1 contains two transcription initiation sites, upstream of exon 1 and within exon 5 respectively.²⁷ The shorter transcript, *TIRC7*, is reported to be expressed only in the immune system. The 26 bp deletion observed in case A removes *TIRC7*'s initial methionine codon, in addition to severely truncating α3. This begs the question of whether the haematological abnormalities observed in case A are attributable to previously recognised osteopetrotic marrow failure, or whether loss of *TIRC7* predicted by the mutation might be

relevant. However, to date, the potential functions of the *TIRC7* protein have not been characterised.

This kindred is also noteworthy in that the two rare recessive genetic disorders present in the index case together create a phenocopy of a third. This sibship illustrates the importance of clinical characterisation of all affected members of such a kindred. It is difficult in this population, where consanguinity is prevalent, to estimate the allele frequency for either recessive osteopetrosis or dRTA. Using a figure of 1:200 for either, the odds of case A inheriting both traits would be tens of millions to 1.

ACKNOWLEDGEMENTS

The second and third authors contributed equally to this work. This work was supported by the Wellcome Trust, of which KJB is a Prize student and FEK is a Senior Clinical Research Fellow. We thank the families for their participation, and Annabel Smith for invaluable assistance.

Authors' affiliations

K J Borthwick, F E Karet, Department of Medical Genetics, Cambridge University, Cambridge, UK
 N Kandemir, R Topaloglu, A Bakkaloglu, N Yordam, S Ozen, Faculty of Medicine, Hacettepe University, Ankara, Turkey
 N Kandemir, A Bakkaloglu, N Yordam, Division of Paediatric Endocrinology and Rheumatology, Hacettepe University, Ankara, Turkey
 R Topaloglu, S Ozen, Division of Paediatric Nephrology, Hacettepe University, Ankara, Turkey
 U Kornak, Zentrum für Molekulare Neurobiologie Hamburg, Hamburg University, Hamburg, Germany
 H Mocan, Department of Paediatrics, Metropolitan Florence Nightingale Hospital, Istanbul, Turkey

G N Shah, W S Sly, E A Doisy Department of Biochemistry, St Louis University School of Medicine, St Louis, Missouri, USA
F E Karet, Division of Nephrology, Cambridge University, Cambridge, UK

Correspondence to: Dr F E Karet, Cambridge Institute for Medical Research, Box 139, Addenbrooke's Hospital, Cambridge CB2 2XY, UK; fek1000@cam.ac.uk

Revised version received 9 October 2002
 Accepted for publication 10 October 2002

REFERENCES

- Guibaud P**, Larbre F, Freycon MT, Genoud J. Osteopetrosis and renal tubular acidosis. 2 cases of this association in a sibship. *Arch Fr Pediatr* 1972;**29**:269-86.
- Vaincel M**, Fondou P, Cadranel S, Rocmans C, Gepts W. Osteopetrosis associated with proximal and distal tubular acidosis. *Acta Paediatr Scand* 1972;**61**:429-34.
- Sly WS**, Lang R, Avioli L, Lubowitz H, McAlister W. Recessive osteopetrosis: new clinical phenotype. *Am J Hum Genet* 1972;**24**:34A
- Sly WS**, Hewett-Emmett D, Whyte MP, Yu YS, Tashian RE. Carbonic anhydrase II deficiency identified as the primary defect in the autosomal recessive syndrome of osteopetrosis with renal tubular acidosis and cerebral calcification. *Proc Natl Acad Sci USA* 1983;**80**:2752-6.
- Lonnerholm G**, Wistrand PJ. Carbonic anhydrase in the human kidney: a histochemical and immunocytochemical study. *Kidney Int* 1984;**25**:886-98.
- Whyte MP**, Murphy WA, Fallon MD, Sly WS, Teitelbaum SL, McAlister WH, Avioli LV. Osteopetrosis, renal tubular acidosis and basal ganglia calcification in three sisters. *Am J Med* 1980;**69**:64-74.
- Strisciuglio P**, Hu PY, Lim EJ, Ciccolella J, Sly WS. Clinical and molecular heterogeneity in carbonic anhydrase II deficiency and prenatal diagnosis in an Italian family. *J Pediatr* 1998;**132**:717-20.
- Batille DC**, Hizon M, Cohen E, Guterman C, Gupta R. The use of the urinary anion gap in the diagnosis of hyperchloremic metabolic acidosis. *N Engl J Med* 1988;**318**:594-9.
- Bell GI**, Karam JH, Rutter WJ. Polymorphic DNA region adjacent to the 5' end of the human insulin gene. *Proc Natl Acad Sci USA* 1981;**78**:5759-63.
- Shimkets RA**, Warnock DG, Bositis CM, Nelson-Williams C, Hansson JH, Schambelan M, Gill JR, Jr., Ulick S, Milora RV, Findling JW, Canessa CM, Rossier BC, Lifton RP. Liddle's syndrome: heritable human hypertension caused by mutations in the beta subunit of the epithelial sodium channel. *Cell* 1994;**79**:407-14.
- Karet FE**, Finberg KE, Nelson RD, Nayir A, Mocan H, Sanjad SA, Rodriguez-Soriano J, Santos F, Cremers CW, Di Pietro A, Hoffbrand BI, Winiarski J, Bakkaloglu A, Ozen S, Dusunsel R, Goodyer P, Hulton SA, Wu DK, Skvorak AB, Morton CC, Cunningham MJ, Jha V, Lifton RP. Mutations in the gene encoding B1 subunit of H⁺-ATPase cause renal tubular acidosis with sensorineural deafness. *Nat Genet* 1999;**21**:84-90.
- Maren ET**. A simplified micromethod for the determination of carbonic anhydrase and its inhibitors. *J Pharmacol Exp Ther* 1960;**130**:26-9.
- Sundaram V**, Rumbolo P, Grubb J, Strisciuglio P, Sly WS. Carbonic anhydrase II deficiency: diagnosis and carrier detection using differential enzyme inhibition and inactivation. *Am J Hum Genet* 1986;**38**:125-36.
- Fratini A**, Orchard PJ, Sobacchi C, Giliani S, Abinun M, Mattsson JP, Keeling DJ, Andersson AK, Wallbrandt P, Zecca L, Notarangelo LD, Vezzoni P, Villa A. Defects in the TCIRG1 subunit of the vacuolar proton pump are responsible for a subset of human autosomal recessive osteopetrosis. *Nat Genet* 2000;**25**:343-6.
- Kornak U**, Schulz A, Friedrich W, Uhlhaas S, Kremens B, Voit T, Hasan C, Bode U, Jentsch TJ, Kubisch C. Mutations in the $\alpha 3$ subunit of the vacuolar H⁺-ATPase cause infantile malignant osteopetrosis. *Hum Mol Genet* 2000;**9**:2059-63.
- Horton WA**, Schimke RN, Iyama T. Osteopetrosis: further heterogeneity. *J Pediatr* 1980;**97**:580-5.
- Kaibara N**, Katsuki I, Hotokebuchi T, Takagishi K. Intermediate form of osteopetrosis with recessive inheritance. *Skeletal Radiol* 1982;**9**:47-51.
- Hu PY**, Lim EJ, Ciccolella J, Strisciuglio P, Sly WS. Seven novel mutations in carbonic anhydrase II deficiency syndrome identified by SSCP and direct sequencing analysis. *Hum Mutat* 1997;**9**:383-7.
- Sly WS**, Shah G. Osteopetrosis with renal tubular acidosis and cerebral calcification. In: Scriver C, ed. *The metabolic and molecular bases of inherited disease*. 8th ed. New York: McGraw-Hill, 2001:5331-43.
- Fathallah DM**, Bejaoui M, Lepaslier D, Chater K, Sly WS, Dellagi K. Carbonic anhydrase II (CA II) deficiency in Maghrebians patients: evidence for founder effect and genomic recombination at the CA II locus. *Hum Genet* 1997;**99**:634-7.
- Ocal G**, Berberoglu M, Adiyaman P, Cetinkaya E, Ekim M, Aycan Z, Evliyaoglu O. Osteopetrosis, renal tubular acidosis without urinary concentration abnormality, cerebral calcification and severe mental retardation in three Turkish brothers. *J Pediatr Endocrinol Metab* 2001;**14**:1671-7.
- Ruben JB**, Morris RJ, Judisch GF. Chorioretinal degeneration in infantile malignant osteopetrosis. *Am J Ophthalmol* 1990;**110**:1-5.
- McMahon C**, Will A, Hu P, Shah GN, Sly WS, Smith OP. Bone marrow transplantation corrects osteopetrosis in the carbonic anhydrase II deficiency syndrome. *Blood* 2001;**97**:1947-50.
- Liu Q**, Kane PM, Newman PR, Forgac M. Site-directed mutagenesis of the yeast V-ATPase B subunit (Vma2p). *J Biol Chem* 1996;**271**:2018-22.
- Leng XH**, Manolson MF, Liu Q, Forgac M. Site-directed mutagenesis of the 100-kDa subunit (Vph1p) of the yeast vacuolar (H⁺)-ATPase. *J Biol Chem* 1996;**271**:22487-93.
- Leng XH**, Manolson MF, Forgac M. Function of the COOH-terminal domain of Vph1p in activity and assembly of the yeast V-ATPase. *J Biol Chem* 1998;**273**:6717-23.
- Heinemann T**, Bulwin GC, Randall J, Schnieders B, Sandhoff K, Volk HD, Milford E, Gullans SR, Utku N. Genomic organization of the gene coding for TIRC7, a novel membrane protein essential for T cell activation. *Genomics* 1999;**57**:398-406.