

# Cryptic terminal deletion of chromosome 9q34: a novel cause of syndromic obesity in childhood?

V Cormier-Daire, F Molinari, M Rio, O Raoul, M-C de Blois, S Romana, M Vekemans, A Munnich, L Colleaux

*J Med Genet* 2003;**40**:300–303

Obesity is a symptom of diagnostic value in multiple congenital anomaly-mental retardation syndromes. While acquired non-specific weight gain related to drug intake or associated behavioural disorders occasionally occurs in the course of mental retardation, obesity is known to be a specific feature of several well defined conditions, including Bardet-Biedl syndrome, Prader-Willi syndrome, Cohen syndrome, fragile X syndrome, and several chromosomal anomalies. Yet a number of mentally retarded children with apparently early onset weight gain remain undiagnosed. Here, we report on a de novo deletion of chromosome 9q34 in two unrelated mentally retarded children with early onset obesity, distinctive facial features (brachycephaly, synophrys, anteverted nostrils, prognathism), sleep disturbances, and behavioural problems. FISH and microsatellite DNA analyses showed that the two children carried a similar small deletion (3 Mb) of the terminal long arm of chromosome 9 (del 9q34). We suggest therefore that the del 9q34 is a novel cause of syndromic obesity and mental retardation. Its association with distinctive facial features and behavioural problems should help in recognising this novel phenotype. Based on this observation, we suggest giving consideration to cryptic deletions of chromosome 9q34 in the diagnosis of unexplained obesity/mental retardation syndromes

## CASE REPORTS

### Case 1

A boy was born to unrelated, healthy parents after a term pregnancy and normal delivery (birth weight 3200 g, length 50 cm, OFC 34.5 cm). He was hypotonic in the first months of life but no feeding difficulties were originally noted. Excessive weight gain with increased appetite and food seeking behaviour were noted at 30 months of age. At 5 years, his weight was 26 kg ( $> +3$  SD), length 112 cm ( $+1$  SD), and OFC 48 cm ( $-2$  SD) and at 9 years his weight was 72 kg ( $> +6$  SD), length 144 cm ( $+2$  SD), and OFC 52.5 cm ( $-0.5$  SD) (figs 1A-C and 2A).

### Key points

- We report on a de novo deletion of chromosome 9q34 in two unrelated mentally retarded children. The phenotype includes early onset weight gain, distinctive facial features (brachycephaly, synophrys, anteverted nostrils, prognathism), sleep disturbances, and behavioural problems.
- FISH and microsatellite DNA analysis showed that the two children carried a similar small deletion (3 Mb) of the terminal long arm of chromosome 9 (del 9q34).
- We suggest therefore giving consideration to cryptic deletions of chromosome 9q34 in the diagnosis of unexplained obesity/mental retardation syndromes.

Distinctive facial features included brachycephaly, flat face, high forehead, synophrys, hypertelorism, anteverted nostrils, thin upper lip, prognathism, short hands, syndactyly of toes 2-3, (fig 1A-C), and abnormal genitalia (cryptorchidism and hypospadias). He had major developmental delay (head control at 11 months, walked unaided at 23 months, no speech at 9 years). Cerebral MRI showed partial frontal atrophy. Psychometric evaluation at 9 years showed performance at a 2 year old level (DQ=50). He was hyperactive, with a short attention span, intolerance to frustration, and sleep disturbances with repeated night awakenings.

### Case 2

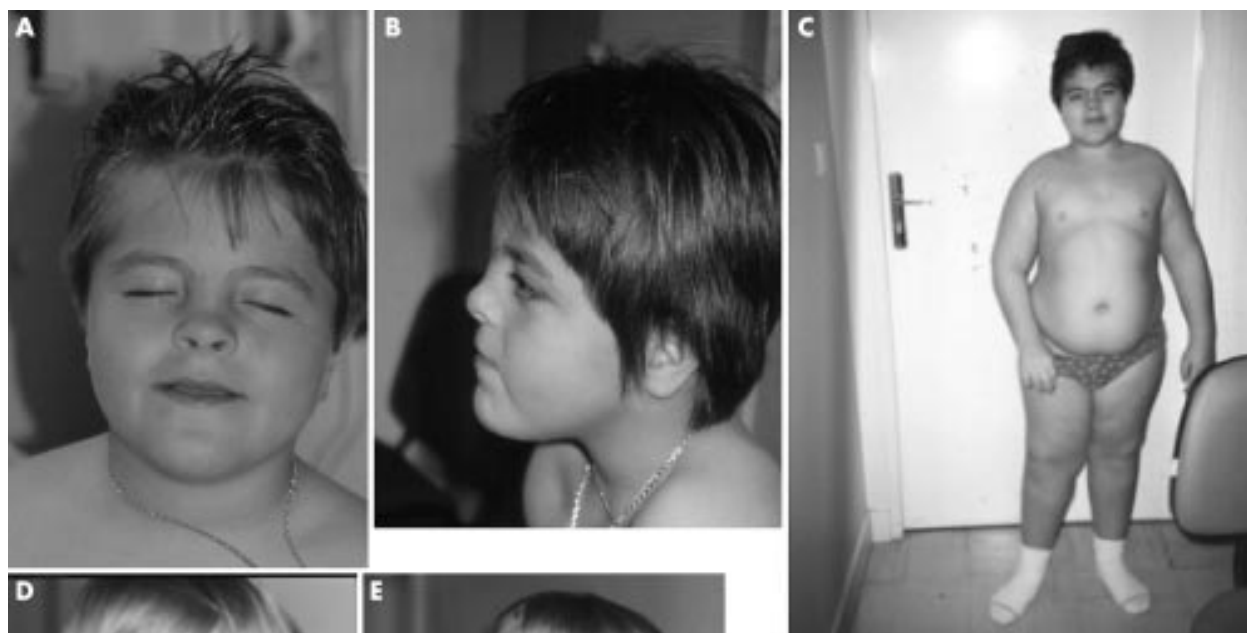A boy was born to healthy, unrelated parents. A karyotype performed at 30 weeks of pregnancy for the ultrasound detection of prognathism was normal (46,XY). Growth parameters at term were normal (weight 3920 g, length 50 cm, OFC 33 cm). At 3 months of age, he was hypotonic with poor visual contact. Excessive weight gain began at 22 months of age (weight 14.5 kg ( $> +2$  SD), height 85 cm (normal), OFC 46 cm ( $-2$  SD)) (fig 2B) and he was put on a low calorie diet. Dysmorphic features included brachycephaly, macroglossia, coarse facies, prognathism, synophrys, short nose, thin upper lip, short neck, and short extremities (fig 1 D, E). He also had abnormal genitalia with cryptorchidism, micropenis, and hypospadias. An atrial septal defect was detected at the systematic heart survey. Skeletal x rays showed small epiphyses, one rostral vertebra, and mild metaphyseal enlargement. He was able to sit unaided at 12 months. At 22 months, he was unable to walk and had no speech. The parents mentioned sleep disturbances with repeated night awakenings and stereotypic hand movements. CT scan and EEG were normal.

Amino acid chromatographies, blood lactate and pyruvate, liver function, blood ammonia, and lysosomal and peroxysomal screenings were normal in the two children. Normal blood glucose (4.3 mmol/l) and plasma lipids, no hyperinsulinaemia, and high level of leptin were noted. Low levels of thyroxine (T4 9 pmol/l, normal 10-20) were noted in case 1 only.

Routine G banding and R banding chromosome analysis of peripheral blood lymphocytes showed a normal 46,XY karyotype with no evidence of deletions or duplications. High resolution karyotypes were normal as well. Fragile X and Prader-Willi syndromes were excluded.

## MOLECULAR AND CYTOGENETIC ANALYSES

Based on the association of dysmorphic features with mental retardation, abnormal behaviour, and cerebral anomalies, patient 1 was investigated for subtelomeric rearrangements using automated fluorescent genotyping of telomeric markers.<sup>1,2</sup> As previously reported,<sup>2</sup> this analysis showed the irregular inheritance of a microsatellite DNA marker at locus D9S1838 with a single paternal contribution and no maternal contribution at this locus (table 1). Segregation of additional polymorphic markers of chromosome 9 and other chromosomes showed regular biparental inheritance (data not



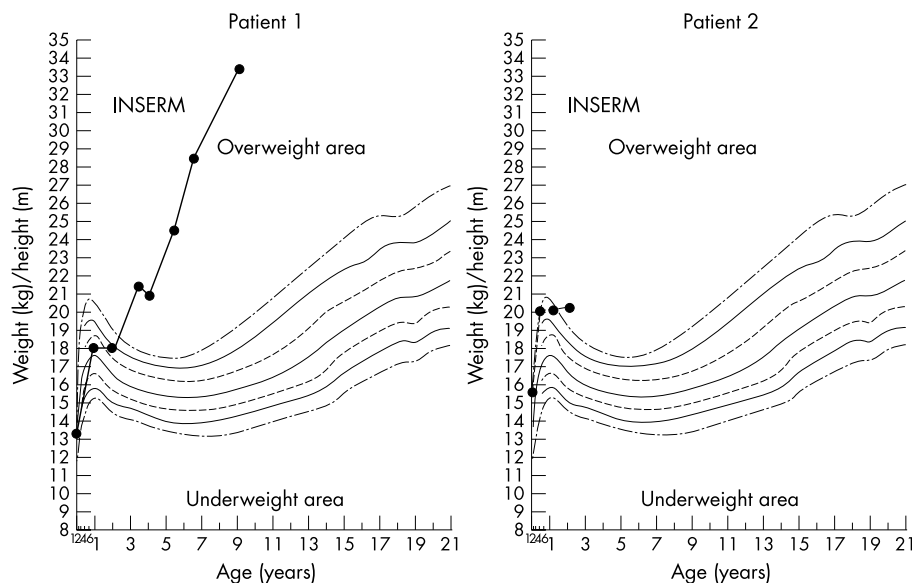
**Figure 1** Clinical features in the 9q34 deletion syndrome. Patient 1 at 4 years (A, B) and 9 years (C). Note the flat face with hypertelorism and anteverted nostrils. Patient 2 at 22 months (D, E). Note the coarse facies with prognathism and synophrys.

shown). FISH analyses using a probe specific for distal chromosome 9q<sup>3</sup> on metaphase nuclei from cultured skin fibroblasts of the proband and his parents' lymphocytes confirmed our finding and showed that the deletion occurred de novo (not shown). The child therefore carried a small de novo deletion of his maternal chromosome 9q34. Clinical and dysmorphic similarities with patient 1 prompted us to test the terminal region of chromosome 9q in patient 2. Microsatellite

DNA and FISH analyses showed that the child carried a similar 9q34 deletion of 3 Mb (from D9S158 to the telomere). In this case also, the rearrangement occurred de novo, but involved the paternal chromosome 9q.

**DISCUSSION**

We report here two cases of de novo chromosome 9q34.3 deletions. Four similar cases of 9q34 deletions have been



**Figure 2** BMI curves of patients 1 (A) and 2 (B).

**Table 1** Genotypes of the patients and their parents at polymorphic loci on chromosome 9q34

Locus	Position	Case 1				Case 2			
		Father	Child	Mother	Interpretation	Father	Child	Mother	Interpretation
D9S1826	130.5 Mb	205/209	205/209	205/207	Normal	201/209	201/205	205	Normal
D9S158	131.25 Mb	339	339	339	NI	217	217	217	NI
D9S1838	132.35 Mb	162/168	168	158/164	Del	158	178	158/178	Del
D9S2168	132.9 Mb		FISH		Del		FISH		Del

Loci are listed according to their relative chromosomal location from pter to qter. Allele sizes are given in base pairs. N=normal, Del=deleted, NI=not informative.

previously reported. Two have been identified in the course of a systematic screening for telomeric rearrangements in subjects with idiopathic mental retardation.<sup>4,5</sup> However, the clinical features of these patients were not reported in detail. For the two other cases, the phenotype includes psychomotor delay, dysmorphic features, and death from respiratory failure at 4/5 months of age.<sup>6,7</sup> Moreover, in the case reported by Schimmenti *et al*,<sup>6</sup> heart defects and abnormal genitalia were also observed. In these two patients, the deletion was detected by G banding analysis. By contrast, in the two cases reported here, high resolution chromosome analyses were normal and only specific genotyping and FISH studies allowed us to detect the deletion. This discrepancy is suggestive of a smaller deletion in our cases and illustrates the importance of refining their clinical profile. The two patients reported here presented with major developmental delay, early onset obesity, distinctive facial features (brachycephaly, synophrys, anteverted nostrils, prognathism), sleep disturbances, genital anomalies, and behavioural problems, but no heart defects.

Since both children shared a similar clinical pattern of obesity, sleep disturbances, and mental retardation, it is tempting to speculate that haploinsufficiency for specific genes may explain this phenotype. The deleted region encompasses 20 known genes, including 1-acylglycerol-3-phosphate O-acyltransferase 2 (*AGPAT2*). Mutations in this gene are responsible for congenital generalised lipodystrophy.<sup>8</sup> Reduced *AGPAT2* activity is believed to increase tissue levels of lysophosphatidic acid and alter adipocyte functions, as the gene product catalyses the acylation of lysophosphatidic

acid.<sup>8</sup> Similarly, it is tempting to ascribe the sleep disturbances to haploinsufficiency for the prostaglandin D2 synthase gene, as prostaglandin D2 is a potent sleep inducing substance.<sup>9</sup> By contrast, ascribing mental retardation to a specific gene in this syndrome is difficult, owing to the number of genes involved in brain development and mapping to this region: the Notch homologue 1 gene,<sup>10</sup> the calcium channel voltage dependent alpha 1B subunit gene,<sup>11</sup> the neural proliferation, differentiation and control 1 gene,<sup>12</sup> and the ATP binding cassette member 2 gene.<sup>13</sup>

In the last few years, several forms of syndromic obesity have been described and the natural history of obesity has a consistently important distinctive value (table 2). In our two cases, obesity was not present at birth and excessive weight gain occurred in the course of the second year. Neonatal hypotonia and secondary food seeking behaviour in patient 2 were suggestive of Prader-Willi syndrome, but the dysmorphic features were different (brachycephaly, synophrys, anteverted nostrils, thin upper lip, prognathism) and no neonatal feeding difficulties were noted. Methyl PCR analyses of chromosome 15q15 ruled out this diagnosis in the two patients. Other syndromic forms of obesity include distinctive features that were not present in our patients, namely distal anomalies (Albright osteodystrophy and del 2q37, Bardet-Biedl and Carpenter syndromes), retinal degeneration (Bardet-Biedl and Cohen syndromes), dysmorphic features (Borjeson, Simpson-Golabi, Wilson-Turner syndromes, del 16q12.2), or specific behavioural problems (Smith-Magenis syndrome). Finally, obesity is a frequent feature in several other chromosome anomalies including fragile X, trisomy 21, and Turner syndrome. However, in

**Table 2** Syndromes of mental retardation and obesity

Syndromes	Obesity	Dysmorphic features	Associated features	Inheritance	Locus or gene
Albright	Generalised	Round face, short MC (4th and 5th)	Short stature, epilepsy, pseudohypoparathyroidism	AD	GsAlpha, del 2q37
Bardet-Biedl	Generalised	PD	Retinal dystrophy, renal dysplasia, hypogenitalism, secondary diabetes	AR	11q13, 16q21, 3q13, 15q22, 16q21
Borjeson-Forsman-Lehmann	Generalised	Coarse face, microcephaly	Ptosis, gynaecomastia, seizures, hypogonadism	X linked	Xq26
Carpenter	Generalised	Acrocephaly, PD/SD/BD	Corpus callosum agenesis	AR	?
Cohen	Secondary (<10 y), truncal	Short philtrum, prominent incisors, long, tapering fingers	Chorioretinopathy, neutropenia	AR	Locus 8q22
Del 6q16.2	Secondary (>2 y)	Square face, small palpebral fissures, thin nose, thin lips	Feeding difficulties, hypotonia, hypogonadism		del 6q16.2, ( <i>SIM1</i> gene?)
MOMO	Macrosomia	Macrocephaly,	Coloboma,	Uncertain	?
Prader-Willi	Secondary (>2 y), generalised	Short extremities	Neonatal hypotonia, feeding difficulties, short stature, secondary food seeking behaviour	AD	15q11
Simpson-Golabi	Macrosomia	Coarse face, broad extremities	Visceromegaly	X linked	Glypican
Smith-Magenis	Generalised	Brachycephaly, midface hypoplasia, wide mouth with downturned corners	Behavioral anomalies, sleep disturbances		del 17p11.2
Wilson-Turner	Generalised	Coarse facies, thick brows, gynaecomastia	Ataxia, diabete mellitus	X linked	Locus Xp11-cen

MC=metacarpal, PD=polydactyly, BD=brachydactyly, SD=syndactyly.

the last cases, obesity is not a major symptom and associated symptoms help in diagnosing these conditions.

In conclusion, while obesity and mental retardation are part of several known conditions, their association with distinctive facial features (that is, brachycephaly, synophrys, anteverted nostrils, prognathism), sleep disturbances, and genital anomalies in the del 9q34 syndrome constitutes, in our opinion, a novel and recognisable phenotype. Refining the clinical features of the "9qter syndrome" will hopefully help in recognising this chromosomal anomaly in children with mental retardation and obesity.

#### ACKNOWLEDGEMENTS

We are grateful to the patients and their family for their cooperation. This study was supported by the Fondation de France.

.....

#### Authors' affiliations

**V Cormier-Daire, F Molinari, M Rio, O Raoul, M-C de Blois, S Romana, M Vekemans, A Munnich, L Colleaux**, INSERM U393 and Département de Génétique Médicale, Hôpital Necker-Enfants Malades, Tour Lavoisier, 149 rue de Sevres, 75015 Paris, France  
Correspondence to: Dr L Colleaux, INSERM U393, Hôpital Necker-Enfants Malades, Tour Lavoisier, 149 rue de Sevres, 75015 Paris, France; colleaux@necker.fr

#### REFERENCES

- Colleaux L, Rio M, Heuertz S, Moindrault S, Turleau C, Ozilou C, Gosset P, Raoult O, Lyonnet S, Cormier-Daire V, Amiel J, Le Merrer M, Picq M, de Blois MC, Prieur M, Romana S, Cornelis F, Vekemans M, Munnich A. A novel automated strategy for screening cryptic telomeric rearrangements in children with idiopathic mental retardation. *Eur J Hum Genet* 2001;**9**:319-27.
- Rio M, Molinari F, Heuertz S, Ozilou C, Gosset P, Raoult O, Cormier-Daire V, Amiel J, Lyonnet S, Le Merrer M, Turleau C, de Blois MC, Prieur M, Romana S, Vekemans M, Munnich A, Colleaux L. Automated fluorescent genotyping detects 10% of cryptic subtelomeric rearrangements in idiopathic syndromic mental retardation. *J Med Genet* 2002;**39**:266-70.
- Knight SJL, Flint J. Perfect endings: a review of subtelomeric probes and their use in clinical diagnosis. *J Med Genet* 2000;**37**:401-9.
- Rossi E, Piccini F, Zollino M, Neri G, Caselli D, Tenconi R, Castellani C, Carozzo R, Danesino C, Zuffardi O, Ragusa A, Castiglia L, Galesi O, Greco D, Romano C, Pierluigi M, Perfume C, Di Rocco M, Faravelli F, Dagna Bricarelli F, Bonaglia M, Bedeschi M, Borgatti R. Cryptic telomeric rearrangements in subjects with mental retardation associated with dysmorphism and congenital malformations. *J Med Genet* 2001;**38**:417-20.
- Anderlid BM, Schoumans J, Anneren G, Sahlen S, Kyllerman M, Vujic M, Hagberg B. Subtelomeric rearrangements detected in patients with idiopathic mental retardation. *Am J Med Genet* 2002;**107**:275-84.
- Schimmenti LA, Berry SA, Tuchman M, Hirsch B. Infant with multiple congenital anomalies and deletion 9(q34.3). *Am J Med Genet* 1994;**51**:140-2.
- Ayyash H, Mueller R, Maltby E, Horsfield P, Telford N, Tyler R. A report of a child with a deletion 9(q34.3): a recognisable phenotype? *J Med Genet* 1997;**34**:610-12.
- Agarwal AK, Arioglu E, de Almeida S, Akkoc N, Taylor SI, Bowcock AM, Barnes RI, Garg A. AGPAT2 is mutated in congenital generalized lipodystrophy linked to chromosome 9q34. *Nat Genet* 2002;**31**:21-3.
- Pinzar E, Kanaoka Y, Inui T, Eguchi N, Urade Y, Hayaishi O. Prostaglandin D synthase gene is involved in the regulation of non-rapid eye movement sleep. *Proc Natl Acad Sci USA* 2000;**97**:4903-7.
- del Amo FF, Gendron-Maguire M, Swiatek PJ, Jenkins NA, Copeland NG, Gridley T. Cloning, analysis, and chromosomal localization of Notch-1, a mouse homolog of *Drosophila* Notch. *Genomics* 1993;**15**:259-64.
- Diriong S, Lory P, Williams ME, Ellis SB, Harpold MM, Taviaux S. Chromosomal localization of the human genes for alpha 1A, alpha 1B, and alpha 1E voltage-dependent Ca<sup>2+</sup> channel subunits. *Genomics* 1995;**30**:605-9.
- Qu X, Zhang C, Zhai Y, Xing G, Wei H, Yu Y, Wu S, He F. Characterization and tissue expression of a novel human gene npdc1. *Gene* 2001;**264**:37-44.
- Kaminski WE, Piehler A, Pullmann K, Porsch-Ozcurumez M, Duong C, Bared GM, Buchler C, Schmitz G. Complete coding sequence, promoter region, and genomic structure of the human ABCA2 gene and evidence for sterol-dependent regulation in macrophages. *Biochem Biophys Res Commun* 2001;**281**:249-58.



## What's in the next issue

**Future content**

See which articles have just been accepted for publication and preview the table of contents for the next issue a month before it is published

[www.jmedgenet.com](http://www.jmedgenet.com)