

ONLINE MUTATION REPORT

Phenotypic and genetic exploration of severe demyelinating and secondary axonal neuropathies resulting from *GDAP1* nonsense and splicing mutations

A De Sandre-Giovannoli, M Chaouch, I Boccaccio, R Bernard, V Delague, D Grid, J M Vallat, N Lévy, A Mégarbané

J Med Genet 2003;40:e87(<http://www.jmedgenet.com/cgi/content/full/40/7/e87>)

We identified two novel *GDAP1* homozygous mutations in children affected with severe demyelinating peripheral neuropathies and born to consanguineous parents. A 9 year old Lebanese girl carried a nonsense mutation in exon 5 and two Algerian brothers aged 10 and 8 years carried a mutation at the intron 3 acceptor splicing site. The clinical, electrophysiological, and neuropathological explorations showed common features consistent with a severe demyelinating peripheral neuropathy associated with loss of major fibres. Our findings, supported by the first *GDAP1* expression study in patients, show further evidence that mutations in this gene cause an autosomal recessive severe demyelinating peripheral phenotype (CMT4A) associated with axon loss.

Charcot-Marie-Tooth disease (CMT) (also called hereditary motor and sensory neuropathy (HMSN)) is clinically, electrophysiologically, and genetically extremely heterogeneous with more than 40 loci and 16 genes identified to date.¹ The most common inherited peripheral neuropathies are CMT type 1 and CMT type 2, which are characterised by progressive weakness and atrophy, initially of the peroneal muscles and later of the distal muscles of the arms. Myelination is mainly affected in CMT1, with neuropathological findings of demyelination and remyelination with onion bulb formation, clusters of regeneration, and Schwann cell proliferation. CMT2 is an

Table 1 Summary of reported mutations of the *GDAP1* gene

Exon/intron	Mutation	Effect	References
Exon 1	c.92G>A	W31X	4
Exon 3	c.349_350insT	T117fs	7
Exon 3	c.359G>A	R120Q	8
Exon 3	c.482G>A	R161H	4
Intron 3	IVS3-2A>G	r.485_579del	This study
Exon 4	c.487C>T	Q163X	5, 8
Intron 4	IVS4+1G>A	?	7
Exon 5	c.581C>G	S194X	4, 5, 6
Exon 5	c.668T>A	L223X	This study
Exon 6	c.844C>T	R282C	6, 7
Exon 6	c.863insA	T288fsX290	5
Exon 6	c.786delG	G262fs	6

axonal neuropathy characterised by the reduction of fibre density in the absence of clusters of myelin regeneration or proliferation of Schwann cells. Very often, neuropathological analysis of patients carrying demyelinating neuropathies shows concomitant axon fibre loss.² A motor nerve conduction velocity (MNCV) threshold value of 38 ms⁻¹ at the median nerve is used to classify patients with CMT as being either CMT1 (MNCV < 38 ms⁻¹) or CMT2 (MNCV > 38 ms⁻¹). CMT4A defines a particularly severe polyneuropathy of the demyelinating type, associated with distal weakness and atrophy of the limbs, with early onset. The muscular atrophy rapidly progresses, extending proximally and leading to inability to walk by the end of the first decade. Skeletal deformities and scoliosis are frequent.³ Mutations in the ganglioside induced differentiation associated protein 1 gene (*GDAP1*) at chromosome 8q21.3 were originally reported in families carrying typical CMT4A⁴ and in families affected with autosomal recessive axonal CMT associated with vocal cord paresis.⁵ Other *GDAP1* mutations in patients affected with demyelinating and axonal peripheral neuropathies have recently been reported.⁶⁻⁸ The 12 published *GDAP1* mutations are listed in table 1.

Here we report on two families, of Lebanese and Algerian origin, in which two new mutations in *GDAP1* have been found. All affected persons had clinical, electrophysiological,

Key points

- We studied two consanguineous families, one Lebanese and one Algerian, affected with early onset, severe peripheral neuropathies.
- Electrophysiological and histopathological characterisation showed prominent, rapidly progressing demyelinating features associated with loss of major fibres.
- We sequenced *GDAP1* exons and intron-exon boundaries in the two families and found two unreported homozygous mutations segregating with the disease, one in exon 5 (c.668T>A) and the other in the intron 3 acceptor splicing site (IVS3-2A>G).
- On the one hand, the c.668T>A mutation is predicted to create a stop codon interrupting the protein at residue 223; on the other hand, expression analyses showed that the intron 3 homozygous mutation has a deleterious effect on transcription, causing the skipping of exon 4 in all the detectable transcribed units.
- Whatever the physiological functions of *GDAP1*, the truncated proteins do not seem to be able to ensure normal peripheral nervous system development, giving rise to the severe, early onset CMT4 phenotype found in the patients reported here.

Abbreviations: CMT, Charcot-Marie-Tooth disease; EMG, electromyography; *GDAP1*, ganglioside induced differentiation associated protein 1 gene; MNCV, motor nerve conduction velocity; NCV, nerve conduction velocity; OFC, occipitofrontal circumference; RT-PCR, reverse transcriptase PCR; SNCV, sensory nerve conduction velocity

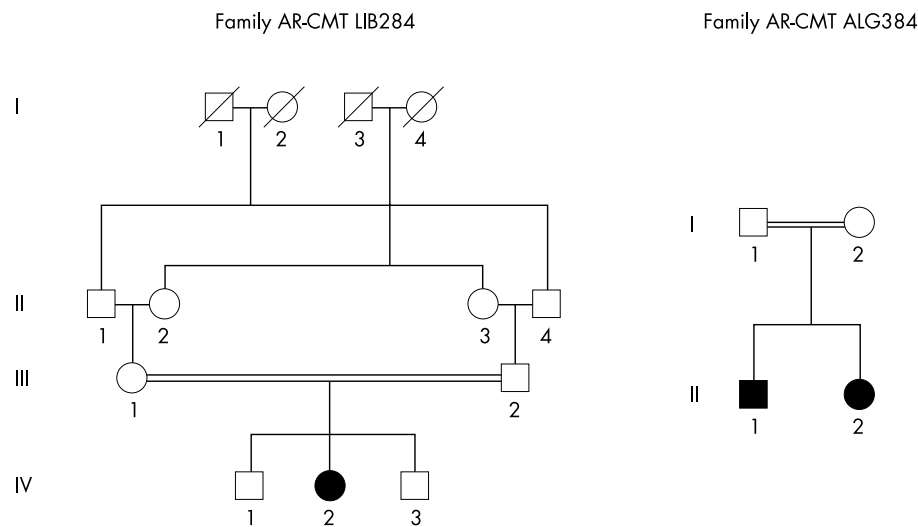


Figure 1 Pedigrees of AR-CMT families LIB284 and ALG384.

and neuropathological features consistent with a severe demyelinating phenotype associated with major fibre loss. The affected Lebanese girl carried a mutation in exon 5 (c.668T>A) leading to the substitution of the leucine 223 residue to a stop codon (p.L223X), and the two affected Algerian brothers carried a mutation of the third intron acceptor splicing site (IVS3-2A>G), which caused the skipping of the fourth exon in all the transcribed units. This report, supported by the first *GDAP1* expression study in patients, shows further evidence that mutations in *GDAP1* cause autosomal recessive, severe, demyelinating peripheral phenotypes (CMT4A) associated with axonal loss.

PATIENTS AND METHODS

AR-CMT families

We studied two consanguineous families (AR-CMT LIB284 and AR-CMT ALG384, fig 1) including children affected with early onset, severe peripheral neuropathy. In both families, consanguinity suggested that the neuropathic phenotype segregated as an autosomal recessive trait.

AR-CMT LIB284

The affected girl (LIB284-IV.2, fig 1) was the second child of healthy, first cousin, Lebanese parents. Pregnancy was uneventful with no history of exposure to prenatal or perinatal environmental toxins, and delivery was at term. Birth weight, length, and occipitofrontal circumference (OFC) measurements were not available but were considered normal by the parents. Psychomotor developmental milestones were in the normal range. Disease onset was around 1 year of age, when walking difficulties became evident with a wide based and ataxic gait associated with steppage/foot dropping. By the age of 5 years, weakness of the upper limbs, particularly affecting the hands, and finger retraction, appeared (fig 2E, F). Since then, the progression of the disease has been slow.

AR-CMT ALG384

ALG384-II.1 and his sister ALG384-II.2 (fig 1) were respectively the first and second (2 years younger) children of healthy, consanguineous, Algerian parents. Pregnancies and birth were both uneventful and at term. Psychomotor developmental milestones were normally acquired until 1 year of age, when both children showed walking difficulties, with impairment in foot lifting and frequent falls. At the age of 2, a progressive atrophy of distal muscles of the arms and hands became evident in both children (fig 2A, C). At the age of 6, the

hands were severely affected, with pronounced weakness and finger retraction (fig 2B, D).

The aim of this study was explained to affected families by the primary doctor or neurologist they were referred to and informed consent was obtained from participating people. The study complies with the ethical guidelines of the institutions involved.

Electrophysiology

Motor and sensory nerve conduction velocities (MNCVs and SNCVs) as well as electromyographic features were examined in the upper and lower limbs. The MNCVs were recorded at medial and peroneal nerves. Median (elbow-wrist), peroneal (head of fibula-ankle) MNCVs, and muscle action potential amplitudes were registered with surface electrodes. Sensory action potentials were recorded antidromically from the median nerve. Needle electromyography (EMG) examination was performed on distal and proximal muscles.

Ultrastructural characterisation

For analysis of nerve biopsies, fascicles of the superficial peroneal nerve were fixed in formaldehyde (10%) and embedded in paraffin. Routine sections were stained using conventional methods. Others fascicles were fixed and buffered in glutaraldehyde, processed, and embedded in epon.

Genotyping and sequence analyses

Involvement of *MPZ* (1q22), *PMP22* (17p11.2), *EGR2* (10q21-q22), and *NDRG1* (8q24) was excluded by direct sequencing. For the other genes reported as being involved in demyelinating AR-CMT (*MTMR2*, *PRX*, and *GDAP1*), a segregation analysis was performed using microsatellite markers respectively on chromosomes 11q22 (AFM119XH4, D11S4134/AFMB021ZG9), 19q13.3 (D19S881/AFMA284YF9, D19S420/AFM326XH9), and 8q21.3 (D8S551/AFM308ZE5, D8S548/AFM301ZC9). Polymerase chain reactions (PCRs) were performed under standard conditions,⁹ using IRD-800 labelled forward primers; analysis of PCR products was obtained with a Li-Cor 4200 automated sequencer. The six *GDAP1* coding exons and splicing sites (Genbank accession number NM_018972.1) from the affected patients were amplified and then sequenced using a BigDye terminator cycle sequencing procedure (Applied Biosystems).⁹ All the sequence variations found were explored in the same conditions from the unaffected members of the families, to confirm the segregation pattern. Sequencing reactions were run on an ABI automated capillary DNA sequencer 310 (Applied Biosystems).

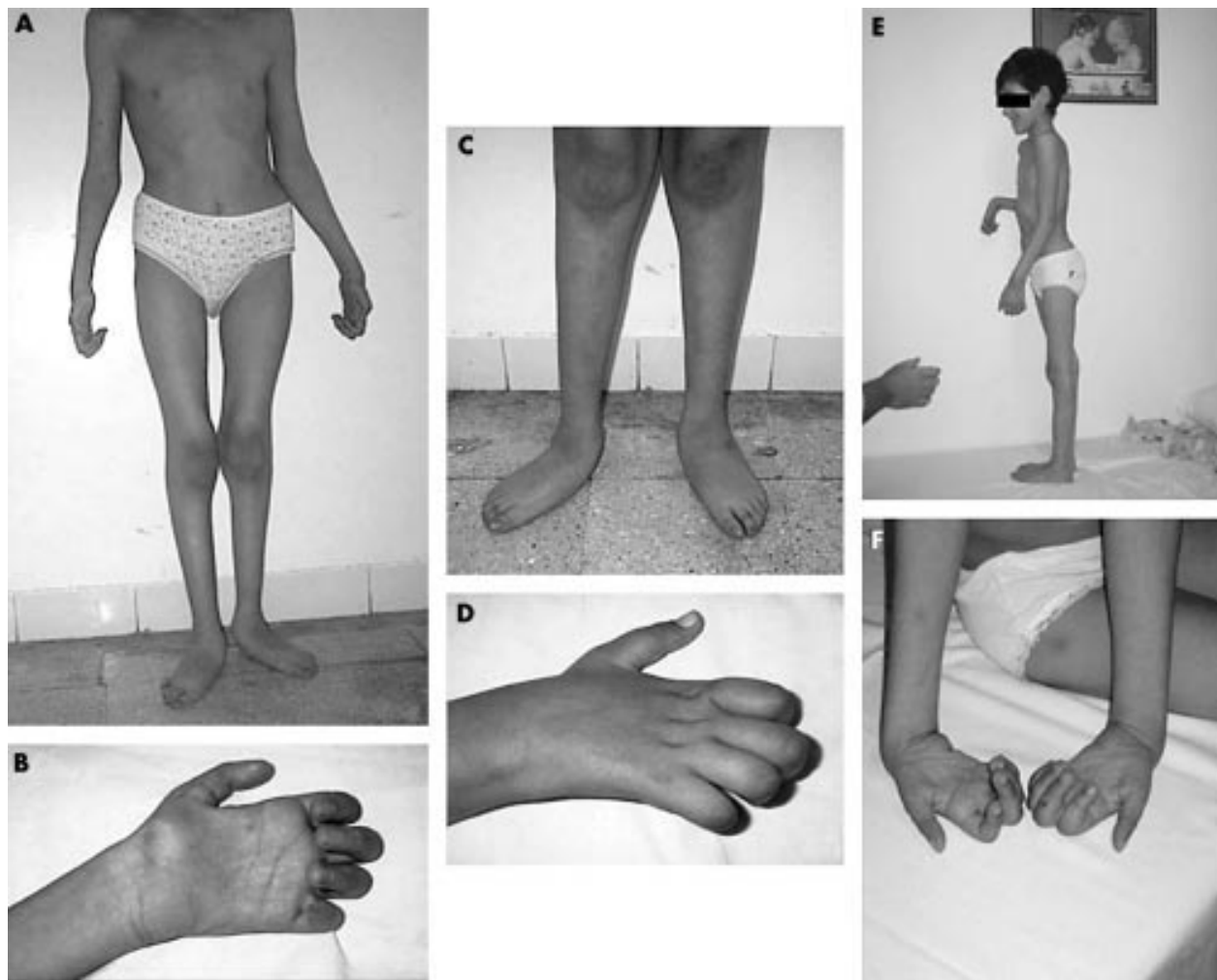

Figure 2 Distal muscular atrophy and finger retraction in patients (A, B) CMT-ALG384.II.2, (C, D) CMT-ALG384.II.1, and (E, F) CMT-LIB.IV.2.

Data were collected and analysed using Sequencher (GeneCodes). All sequence mutations are described according to den Dunnen and Antonarakis.¹⁰

Effect on splicing of the IVS3–2A>G mutation Predicted effect

Wild type and mutated IVS3–2A>G genomic sequences were analysed at the web site http://www.charite.de/ch/medgen/img_files/Forschung/Splice/splice.html using the splice score algorithm of Shapiro and Senapathy.¹¹

Reverse transcription (RT)-PCR

Total RNA was extracted from EBV immortalised lymphoblastoid cell lines of patients ALG384-II.1 and ALG384-II.2 and an age matched control, with TRIZOL (Invitrogen-Life Technologies). Reverse transcription was performed with Superscript II reverse transcriptase (Invitrogen-Life Technologies) following company recommendations. To obtain enough DNA for sequencing, nested PCRs were performed on cDNAs with primers lying in *GDAP1* exons 3 and 5 (see fig 5A, C, D, E). The expected amplicon sizes were 203 bp for controls and 108 bp for a transcript missing exon 4 (r.485_579del); with those primers (fig 5 E), eventual genomic contaminants would have been amplified at a 2736 bp size. A PCR with primers lying in glyceraldehyde-3-phosphate dehydrogenase (*GADPH*) exons 7 and 8 (amplicon size 298 bp) was used as a control of cDNA quality, as previously described (see fig 5B).⁹ The products of reverse transcriptase PCR (RT-PCR) were subsequently sequenced (see genotyping and sequence analysis).

RESULTS

Clinical follow up AR-CMT LIB284

During the follow up, our first clinical examination of the girl, when she was 9 years old, showed normal psychological development, and she was registered in a public school. On examination, head circumference and stature were normal. There were no dysmorphic features except a pectum excavatum. Neurological examination showed important sensory ataxia, bilateral steppage gait, mild kyphoscoliosis, symmetrical and marked atrophy of intrinsic hand muscles and lower leg muscles, and retraction of the fingers (fig 2E, F). Muscle strength was very diminished distally in the upper and lower limbs. Tendon reflexes were absent in the four limbs, and distal sensory abnormalities including deficits of position, vibration, pain, and temperature were registered in both upper and lower limbs in a glove/stocking distribution. No seizures or facial weakness were noted. Abdominal ultrasound, echocardiography, electroencephalography, and ophthalmological evaluation were all unremarkable. Results of routine laboratory tests were within the normal range.

AR-CMT ALG384

Affected patients ALG384-II.1 and ALG384-II.2 were examined at the ages of 9 and 7 years respectively. They both showed a distal pronounced amyotrophy of the upper and lower limbs with finger retraction and claw hands (fig 2C, D, and A, B respectively). Motor deficit was predominantly distal with foot drop and severe steppage. Hypotonia and areflexia

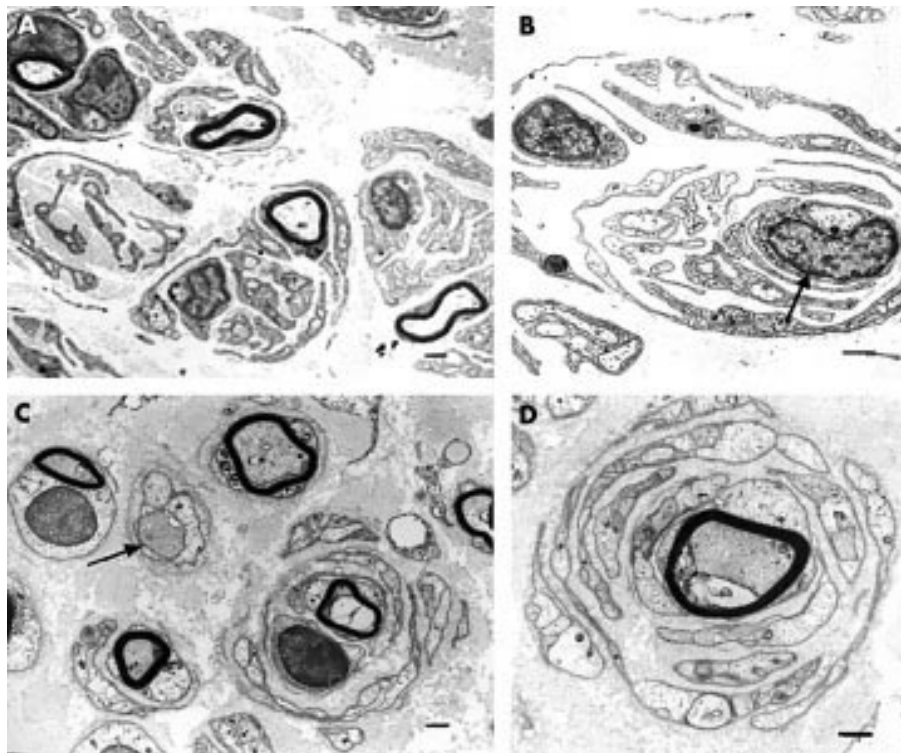


Figure 3 Ultrastructural micrographs of transverse sections of the peroneal nerve of patients (A, B) CMT-LIB284.IV.2 and (C, D) CMT-ALG384.II.1. Bars=1 μ m. A rarefaction of myelinated and unmyelinated fibres and an increase of connective tissue is evident. The thickness of the myelin sheaths is reduced and naked axons (arrows) are present. Significant concentric proliferation of Schwann cell cytoplasmic and basal lamina fragments around an unmyelinated axon (B) and a thinly myelinated axon (D) is visible.

were seen in the four limbs. Lumbar kyphoscoliosis was discrete. No sensitive or vasomotor disturbances were found. Subsequent neurological examination at the ages of 12 and 10 respectively showed extension of atrophy and motor deficit in proximal muscles of the lower limbs, causing difficulties in standing up. Vasomotor disturbances had appeared, with increased sweating and cold extremities. Distal sensory abnormalities were mild. No cranial nerve involvement was apparent, and abdominal ultrasound, echocardiography, electroencephalography, and ophthalmological evaluation were all unremarkable. Results of routine laboratory tests were within the normal range.

Electrophysiology

LIB284-IV.2

Electromyography performed at the age of 18 months showed the absence of evoked sensory action potentials at median nerves. Evoked motor action potentials were also absent in the tibial and peroneal nerves, and in the cubital and median nerves they had low amplitudes (0.4 and 1.4 mV respectively) with normal conduction velocities (45 and 40 ms^{-1} respectively). No potentials were obtained through voluntary contraction at tibial nerves whereas a low amplitude tracing with an accelerated pattern was obtained at the lateral right gastrocnemius. Nerve conduction studies and EMG performed on the unaffected parents and brothers were normal.

ALG384-II.1

Electromyography performed at the age of 5 was compatible with axonal loss associated with demyelination. Potential amplitudes (0.48 mV), and MNCVs at the median nerve were very low (20 ms^{-1}). Also, SNCVs at the sural nerve were 34.8 ms^{-1} with amplitude 5.4 mV. Sensory potential amplitudes were 1.7 and 1.9 mV respectively in the median and ulnar nerves. A second EMG, performed at the age of 10, indicated worsening of the neuropathy with progressive axonal loss.

ALG384-II.2

Electromyography performed at the age of 3 showed MNCVs of 39 ms^{-1} at the left ulnar nerve, with a 6 mV potential amplitude, indicating a demyelinating process. A second EMG at the age of 8 showed an associated axonal involvement at the sural nerve, with a 31 ms^{-1} SNCV and a 2.7 mV potential amplitude. Sensory potentials were undetectable in the ulnar nerve.

Thus, the EMG results indicated an association of demyelinating neuropathological processes with axonal loss. Nerve conduction studies and EMG performed on the unaffected parents were unremarkable.

Nerve biopsy results

Ultrastructural analysis of all patients' nerve biopsies showed prominent, likely chronic, demyelinating features, with a severe reduction of myelinated fibres (fig 3A, C). The large diameter fibres were primarily lacking. The myelin sheaths of most of the few remaining myelinated fibres were abnormally thin although compaction was not modified; some Schwann cells contained one naked axon typical of complete demyelination (fig 3B). Many large onion bulbs were seen around unmyelinated and myelinated fibres (fig 3B, D). They were made of numerous, concentrically arranged, flattened processes of Schwann cell cytoplasm. Unmyelinated fibres were also significantly decreased. These anomalies were characteristic of a typical chronic "demyelinating-remyelinating" process associated with a large reduction of axonal density.

Molecular genetic analysis

Involvement of *MPZ* (1q22),¹² *PMP22* (17p11.2),¹³ *EGR2* (10q21-q22),¹⁴ and *NDRG1* (8q24)¹⁵ was excluded by direct sequencing. Because the affected patients were born to consanguineous parents, we assumed identity by descent and used a homozygosity mapping approach¹⁶ for the other genes reported as being involved in demyelinating AR-CMT: *MTMR2* (11q22),¹⁷ *PRX* (19q13.3),¹⁸ and *GDAP1* (8q21.3).^{4,8} The

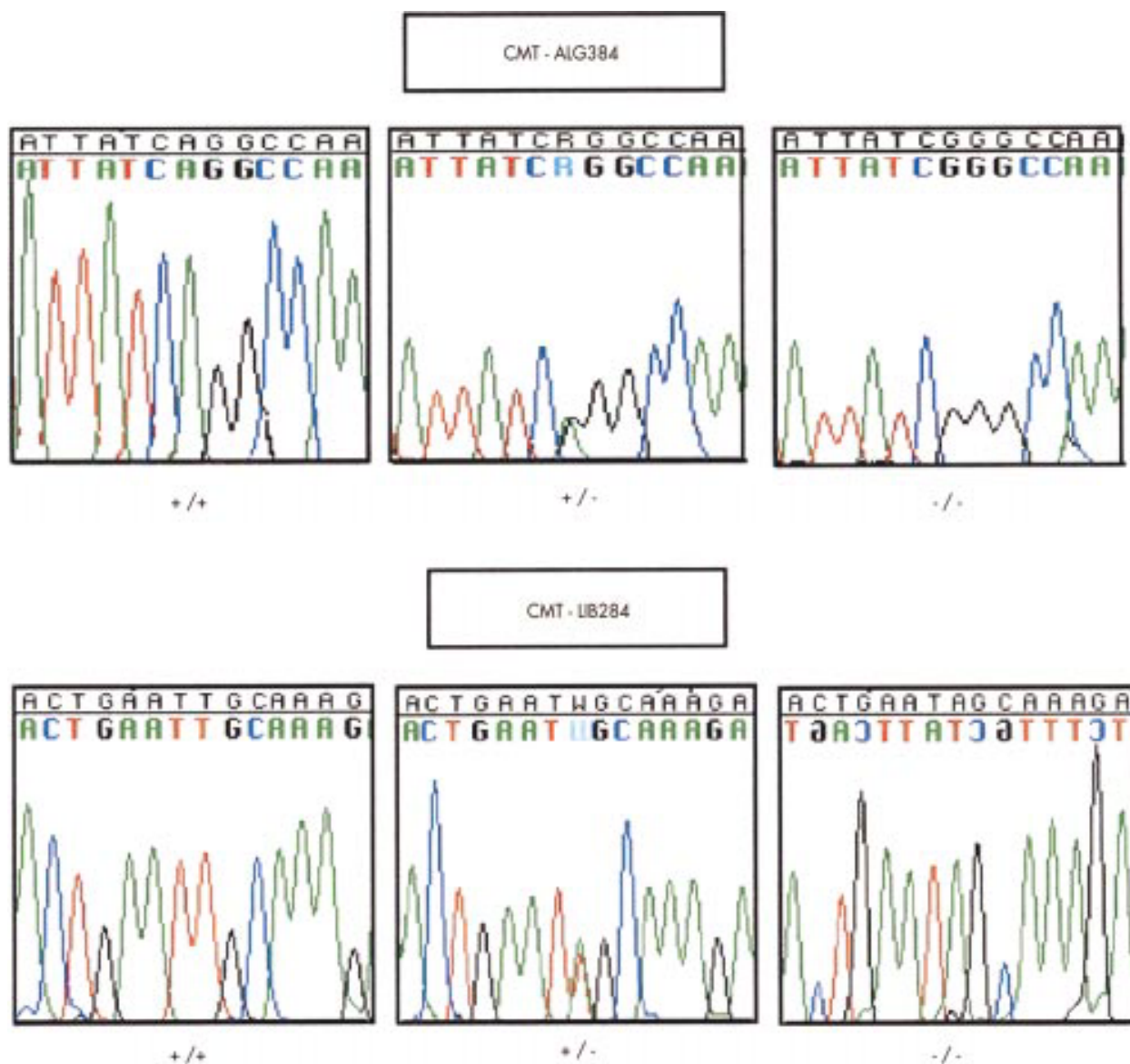


Figure 4 Genomic normal (+/+), heterozygous (+/-), and homozygous (-/-) mutated sequences in families CMT-ALG384 and CMT-LIB284.

segregation analysis excluded linkage to chromosomes 11q22 and 19q13.3 whereas the segregation of haplotypes at chromosome 8q21.3 was compatible with linkage of the disorder to this region in both family CMT-LIB284 and family CMT-ALG384. Genotyping analysis showed positive although not significant linkage to chromosome 8q21.3, from D8S551 to D8S548 ($Z_{\max} = 0.25$ at $\theta = 0$ for both markers) in family CMT-LIB284 (data not shown). Only the affected people were homozygous for these markers, with alleles that were not shared by the two families; we thus continued screening for mutations in the coding region and splicing sites of the *GDAP1* gene. Sequencing showed a single nonsense mutation lying in *GDAP1* exon 5 carried by patient LIB284-IV.2 (c.668T>A, fig 4) and a mutation in the acceptor splicing site of intron 3 (IVS3-2A>G) carried by the sibs ALG384-II.1 and ALG384-II.2 (fig 4). The c.668T>A change is predicted to lead to the transition from leucine to a premature stop codon at position 223 of the protein product (p.L223X). The splice score consensus values of the IVS3-2A>G genomic sequence versus the wild type were, respectively, 78.66 and 94.69, with a 0.83 mutant/wild type score ratio, indicating a reduced splicing efficiency for the IVS3-2A>G mutated site. Transcripts of patient ALG384-II.1

were subsequently analysed at the mutated splicing site. RT-PCR amplification showed a 108 bp fragment in patient ALG384-II.1 instead of the 203 bp expected, which was present in the normal control and in patient LIB284-IV.2 (fig 5A). Sequencing of the RT-PCR products showed that patient ALG384-II.1 expressed a unique, aberrant transcript missing exon 4 (r.485_579del) (fig 5D).

In both families the segregation of the mutated alleles was consistent with the autosomal recessive inheritance of the disorder.

DISCUSSION

gdap1 was first identified as one of 10 cDNAs (*gdap1-10*) highly expressed in a differentiated Neuro2a mouse neuroblastoma cell line, in which cholinergic differentiation with neurite sprouting had been induced by transfection of GD3 synthase (α ,8 sialyltransferase) cDNA.¹⁹ Transfection of GD3 synthase cDNA in Neuro2a cells has been shown to induce the expression of GD3 as well as GQ1b and GD1b, which are b series complex gangliosides (glycosphingolipids containing sialic acid).²⁰ Ganglioside specific sialyltransferases as well as gangliosides are highly enriched and specifically localised in

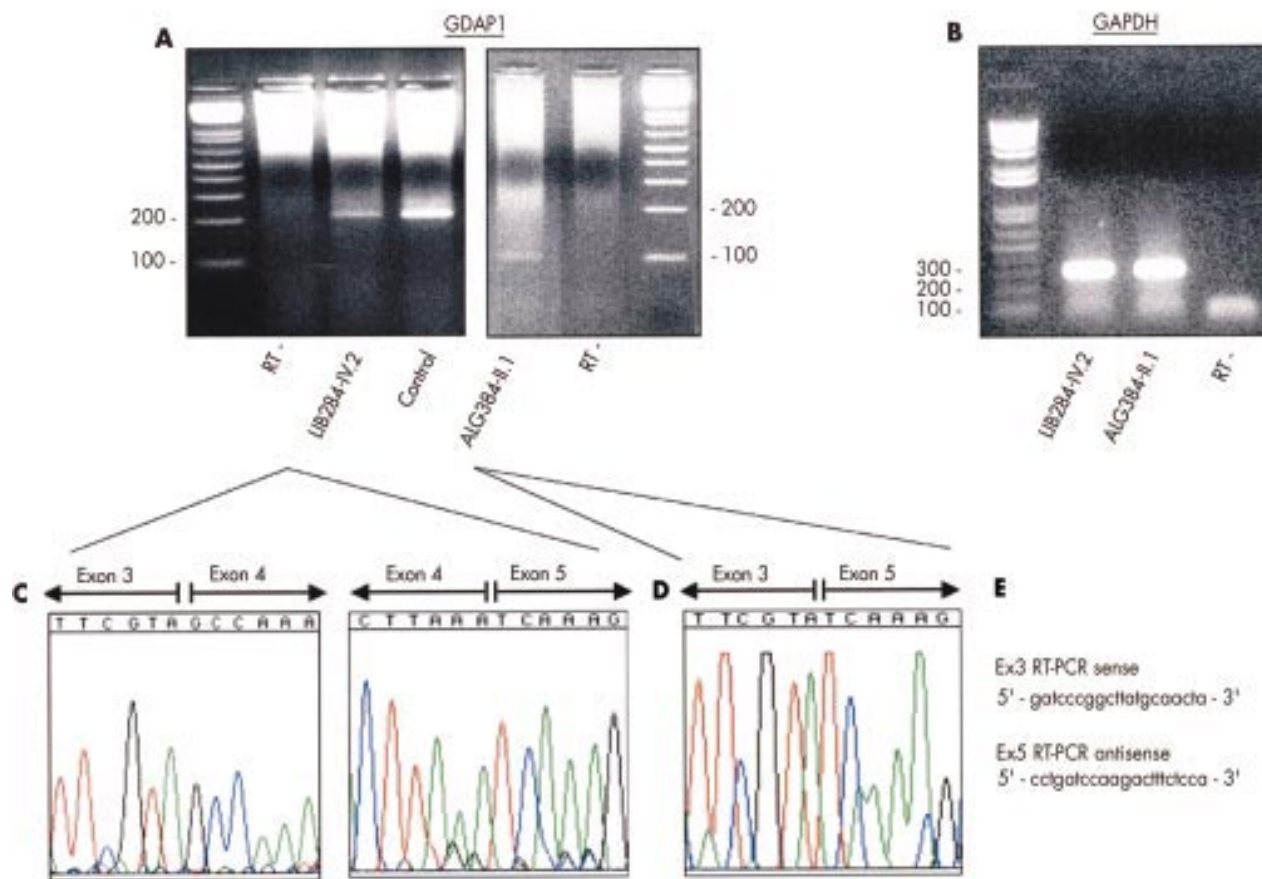


Figure 5 Exon 4 skipping in *GDAP1* transcripts from patient ALG384-II.1. Agarose gel electrophoresis of RT-PCR fragments performed between (A, B) *GDAP1* exons 3 and 5 and *GAPDH* exons 7 and 8 as a control. (C) Sequence of exons 3–4 and 4–5 junction fragments in control LIB284-IV.2 and (D) of exons 3–5 aberrant junction fragment in patient ALG384-II.1. (E) Sequence of the sense and antisense primers used to amplify cDNAs between exons 3 and 5.

the vertebrate nervous system,^{21–23} where they have been involved in signal transduction pathways leading to neural differentiation.^{20 24–27}

gdap1 expression increases greatly during Neuro2a neural differentiation induced by GD3 synthase; in parallel, its expression pattern seems to be developmentally regulated in mice,¹⁹ being maximal and specific in adult mouse brain. *GDAP1*, the human orthologue, is also mostly expressed in central and peripheral nervous tissues.⁵ It is expressed in neurones or in Schwann cells, as it has been isolated from human sural nerve, mouse sciatic nerve,⁵ and cauda equina,⁴ and is likely to play a fundamental part during development and myelination of the peripheral nervous system.

GDAP1 encodes a 358 aa protein, containing two predicted transmembrane helices (aa 292–311 and 319–343). In parallel, phylogenetic and secondary structure analysis has shown that *GDAP1* belongs to a new and probably monophyletic group of glutathione S-transferases. Amino acid residues 26–119 (N-terminal subdomain) show homology with the thioredoxin-like fold domain binding glutathione and amino acid residues 210–287 (C-terminal subdomain) show homologies with the domain recognising xenobiotic substrates.⁵

Structure and expression patterns of *GDAP1* locate this protein at the “crossroads” between gangliosides and glutathione S-transferases in terms of diverse and possibly linked functions.

Because of its primary structure, *GDAP1* is likely to be localised at the cellular membrane, where it might participate in the complex and permanent interactions existing between Schwann cells and neurones.^{28 29} It should be investigated, for instance, whether *GDAP1* is included in the membrane

glycosphingolipid enriched signalling domain of Neuro2a cells. This domain contains the signal transducer molecules c-Src, Lyn, Rho A, and Ha-Ras and is likely to participate in signalling pathways leading to differentiation and neurogenesis through the enhancement of MAPK activity.²⁷

In parallel, proteins belonging to the GST multigenic family are continuing to be discovered as having many diverse functions besides the detoxification of electrophilic compounds through glutathione conjugation and maintenance of the cellular redox state, for example, transactivation of transcription factors,³⁰ composition and regulation of ionic channels,³¹ and activity as recognition molecules.³²

GDAP1 might thus have diverse possible functions in the development of the peripheral nervous system, which remain to be elucidated.

Whether *GDAP1* is physiologically involved in signal transduction, cell-cell recognition, neurotransmitter release modulation, or cellular detoxification, the mutated proteins (that of LIB284-IV.2 is predicted to be truncated at aa 223, which is localised in the GST-xenobiotic recognising domain, and those of ALG384-II.1 and ALG384-II.2 are predicted to be missing amino acids 162–193, which are *GDAP1* specific) are likely not able to ensure the proper communication between Schwann cells and axons, giving rise to the severe, early onset CMT4 phenotype found in the patients reported on here.

To date, only *GDAP1* mutations causing recessive CMT have been reported; the mutations thus do not seem to act in a dominant negative fashion and half gene dosage seems sufficient to preserve a normal peripheral nerve function. It is worth noting that all patients carrying a mutation in *GDAP1* do not show central nervous system involvement,^{4–8} making it

likely that a certain redundancy of function exists between GDAP1 and other proteins in this tissue. Several findings suggest indeed that different signalling pathways are likely to be involved in myelination processes in the peripheral versus the central nervous system.^{28 33}

Peripheral nerve ultrastructure, together with EMG results in the patients described here, suggest that *GDAP1* mutations affect myelin sheaths as well as axons. Other reports have shown that demyelination and axonal loss often coexist in Charcot-Marie-Tooth disease, axonal degeneration probably being secondary to the disruption of Schwann cell-axon interactions^{2 33-35} and probably being the main cause of clinical disability.^{36 37}

Animal models, along with more detailed functional studies in humans, will help to understand further the role of *GDAP1* and its molecular partners in the complex molecular interactions underlying the physiological development as well as the pathophysiology of the peripheral nervous system.

ACKNOWLEDGEMENTS

ADSG was supported by a grant of the Association Française contre les Myopathies (AFM), Evry, France, 2001. We are grateful to Josette Pizant for excellent technical assistance. We thank all the family members, without whom this study would not have been possible.

.....

Authors' affiliations

A De Sandre-Giovannoli, I Boccaccio, N Lévy, Inserm U491, Génétique Médicale et Développement, Faculté de Médecine la Timone, 13385 Marseille, France
M Chaouch, Service de Neurologie, Centre Hospitalier Universitaire Ben Aknoun, Algiers, Algeria
V Delague, A Mégarbané, Unité de Génétique Médicale, Université Saint-Joseph, Faculté de Médecine, BP 11-5076, Beyrouth, Lebanon
R Bernard, N Lévy, Département de Génétique Médicale, Hôpital d'Enfants de la Timone, 13385 Marseille, France
D Grid, Généthron III, Evry, France
J M Vallat, Service et Laboratoire de Neurologie, Centre Hospitalier Universitaire Dupuytren, Limoges, France

Correspondence to: Dr N Lévy, Inserm U491, Génétique Médicale et Développement, Faculté de Médecine la Timone, 13385 Marseille Cedex 05, France; nicolas.levy@medecine.univ-mrs.fr

REFERENCES

- 1 **IPNMD**. Inherited peripheral neuropathies mutation database at <http://molgen-www.uia.ac.be/CMTMutations/>.
- 2 **Hanemann CO**, Gabreels-Festen AA. Secondary axon atrophy and neurological dysfunction in demyelinating neuropathies. *Curr Opin Neurol* 2002;**15**:611-15.
- 3 **Ben Othmane K**, Hentati F, Lennon F, Ben Hamida C, Blel S, Roses AD, Pericak-Vance MA, Ben Hamida M, Vance JM. Linkage of a locus (CMT4A) for autosomal recessive Charcot-Marie-Tooth disease to chromosome 8q. *Hum Mol Genet* 1993;**2**:1625-8.
- 4 **Baxter RV**, Ben Othmane K, Rochelle JM, Stajich JE, Hulette C, Dew-Knight S, Hentati F, Ben Hamida M, Bel S, Stenger JE, Gilbert JR, Pericak-Vance MA, Vance JM. Ganglioside-induced differentiation-associated protein-1 is mutant in Charcot-Marie-Tooth disease type 4A/8q21. *Nat Genet* 2002;**30**:21-2.
- 5 **Cuesta A**, Pedrola L, Sevilla T, Garcia-Planells J, Chumillas MJ, Mayordomo F, LeGuern E, Marin I, Vilchez JJ, Palau F. The gene encoding ganglioside-induced differentiation-associated protein 1 is mutated in axonal Charcot-Marie-Tooth type 4A disease. *Nat Genet* 2002;**30**:22-5.
- 6 **Nelis E**, Erdem S, Van Den Bergh PY, Belpaire-Dethiou MC, Ceuterick C, Van Gerwen V, Cuesta A, Pedrola L, Palau F, Gabreels-Festen AA, Verellen C, Tan E, Demirci M, Van Broeckhoven C, De Jonghe P, Topaloglu H, Timmerman V. Mutations in *GDAP1*: autosomal recessive CMT with demyelination and axonopathy. *Neurology* 2002;**59**:1865-72.
- 7 **Senderek J**, Bergmann C, Ramaekers VT, Nelis E, Bernert G, Makowski A, Zuchner S, De Jonghe P, Rudnik-Schoneborn S, Zerres K, Schroder JM. Mutations in the ganglioside-induced differentiation-associated protein-1 (*GDAP1*) gene in intermediate type autosomal recessive Charcot-Marie-Tooth neuropathy. *Brain* 2003;**126**:642-9.
- 8 **Boerkoel CF**, Takashima H, Nakagawa M, Izumo S, Armstrong D, Butler I, Mancias P, Pappasozomenos SC, Stern LZ, Lupski JR. CMT4A: Identification of a Hispanic *GDAP1* founder mutation. *Ann Neurol* 2003;**53**:400-5.

- 9 **De Sandre-Giovannoli A**, Chaouch M, Kozlov S, Vallat JM, Tazir M, Kassouri N, Szepletowski P, Hammadouche T, Vandenberghe A, Stewart CL, Grid D, Levy N. Homozygous defects in *LMNA*, encoding lamin A/C nuclear-envelope proteins, cause autosomal recessive axonal neuropathy in human (Charcot-Marie-Tooth disorder type 2) and mouse. *Am J Hum Genet* 2002;**70**:726-36.
- 10 **den Dunnen JT**, Antonarakis SE. Mutation nomenclature extensions and suggestions to describe complex mutations: a discussion. *Hum Mutat* 2000;**15**:7-12.
- 11 **Shapiro MB**, Senapathy P. RNA splice junctions of different classes of eukaryotes: sequence statistics and functional implications in gene expression. *Nucleic Acids Res* 1987;**15**:7155-74.
- 12 **Hayasaka K**, Takada G, Ionasescu VV. Mutation of the myelin PO gene in Charcot-Marie-Tooth neuropathy type 1B. *Hum Mol Genet* 1993;**2**:1369-72.
- 13 **Roa BB**, Dyck PJ, Marks HG, Chance PF, Lupski JR. Dejerine-Sottas syndrome associated with point mutation in the peripheral myelin protein 22 (PMP22) gene. *Nat Genet* 1993;**5**:269-73.
- 14 **Warner LE**, Mancias P, Butler U, McDonald C, Keppen L, Koob KG, Lupski JR. Mutations in the early growth response 2 (*EGR2*) gene are associated with hereditary myelinopathies. *Nat Genet* 1998;**18**:382-4.
- 15 **Kalaydjieva L**, Gresham D, Gooding R, Heater L, Baas F, de Jonghe R, Blechschmidt K, Angelicheva D, Chandler D, Worsley P, Rosenthal A, King RHM, Thomas PK. *N-myc Downstream regulated gene 1* is mutated in hereditary motor and sensory neuropathy-lom. *Am J Hum Genet* 2000;**67**:47-58.
- 16 **Lander ES**, Botstein D. Homozygosity mapping: a way to map human recessive traits with the DNA of inbred children. *Science* 1987;**236**:1567-70.
- 17 **Bolino A**, Muglia M, Conforti FL, LeGuern E, Salih MAM, Georgiou DM, Christodoulou K, Hausmanova-Petruševic I, Mandich P, Schenone A, Gambardella A, Bono F, Quattrone A, Devoto M, Monaco AP. Charcot-Marie-Tooth type 4B is caused by mutations in the gene encoding myotubularin-related protein-2. *Nat Genet* 2000;**25**:17-19.
- 18 **Guilbot A**, Williams A, Ravise N, Verny C, Brice A, Sherman DL, Brophy PJ, LeGuern E, Delague V, Bareil C, Megarbane A, Claustres M. A mutation in periaxin is responsible for CMT4F, an autosomal recessive form of Charcot-Marie-Tooth disease. *Hum Mol Genet* 2001;**10**:415-21.
- 19 **Liu H**, Nakagawa T, Kanematsu T, Uchida T, Tsuji S. Isolation of 10 differentially expressed cDNAs in differentiated Neuro2a cells induced through controlled expression of the *GD3* synthase gene. *J Neurochem* 1999;**72**:1781-90.
- 20 **Kojima N**, Kurosawa N, Nishi T, Hanai N, Tsuji S. Induction of cholinergic differentiation with neurite sprouting by de novo biosynthesis and expression of *GD3* and b-series gangliosides in Neuro2a cells. *J Biol Chem* 1994;**269**:30451-6.
- 21 **Yu RK**, Saito M. Structure and localization of gangliosides. In: Margolis RL, Margolis RK, eds. *Neurobiology of glycoconjugates*. New York: Plenum Press, 1989:1-42.
- 22 **Gong Y**, Tagawa Y, Lunn MP, Laroy W, Heffer-Lauc M, Li CY, Griffin JW, Schnaar RL, Sheikh KA. Localization of major gangliosides in the PNS: implications for immune neuropathies. *Brain* 2002;**125**:2491-506.
- 23 **Stern CA**, Tiemeyer M. A ganglioside-specific sialyltransferase localizes to axons and non-Golgi structures in neurons. *J Neurosci* 2001;**21**:1434-43.
- 24 **Liour SS**, Kapitonov D, Yu RK. Expression of gangliosides in neuronal development of P19 embryonal carcinoma stem cells. *J Neurosci Res* 2000;**62**:363-73.
- 25 **Fang Y**, Wu G, Xie X, Lu ZH, Ledeen RW. Endogenous GM1 ganglioside of the plasma membrane promotes neurite outgrowth by two mechanisms. *Neurochem Res* 2000;**25**:931-40.
- 26 **Kimura M**, Hidari KI, Suzuki T, Miyamoto D, Suzuki Y. Engagement of endogenous ganglioside GM1a induces tyrosine phosphorylation involved in neuron-like differentiation of PC12 cells. *Glycobiology* 2001;**11**:335-43.
- 27 **Prinetti A**, Iwabuchi K, Hakomori S. Glycosphingolipid-enriched signaling domain in mouse neuroblastoma Neuro2a cells. Mechanism of ganglioside-dependent neurite outgrowth. *J Biol Chem* 1999;**274**:20916-24.
- 28 **Fields RD**, Stevens-Graham B. New insights into neuron-glia communication. *Science* 2002;**298**:556-62.
- 29 **Fields RD**, Stevens B. ATP: an extracellular signaling molecule between neurons and glia. *Trends Neurosci* 2000;**23**:625-33.
- 30 **Adler V**, Yin Z, Fuchs SY, Benezra M, Rosario L, Tew KD, Pincus MR, Sardana M, Henderson CJ, Wolf CR, Davis RJ, Ronai Z. Regulation of JNK signaling by GSTP. *EMBO J* 1999;**18**:321-34.
- 31 **Dulhunty A**, Gage P, Curtis S, Chelvanayagam G, Board P. The glutathione transferase structural family includes a nuclear chloride channel and a ryanodine receptor calcium release channel modulator. *J Biol Chem* 2001;**276**:3319-23.
- 32 **Hemachand T**, Gopalakrishnan B, Salunke DM, Totey SM, Shaha C. Sperm plasma-membrane-associated glutathione S-transferases as gamete recognition molecules. *J Cell Sci* 2002;**115**:2053-65.
- 33 **Brady ST**, Witt AS, Kirkpatrick LL, de Waegh SM, Readhead C, Tu PH, Lee VM. Formation of compact myelin is required for maturation of the axonal cytoskeleton. *J Neurosci* 1999;**19**:7278-88.
- 34 **de Waegh SM**, Lee VM, Brady ST. Local modulation of neurofilament phosphorylation, axonal caliber, and slow axonal transport by myelinating Schwann cells. *Cell* 1992;**68**:451-63.
- 35 **Watson DF**, Nachtman FN, Kunz RW, Griffin JW. Altered neurofilament phosphorylation and beta tubulin isotypes in Charcot-Marie-Tooth disease type 1. *Neurology* 1994;**44**:2383-7.

- 36 **Garcia A**, Combarros O, Calleja J, Berciano J. Charcot-Marie-Tooth disease type 1A with 17p duplication in infancy and early childhood: a longitudinal clinical and electrophysiologic study. *Neurology* 1998;**50**:1061-7.
- 37 **Krajewski K**, Turansky C, Lewis R, Garbern J, Hinderer S, Kamholz J, Shy ME. Correlation between weakness and axonal loss in patients with CMT1A. *Ann N Y Acad Sci* 1999;**883**:490-2.