

## ELECTRONIC LETTER

# De novo germline *PTEN* mutation in a man with Lhermitte-Duclos disease which arose on the paternal chromosome and was transmitted to his child with polydactyly and Wormian bones

M B Delatycki, A Danks, A Churchyard, X-P Zhou, C Eng

*J Med Genet* 2003;**40**:e92(<http://www.jmedgenet.com/cgi/content/full/40/8/e92>)

Cowden syndrome (CS), also known as multiple hamartoma-neoplasia syndrome, is an autosomal dominant disease with numerous possible clinical manifestations.<sup>1</sup> Commonly present are skin changes including acral keratoses and facial trichilemmomas, as well as oral papillomas and scrotal tongue. There is an increased risk of malignancies including breast, thyroid, and endometrial cancers. Hamartomas may affect multiple systems including the skin, gastrointestinal tract, central nervous system, breast, and thyroid.<sup>1</sup>

CS is the result of germline mutations in the *PTEN* (phosphatase and tensin homologue deleted on chromosome 10) gene on chromosome subband 10q23.<sup>2</sup> Germline *PTEN* mutations have been described in a family with CS with one member with Lhermitte-Duclos disease (LDD),<sup>2,3</sup> Bannayan-Riley-Ruvalcaba syndrome (in the past variously called Bannayan-Zonana, Riley-Smith, or Ruvalcaba-Myhre-Smith syndrome)<sup>4</sup> as well as some cases of Proteus syndrome.<sup>5-7</sup> These diseases resulting from germline *PTEN* mutations are grouped as the PTEN hamartoma-tumour syndrome (PHTS).<sup>8</sup> Lhermitte-Duclos disease is characterised by dysplastic gangliocytoma of the cerebellum, usually presenting with signs of cerebellar dysfunction, cranial nerve palsies, and raised intracranial pressure.<sup>9,10</sup> Bannayan-Riley-Ruvalcaba syndrome is characterised by macrocephaly, lipomatosis, and pigmented macules of the glans penis.<sup>8</sup> Proteus syndrome, by contrast, is characterised by hemihypertrophy, macrocephaly, connective tissue naevi, and lipomatosis.<sup>5</sup>

Here we present a case of a male proband with LDD found to have a de novo *PTEN* mutation, whose son, with the same mutation, had macrocephaly, developmental delay, preaxial polydactyly, and wormian bones. This case raises the question of whether the last two features in the son relate to the *PTEN* mutation or are a coincidental occurrence. Of relevance, we show that the proband's de novo germline *PTEN* mutation arose on the paternal chromosome.

## MATERIALS AND METHODS

### *PTEN* mutation analysis

Genomic DNA was extracted from peripheral blood leucocytes from the proband, his son, and the proband's parents and subjected to polymerase chain reaction (PCR) based DGGE followed by direct sequence analysis as previously described.<sup>5,11</sup>

### Microsatellite genotyping analysis

Genomic DNA from the affected proband, his unaffected parents, and affected son were subjected to standard genotyping using fluorescent tagged primers and a Perkin-Elmer 3700 as previously described.<sup>12</sup> To determine parent of origin of the de novo mutation, microsatellite markers from the 10q22-q24

## Key points

- Lhermitte-Duclos disease and Cowden syndrome are often found to coexist and to be due to germline mutations in the *PTEN* gene.
- Here we present a proband with Lhermitte-Duclos disease with a pathogenic *PTEN* mutation. His 4 year old son with the same mutation has developmental delay, macrocephaly, preaxial polydactyly, and wormian bones on skull radiography. Polydactyly has once been described in a patient with Lhermitte-Duclos disease and is therefore likely to be a rare association with *PTEN* mutations.
- Genotyping of the affected proband, his unaffected parents, and his affected son using 10q markers flanking and within *PTEN* showed that the de novo mutation in the proband arose on the paternally inherited chromosome 10.

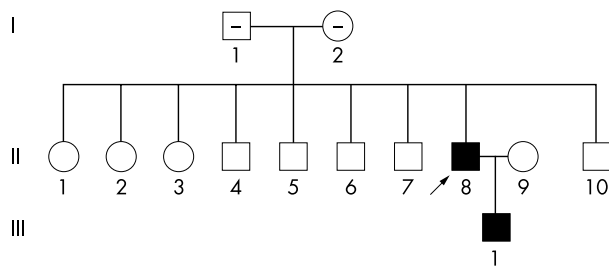
region flanking *PTEN* (D10S1765 which is within 1 Mb upstream of the 5' end of *PTEN*; D10S541 which is 1 Mb downstream of the 3' end of *PTEN*) and within *PTEN* (AFMa086wg9, *PTEN* IVS4+109del/ins5, *PTEN* IVS8+32T/G) were used. To exclude non-paternity, as well as the polymorphic markers on 10q22-q24, five further microsatellite markers were randomly selected from chromosome 3 (D3S1578, D3S1766, and D3S3697), and chromosome 9 (D9S171, D9S283). For the second, both individual allelic inheritance at each marker and haplotype inheritance were inspected.

## RESULTS

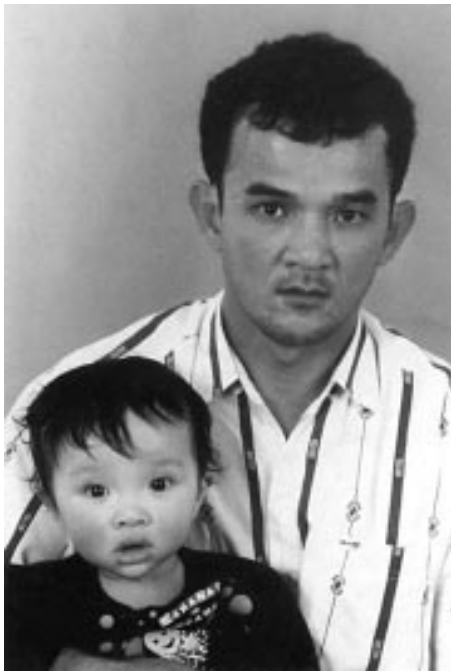### Case reports

The proband (fig 1, II.8) was a Vietnamese man who presented at 35 years with progressive ataxia and left seventh cranial nerve palsy. He is the eighth of nine children born to non-consanguineous parents. A computed tomography (CT) scan disclosed a 6 cm mass in the left cerebellar hemisphere with mass effect and compression of the fourth ventricle. He underwent craniotomy with excision of the lesion. Histopathology showed the lesion to be a dysplastic gangliocytoma. His neurological function improved postoperatively with marked improvement of ataxia and resolution of the seventh nerve palsy.

**Abbreviations:** CS, Cowden syndrome; CT, computed tomography; LDD, Lhermitte-Duclos disease; PCR, polymerase chain reaction; PHTS, PTEN hamartoma-tumour syndrome; *PTEN*, phosphatase and tensin homologue deleted on chromosome 10



**Figure 1** Pedigree of the family described. Filled figures are those with *PTEN* mutations and manifestations of PHTS. A minus sign within the figure means that that person has been tested for the familial *PTEN* mutation and was negative for it. The arrow points to the proband.



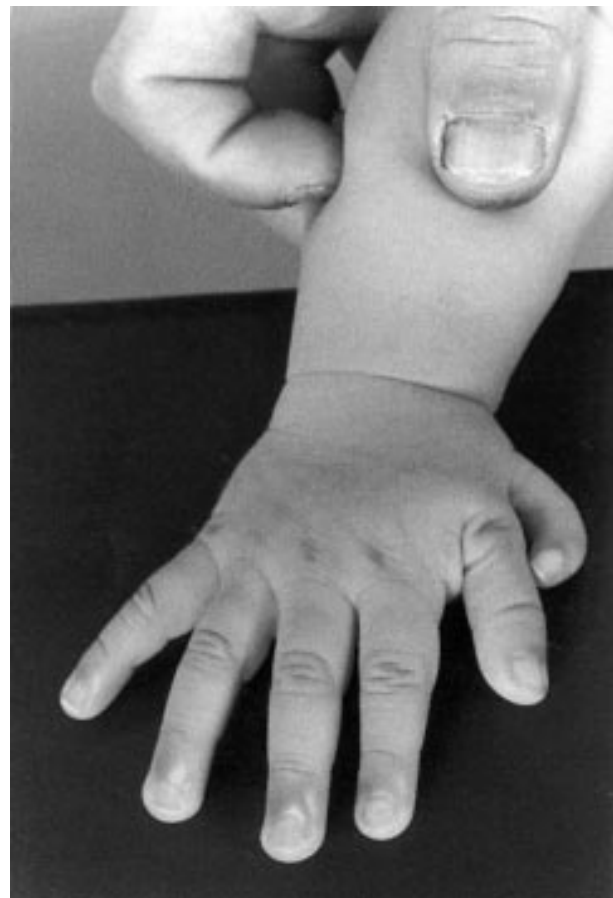**Figure 2** Face of proband and father.

Because of the association of dysplastic gangliocytoma with CS, the patient was seen by a dermatologist and noted to have multiple skin coloured papules on the head, neck, and lower legs. He had keratoses on the backs of his hands, punctate keratoderma on the palms, and white pinpoint keratoses of the lower lip. Biopsy of two of the papules showed inverted follicular keratosis. These findings are therefore consistent with CS, and do meet the operational diagnostic criteria of the International Cowden Consortium.<sup>13</sup>

As a result of the diagnosis of Lhermitte-Duclos disease, II.8 underwent investigations of thyroid pathology and was found to have a “cold” nodule and proceeded to a total thyroidectomy. Histopathology disclosed a multinodular goitre with no evidence of malignancy. Also, he had no symptoms to suggest the presence of gastrointestinal polyps but he had not been specifically investigated for this.

II.8 was born at term with a weight of 4300g (>90th centile). He was always noted to have a “big head” but no records exist with childhood head circumference measurements. He had significant learning problems throughout childhood and left school at 14 years of age. He currently works in a factory doing “odd jobs”.

On examination II.8 had significant macrocephaly with a head circumference of 66 cm (>98th centile), a height of 169 cm (10th centile), and a weight of 73 kg (60th centile) (fig 2).



**Figure 3** Hand of proband.

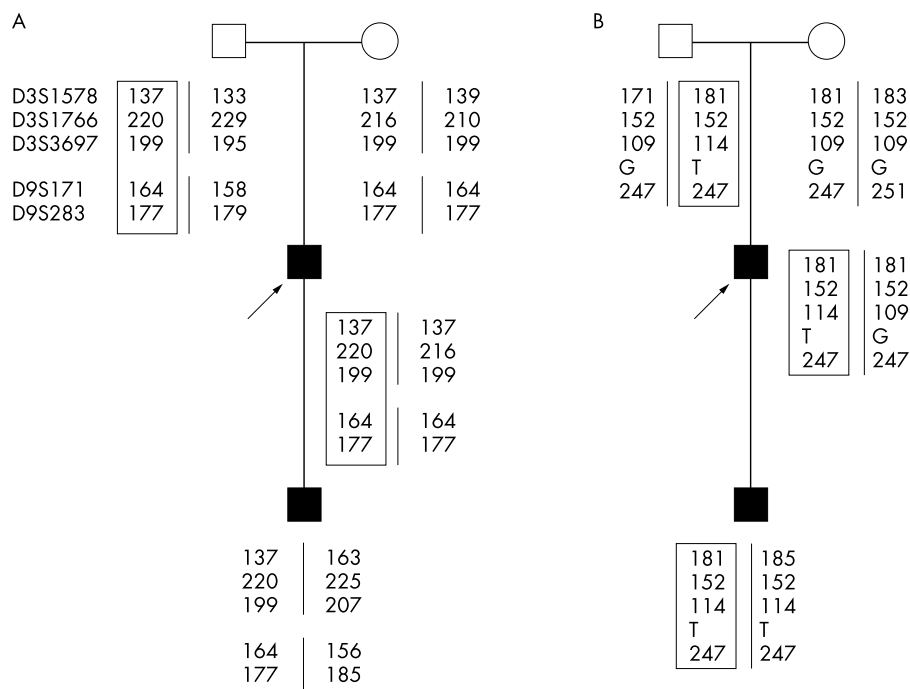
He had the dermatological findings already described. Papillomas were present on oral examination. There were no macules on his glans penis, no lipomata, and no other relevant findings.

II.8’s son III.1 was last seen when 4 years old. He was born with preaxial polydactyly of the right hand (fig 3). This was managed with surgery. His birth growth indices were a head circumference of 36 cm (50th centile), weight 3160 g (20th centile), and a length of 49.5 cm (50th centile).

When seen most recently, III.1 had developmental delay. He had been assessed as having an autism spectrum disorder. He walked at 19 months. At 4 years he was saying single words and was toilet trained in the day but not at night. He could feed himself with his hands but could not use any eating utensils. He was having early intervention. III.1 has had an adenotonsillectomy because of obstructive sleep apnoea. Formal audiology and ophthalmological examinations were normal.

On recent examination the head circumference of III.1 was 59.3 cm, which is well above the 98th centile. His height was 107 cm (80th centile) and his weight 18 kg (75th centile). He had an obviously large head with thick lips, but was otherwise not significantly dysmorphic (fig 2). He had a scar from the surgery to remove the extra preaxial digit. He had one café au lait patch and a mongolian blue patch, but his dermatological examination was otherwise unremarkable and in particular he had no penile macules.

III.1 has been investigated with a karyotype and fragile X studies, both of which were normal. An MRI scan of his head disclosed dilated Virchow-Robin spaces and a small venous angioma of the right posterior frontal lobe. The cerebellum was normal. A skeletal survey on III.1 showed preaxial polydactyly with a small metacarpal and two small phalanges. Also, numerous wormian bones were noted. There were no



**Figure 4** (A) Haplotypes comprising alleles from chromosomes 3 and 9 showing, along with the haplotypes in (B), that non-paternity is excluded with a very high degree of certainty. The markers used from chromosomes 3 and 9 are shown to the left of the proband's father's haplotypes. The haplotype inherited by the proband from his father is boxed. The arrow denotes the proband. (B) Haplotypes comprising alleles at 10q22-q24 markers flanking and within *PTEN*. The markers used are D10S1765 (top), AFma086wg9, IVS4+109ins/del5 (the del5 allele is denoted 109 and the ins5 allele 114), IVS8+32T/G, and D10S541 (bottom). The boxed haplotype is the paternal one on which the *PTEN* mutation arose. The arrow denotes the proband.

other features of osteogenesis imperfecta on the skeletal survey and III.1 did not have blue sclerae.

The family history was otherwise unremarkable and in particular there was no family history of malignancies of the breast or thyroid and no other family members with learning disabilities (fig 1).

### Molecular analyses

*PTEN* mutation analysis showed a c.177–179 delA mutation in exon 3 of the *PTEN* gene in both the proband, II.8, and his affected son. This single base deletion is predicted to result in a stop codon 39 codons downstream and thus in a severely truncated protein product. Testing of the unaffected parents of II.8 showed that this mutation was not present and therefore it is de novo in the proband. Genotyping using seven microsatellite markers on chromosomes 3, 9, and 10 and three polymorphic loci within *PTEN* excluded non-paternity (fig 4A B). Segregation of alleles at each informative polymorphic locus was consistent with mendelian inheritance. Further, haplotypes formed by markers on chromosomes 3, 9, and 10q, respectively, were all informative and excluded non-paternity as well.

Haplotypes were formed from individual genotypes at the two microsatellite loci flanking *PTEN* and the three intragenic polymorphic loci for the affected proband, his affected son, and his unaffected parents (fig 4 B). Inspection of the 10q22-q24 haplotypes showed that the de novo *PTEN* mutation in the proband arose on the paternal chromosome 10 (haplotype 181-152-114-T-247), and that both the mutation and this haplotype were transmitted from the proband to his affected son.

### DISCUSSION

Both our proband II.8 and his son had a germline truncating *PTEN* mutation with II.8 having LDD and other features of CS, and the son having so far macrocephaly, developmental delay, polydactyly, and wormian bones. Polydactyly and wormian

bones have not been described in PHTS although polydactyly was described in association with LDD.<sup>14</sup> It is presumed that the developmental delay and macrocephaly of III.1 relate to the mutation in *PTEN*. Of note, we have shown that this de novo germline *PTEN* mutation arose on the paternal chromosome.

The coexistence of LDD and CS was recognised by Padberg *et al*,<sup>15</sup> highlighted by Eng *et al*<sup>3</sup> and was proved when mutations in *PTEN* were recognised as the underlying cause.<sup>2 16</sup> It is clear that the diagnosis of LDD should prompt the assessment for features of CS and surveillance for CS associated malignancies; however, it remains unclear whether all cases of LDD coexist with CD.<sup>10 13</sup>

The issue of surveillance for III.1, who is germline *PTEN* mutation positive, is a complex one and no guidelines exist for surveillance for LDD. The complexity exists because any single feature of CS/PHTS may not breed true. Thus, it is unclear what the prior probability of the proband's son actually developing this component. He is presumably at increased risk of a cerebellar gangliocytoma. Given that LDD can present in childhood,<sup>17-21</sup> he will be monitored by yearly neurological examinations and repeat MRI at 10 years of age and three yearly thereafter, if asymptomatic. The rationale for surveillance for LDD is that it is a progressive lesion and therefore early diagnosis and treatment may be beneficial.<sup>9</sup> As well as offering surveillance for LDD, both the proband and his son, who are both mutation positive, will be recommended to have surveillance for the component tumours associated with CS/PHTS in accordance with the United States National Comprehensive Cancer Centre High Risk/Genetics Panel guidelines, which are similar to those of the International Cowden Consortium.<sup>15</sup> For example, annual thyroid surveillance is recommended beginning in the teens. Minimally, a single baseline thyroid ultrasound followed by careful physical examination of the neck would therefore be recommended. It is thought that clear cell renal cell carcinoma may be a component in male patients and so an annual urine dipstick

for occult blood or abdominal ultrasound may be considered. The second is particularly pertinent in families with a known history of renal cell carcinoma.

The causative mutation in the father and son lies in exon 3 and results in a severely truncated protein. Genotype-phenotype association analyses have previously shown that germline mutations that are within or 5' to the phosphatase core motif in exon 5 are associated with more severe disease.<sup>22</sup> Also, most *PTEN* mutations in LDD have been truncating<sup>21,23</sup> with the exception of an exon 5 missense mutation that was shown to reduce phosphatase activity very significantly.<sup>24</sup> The proband presented here clearly had severe disease with significant intellectual impairment, a cerebellar gangliocytoma, macrocephaly, and benign thyroid disease. His son had significant developmental delay and macrocephaly. Time will tell how many other manifestations will arise.

The same *PTEN* mutation can result in very different phenotypes in the same family<sup>25</sup> and between families.<sup>12</sup> The features in III.1 of preaxial polydactyly and wormian bones have not previously been described in those with *PTEN* mutations although polydactyly has been described in LDD.<sup>14</sup> Neither II.8 nor III.1 fit the diagnostic criteria of Bannayan-Riley-Ruvalcaba syndrome. A dysmorphology database search did not show any other cause for this combination of features.<sup>26</sup>

In conclusion, therefore, based on the family presented and the protean manifestations of PHTS, it is probable that postaxial polydactyly and wormian bones are rare manifestations of *PTEN* mutations. More importantly, we have shown for the first time that a de novo germline *PTEN* mutation has arisen on the paternal chromosome.

#### Authors' affiliations

**M B Delatycki**, Bruce Lefroy Centre for Genetic Health Research, Royal Children's Hospital, Parkville, Victoria, 3052, Australia

**M B Delatycki**, Murdoch Children's Research Institute, Royal Children's Hospital, Parkville, Victoria, 3052, Australia

**A Danks**, Department of Neurosurgery, Southern Health, Monash Medical Centre, Clayton, Victoria, 3168, Australia

**A Churchyard**, Department of Neurology, Southern Health, Monash Medical Centre, Clayton, Victoria, 3168, Australia

**X-P Zhou, C Eng**, Human Cancer Genetics Program, and the Division of Human Genetics, Department of Internal Medicine, The Ohio State University, Columbus, Ohio 43210, USA

Correspondence to: Dr M B Delatycki, Bruce Lefroy Centre for Genetic Health Research, Royal Children's Hospital, Flemington Road Parkville, 3052 Victoria, Australia; delatyckm@cryptic.rch.unimelb.edu.au

#### REFERENCES

- Hanssen AM**, Fryns JP. Cowden syndrome. *J Med Genet* 1995;**32**:117-9.
- Liaw D**, Marsh DJ, Li J, Dahia PL, Wang SI, Zheng Z, Bose S, Call KM, Tsou HC, Peacocke M, Eng C, Parsons R. Germline mutations of the *PTEN* gene in Cowden disease, an inherited breast and thyroid cancer syndrome. *Nat Genet* 1997;**16**:64-7.
- Eng C**, Murday V, Seal S, Mohammed S, Hodgson SV, Chaudary MA, Fentiman IS, Ponder BA, Eeles RA. Cowden syndrome and Lhermitte-Duclos disease in a family: a single genetic syndrome with pleiotropy? *J Med Genet* 1994;**31**:458-61.

- Marsh DJ**, Dahia PL, Zheng Z, Liaw D, Parsons R, Gorlin RJ, Eng C. Germline mutations in *PTEN* are present in Bannayan-Zonana syndrome. *Nat Genet* 1997;**16**:333-4.
- Zhou XP**, Marsh DJ, Hampel H, Mulliken JB, Gimm O, Eng C. Germline and germline mosaic *PTEN* mutations associated with a Proteus-like syndrome of hemihypertrophy, lower limb asymmetry, arteriovenous malformations and lipomatosis. *Hum Mol Genet* 2000;**9**:765-8.
- Zhou X**, Hampel H, Thiele H, Gorlin RJ, Hennekam RC, Parisi M, Winter RM, Eng C. Association of germline mutation in the *PTEN* tumour suppressor gene and Proteus and Proteus-like syndromes. *Lancet* 2001;**358**:210-11.
- Smith J**, Kirk E, Theodosopoulos G, Marshall G, Walker J, Rogers M, Field M, Brereton J, Marsh D. Germline mutation of the tumour suppressor *PTEN* in Proteus syndrome. *J Med Genet* 2002;**39**:937-40.
- Waite KA**, Eng C. Protean *PTEN*: form and function. *Am J Hum Genet* 2002;**70**:829-44.
- Nowak DA**, Trost HA. Lhermitte-Duclos disease (dysplastic cerebellar gangliocytoma): a malformation, hamartoma or neoplasm? *Acta Neurol Scand* 2002;**105**:137-45.
- Robinson S**, Cohen AR. Cowden disease and Lhermitte-Duclos disease: characterization of a new phakomatosis. *Neurosurgery* 2000;**46**:371-83.
- Mutter GL**, Lin MC, Fitzgerald JT, Kum JB, Baak JP, Lees JA, Weng LP, Eng C. Altered *PTEN* expression as a diagnostic marker for the earliest endometrial precancers. *J Natl Cancer Inst* 2000;**92**:924-30.
- Marsh DJ**, Kum JB, Lunetta KL, Bennett MJ, Gorlin RJ, Ahmed SF, Bodurtha J, Crowe C, Curtis MA, Dasouki M, Dunn T, Feit H, Geraghty MT, Graham JM Jr, Hodgson SV, Hunter A, Korf BR, Manchester D, Miesfeldt S, Murday VA, Nathanson KL, Parisi M, Pober B, Romano C, Eng C. *PTEN* mutation spectrum and genotype-phenotype correlations in Bannayan-Riley-Ruvalcaba syndrome suggest a single entity with Cowden syndrome. *Hum Mol Genet* 1999;**8**:1461-72.
- Eng C**. Will the real Cowden syndrome please stand up: revised diagnostic criteria. *J Med Genet* 2000;**37**:828-30.
- Bielschowsky M**, Simons A. Uber di use hamartome (ganglioneurome) des Kleinhirns und ihrer genese. *J Psychol Neurol* 1930;**41**:50-75.
- Padberg GW**, Schot JD, Vielvoye GJ, Bots GT, de Beer FC. Lhermitte-Duclos disease and Cowden disease: a single phakomatosis. *Ann Neurol* 1991;**29**:517-23.
- Nelen MR**, van Staveren WC, Peeters EA, Hassel MB, Gorlin RJ, Hamm H, Lindboe CF, Fryns JP, Sijmons RH, Woods DG, Mariman EC, Padberg GW, Kremer H. Germline mutations in the *PTEN/MMAC1* gene in patients with Cowden disease. *Hum Mol Genet* 1997;**6**:1383-7.
- Amblor M**, Pogacar S, Sidman R. Lhermitte-Duclos disease (granule cell hypertrophy of the cerebellum) pathological analysis of the first familial cases. *J Neuropathol Exp Neurol* 1969;**28**:622-47.
- Heitkamp JW**, Rose JE. Neck pain following migration of a ventriculocervical shunt. *Surg Neurol* 1983;**19**:285-7.
- Roessmann U**, Wongmongkolrit T. Dysplastic gangliocytoma of cerebellum in a newborn. Case report. *J Neurosurg* 1984;**60**:845-7.
- Marano SR**, Johnson PC, Spetzler RF. Recurrent Lhermitte-Duclos disease in a child: case report. *J Neurosurg* 1988;**69**:599-603.
- Wells GB**, Lasner TM, Yousem DM, Zager EL. Lhermitte-Duclos disease and Cowden's syndrome in an adolescent patient. Case report. *J Neurosurg* 1994;**81**:133-6.
- Marsh DJ**, Coulon V, Lunetta KL, Rocca-Serra P, Dahia PL, Zheng Z, Liaw D, Caron S, Duboue B, Lin AY, Richardson AL, Bonnetblanc JM, Bressieux JM, Cabarrot-Moreau A, Chompert A, Demange L, Eeles RA, Yahanda AM, Fearon ER, Fricker JP, Gorlin RJ, Hodgson SV, Huson S, Lacombe D, Eng C. Mutation spectrum and genotype-phenotype analyses in Cowden disease and Bannayan-Zonana syndrome, two hamartoma syndromes with germline *PTEN* mutation. *Hum Mol Genet* 1998;**7**:507-15.
- Koch R**, Scholz M, Nelen MR, Schweddeheimer K, Epplen JT, Harders AG. Lhermitte-Duclos disease as a component of Cowden's syndrome. Case report and review of the literature. *J Neurosurg* 1999;**90**:776-9.
- Sutphen R**, Diamond TM, Minton SE, Peacocke M, Tsou HC, Root AW. Severe Lhermitte-Duclos disease with unique germline mutation of *PTEN*. *Am J Med Genet* 1999;**82**:290-3.
- Zori RT**, Marsh DJ, Graham GE, Marliss EB, Eng C. Germline *PTEN* mutation in a family with Cowden syndrome and Bannayan-Riley-Ruvalcaba syndrome. *Am J Med Genet* 1998;**80**:399-402.
- Bankier A**. *Pictures of standard syndromes and undiagnosed malformations*: Melbourne: Murdoch Childrens Research Institute, 2002.