

## ONLINE MUTATION REPORT

## Clinical features of type 2 Stickler syndrome

A V Poulson, J M M Hooymans, A J Richards, P Bearcroft, R Murthy, D M Baguley, J D Scott, M P Snead

*J Med Genet* 2004;41:e107 (<http://www.jmedgenet.com/cgi/content/full/41/8/e107>). doi: 10.1136/jmg.2004.018382

The Stickler syndromes<sup>1-8</sup> (hereditary arthro-ophthalmopathy; McKusick nos. 108300 and 604841) are one of the more frequently occurring groups of chondrodysplasias and are the commonest inherited cause of rhegmatogenous retinal detachment.<sup>9</sup> The majority of patients and pedigrees exhibit the type 1 or "membranous" vitreous phenotype<sup>10-11</sup> and harbour mutations in the gene for type II collagen (*COL2A1*).<sup>12-21</sup> While not all mutations in type II collagen result in the membranous vitreous anomaly,<sup>22-23</sup> when it is exhibited it appears to be congenital and provides a useful basis for mutant locus assignment. This is particularly helpful for sporadic cases where linkage is impossible, and especially in those individuals with mild or minimal systemic involvement where the diagnosis might otherwise be overlooked.<sup>19-24-26</sup> Other pedigrees exhibit a different "beaded" vitreous phenotype and are linked to a different locus.<sup>11-27</sup> We reported the first mutation in the gene encoding the  $\alpha 1$  chain of type XI collagen (*COL11A1*) in one of these pedigrees<sup>28</sup> and this locus was confirmed in other pedigrees,<sup>29-30</sup> and is now known as type 2 Stickler syndrome (McKusick no. 604841). The intimate post-translational molecular associations between types II and XI collagen form the foundation of the close clinical overlap between these two sub-groups of Stickler syndrome, but the extent of this clinical overlap and variation remains to be defined. Whilst type 1 Stickler syndrome pedigrees have a particularly high risk of blindness through giant retinal tear and retinal detachment, Annunen *et al* suggest that patients with *COL11A1* mutations are at a low risk of retinal detachment and have a higher incidence of midfacial hypoplasia.<sup>29</sup> This would be an important prognostic difference if confirmed. Here we wish to report the first description of the ophthalmic, oro-facial, audiological, skeletal, and echocardiographic features of a large cohort of patients with type 2 Stickler syndrome in which molecular genetic analysis has confirmed mutations in *COL11A1*.

## METHODS

Five pedigrees with Stickler syndrome, all exhibiting the beaded or type 2 vitreous phenotype, were identified from the Vitreous Research Clinic at Addenbrooke's Hospital, Cambridge, UK. Ethical approval was granted (LRC92/019) and informed written consent was received in all cases. A sixth pedigree was identified via our collaboration with the University Hospital of Groningen, Netherlands.

The diagnostic criteria used to identify the index cases were modified from those previously published for type 1 Stickler syndrome<sup>11</sup> and are as follows: a "major" criterion: "beaded" vitreous anomaly and, in addition, any three of the following "minor" criteria:

1. Myopia with onset before 6 years of age.
2. Rhegmatogenous retinal detachment or paravascular pigmented lattice retinopathy.
3. Joint hypermobility with abnormal Beighton score, with or without radiological evidence of joint degeneration.

## Key points

- The clinical features of patients with type 2 Stickler syndrome with confirmed mutations in the gene encoding the  $\alpha 1$  chain of type XI collagen (*COL11A1*) are described.
- Six pedigrees, all exhibiting the beaded or type 2 vitreous phenotype, were identified. Ophthalmic, oro-facial, skeletal, and audiological features were assessed in addition to echocardiography. Linkage analysis was carried out with markers for the candidate genes *COL2A1*, *COL11A1*, and *COL11A2*. Amplification and sequencing of *COL11A1* cDNA was achieved using RNA from cultured dermal fibroblasts.
- Thirty one affected members from the six pedigrees were identified. Of these 87% were myopic and 38% had paravascular lattice retinopathy, 64% had a cataract and five exhibited the wedge-shaped cortical opacities typical of Stickler syndrome. Forty two per cent had suffered retinal detachment, 19% bilaterally. The average age at which retinal detachment occurred was 34 years (range 9-55). Thirty seven per cent showed evidence of midline clefting and 80% were found to have mild (asymptomatic) or moderate high tone sensorineural hearing loss. No patient had evidence of mitral valve prolapse.
- Type 2 Stickler pedigrees with confirmed mutations in *COL11A1* have a high risk of retinal detachment. The facial phenotype is highly variable. The diagnosis, which can be determined by observation of the vitreous phenotype, can be helped by audiological evidence of sensorineural deafness.

4. Audiometric confirmation of sensorineural hearing defect.
5. Midline clefting (bifid uvula, submucous cleft, high arch palate, cleft repair, Pierre Robin sequence).

Ophthalmic, oro-facial, skeletal, and audiological features were assessed using the methods reported previously<sup>19</sup> in addition to echocardiography. A general ophthalmic history was recorded with particular attention to the age of onset, degree and progression of myopia, cataract, and vitreoretinal disease. A full ophthalmic examination was carried out. In some of the younger patients applanation tonometry and gonioscopy were not possible. Anterior and posterior segment photographs were taken where appropriate.

Orofacial features were assessed according to standard protocols.<sup>31</sup> Antero-posterior and lateral facial photographs at a standardised scale of 1:8 using a Nikon FM2 camera with Micro Nikon 105 mm medical lens and Kodachrome 64 film

at F16. A 1 cm grid was printed and then photographed at a scale of 1:8 to match and clinical measurements of outer canthal distance, inner canthal distance, philtrum length, and middle finger length were also recorded. These measurements were used as controls for the photographic calibration. Control measurements of inner and outer canthal distance, interpupillary distance, and philtrum length from 20 unaffected siblings and 60 age matched controls (recruited from the general ophthalmic clinic) were also recorded.

Joint hypermobility was assessed objectively using the Beighton scoring system.<sup>32</sup> A score of 1 or 0 is given for a series of joint manoeuvres and the total sum allocated up to a possible maximum score of 9/9.

An enquiry was made regarding the date and progression of any subjective hearing loss and, in particular, whether this had been a congenital, sudden, or progressive deterioration. A record of the type and duration of noise exposure was made together with any factors likely to contribute a conductive element to any hearing loss. All affected patients underwent bilateral otoscopy and audiometry involving air and bone conduction testing according to standardised procedures.<sup>33</sup>

Patients were questioned about their cardiovascular history and underwent a full cardiological examination including auscultation and 2-D echocardiography. Echocardiographic studies were carried out using a Hewlett-Packard Sonos 1000 with 3.5–2.5 MHz phased array transducers. Echocardiographic views consisted of long and short axes, apical four and apical two chambers, incorporating conventional pulsed and colour flow Doppler.

For the large families MS1, MS40, MS42, and JH1, linkage analysis was carried out with flanking and/or intragenic markers for the candidate genes *COL2A1*, *COL11A1*, and *COL11A2* as previously described.<sup>30</sup> For MS67 and MS71, analysis of *COL11A1* was performed on the basis of vitreous phenotype. Amplification and sequencing of *COL11A1* cDNA was achieved using RNA from cultured dermal fibroblasts.<sup>28 30</sup>

## RESULTS

A total of 31 affected members from six pedigrees were identified. The pedigrees are shown in fig 1.

All patients exhibited the “beaded” vitreous phenotype (fig 2) and had confirmed mutations in the  $\alpha 1$  chain of type XI collagen (*COL11A1*) shown in table 1. The Dutch family JH1 was found to have the same mutation as the British family MS42.

### Clinical features

Twenty patients (65%) were female and 11 (35%) male. The ages ranged from 10 to 84 years with an average age of 38. The clinical features are summarised in table 2.

### Ophthalmic

A total of 87% of patients were short sighted (myopic) and 14 (52%) of the patients reported their myopia to be stable. Some unaffected individuals exhibiting a normal vitreous phenotype were also myopic, including one of non-identical twins, MS40 IV:5, emphasising the importance of vitreous phenotype as a marker for the disorder.

Some 64% of patients either had cataract or were aphakic or pseudophakic. Of the phakic patients with cataract, 33% (5/15) exhibited the wedge-shaped lens opacity peculiar to Stickler syndrome<sup>34 35</sup> and some sporadic cases of rhegmatogenous retinal detachment (fig 3).

A total of 38% had pigmented paravascular lattice. Thirteen patients (42%) suffered retinal detachment. Six had bilateral retinal detachment, one with bilateral giant retinal tears. The average age at which retinal detachment had occurred was

34 years with a range of 9–55 years. Two patients had retinal detachment under the age of 16.

### Orofacial

One third of patients were found to have variable manifestations of mid-line clefting including bifid uvula, high arched palate, and cleft palate. Facial features were in general more subtle than those seen in type 1 Stickler syndrome with mild mid-facial and nasal hypoplasia. In some affected individuals the facial phenotype did not vary significantly from age/sex matched controls<sup>31</sup> (fig 4).

Seven patients had lateral skull *x* rays. Four were normal (normal calvaria and frontal sinuses). Of the three abnormal cases, in one the frontal sinus was absent; in another it was small and, in contrast, large in the third.

No patient had any abnormalities of skin, hair, or sweating as reported in Marshall syndrome.<sup>36</sup>

### Skeletal

One third of patients exhibited or reported previous joint laxity (fig 5) with almost half experiencing symptoms of arthritis (most frequently knees, ankles, back, and wrists).

### Audiological

A total of 45% of patients reported symptomatic hearing loss but, of those tested, 20/25 (80%) had some degree of high frequency sensorineural hearing loss ranging from mild (30 dB) to moderate (30–60 dB) loss. No patient reported profound deafness in either ear. Three patients had mild or moderate conductive hearing loss in addition to sensorineural loss.

### Mitral valve prolapse

None of the 12 patients who underwent echocardiography had mitral valve prolapse.

## DISCUSSION

This is the first report describing the clinical features of type 2 Stickler syndrome. All patients have a proven mutation in *COL11A1* and exhibited the “beaded” type 2 vitreous phenotype.

The range of clinical features is similar to those in type 1 Stickler syndrome, with variability between and within families, but with a particularly high prevalence of sensorineural hearing loss which is often mild enough to go unnoticed by the patient. In contrast to the study by Annunen *et al*, this study confirms that individuals are indeed at high risk of retinal detachment, 42% of this group having suffered a retinal detachment in at least one eye at the time of study.

There has been some confusion in the literature regarding the vitreous phenotypes of type 1 and type 2 Stickler syndrome. It is important to recognise that the type 1 anomaly is a congenital and not a degenerative manifestation. Following a case report by Parentin *et al*,<sup>37 38</sup> McLeod *et al*<sup>39</sup> have suggested that observation of the vitreous phenotype is not reliable in distinguishing between type 1 and type 2 Stickler syndromes. The pedigree reported by Parentin *et al*<sup>37 38</sup> was classified as type 1 Stickler syndrome but linkage analysis was thought to favour *COL11A1* rather than *COL2A1*, although no mutation analysis was performed. The description in the manuscript of the vitreous phenotype suggested type 1 Stickler syndrome, but the photographs included in the paper did not demonstrate the type 1 vitreous anomaly. All three patients, in whom the vitreous had been commented upon, had bilateral retinal detachment. An alternative explanation is that the type 1 vitreous anomaly was confused with the detached posterior hyaloid membrane. In addition, the implication of *COL11A1* was only weakly

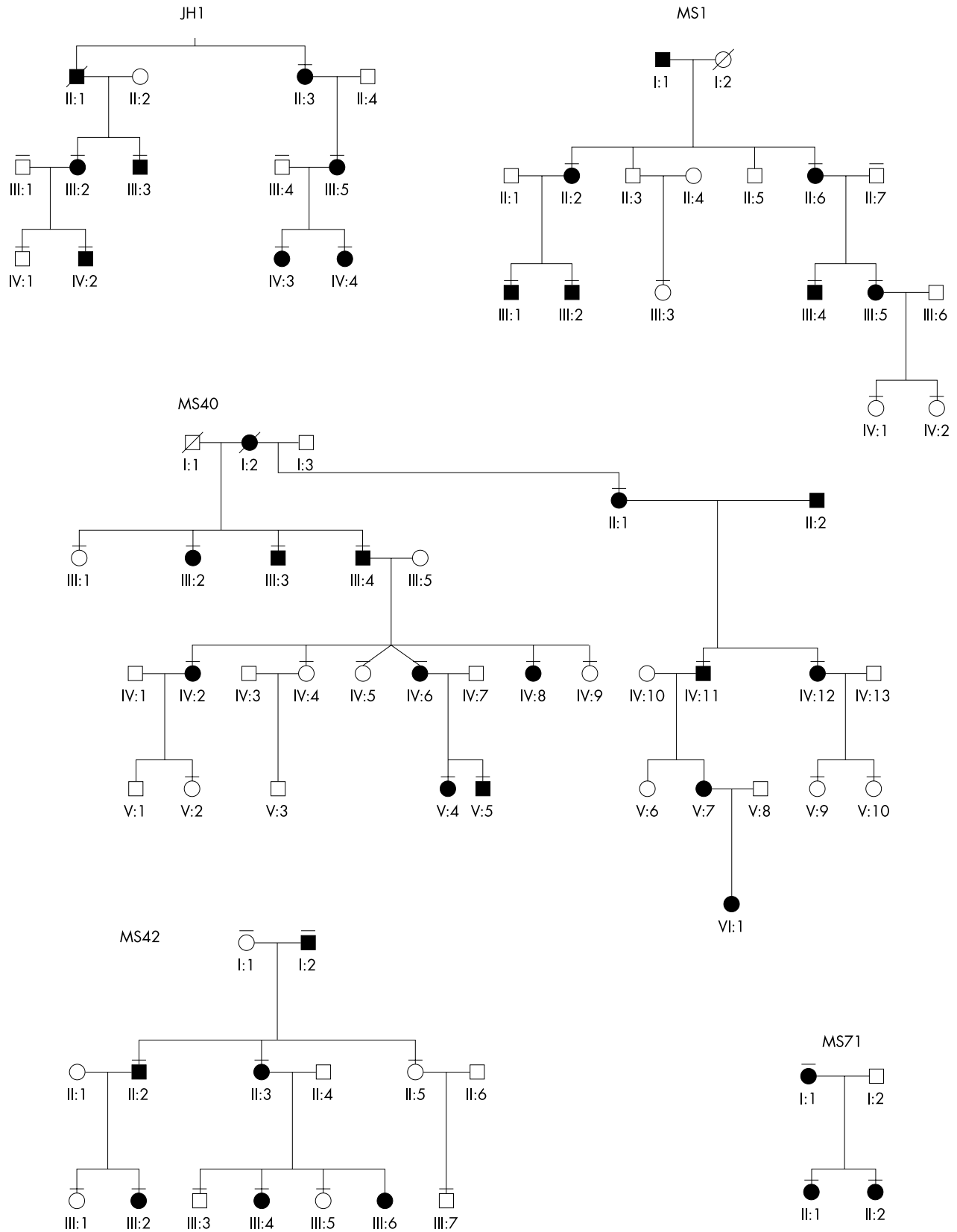
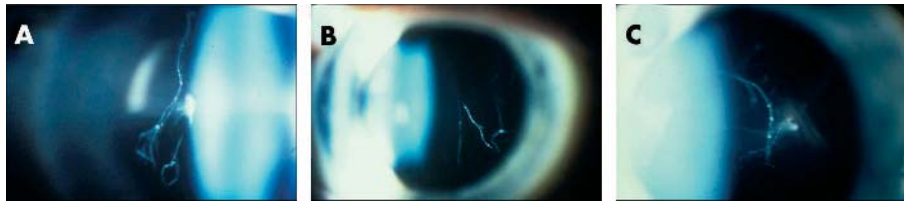


Figure 1 Type 2 Stickler syndrome pedigrees. The sixth pedigree consists of one member MS67 I:1.



**Figure 2** “Beaded” vitreous phenotype: (A, B) MS42 III:2; (C) MS42 II:2.

supported by the linkage analysis, whilst the markers used for the linkage analysis did not adequately exclude a mutation in *COL2A1* as they did not flank both sides of the gene.

McLeod *et al*<sup>39</sup> also describe two affected members of a type 2 Stickler syndrome pedigree (with a *COL11A1* mutation confirmed) and report that the vitreous phenotype appeared

to change from a type 2 anomaly to a type 1 anomaly with the development of a posterior vitreous detachment. In contrast to the congenital type 1 vitreous anomaly, the posterior hyaloid membrane is visible only after posterior vitreous detachment and is clearly a separate entity.<sup>40</sup> Both membranes can be demonstrated in the same eye when a patient with type 1 Stickler syndrome develops a posterior vitreous

**Table 1** *COL11A1* mutations

ID	cDNA mutation	Genomic DNA mutation	Reference
MS1	G-T G97V	G-T G97V	Richards <i>et al</i> , 1996 <sup>28</sup>
MS40	774 bp deletion	Exon 31–42 deletion	Martin <i>et al</i> , 1999 <sup>30</sup>
MS42	Exon 15 skip (54 bp)	IVS 14 A-2 del	Martin <i>et al</i> , 1999 <sup>30</sup>
MS67	Exon 52 skip (54 bp)	IVS 52 G+1 – A+1	This report
MS71	Exon 61 skip (36 bp)	IVS 60 A-2 – G-2	This report
JH1	Exon 15 skip (54 bp)	IVS 14 A-2 del	This report

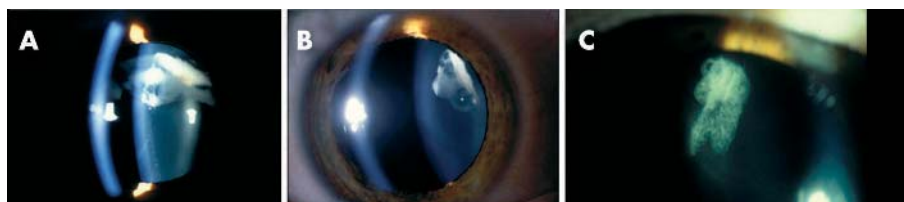
**Table 2** Clinical features of patients with type 2 Stickler syndrome

Pedigree number	Age	Ocular phenotype		Articular phenotype		Aural phenotype		Oro-facial phenotype	
		Myopia*	RD†	Joint hypermobility	Radiological abnormality	Conductive loss‡	Sensorineural loss‡	Midface hypoplasia	Cleft§
JH1	IV:3	21	+	+	0			0	0
JH1	IV:2	10	+	0	0			0	0
JH1	III:5	49	+	+	0			0	0
JH1	III:3	34	+	Cryo	0				+++
JH1	III:2	42	++	++	0			0	+++
JH1	II:3	84	+	Laser	0			0	0
JH1	IV:4	18	+	+	0	0	0	+	+++
MS1	III:4	32	+++	++	+	++	++	+	+++
MS1	III:5	34	+++	+	0	0	+	+	0
MS1	III:2	28	++	Cryo	+	0	+	+	+++
MS1	III:1	31	+++	++	0	0	0	+	0
MS1	II:6	59	+++	0	0	0	+	+	+
MS1	II:2	55	+	+	0	0	++	0	0
MS40	III:3	63	++	0	0	+	++	0	0
MS40	III:2	68	+++	+	++	0	++	+	0
MS40	IV:12	43	0	0	0	0/+	+	+	0
MS40	IV:11	47	0	0	+	0	++	+	0
MS40	III:4	57	+	++	0	+	+	+	++
MS40	II:1	65	+	++	0	+	++	0	0
MS40	IV:2	36	+	0	++	0	+	+	0
MS40	IV:6	34	0	0	0	0	0	+	0
MS40	IV:8	32	+	0	0	+	+	0	0
MS42	I:2	73	+	+	0	+	+	+	0
MS42	II:3	41	+	++	0	0	+	++	0
MS42	III:2	14	+	0	0	0	0	0	0
MS42	III:4	12	++	0	0	0	+	+	++
MS42	II:2	44	+	Laser	0	+	+	+	0
MS67	I:1	19	+++	0	+	+	++	+	
MS71	I:1	47	+	0	++	0	+	+	++
MS71	II:1	17	++	0	++	+	++	+	+++
MS71	II:2	11	0	0	++	+	+	+	+++

0: absent; +: mild; ++: moderate; +++: severe.

\*0: not myopic; +: mild (<-5); ++: moderate (-5 to -10); +++: high (>-10); †Retinal detachment (RD): 0: no RD; +: RD in one eye; ++: RD in both eyes; cryo/laser: prophylactic cryo or laser retinopexy; ‡0: none; +: mild 30 dB; ++: moderate 30–60 dB; +++: severe >60 dB; §0: none; +: bifid uvula; ++: high arched; +++: cleft palate.

All patients exhibited the “beaded” vitreous phenotype and had confirmed mutations in the  $\alpha 1$  chain of type XI collagen (*COL11A1*).



**Figure 3** Characteristic cortical cataract: (A) MS40 IV:2; (B) MS1 III:2; (C) MS1 III:5.

detachment. The posterior hyaloid membrane differs in its position, its movement, and the degree of surface crinkling. We believe the suggestion that the type 2 phenotype can convert to the type 1 phenotype is misleading.

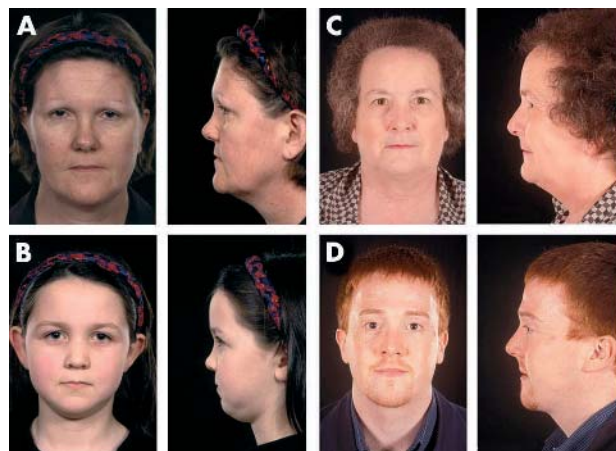The “beaded” type 2 vitreous anomaly is less easy to distinguish but, as our study demonstrates, is sufficiently characteristic to be a useful clinical hallmark differentiating type 2 from type 1 Stickler syndrome.

In contrast to the findings of Liberfarb and Goldblatt<sup>41</sup> who found that over 45% of their patients had mitral valve prolapse, Ahmad *et al*<sup>42</sup> looked at 78 patients who included both type 1 and the type 2 Stickler syndrome patients included in this study and found that none had mitral valve prolapse.

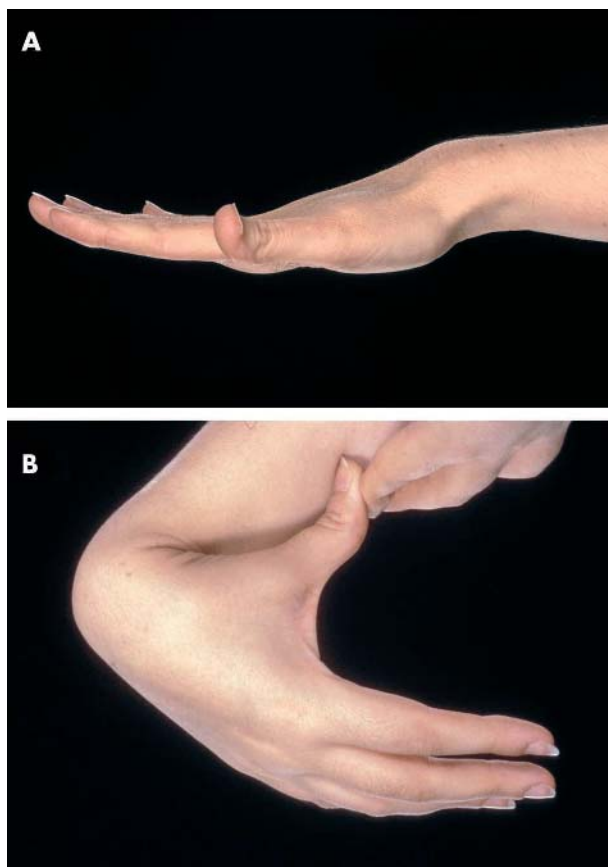
Other disorders have been reported to share some of the features of Stickler syndrome. Wagner<sup>43</sup> reported a large Swiss family with an autosomal dominant vitreoretinal disorder resembling Stickler syndrome but without retinal detachment. Analysis of the original Wagner pedigree has shown linkage to 5q13–q14,<sup>44</sup> confirming that it is genetically distinct from Stickler syndrome. The original Weissenbacher-Zweymuller syndrome patient<sup>45</sup> was found to be heterozygous for a mutation in *COL11A2*.<sup>46</sup> Although, in cartilage, the  $\alpha 2(XI)$  collagen forms heterotrimers with  $\alpha 1(XI)$  collagen, it is not expressed in the eye and thus there are no associated eye changes. The term non-ocular Stickler syndrome (McKusick no. 184840) encompassing *COL11A2* disorders has been suggested.

There is continuing debate over the clinical overlap and differential diagnosis of Stickler and Marshall syndromes.<sup>29 47–49</sup> Marshall<sup>36</sup> described seven members in a three generation pedigree who were affected with a hereditary “ectodermal dysplasia” with ocular abnormalities and hearing defect. The pedigree showed autosomal dominant inheritance, normal stature but diminished sweating, and abnormal teeth. Hair and nails were normal. All patients

were myopic (moderate to high) with fluid vitreous, although the vitreous phenotype was not described in detail. Several affected individuals had congenital or juvenile cataract which underwent sudden maturation, some with lens subluxation and secondary glaucoma. At the age of 43, one patient suffered a retinal detachment, 9 months following traumatic lens dislocation. Otherwise, there were no localised retinal lesions. In contrast to the series of patients described here, all the patients reported by Marshall had a short, depressed nose and an underdeveloped maxilla. *x* Rays showed a thickening of the outer table of the skull and absent frontal sinus in two siblings. Midline clefting and arthropathy were not reported although one patient had mild postural scoliosis. Shanske *et al*<sup>50</sup> argue that photographs published in Marshall’s original paper also show that several of the patients have striking ocular hypertelorism, and confirm that Marshall syndrome is a rare condition, with only eight additional reports since 1958. In two of these reports cited by Shanske *et al*, the authors did not consider their patients to have Marshall syndrome.<sup>51 52</sup> The distinction between the Stickler and Marshall syndromes is complicated by further reports describing Marshall syndrome but with features that were



**Figure 4** Facial phenotype: (A) MS71 I:1; (B) MS71 II:2; (C) MS1 II:6; (D) MS1 III:2.



**Figure 5** Joint hypermobility: (A) MS71 I:1, (B) MS67 I:1.

not described in the original Marshall kindred, and yet are known features in cases of Stickler syndrome confirmed by molecular genetic analysis. Annunen *et al*<sup>29</sup> described a series of patients with mutations in *COL11A1* and *COL2A1* and found similar clinical findings in patients with mutations in either gene. The notable differences were that those with *COL11A1* mutations more commonly had severe hearing impairment and seldom had vitreoretinal degeneration or retinal detachment. Those with *COL11A1* mutations were classified as having Marshall syndrome or an overlapping Marshall–Stickler syndrome, whilst those with *COL2A1* mutations were considered to have Stickler syndrome. The controversy will continue until the molecular genetic basis of the original Marshall pedigree is resolved.

In the continuing search for a clinical distinction between Stickler syndrome and Marshall syndrome, concentration on subtle facial differences may detract from recognising the serious risk of retinal detachment. This study demonstrates the importance of the vitreous phenotype in the diagnosis of Stickler syndrome, even in those individuals who appear clinically normal in other aspects of the disorder. Recognising the risk to the individual and to members of the family allows appropriate steps to be taken to educate, offer genetic counselling, consider prophylaxis, and offer prompt remedial treatment.

## ACKNOWLEDGEMENTS

The authors gratefully acknowledge the help of the Stickler Syndrome Support Group, Gillian Whitmore and Katherine Haslam.

## Authors' affiliations

**A V Poulson, R Murthy, J D Scott, M P Snead**, Vitreoretinal Service, Addenbrooke's NHS Trust, Cambridge, UK  
**J M M Hooymans**, Department of Ophthalmology, University Hospital of Groningen, Groningen, Netherlands  
**A J Richards**, Department of Pathology, University of Cambridge, Cambridge, UK  
**P Bearcroft**, Department of Radiology, Addenbrooke's NHS Trust, Cambridge, UK  
**D M Baguley**, Department of Audiology, Addenbrooke's NHS Trust, Cambridge, UK

This research is funded by grants from The Guide Dogs for the Blind Association, The Isaac Newton Trust, The Stanley Thomas Johnson Foundation, Action Medical Research and The University of Cambridge Retinal Research Fund.

Conflict of interest: none declared.

Correspondence to: M P Snead, Vitreoretinal Service, Box 41, Addenbrooke's NHS Trust, Hills Road, Cambridge, CB2 2QQ, UK; mps34@cam.ac.uk

Revised version received 29 February 2004  
 Accepted for publication 1 March 2004

## REFERENCES

- 1 **Stickler GB**, Belau PG, Farrell FG, Jones J, Pugh DG, Steinberg AG, Ward LE. Hereditary progressive arthro-ophthalmopathy. *Mayo Clin Proc* 1965;**40**:433–55.
- 2 **Stickler GB**, Pugh DG. Hereditary progressive arthro-ophthalmopathy II. Additional observations on vertebral abnormalities, a hearing defect, and a report of a similar case. *Mayo Clin Proc* 1967;**42**:495–500.
- 3 **Hall JG**, Herrod H. The Stickler syndrome presenting as a dominantly inherited cleft palate and blindness. *J Med Genet* 1975;**12**:397–400.
- 4 **Herrmann J**, France TD, Spranger JW, Opitz JM, Wiffler C. The Stickler syndrome (hereditary arthroophthalmopathy). *Birth Defects Orig Artic Ser* 1975;**11**:76–103.
- 5 **Opitz JM**, France T, Herrmann J, Spranger JW. The Stickler syndrome. *N Engl J Med* 1972;**286**:546–7.
- 6 **Schreiner RL**, McAlister WH, Marshall RE, Shearer WT. Stickler syndrome in a pedigree of Pierre Robin syndrome. *Am J Dis Child* 1973;**126**:86–90.
- 7 **Snead MP**. Hereditary vitreopathy. *Eye* 1996;**10**(Pt 6):653–63.
- 8 **Stickler GB**, Hughes W, Houchin P. Clinical features of hereditary progressive arthro-ophthalmopathy (Stickler syndrome): a survey. *Genet Med* 2001;**3**:192–6.
- 9 **Snead MP**, Yates JR. Clinical and molecular genetics of Stickler syndrome. *J Med Genet* 1999;**36**:353–9.
- 10 **Scott JD**. Congenital myopia and retinal detachment. *Trans Ophthalmol Soc UK* 1980;**100**:69–71.
- 11 **Snead MP**, Payne SJ, Barton DE, Yates JR, al Imara L, Pope FM, Scott JD. Stickler syndrome: correlation between vitreoretinal phenotypes and linkage to COL2A1. *Eye* 1994;**8**(Pt 6):609–14.
- 12 **Francomano CA**, Liberfarb RM, Hirose T, Maumenee IH, Streeten EA, Meyers DA, Pyeritz RE. The Stickler syndrome: evidence for close linkage to the structural gene for type II collagen. *Genomics* 1987;**1**:293–6.
- 13 **Francomano CA**, Liberfarb RM, Hirose T, Maumenee IH, Streeten EA, Meyers DA, Pyeritz RE. The Stickler syndrome is closely linked to COL2A1, the structural gene for type II collagen. *Pathol Immunopathol Res* 1988;**7**:104–6.
- 14 **Ahmad NN**, Ala-Kokko L, Knowlton RG, Jimenez SA, Weaver EJ, Maguire JL, Tasman W, Prockop DJ. Stop codon in the procollagen II gene (COL2A1) in a family with the Stickler syndrome (arthro-ophthalmopathy). *Proc Natl Acad Sci U S A* 1991;**88**:6624–7.
- 15 **Ahmad NN**, McDonald-McGinn DM, Zackai EH, Knowlton RG, LaRossa D, Dimascio J, Prockop DJ. A second mutation in the type II procollagen gene (COL2A1) causing Stickler syndrome (arthro-ophthalmopathy) is also a premature termination codon. *Am J Hum Genet* 1993;**52**:39–45.
- 16 **Ahmad NN**, Dimascio J, Knowlton RG, Tasman WS. Stickler syndrome. A mutation in the non-helical 3' end of type II procollagen gene. *Arch Ophthalmol* 1995;**113**:1454–7.
- 17 **Brown DM**, Nichols BE, Weingeist TA, Sheffield VC, Kimura AE, Stone EM. Procollagen II gene mutation in Stickler syndrome. *Arch Ophthalmol* 1992;**110**:1589–93.
- 18 **Brown DM**, Vandenberg K, Kimura AE, Weingeist TA, Sheffield VC, Stone EM. Novel frameshift mutations in the procollagen 2 gene (COL2A1) associated with Stickler syndrome (hereditary arthro-ophthalmopathy). *Hum Mol Genet* 1995;**4**:141–2.
- 19 **Richards AJ**, Martin S, Yates JR, Scott JD, Baguley DM, Pope FM, Snead MP. COL2A1 exon 2 mutations: relevance to the Stickler and Wagner syndromes. *Br J Ophthalmol* 2000;**84**:364–71.
- 20 **Ritvanieni P**, Hyland J, Ignatius J, Kivirikko KI, Prockop DJ, Ala-Kokko L. A fourth example suggests that premature termination codons in the COL2A1 gene are a common cause of the Stickler syndrome: analysis of the COL2A1 gene by denaturing gradient gel electrophoresis. *Genomics* 1993;**17**:218–21.
- 21 **Williams CJ**, Ganguly A, Considine E, McCarron S, Prockop DJ, Walsh-Vockley C, Michels VV. A-2→G transition at the 3' acceptor splice site of IVS17 characterizes the COL2A1 gene mutation in the original Stickler syndrome kindred. *Am J Med Genet* 1996;**63**:461–7.
- 22 **Richards AJ**, Baguley DM, Yates JR, Lane C, Nicol M, Harper PS, Scott JD, Snead MP. Variation in the vitreous phenotype of Stickler syndrome can be caused by different amino acid substitutions in the X position of the type II collagen Gly-X-Y triple helix. *Am J Hum Genet* 2000;**67**:1083–94.
- 23 **Richards AJ**, Scott JD, Snead MP. Molecular genetics of rhegmatogenous retinal detachment. *Eye* 2002;**16**:388–92.
- 24 **Van der Hout AH**, Verlind E, Scheffer H, Hooymans JMM. A new family with a mutation in exon 2 of COL2A1 and Stickler syndrome without systemic manifestations (abstract). *Am J Hum Genet* 2001;**69**.
- 25 **Donoso LA**, Edwards AO, Frost AT, Ritter R, Ahmad NN, Vrabec T, Rogers J, Meyer D. Identification of a stop codon mutation in exon 2 of the collagen 2A1 gene in a large Stickler syndrome family. *Am J Ophthalmol* 2002;**134**:720–7.
- 26 **Parma ES**, Korkko J, Hagler WS, Ala-Kokko L. Radial perivascular retinal degeneration: a key to the clinical diagnosis of an ocular variant of Stickler syndrome with minimal or no systemic manifestations. *Am J Ophthalmol* 2002;**134**:728–34.
- 27 **Snead MP**, Yates JR, Williams R, Payne SJ, Pope FM, Scott JD. Stickler syndrome type 2 and linkage to the COL11A1 gene. *Ann N Y Acad Sci* 1996;**785**:331–2.
- 28 **Richards AJ**, Yates JR, Williams R, Payne SJ, Pope FM, Scott JD, Snead MP. A family with Stickler syndrome type 2 has a mutation in the COL11A1 gene resulting in the substitution of glycine 97 by valine in alpha 1 (XII) collagen. *Hum Mol Genet* 1996;**5**:1339–43.
- 29 **Annunen S**, Korkko J, Czarny M, Warman ML, Brunner HG, Kaariainen H, Mulliken JB, Tranebjærg L, Brooks DG, Cox GF, Cruysberg JR, Curtis MA, Davenport SL, Friedrich CA, Kaitila I, Krawczynski MR, Latos-Bielenska A, Mukai S, Olsen BR, Shinno N, Somer M, Vikkula M, Zlotogora J, Prockop DJ, Ala-Kokko L. Splicing mutations of 54-bp exons in the COL11A1 gene cause Marshall syndrome, but other mutations cause overlapping Marshall/Stickler phenotypes. *Am J Hum Genet* 1999;**65**:974–83.
- 30 **Martin S**, Richards AJ, Yates JR, Scott JD, Pope FM, Snead MP. Stickler syndrome: further mutations in COL11A1 and evidence for additional locus heterogeneity. *Eur J Hum Genet* 1999;**7**:807–14.
- 31 **Hall JG**, Froster-Iskenius UG, Allanson JE. *Handbook of normal physical measurements*. New York: Oxford University Press, 1989.
- 32 **Beighton P**. *McKusick's heritable disorders of connective tissue*, 5th ed. St Louis: Mosby, 1993.
- 33 **British Society of Audiology**. Recommended procedures for pure-tone audiometry using a manually operated instrument. *Br J Audiol* 1981;**15**:213–6.
- 34 **Seery CM**, Pruett RC, Liberfarb RM, Cohen BZ. Distinctive cataract in the Stickler syndrome. *Am J Ophthalmol* 1990;**110**:143–8.
- 35 **Scott JD**. Duke-Elder lecture. Prevention and perspective in retinal detachment. *Eye* 1989;**3**(Pt 5):491–515.
- 36 **Marshall D**. Report of a kindred with ocular abnormalities and hearing defect. *Am J Ophthalmol* 1958;**45**:143–56.
- 37 **Parentin F**, Sangalli A, Mottes M, Perissutti P. Stickler syndrome and vitreoretinal degeneration: correlation between locus mutation and vitreous

- phenotype. Apropos of a case. *Graefe's Arch Clin Exp Ophthalmol* 2001;**239**:316–9.
- 38 **Parentin F**. Reply to McLeod, *et al.*; Vitreous phenotype: genotype correlation in Stickler syndrome. *Graefe's Arch Clin Exp Ophthalmol* 2002;**240**:66.
- 39 **McLeod D**, Black GC, Bishop PN. Vitreous phenotype:genotype correlation in Stickler syndrome. *Graefe's Arch Clin Exp Ophthalmol* 2002;**240**:63–5.
- 40 **Snead MP**, Snead DR, Richards AJ, Harrison JB, Poulson AV, Morris AH, Sheard RM, Scott JD. Clinical, histological and ultrastructural studies of the posterior hyaloid membrane. *Eye* 2002;**16**:447–53.
- 41 **Liberfarb RM**, Goldblatt A. Prevalence of mitral-valve prolapse in the Stickler syndrome. *Am J Med Genet* 1986;**24**:387–92.
- 42 **Ahmad N**, Richards AJ, Murfett HC, Shapiro L, Scott JD, Yates JR, Norton J, Snead MP. Prevalence of mitral valve prolapse in Stickler syndrome. *Am J Med Genet* 2003;**116**:234–7.
- 43 **Wagner H**. Ein bisher unbekanntes Erbleiden des Auges (degeneratio hyaloideo-retinalis hereditaria), beobachtet im Kanton Zurich. *Klin Mbl Augenheilk* 1938;**100**:840–58.
- 44 **Brown DM**, Graemiger RA, Hergersberg M, Schinzel A, Messmer EP, Niemeyer G, Schneeberger SA, Streb LM, Taylor CM, Kimura AE. Genetic linkage of Wagner disease and erosive vitreoretinopathy to chromosome 5q13–14. *Arch Ophthalmol* 1995;**113**:671–5.
- 45 **Weissenbacher G**, Zweymuller E. Coincidental occurrence of Pierre Robin and foetal chondrodysplasia. *Monatsschr Kinderheilkd* 1964;**112**:315–7.
- 46 **Pihlajamaa T**, Prockop DJ, Faber J, Winterpacht A, Zabel B, Giedion A, Wiesbauer P, Spranger J, Ala-Kokko L. Heterozygous glycine substitution in the COL11A2 gene in the original patient with the Weissenbacher-Zweymuller syndrome demonstrates its identity with heterozygous OSMED (nonocular Stickler syndrome). *Am J Med Genet* 1998;**80**:115–20.
- 47 **Griffith AJ**, Sprunger LK, Sirko-Osadsa DA, Tiller GE, Meisler MH, Warman ML. Marshall syndrome associated with a splicing defect at the COL11A1 locus. *Am J Hum Genet* 1998;**62**:816–23.
- 48 **Shanske A**, Bogdanow A, Shprintzen RJ, Marion RW. Marshall syndrome and a defect at the COL11A1 locus. *Am J Hum Genet* 1998;**63**:1558–61.
- 49 **Ayme S**, Preus M. The Marshall and Stickler syndromes: objective rejection of lumping. *J Med Genet* 1984;**21**:34–8.
- 50 **Shanske AL**, Bogdanow A, Shprintzen RJ, Marion RW. The Marshall syndrome: report of a new family and review of the literature. *Am J Med Genet* 1997;**70**:52–7.
- 51 **Keith CG**, Dobbs RH, Shaw DG, Cottrill K. Abnormal facies, myopia, and short stature. *Arch Dis Child* 1972;**47**:787–93.
- 52 **Ruppert ES**, Buerk E, Pfordresher MF. Hereditary hearing loss with saddle-nose and myopia. *Arch Otolaryngol* 1970;**92**:95–8.