

The use of electrophysiological monitoring in the intraoperative management of intracranial aneurysms

Jaime R López, Steven D Chang, Gary K Steinberg

Abstract

Objectives—Somatosensory evoked potentials (SSEPs) and brainstem auditory evoked potentials (BAEPs) have been increasingly utilised during surgery for intracranial aneurysms to identify cerebral ischaemia. Between July 1994 and April 1996, we surgically treated 70 aneurysms in 49 consecutive patients (58 operations) with the aid of intraoperative evoked potential monitoring. This study sought to evaluate the usefulness of SSEP and BAEP monitoring during intracranial aneurysm surgery.

Methods—Mean patient age was 51.9 (range 18–79) years. The sizes of the aneurysms were 3–4 mm (15), 5–9 mm (26), 10–14 mm (11), 15–19 mm (seven), 20–24 mm (six), and >25 mm (five). SSEPs were monitored in 58 procedures (100%) and BAEPs in 15 (26%). The neurological status of the patients was evaluated before and after surgery.

Results—Thirteen of the 58 procedures (22%) monitored with SSEPs had SSEP changes (12 transient, one persistent); 45 (78%) had no SSEP changes. Three of 15 patients (20%) monitored with BAEPs had changes (two transient, one persistent); 12 (80%) had no BAEP changes. Of the 14 patients with transient SSEP or BAEP changes, these changes resolved with adjustment or removal of aneurysm clips (nine), elevating MAP (four), or retractor adjustment (one). Mean time from precipitating event to electrophysiological change was 8.9 minutes (range 3–32), and the mean time for recovery of potentials in patients with transient changes was 20.2 minutes (range 3–60). Clinical outcome was excellent in 39 patients, good in five, and poor in three (two patients died), and was largely related to pretreatment grade.

Conclusions—SSEPs and BAEPs are useful in preventing clinical neurological injury during surgery for intracranial aneurysms and in predicting which patients will have unfavourable outcomes.

(J Neurol Neurosurg Psychiatry 1999;66:189–196)

Keywords: aneurysm, electrophysiology, evoked potentials

tentials (BAEPs) with cortical blood flow.^{1–16} Despite the benefits suggested in these reviews, electrophysiological monitoring has not been routinely used by neurosurgeons during intracranial aneurysm surgery. Many of the previous reviews utilised single modality evoked potential recordings, and, to date, very few reviews have documented larger series results using multimodality intraoperative electrophysiological monitoring. We report our results in 49 consecutive patients with 70 aneurysms who underwent 58 operations with the aid of multimodality intraoperative monitoring.

Methods

PATIENT POPULATION

From September 1994 to April 1996, the senior author (GKS) surgically clipped 70 aneurysms in 49 patients (58 operations) with the aid of evoked potential monitoring. The patients had a mean age of 51.9 years (range 18–79). There were 16 men and 33 women in this review. The patients were graded clinically using the scale of Drake *et al*,^{17,18} both before and after surgery. Grades are defined as excellent (able to work with no neurological handicaps); good (having a neurological deficit but being able to work and live independently); poor (having a severe neurological deficit and dependent on family or nursing for help); or dead. At initial presentation, 40 of the patients were graded excellent and nine were good (table 1).

Twenty two of the patients (45%) presented with one or more clinical haemorrhages, seven patients (14%) presented with visual changes, six patients (12%) presented with severe headaches, three patients (6%) presented with progressive neurological deficits, and 11 patients (22%) had their aneurysms identified as incidental findings during MRI evaluations for other diagnoses. Thirty six of the patients (73%) had one intracranial aneurysm requiring clipping; nine (18%) had two aneurysms; two (4%) had three aneurysms; and two (4%) had five aneurysms. The size of each patient's aneurysm was measured on preoperative angiograms. Fifteen aneurysms (21%) were 3–4 mm; 26 (37%) were 5–9 mm; 11 (16%) were 10–14 mm; seven (10%) were 15–19 mm; six (9%) were 20–24 mm; and five (7%) were greater than 25 mm in maximal diameter.

ELECTROPHYSIOLOGICAL MONITORING

In the majority (52) of cases, preoperative SSEP and/or BAEP testing was performed. No

Department of
Neurology
J R López

Department of
Neurosurgery
S D Chang
G K Steinberg

The Stanford Stroke
Center, Stanford
Medical Center,
Stanford, CA 94305,
USA

J R López
S D Chang
G K Steinberg

Correspondence to:
Dr Jaime R López,
Department of Neurology,
Stanford Medical Center,
300 Pasteur Drive, Stanford,
CA 94305, USA. Telephone
001 650 723 1975; fax 001
650 725 7459; email
ma.jrl@forsythe.stanford.edu

Received 30 December 1998
and in revised form
15 June 1998
Accepted 13 July 1998

Previous reviews have documented the relation of somatosensory evoked potentials (SSEPs) and brainstem auditory evoked po-

Table 1 Clinical results

	E	G	P	D
Before surgery	40	9	0	0
After surgery	39	5	3	2

E=excellent; G=good; P=poor; D=dead.

adverse effects were seen in those patients who underwent preoperative evoked potential testing. In cases where the internal carotid artery (ICA) and/or middle cerebral artery (MCA) vascular territory was at risk, cortical SSEPs in response to contralateral median nerve stimulation at the wrist were performed. Cortical SSEP monitoring of the anterior cerebral artery (ACA) vascular territory was accomplished by stimulating the contralateral posterior tibial nerve at the ankle. Monitoring of the vertebral and basilar artery vascular supply required a combination of median nerve generated cortical SSEPs and BAEPs, which were acquired after bilateral independent stimulation.

A Nicolet Viking Four Electrodiagnostic System (Nicolet Instrument Corporation, Madison, Wisconsin) was used to obtain the evoked potentials. Standard surface EEG electrodes were used and placed, using collodion (except for Erb's point), according to the International 10–20 system. Recording electrode positions included bilateral Erb's point, cervical spine (C7), C3', C4', CZ, and CZ' for SSEP recordings and CZ for BAEP recordings. A frontal (FZ) reference was used for SSEPs, and an ear (A1/A2) was used for BAEPs. For SSEP recordings, bilateral alternating side to side stimulation was performed. Constant current stimulation of 0.2 ms duration was delivered via standard surface bar electrodes with a cathode 3 cm proximal to the anode. Stimulation intensity was sufficient to elicit thumb twitch or a clear Erb's point evoked

potential. Rate of stimulation varied between 3.7 and 4.7 Hz. Electrode impedances were kept below 5000 Ω . Filters were routinely set at 30 Hz and 3000 Hz. Sweep time was at 50 ms (median nerve) and 100 ms (posterior tibial nerve). Two hundred and fifty responses were averaged.

BAEPs were generated by applying transducer induced ear clicks using ear inserts. Click polarity was rarefaction and delivered at a rate between 10.7 and 11.1 Hz. One thousand responses were averaged. Click intensity varied from patient to patient but did not exceed 105 dB. White noise was always applied to the contralateral ear.

For analysis of SSEP recordings, both the latency and amplitude (N19-P24) of the cerebral generated evoked responses were used. Central conduction time (CCT) (N19-N13) was also used whenever a reproducible cervical spine potential was obtained. Critical SSEP changes were defined as an amplitude reduction of the cerebral evoked potential of greater than 50%, latency delay (N19/P24) of greater than 10%, and/or an increase in the CCT of >1.0 ms. For BAEP analysis, the latency and amplitude of all peaks (I-V) were measured. Changes in BAEP which were thought to be significant included a >50% amplitude reduction in waves III or V, and/or an increase in latency of the fifth peak or of the interpeak latency difference (PV-PI) greater than 1 ms.

Temperature effects were taken into consideration for both the SSEP and BAEP. Changes were further classified as permanent if the changes persisted to the end of the procedure and transient if the changes recovered to >50% of the baseline before completion of surgery.

Table 2 Patients with electrophysiological changes and/or new postoperative neurological deficits

Patient age	Aneurysm locations	EP change	Time from event to EP change	Intervention	Time to resolution	Neurological change
34	R superior hypophyseal, 5 mm	60% decrease in SSEP	4 min	Clip repositioned	Complete resolution in 3 minutes	None
47	L P-com, 6 mm	60% decrease in SSEP	5 min	Clip repositioned	Complete resolution in 16 minutes	None
47	R P-com, 15 mm	100% decrease in SSEP	10 min	Clip repositioned	Complete resolution in 14 minutes	None
57	R P-com, 3 mm; R ICA, 10mm; R MCA, 15 mm	55% decrease in left SSEP; 39% decrease in right SSEP	15 min	Increased MAP	Complete resolution in 9 minutes	None
49	L PICA, 10 mm	50% decrease in SSEP	5 min	Temporary clip removed	Complete resolution in 5 minutes	None
38	R P-com, 18 mm; R ICA, 15 mm	50% decrease in SSEP	17 min	Increased MAP	Complete resolution in 26 minutes	None
51	A-com, 35 mm	60% decrease in SSEP bilateral	12 min	Increased MAP	Complete resolution in 12 minutes	None
34	L MCA, 7 mm	70% decrease in SSEP	5 min	Retractor adjusted	Complete resolution in 4 minutes	None
48	Basilar, 10 mm	60% decrease in SSEP	3 min	Clip repositioned	Complete resolution in 3 minutes	None
48	Basilar, 10 mm	100% decrease in SSEP bilateral	3 min	Increased MAP	50% recovery in 52 minutes;	Dead
60	L MCA, 25 mm	60% decrease in SSEP	5 min	Temporary clip removed	Complete resolution in 10 minutes	None
48	A-com, 22 mm	65% decrease in SSEP (right)	8 min	Temporary clip removed	Complete resolution in 18 minutes	None
57	L vertebral, 20 mm	Delayed left BAEP, waves III-V	7 min	Temporary clip removed	Partial recovery in 5 minutes; complete recovery in 60 minutes	None
61	R MCA, 7 mm; 3 R P1 segment aneurysms (2-3 mm)	100% decrease in SSEP	5 min	Clip repositioned	Complete resolution in 59 minutes	Dead
		100% decrease in SSEP	32 min	Clip repositioned	Complete resolution in 16 minutes	
		R BAEP waves delayed	8 min	Increased MAP	Persistent wave V delay (occurred during closure)	
47	Vertebral-basilar junction, 10 mm	50% decrease in SSEP (left)	12 min	Increased MAP	Complete resolution in 30 minutes	None
		50% decrease in BAEP (right)	8 min	Increased MAP	Complete resolution in 16 minutes	

All electrophysiological changes are cortical potentials and correspond to the same side of the brain as the aneurysm in question, except where indicated; SSEP=somatosensory evoked potential; BAEP=brainstem auditory evoked potential; EP=electrophysiological; R=right; L=left; MCA=middle cerebral artery; ICA=internal cerebral artery; P-com=posterior communicating artery; PICA=posterior inferior cerebral artery; A-com=anterior communicating artery.

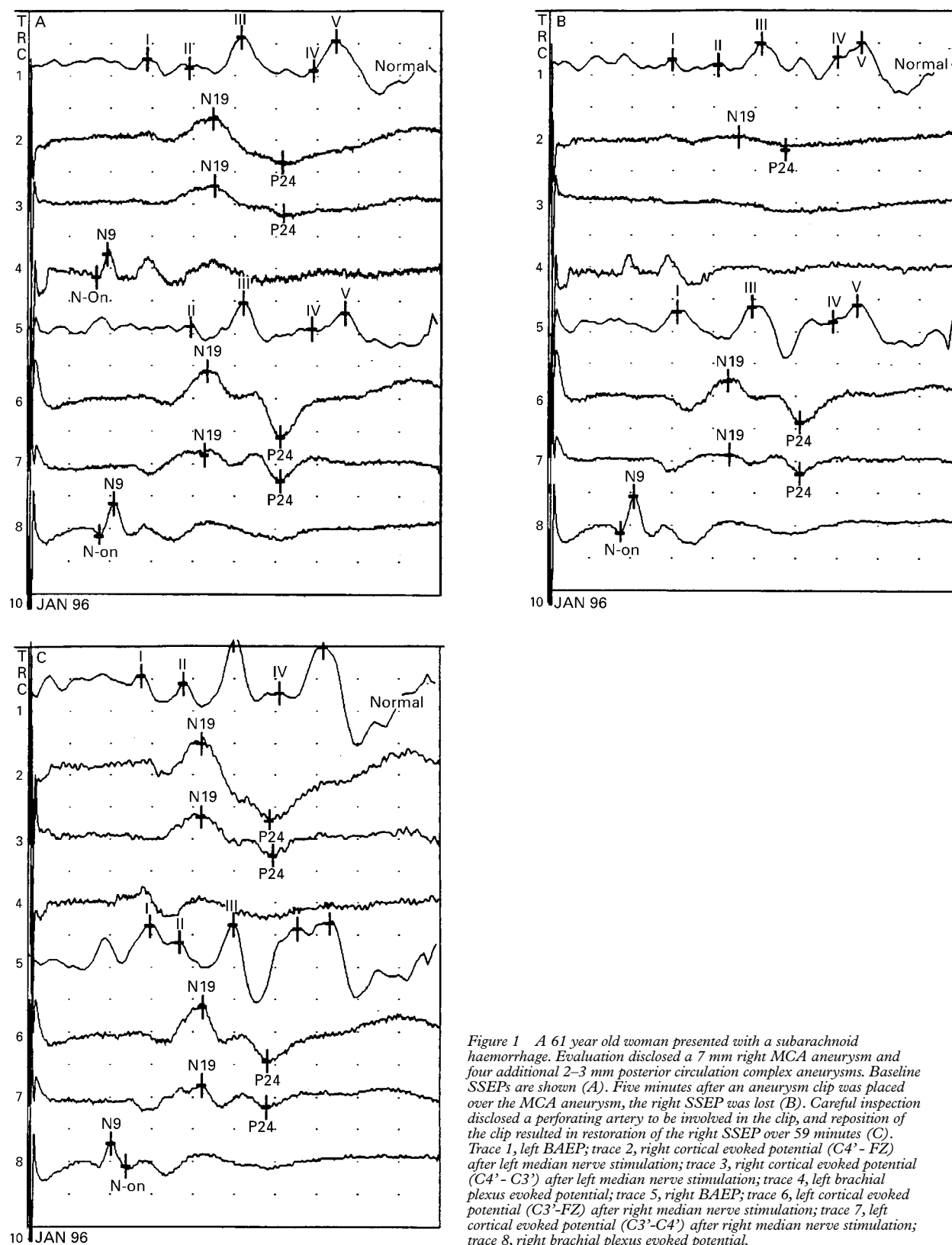


Figure 1 A 61 year old woman presented with a subarachnoid haemorrhage. Evaluation disclosed a 7 mm right MCA aneurysm and four additional 2–3 mm posterior circulation complex aneurysms. Baseline SSEPs are shown (A). Five minutes after an aneurysm clip was placed over the MCA aneurysm, the right SSEP was lost (B). Careful inspection disclosed a perforating artery to be involved in the clip, and reposition of the clip resulted in restoration of the right SSEP over 59 minutes (C). Trace 1, left BAEP; trace 2, right cortical evoked potential (C4' - FZ) after left median nerve stimulation; trace 3, right cortical evoked potential (C4' - C3') after left median nerve stimulation; trace 4, left brachial plexus evoked potential; trace 5, right BAEP; trace 6, left cortical evoked potential (C3' - FZ) after right median nerve stimulation; trace 7, left cortical evoked potential (C3' - C4') after right median nerve stimulation; trace 8, right brachial plexus evoked potential.

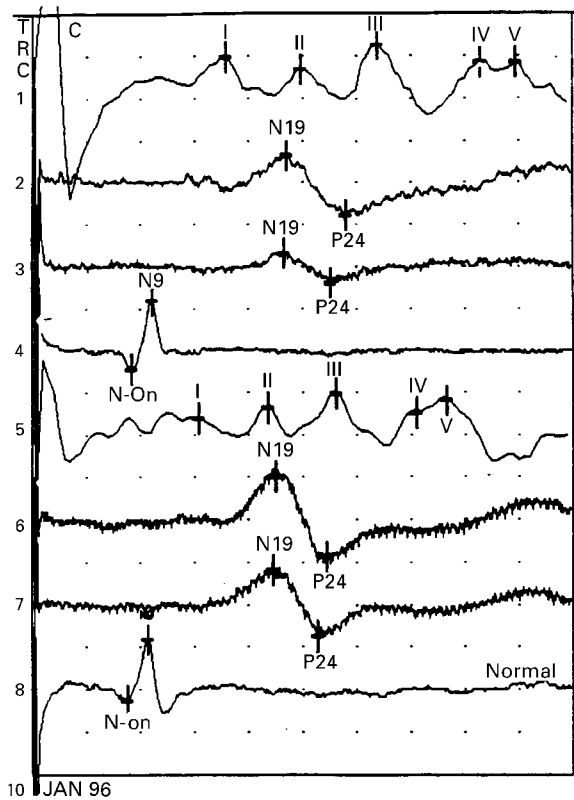
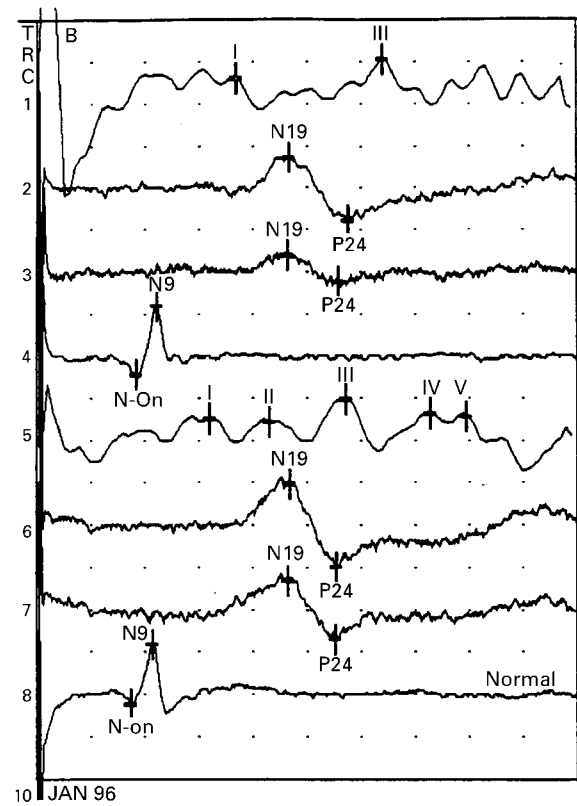
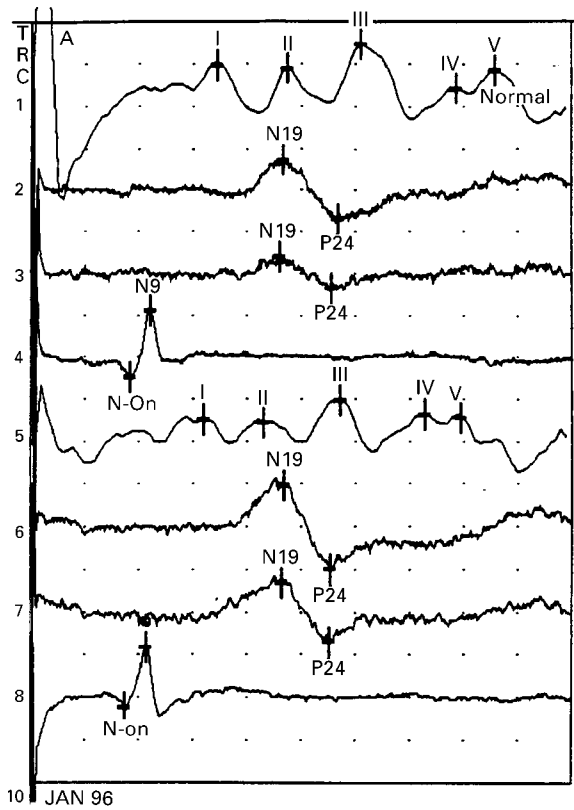


Figure 2 A 57 year old woman presented with a 2 cm left vertebral artery aneurysm after a subarachnoid haemorrhage. (A) Shows baseline SSEPs and BAEPs. (B) Seven minutes after a temporary clip was placed on the vertebral artery, the left BAEP was prolonged and waves IV and V were lost. (C) Removal of the clip resulted in restoration of the left BAEP over 5 minutes. Trace 1, left BAEP; trace 2, right cortical evoked potential (C4'-FZ) after left median nerve stimulation; trace 3, right cortical evoked potential (C4'-C3') after left median nerve stimulation; trace 4, left brachial plexus evoked potential; trace 5, right BAEP; trace 6, left cortical evoked potential (C3'-FZ) after right median nerve stimulation; trace 7, left cortical evoked potential (C3'-C4') after right median nerve stimulation; trace 8, right brachial plexus evoked potential.

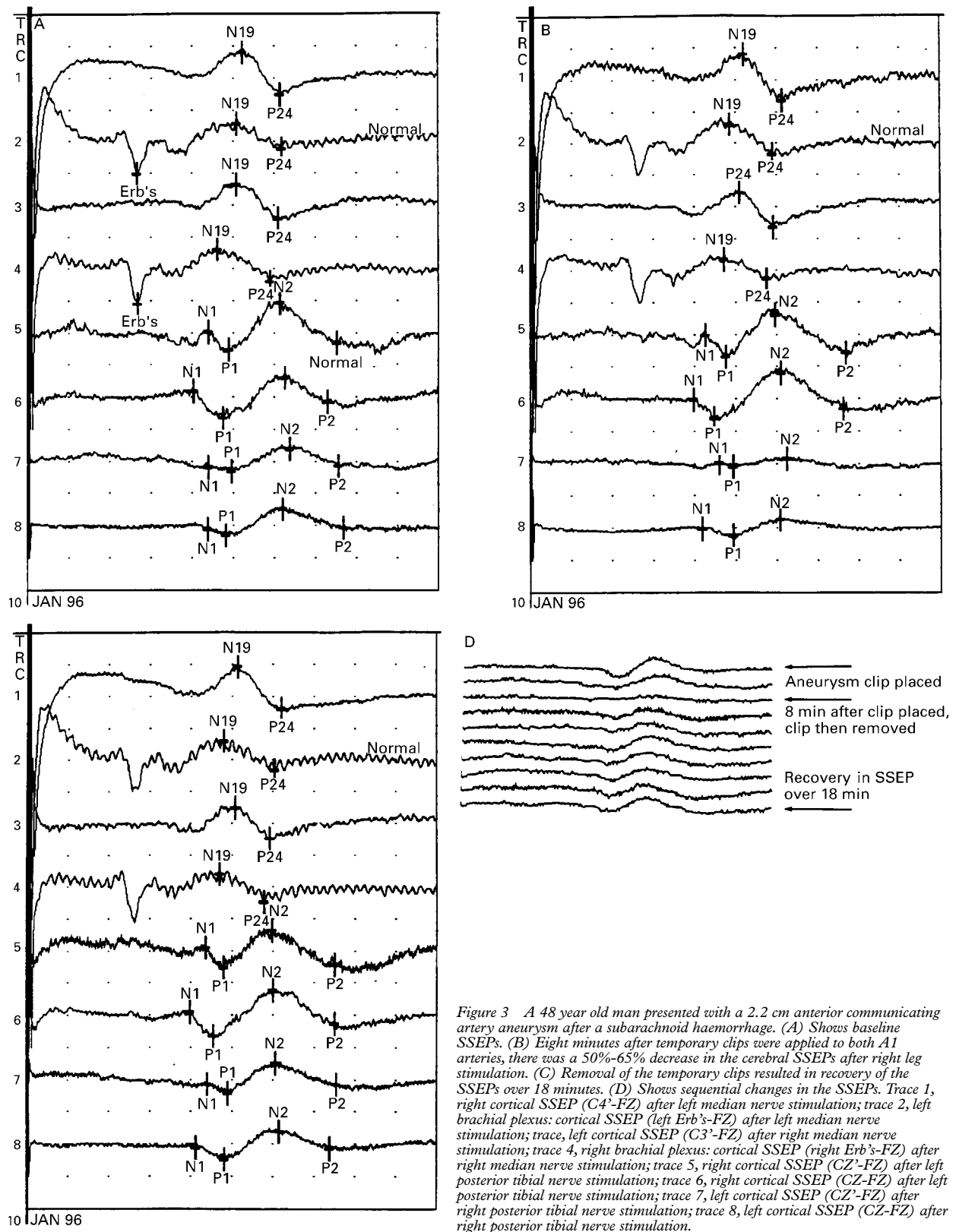


Figure 3 A 48 year old man presented with a 2.2 cm anterior communicating artery aneurysm after a subarachnoid haemorrhage. (A) Shows baseline SSEPs. (B) Eight minutes after temporary clips were applied to both A1 arteries, there was a 50%-65% decrease in the cerebral SSEPs after right leg stimulation. (C) Removal of the temporary clips resulted in recovery of the SSEPs over 18 minutes. (D) Shows sequential changes in the SSEPs. Trace 1, right cortical SSEP (C4'-FZ) after left median nerve stimulation; trace 2, left brachial plexus: cortical SSEP (left Erb's-FZ) after left median nerve stimulation; trace 3, left cortical SSEP (C3'-FZ) after right median nerve stimulation; trace 4, right brachial plexus: cortical SSEP (right Erb's-FZ) after right median nerve stimulation; trace 5, right cortical SSEP (CZ'-FZ) after left posterior tibial nerve stimulation; trace 6, right cortical SSEP (CZ-FZ) after left posterior tibial nerve stimulation; trace 7, left cortical SSEP (CZ'-FZ) after right posterior tibial nerve stimulation; trace 8, left cortical SSEP (CZ-FZ) after right posterior tibial nerve stimulation.

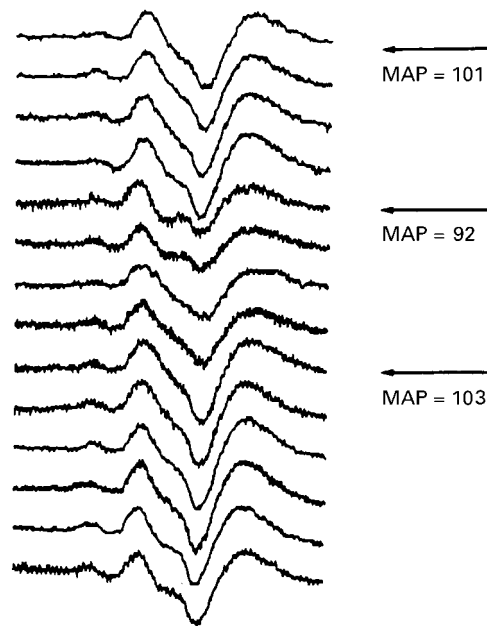


Figure 4 A 51 year old woman presented with a 35 mm anterior communicating artery aneurysm after a subarachnoid haemorrhage. During the procedure, and after temporary clips were placed, the cortical SSEP amplitude decrease by 50% as the MAP decreased to 92. As the MAP was increased back to 103, SSEP tracings returned to baseline over a 12 minute period.

SURGICAL TREATMENT

There were a total of 58 separate operations in the 49 patients. Forty patients had their aneurysms treated with one operation, whereas nine patients required two operations to complete clipping of their aneurysms. Surgical stages were spaced 1 to 4 weeks apart. Intraoperative angiograms were performed in seven cases. All operations were performed under mild hypothermia for cerebral protection,¹⁹ with a mean temperature of 32.6°C and a range of 30.4 to 35.3°C.

Results

ELECTROPHYSIOLOGICAL RESULTS

Thirteen of the 58 procedures (22%) monitored with SSEPs were noted to have electrophysiological changes manifested as a 50% or greater decrease in amplitude (table 2). Forty five (78%) procedures had no SSEP changes. Of the 13 procedures with unilateral SSEP changes, 12 were transient unilateral changes which resolved intraoperatively over an average of 17.2 minutes (range 3 to 59 minutes), whereas one was a persistent SSEP change (table 2). Of the 15 cases monitored with BAEPs, three (20%) showed a significant change in the BAEP ipsilateral to the side of surgery (two transient, one permanent). In the two procedures with transient BAEP changes, these changes resolved in 60 and 16 minutes. Twelve (80%) of the patients monitored with BAEPs showed no significant changes.

For the series in total, transient significant changes were noted in 14 cases (12 cases with SSEP changes and two cases with BAEP changes). The average time from precipitating event to electrophysiological change was 8.9

minutes (range 3–32 minutes). The average time for recovery of potentials in patients with transient electrophysiological changes was 20.2 minutes (range 3–60 minutes).

INTRAOPERATIVE MANAGEMENT

All significant changes in either SSEPs or BAEPs were immediately relayed to the operating surgeon. In the 14 cases of transient electrophysiological changes, the evoked potential deficit resolved with adjustment of clips (nine patients) (figs 1–3), raising the mean arterial pressure (four patients) (fig 4), or adjustment of the retractors (one patient). In the two persistent cases of SSEP and BAEP changes, no precipitating event could be identified, and increases in MAP resulted in no significant improvement in the evoked potential.

CLINICAL RESULTS

Preoperative neurological examinations were performed by a neurologist 24 hours before surgery. Postoperative examinations were performed by the same neurologist within 24 hours of surgery. All patients with transient SSEP changes intraoperatively had no new neurological deficit postoperatively (table 2). The one patient with a persistent SSEP change had a complete loss of bilateral cortical SSEPs after a temporary clip was quickly placed on the basilar artery after rupture of a 2 cm basilar tip aneurysm. The aneurysm was successfully clipped, but both SSEP potentials only returned to 50% of their baseline levels; there were no changes in BAEP. The patient was obtunded postoperatively and expired 2 weeks after surgery. The two patients with transient intraoperative BAEP changes had no new postoperative deficits. The one patient with a persistent intraoperative BAEP change (persistent wave V delay occurring late in the case) emerged slowly from anaesthesia and initially appeared to have no postoperative deficit. However, 2 hours later she required an emergent craniotomy for evacuation of a remote cerebellar haemorrhage with compression of the brainstem. Overall, patient clinical outcome was excellent in 39 patients, good in five, and poor in three. Two patients died during the follow up period (table 1). Clinical outcome was largely related to pretreatment grade.

Discussion

ELECTROPHYSIOLOGICAL MONITORING FOR INTRACRANIAL SURGERY

Electrophysiological monitoring in the form of SSEPs and BAEPs has been used to evaluate cerebral function in intracranial aneurysm and tumour operative procedures,^{1–16} and a well established correlation exists between cerebral ischaemia or injury and decreased electrophysiological function.^{1–3 5 9–16} The vascular distributions of the MCA, ACA, and ICA can be monitored with SSEPs, as the somatosensory cortex and internal capsule are supplied by branches of these vessels. In addition, thalamic subcortical activity, supplied by the posterior cerebral artery (PCA), can also be monitored using median nerve SSEPs.¹⁴ BAEPs are useful in monitoring the posterior circulation, as a

substantial decrease in blood supply to the auditory pathways within the brainstem should result in an electrophysiological change.

The rationale for employing SSEPs and BAEPs is the strong correlation between electrophysiological changes and regional cerebral blood flow (rCBF). Primate studies have shown that SSEPs are maintained at levels of rCBF >16 ml/100 g/min but are absent at levels below 12 ml/100 g/min.²⁰⁻²³ At rCBF levels between 14 and 16 ml/100 g/min there is a sharp reduction in the cortical SSEP amplitude (50%) when compared with baseline.²⁰⁻²³ Ischaemia also prolongs the CCT >10 ms with an rCBF threshold of about 15 ml/100 g/min.^{24 25} As rCBF further decreases, infarctions result. A baboon chronic stroke model disclosed areas of infarction corresponding to rCBF of 10 ml/100 g/min or less after MCA occlusion for 48 hours.^{23 26} A similar primate model, focusing on acute stroke, disclosed that infarction occurred at a rCBF threshold of 12 ml/100g/min maintained for >2 hours.^{27 28} These findings suggest that a 50% reduction in amplitude of the SSEP or a prolonged CCT >10 ms corresponds to an rCBF of 14-16 ml/100 g/min and is indicative of ischaemia and possible progression to infarction.

Studies involving surgery for MCA aneurysms have shown that a CCT >9-10 ms correlated with postoperative neurological deficit, whereas preservation of a CCT with <10 ms delay was associated with good outcome.^{11 29} A high correlation between significant permanent changes in the SSEP during MCA aneurysm surgery and new postoperative deficits has been documented,¹⁵ and the disappearance of the SSEP accurately predicts postoperative deficits.¹ Previous studies have shown that temporary vascular occlusions are relatively safe for about 10 minutes after a gradual loss of the SSEP.⁶ In several series, alterations in the evoked potentials have changed the surgical management including removal of temporary or permanent clips, a decrease in excessive brain retraction, or a decrease in brain manipulation.^{4 13} Bilateral changes in SSEP have also proved useful in the detection of overall hypotension.¹⁵

Posterior circulation monitoring using only SSEPs or BAEPs is thought to be unreliable by several investigators,^{7 12 15} as ischaemia due to basilar perforator occlusion may not affect the auditory or somatosensory pathways in the brainstem.^{15 20} However, recent studies show that dual monitoring with both SSEPs and BAEPs is useful, as their combined use resulted in lower false positive and false negative results.³ Two patients in this series who had posterior circulation aneurysms exhibited changes in SSEPs without changes in BAEPs. Based on this, we think that dual BAEP and SSEP monitoring should be performed for cases of posterior circulation aneurysm.

CHANGES IN INTRAOPERATIVE MANAGEMENT

The intraoperative benefit of electrophysiological monitoring is shown in the 13 patients (26%) who had transient changes in SSEP and the two patients (4%) with transient BAEP

changes. Correlating SSEP or BAEP change with a precipitating event allows a rapid response to prevent neural injury. In nine cases placement of aneurysm clips, either due to parent vessel or perforator occlusion, resulted in significant SSEP or BAEP changes, usually within several minutes. Rapid removal and/or adjustment of clip position resolved the SSEP and BAEP changes in all these cases. In four cases, transient hypotension caused SSEP and BAEP changes (bilateral in two patients), generally with a critical threshold of 55-60 mm Hg. Increases in MAP by the anaesthesia team resolved these changes. Additionally, adjustment of retractors resolved electrophysiological changes in one patient.

Two patients had persistent electrophysiological changes. In the patient with persistent intraoperative SSEP changes (bilateral) they occurred as a result of emergent basilar artery clipping after intraoperative rupture. Bilateral thalamic ischaemia is the likely cause of these changes. The one patient with persistent intraoperative BAEP changes emerged from surgery for a right MCA aneurysm neurologically intact, but expired from a posterior fossa haemorrhage several hours later. This haemorrhage may have occurred during the aneurysm surgery, accounting for the change in BAEP, which was ipsilateral to the posterior fossa haemorrhage.

CLINICAL RESULTS

The clinical results largely paralleled the electrophysiological results. All patients with transient evoked potential changes had these potentials return to baseline levels by the conclusion of the procedure. None of these patients had postoperative deficits. By contrast, both patients with persistent electrophysiological changes had poor neurological outcomes and expired early in the postoperative course. Many of the patients with transient electrophysiological changes, particularly those secondary to clip placement, may have had clinical neurological deficits prevented as a direct result of the early warnings from changes in SSEPs or BAEPs.

OTHER FACTORS AFFECTING EVOKED POTENTIALS

All of the aneurysms clipped in this series were performed under mild hypothermia (mean temperature 32.6°C).¹⁹ This hypothermia usually caused a generalised slowing of conduction time and a decrease in evoked potential amplitude. We have, however, seen several cases of intracranial aneurysm surgery at our institution in which more severe hypothermia (28-29°C) was associated with severe bilateral changes in the evoked potential amplitudes which corrected on rewarming of the patient. Systemic hypotension causes bilateral decreases in evoked potential amplitude and delay of the onset latencies due to secondary hypoperfusion of neural structures. Anaesthesia can also alter evoked potentials through various mechanisms including a direct effect on monitoring modality, effects on cerebral blood flow, and systemic hypotension.³⁰ We have noted significant changes in evoked potentials with higher levels

of inhaled anaesthetics such as isoflurane and desflurane, and barbiturates. For this reason, we employ a strict anaesthesia regimen consisting of a maximum of 0.6% isoflurane and 5% nitrous oxide; doses above 0.6% isoflurane interfere with electrophysiological monitoring. Fentanyl is administered during induction, but during the actual surgery, only very short acting remifentanyl is administered if needed to supplement the inhaled agents. Finally, technical difficulties with equipment, although rare, can occur. In two cases of electrophysiological monitoring during resection of vascular malformation at our institution, technical interference between operating room and evoked potential equipment resulted in non-continuous monitoring, and subsequent bilateral changes in evoked potentials (SSEPs) were noted once monitoring was resumed.

Summary

Electrophysiological monitoring has been shown, in this series, to be a useful intraoperative surgical adjunct during surgery for intracranial aneurysms. Evoked potential changes correlated with clinical outcome, and significant clinical deficits were predicted by electrophysiological changes. Furthermore, posterior circulation aneurysms were optimally monitored with dual SSEP and BAEP recordings in an attempt to minimise false negative results. Based on these findings, we think that rapid response to events precipitating electrophysiological changes may improve patient outcome. In this way, SSEPs and BAEPs become an important intraoperative tool for aneurysm surgery.

We thank JoAnn Ceranski and Rita Sullivan for assistance with patient data collection. This work was supported in part by funding from Bernard and Ronni Lacroute (to GKS) and from the William Randolph Hearst Foundation (to GKS).

- 1 Friedman WA, Kaplan BL, Day AL, *et al.* Evoked potential monitoring during aneurysm operation: observations after fifty cases. *Neurosurgery* 1987;20:678-87.
- 2 Aravabhumi S, Izzo KL, Bakst BL. Brainstem auditory evoked potentials: intraoperative monitoring technique in surgery of posterior fossa tumors. *Arch Phys Med Rehabil* 1987;68:142-6.
- 3 Manninen PH, Patterson S, Lam AM, *et al.* Evoked potential monitoring during posterior fossa aneurysm surgery: a comparison of two modalities. *Can J Anaesth* 1994;41:92-7.
- 4 Djuric S, Milenkovic Z, Klopacic-Spevak M, *et al.* Somatosensory evoked potential monitoring during intracranial surgery. *Acta Neurochir (Wien)* 1992;119:85-90.
- 5 Buchthal A, Belopavlovic M, Mooij JJ. Evoked potential monitoring and temporary clipping in cerebral aneurysm surgery. *Acta Neurochir (Wien)* 1988;93:28-36.
- 6 Mizoi K, Yoshimoto T. Permissible temporary occlusion time in aneurysm surgery as evaluated by evoked potential monitoring. *Neurosurgery* 1993;33:434-40.
- 7 Little JR, Lesser RP, Luders H. Electrophysiological monitoring during basilar aneurysm operation. *Neurosurgery* 1987;20:421-7.
- 8 Wagner W, Peghini-Halbig L, Maurer JC, *et al.* Intraoperative SEP monitoring in neurosurgery around the brain stem and cervical spinal cord: differential recording of subcortical components. *J Neurosurg* 1994;81:213-20.
- 9 McPherson RW, Niedermeyer EF, Otenasek RJ, *et al.* Correlation of transient neurological deficit and somatosensory evoked potentials after intracranial aneurysm surgery. Case report. *J Neurosurg* 1983;59:146-9.
- 10 Symon L, Wang AD, Costa e Silva IE, *et al.* Perioperative use of somatosensory evoked responses in aneurysm surgery. *J Neurosurg* 1984;60:269-75.
- 11 Symon L, Momma F, Murota T. Assessment of reversible cerebral ischaemia in man: intraoperative monitoring of the somatosensory evoked response. *Acta Neurochir Suppl (Wien)* 1988;42:3-7.
- 12 Momma F, Wang AD, Symon L. Effects of temporary arterial occlusion on somatosensory evoked responses in aneurysm surgery. *Surg Neurol* 1987;27:343-52.
- 13 Schramm J, Koht A, Schmidt G, *et al.* Surgical and electrophysiological observations during clipping of 134 aneurysms with evoked potential monitoring. *Neurosurgery* 1990;26:61-70.
- 14 Buchthal A, Belopavlovic M. Somatosensory evoked potentials in cerebral aneurysm surgery. *Eur J Anaesthesiol* 1992;9:493-7.
- 15 Friedman WA, Chadwick GM, Verhoeven FJ, *et al.* Monitoring of somatosensory evoked potentials during surgery for middle cerebral artery aneurysms. *Neurosurgery* 1991;29:83-8.
- 16 Grundy BL, Nelson PB, Lina A, *et al.* Monitoring of cortical somatosensory evoked potentials to determine the safety of sacrificing the anterior cerebral artery. *Neurosurgery* 1982;11:64-7.
- 17 Drake CG. Cerebral arteriovenous malformations: considerations for and experience with surgical treatment in 166 cases. *Clin Neurosurg* 1979;26:145-208.
- 18 Drake CG, Friedman AH, Peerless SJ. Posterior fossa arteriovenous malformations. *J Neurosurg* 1986;64:1-10.
- 19 Steinberg GK, Grant G, Yoon EJ. Deliberate hypothermia. In: Andrews RJ, ed. *Intraoperative neuroprotection*. Baltimore: Williams and Wilkins, 1996:65-84.
- 19 Branston NM, Strong AJ, Symon L. Extracellular potassium activity, evoked potential and tissue blood flow. Relationships during progressive ischaemia in baboon cerebral cortex. *J Neurol Sci* 1977;32:305-21.
- 20 Branston NM, Ladds A, Symon L, *et al.* Comparison of the effects of ischaemia on early components of the somatosensory evoked potential in brainstem, thalamus, and cerebral cortex. *J Cereb Blood Flow Metab* 1984;4:68-81.
- 21 Branston NM, Symon L, Crockard HA, *et al.* Relationship between the cortical evoked potential and local cortical blood flow following acute middle cerebral artery occlusion in the baboon. *Exp Neurol* 1974;45:195-208.
- 22 Symon L. The relationship between CBF, evoked potentials and the clinical features in cerebral ischaemia. *Acta Neurol Scand Suppl* 1980;78:175-90.
- 23 Lesnick JE, Michele JJ, Simeone FA, *et al.* Alteration of somatosensory evoked potentials in response to global ischemia. *J Neurosurg* 1984;60:490-4.
- 24 Hargadine JR, Branston NM, Symon L. Central conduction time in primate brain ischemia: a study in baboons. *Stroke* 1980;11:637-42.
- 25 Symon L, Crockard HA, Dorsch NW, *et al.* Local cerebral blood flow and vascular reactivity in a chronic stable stroke in baboons. *Stroke* 1975;6:482-92.
- 26 Morawetz RB, DeGirolami U, Ojemann RG, *et al.* Cerebral blood flow determined by hydrogen clearance during middle cerebral artery occlusion in unanesthetized monkeys. *Stroke* 1978;9:143-9.
- 27 Jones TH, Morawetz RB, Crowell RM, *et al.* Thresholds of focal cerebral ischemia in awake monkeys. *J Neurosurg* 1981;54:773-82.
- 28 Ducati A, Landi A, Cenzato M, *et al.* Monitoring of brain function by means of evoked potentials in cerebral aneurysm surgery. *Acta Neurochir Suppl (Wien)* 1988;42:8-13.
- 29 Emerson RG, Turner CA. Monitoring during supratentorial surgery. *J Clin Neurophysiol* 1993;10:404-11.
- 30 McPherson RW. General anesthetic considerations in intraoperative monitoring: effects of anesthetic agents and neuromuscular blockade on evoked potentials, EEG, and cerebral blood flow. In: Loftus CM, Traynelis VC, eds. *Intraoperative monitoring techniques in neurosurgery*. New York: McGraw-Hill, 1994:97-106.