

SHORT REPORT

## Levodopa may improve orthostatic tremor: case report and trial of treatment

A J Wills, L Brusa, H C Wang, P Brown, C D Marsden

### Abstract

**Primary orthostatic tremor is a regular fast lower limb tremor causing unsteadiness on standing. Treatment is generally unsatisfactory. A patient with primary orthostatic tremor who 9 years later developed levodopa responsive idiopathic Parkinson's disease is described. The patient exhibited the classic features of primary orthostatic tremor with relief of the tremor by walking or sitting while treated with levodopa. However, in the "off" state, when the benefits of levodopa disappeared, this orthostatic tremor was continuous and severely compromised the patient's gait. On the basis of this finding eight patients with primary orthostatic tremor were treated with levodopa. Five patients experienced benefit and elected to remain on long term treatment. This study is the first trial of therapy in primary orthostatic tremor and suggests that levodopa can lead to good symptomatic relief in this potentially disabling condition.**

*(J Neurol Neurosurg Psychiatry* 1999;66:681-684)

Keywords: orthostatic tremor; idiopathic Parkinson's disease; levodopa

Primary orthostatic tremor was first described by Heilman in 1984.<sup>1</sup> The clinical syndrome consists of unsteadiness on standing accompanied by the electrophysiological finding of a 14-16 Hz tremor, mainly in the legs.<sup>2</sup> Auscultation over the muscles of the thigh and calf may disclose a characteristic thumping sound which is useful diagnostically.<sup>3</sup> There has been debate whether primary orthostatic tremor is a variant of essential tremor or a separate entity.<sup>4,5</sup> The response to standard drug treatment is generally disappointing, although clonazepam is occasionally helpful.<sup>6</sup> Here we report the case of a patient with longstanding primary orthostatic tremor who later developed idiopathic Parkinson's disease. Levodopa ameliorated both his akinetic rigid syndrome and his orthostatic tremor. In the light of this finding we performed a trial of levodopa therapy in eight patients with primary orthostatic tremor, but no other evidence of neurological disease.

### Case report

A 74 year old man presented with a 14 year history of difficulty in standing still. This problem became progressively more severe and he found that he was having to lean on objects while standing to prevent himself falling. He did not describe propulsion or retropulsion. Nine years after the onset of his symptoms he developed micrographia and an insidious upper limb resting tremor that began in the right arm and evolving to affect the left side. He also noticed generalised "slowness", dysarthria, and difficulty turning in bed at night. Four years later he noticed that he was able to walk better at a pace than slowly. He did not report leg cramps. There was no family history of parkinsonism or essential tremor. His medications consisted of 25 mg benserazide and 100 mg levodopa (twice daily) and ranitidine for the treatment of mild oesophagitis. Alcohol had no effect on any of his symptoms.

General examination was normal with no evidence of postural hypotension. Neurological assessment (after overnight withdrawal of levodopa) disclosed facial hypomimia with monotonous speech, a 5 Hz jaw tremor, and a tendency to stammer. The glabellar tap was positive but examination of the rest of the cranial nerves, including eye movements, was normal. He had mild to moderate extrapyramidal rigidity of the limbs with asymmetric bradykinesia, more marked on the right. A fine fast (14.4 Hz) tremor was visible in the upper limbs at rest, and was exacerbated by holding the arms outstretched in front of the body and on standing. There was a similar fast tremor of the legs when standing, manifest as a shuddering of the thighs and patellae. There was no slow parkinsonian rest tremor in the arms or legs. He found it impossible to stand upright without marked swaying. His gait was abnormal with loss of arm swing and a wide base. He found gait initiation extremely difficult and needed assistance to take a few steps. After a dopa challenge (50 mg carbidopa and 200 mg levodopa) he exhibited a marked improvement of rigidity and bradykinesia. The high frequency tremor of the upper limbs disappeared, but he developed an intermittent, slow resting tremor of the right hand and foot. He was able to walk unaided and his gait became narrow based. He still had some difficulty in standing still and was

### National Hospital for Neurology and Neurosurgery

A J Wills  
L Brusa  
P Brown  
C D Marsden

### Human Movement and Balance Disorder Unit

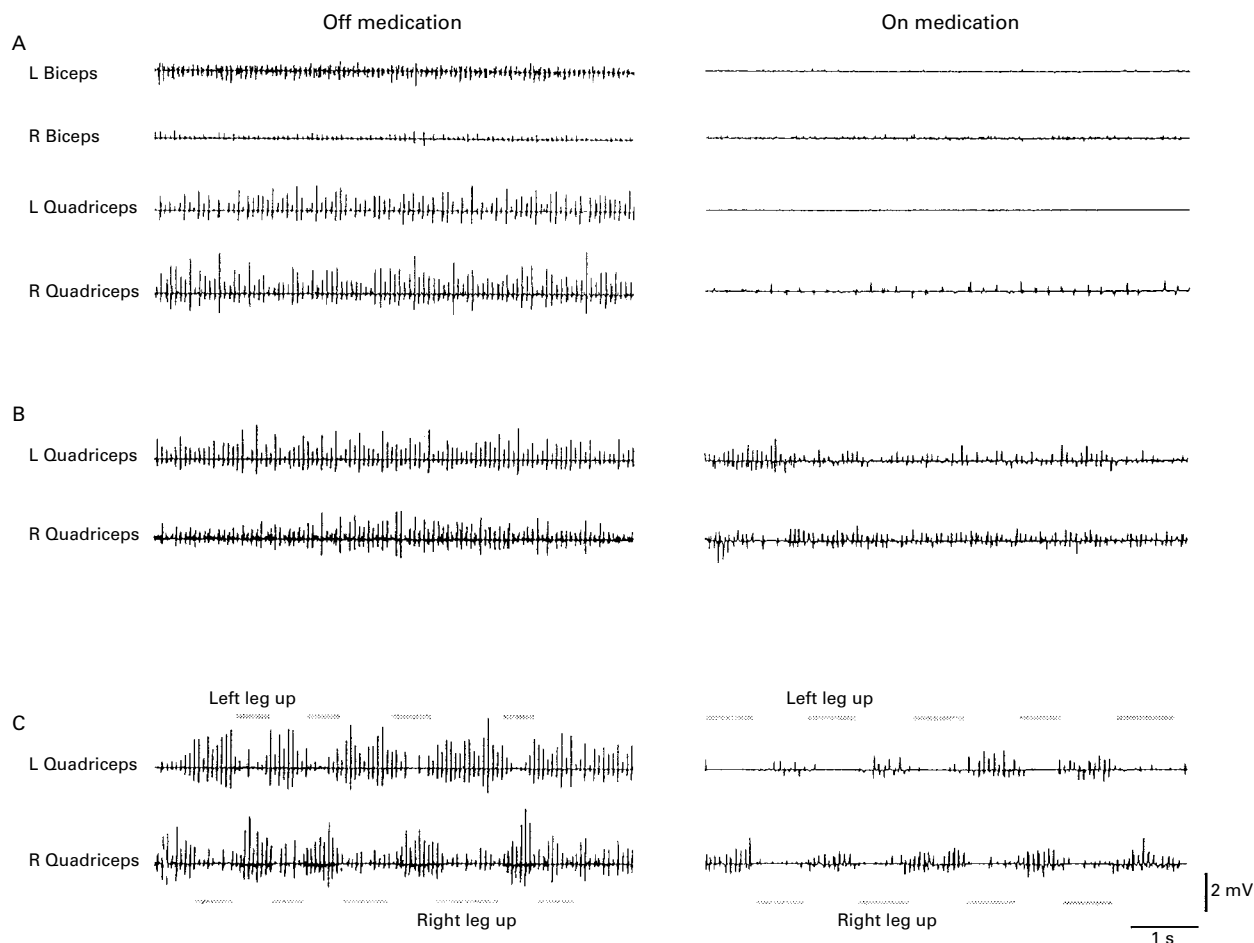
H C Wang  
P Brown  
C D Marsden

### Institute of Neurology, Queen Square, London WC1N 3BG, UK

C D Marsden

Correspondence to:  
Dr A J Wills, National Hospital for Neurology and Neurosurgery, Queen Square, London WC1N 3BG, UK. Telephone 0044 171 837 3611; fax 0044 171 263 1641.

Received 14 May 1998 and in revised form 2 October 1998  
Accepted 20 November 1998



Unrectified EMG recordings in the patient with primary orthostatic tremor and idiopathic Parkinson's disease after overnight withdrawal of medication (left) and after 50 mg carbidopa and 200 mg *d* levodopa (right). It is noteworthy that the electrode sites remained unchanged throughout the recording: (A) seated; (B) standing; (C) walking.

unable to tandem walk slowly but could accomplish this at pace.

Brain MRI was normal. An EEG and routine haematology and biochemistry were normal.

#### EMG RECORDINGS

##### Methods

Surface EMG recordings were made using bipolar silver/silver chloride electrodes placed 2 to 4 cm apart over the muscle bellies. Electrode sites remained unchanged throughout the recording. EMG signals were band pass filtered at 300 Hz, with a time constant of 3 ms. The sampling rate was 640 Hz per channel. Signals were amplified and digitised with 12 bit resolution by a CED 1401-plus analogue to digital converter. They were collected and analysed on a PC by a software package (CED Spikedos). Tremor frequency was estimated by measurement of interburst intervals, and confirmed by Fourier analysis of the digitally rectified EMG signal.

##### Results

The figure shows the EMG findings after overnight withdrawal of antiparkinsonian medication. In the figure A the patient was seated. Off medication, a 14.5 Hz tremor was apparent bilaterally in upper and lower limb muscles. This fast tremor disappeared with levodopa

treatment although a 5 Hz tremor sometimes appeared in the right sided limbs. The figure B illustrates the findings on standing. A 14.5 Hz tremor occurred in the quadriceps, regardless of treatment state. However, the amplitude of this tremor was much greater when off medication, where the peak to peak size of tremor bursts in the quadriceps muscle was up to 2.5 mV. The tremor recorded while walking is shown in the figure C. Off medication, a large amplitude tremor persisted in the quadriceps and was only partially suppressed when each leg was raised in turn. With treatment, the tremor during contact of each leg with the ground was much reduced and almost disappeared as each leg was raised.

#### TRIAL OF LEVODOPA IN ORTHOSTATIC TREMOR

##### Materials and methods

On the basis of this finding we treated eight patients with primary orthostatic tremor (age range 58 to 73; five women, three men) with levodopa. All the patients had prior EMG studies showing the classic 14–16 Hz tremor on standing. The patients were asked to fill in a visual analogue scale describing their overall disability (graded 0–10) and to rate their difficulties in walking to the shops and standing in queues (no difficulty, some difficulty, extreme difficulty and inability; graded 0–3). All

## Results of levodopa challenge in eight patients with primary orthostatic tremor

	Pretreatment total (n=8)	Post-treatment total (n=8)	p Value	Median	95% CI.
Gait	8	6	0.5	1.0 Pre 0.5 Post	0.4–1.6 Pre 0.0–1.5 Post
TQ	12	9	0.5	1.5 Pre 1.0 Post	0.7–2.3 Pre 0.1–1.9 Post
TS	19	16	0.5	2.5 Pre 2.0 Post	1.7–3.0 Pre 1.4–2.6 Post
SFA	14	10	0.12	2.0 Pre 1.0 Post	1.3–2.4 Pre 0.6–1.6 Post
SFT	25	12	0.02	3.0 Pre 1.5 Post	2.2–4.0 Pre 0.7–2.2 Post

TQ=Tandem walking quickly\*; TS=tandem walking slowly\*; SFA=standing feet apart\*; SFT=standing feet together\*; SUM=sum score of above (maximum 20 in each subject); Pre = pre-levodopa therapy; Post=post-levodopa therapy.

\*Graded 0–4 (see methods).

patients were pretreated for 3 days with 10 mg domperidone three times daily. The patients were videotaped performing five tasks including standing upright (feet together (SFT) and apart (SFA), tandem walking (quickly (TQ) and slowly (TS)) and walking normally (GAIT). They were then given a levodopa challenge (250 mg dispersible Madopar) and the video was repeated after 60 minutes. Thereafter they were prescribed 62.5 mg Madopar three times daily increasing to 250 mg three times daily over 8 weeks with domperidone cover.

The pretreatment and post-treatment videos were assessed in a blinded fashion by the same rater and each task graded from 0 to 4 (normal, mild impairment, moderate impairment, severe impairment, and inability). Wilcoxon's matched pairs sum rank test (two tailed p values, 95% confidence intervals (95% CIs)) was used to calculate whether the levodopa challenge had a statistically significant effect on the various tasks.

### Results

The results are shown in the table. As expected, there was no effect on normal gait or tandem walking, but treatment did significantly improve standing upright.

Three patients withdrew from long term treatment because of side effects (nausea in two, insomnia in one). The remaining five patients experienced a marked improvement in their symptoms of unsteadiness and elected to remain on long term therapy. One patient was able to completely discontinue domperidone without loss of therapeutic effect implying that the response of the primary orthostatic tremor to levodopa is centrally mediated. Over an 8 week assessment period there was an average improvement on the 10 point visual analogue scale of three points (pretreatment mean score 5, post-treatment mean score 2). In addition, the patients' rating of their ability to stand in queues improved by a mean of two points (pretreatment mean score 4, post-treatment mean score 2).

### Discussion

The cause of primary orthostatic tremor is unknown. A recent PET study has shown abnormal bilateral cerebellar and contralateral lentiform and thalamic blood flow in patients with primary orthostatic tremor.<sup>7</sup> There are

reciprocal connections between the thalamus and pallidum mediated by a number of neurotransmitters.<sup>8</sup> Whether this pattern of functional abnormality represents a mismatch of neural traffic flowing to the pedunculopontine nucleus resulting in postural instability remains speculative.

We have presented an unusual case exhibiting features consistent with both primary orthostatic tremor and idiopathic Parkinson's disease. His history was suggestive of classic primary orthostatic tremor with the development of idiopathic Parkinson's disease 9 years later. There have been previous case reports of dopa responsive primary orthostatic tremor<sup>9</sup> with associated parkinsonism but the neurophysiological findings in these patients have been atypical with tremors of much lower frequencies (4–5 Hz).<sup>11</sup> It seems likely that these cases represent idiopathic Parkinson's disease with an associated symptomatic parkinsonian leg tremor.

The patient reported here developed a marked worsening of his symptoms of primary orthostatic tremor once idiopathic Parkinson's disease had developed. In addition, these symptoms persisted in atypical situations, such as when walking, and it was this aspect which seemed to be levodopa responsive. Treatment reduced the fast tremor in the legs when walking, although a typical 14.5 Hz tremor persisted on standing, albeit to a lesser degree. In addition, a slow 5 Hz resting tremor did appear after treatment, perhaps suggesting masking by the more rapid tremor when off medication. However, without dopaminergic therapy, the patient exhibited a more or less continuous 14.5 Hz tremor in the arms and legs. Tremor bursts were of large amplitude, so that much of the lower limb musculature was involved in a partially fused contraction which, no doubt contributed to the marked abnormality of gait in the untreated state. The time course of the response of the primary orthostatic tremor to the initial challenge with levodopa was similar to that of the bradykinesia and rigidity implying a common origin.

Our trial of therapy in patients with primary orthostatic tremor without evidence of other neurological disease suggests that levodopa can lead to good symptomatic relief of this potentially disabling condition in some patients. We have not seen the development of tolerance to levodopa so far but we are assessing this aspect and this will be the subject of a future communication. Whether dopamine agonists or even stereotactic thalamotomy might have a role in the management of disabling primary orthostatic tremor also awaits the outcome of further studies.

- 1 Heilman KM. Orthostatic tremor. *Arch Neurol* 1984;41:880–1.
- 2 Thompson PD, Rothwell JC, Day BL, et al. The physiology of orthostatic tremor. *Arch Neurol* 1986;43:584–7.
- 3 Brown P. New clinical sign for orthostatic tremor [letter]. *Lancet* 1995;346:306–7.
- 4 Wee AS, Subramony SH, Currier RD. Orthostatic tremor in familial-essential tremor. *Neurology* 1986;36:1241–5.
- 5 FitzGerald PM, Jankovic J. Orthostatic tremor: an association with essential tremor. *Mov Disord* 1991;6:60–4.

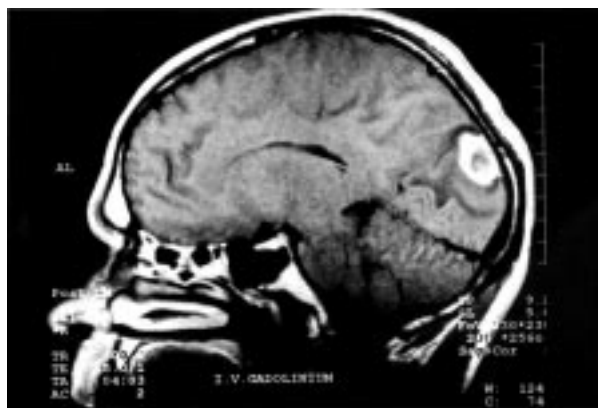
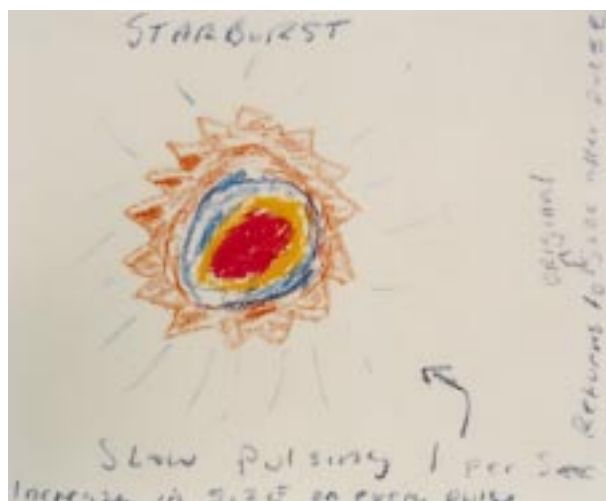
- 6 Poersch M. Orthostatic tremor: combined treatment with primidone and clonazepam [letter]. *Mov Disord* 1994;9:467.
- 7 Wills AJ, Thompson PD, Findley LJ, et al. A positron emission tomography study of primary orthostatic tremor. *Neurology* 1996;46:747-52.
- 8 Marsden CD. Neurotransmitters and CNS disease-basal ganglia disease. *Lancet* 1982;ii:1141-7.
- 9 Cristea RL, Goren H. Orthostatic tremor. *Arch Neurol* 1991;48:1119.
- 10 Oda K, Fukushima N, Kakigi R, et al. A case of orthostatic tremor in parkinsonism. *Rinsho Shinkeigaku* 1989;29:924-6.
- 11 Kim JS, Lee MC. Leg tremor mimicking orthostatic tremor as an initial manifestation of Parkinson's disease [letter]. *Mov Disord* 1993;8:397-8.

---

## NEUROLOGICAL PICTURE

---

### Visual hallucinations and palinopsia due to an occipital lobe tuberculoma



A 35 year old man noted a “starburst” in his right visual field (see his own illustration, figure, left) and a posterior headache. These symptoms resolved but returned intermittently over the next 2 months. He also described the persistence of images of objects seen in his right hemifield. Examination disclosed no abnormality of pupillary responses or of formally performed visual fields. Contrast enhanced MRI (figure, right) disclosed a ring enhancing lesion in the left occipital lobe, which was shown to contain tuberculous granulomata by biopsy. He responded to standard antituberculous therapy, and remains symptom free 2 years later. The coloured visual symptoms, which were probably due to focal cortical irritation from the tuberculoma, may have been mistaken clinically for migraine; however, perseveration of images (*palinopsia*) is highly suggestive of a structural occipitoparietal lesion.

D J WERRING  
 C D MARSDEN  
*Institute of Neurology,  
 The National Hospital for Neurology and Neurosurgery,  
 Queen Square,  
 London WC1N 3BG, UK*

Correspondence to: Dr DJ Werring, NMR Research Unit, Institute of Neurology, The National Hospital for Neurology and Neurosurgery, Queen Square, London WC1N 3BG, UK. Telephone 0044 171 837 3611 extension 4307; fax 0044 171 278 5616; email d.werring@ion.ucl.ac.uk.