

Mutations producing premature termination of translation and an amino acid substitution in the sterol 27-hydroxylase gene cause cerebrotendinous xanthomatosis associated with parkinsonism

First Department of Internal Medicine, School of Medicine, The University of Tokushima, Tokushima, Japan
 N Wakamatsu
 H Kawai
 Y Gotoda
 Y Nishida
 T Matsumoto

Department of Neurology, Kofu City Hospital, Kofu, Japan
 M Hayashi

Department of Neurology, Niigata National Hospital, Kashiwazaki, Japan
 H Kondo
 R Kondo

Department of Neurology, Brain Research Institute, Niigata University, Niigata, Japan
 S Tsuji

Correspondence to:
 Dr Nobuaki Wakamatsu,
 Department of Genetics,
 Institute for Developmental
 Research, Aichi Human
 Service Center, 713-8
 Kamiya, Kasugai, Aichi
 480-0392, Japan. Telephone
 0081 568 88 0811; fax 0081
 568 88 0829; email
 nwake@inst-hsc.pref.aichi.jp

Received 5 November 1998
 and in revised form
 8 February 1999
 Accepted 18 March 1999

Clinical and laboratory manifestations of three patients with CTX with parkinsonism

Patients	Family T		Family S
	CTX-1	CTX-2	CTX-3
Sex	F	F	F
Age (y)	46	43	33
Age at onset (y)	1.5	1.5	9
Consanguinity	+	+	-
Cataracts	++	++	++
Xanthoma	++	++	+
Neurological dysfunctions			
Low intelligence	+++	+++	++
Convulsion	++	++	++
Pyramidal sign	+++	+++	++
Cerebellar sign	+++	+++	++
Peripheral neuropathy	+	-	-
Tremor	++	-	+
Akinesia	++	++	+
Rigidity	+	++	-
Serum cholestanol (µg/ml)*	47.1	11.8	31.4
CSF HVA (ng/ml)†	17.4	13.6	16.5
Brain MRI	Severe brain atrophy, abnormal intensities in the pyramidal tract and midbrain		Cerebellar atrophy

Scoring system: (+++) to (-) = severe to absent; *normal concentration: 2.4±0.7 µg/ml; †normal concentration: 33.2±5.1ng/ml.

Nobuaki Wakamatsu, Masataka Hayashi, Hisaomi Kawai, Hiroshi Kondo, Yasuo Gotoda, Yoshihiko Nishida, Rui Kondo, Shoji Tsuji, Toshio Matsumoto

Abstract

Objectives—Mutational analysis of the sterol 27-hydroxylase (*CYP27*) gene was performed on three patients from two Japanese families who had cerebrotendinous xanthomatosis (CTX) associated with parkinsonism.

Methods—Clinical evaluations, brain MRI studies, and laboratory analyses were completed on the three patients. The *CYP27* gene was analysed for mutations by PCR amplification of gene segments followed by direct sequencing.

Results—Two different, homozygous mutations were identified in these families. One is a novel transition, substituting T for G at Glu162 (GAG) resulting in a stop codon (TAG). The other is also a transition, substituting T for C at Arg441 (CGG) resulting in Trp (TGG). The second is located in two amino acids ahead of the heme ligand binding site (Cys443) of the protein likely rendering it non-functional. It is the most common CTX mutation in Japanese patients.

Conclusions—CTX with parkinsonism is caused by mutations with a severe impact on enzyme function. The two mutations described here are likely to cause loss of function because they are chain terminat-

ing or affect an essential site in the protein.

(J Neurol Neurosurg Psychiatry 1999;67:195-198)

Keywords: cerebrotendinous xanthomatosis; parkinsonism; premature termination codon; missense mutation

Cerebrotendinous xanthomatosis (CTX) is an autosomal recessive lipid storage disease caused by a deficiency of mitochondrial sterol 27-hydroxylase (EC 1.14.13.15) resulting in the accumulation of a bile alcohol and cholestanol in the nervous system, tendons, and vessels.¹ Xanthomas of the Achilles tendons, cataracts, low intelligence, pyramidal signs, and cerebellar signs are the main clinical features.² As long term treatment with chenodeoxycholic acid (CDCA)^{3,4} with or without an inhibitor of hydroxy-methylglutaryl CoA reductase⁵ may prevent the progression of clinical manifestations, early diagnosis is important.

Recent molecular cloning of the human sterol 27-hydroxylase cDNA⁶ and characterisation of the genomic structure of the *CYP27* gene have led to identification of molecular defects in patients and carriers.⁷

We recently examined two unrelated CTX families in which three patients presented with symptoms of parkinsonism as well as more typical clinical features. Two patients in the T family showed more severe clinical findings including parkinsonism than the other patient in the S family. Abnormalities on brain MRI in the T family patients also were more evident than in the other patient. To elucidate the molecular mechanisms for the unusual clinical phenotypes, we determined the molecular mechanisms responsible and analysed genotype-phenotype correlations.

Patients and methods

PATIENTS

T family

Proband (CTX-1) was a 46 year old Japanese female born from consanguineous parents. Her father and her maternal grandfather were first cousins. The proband's 43 year old sister (CTX-2) had identical clinical signs and symptoms. Febrile convulsions appeared at the age of 1.5 years in both sisters. They gradually developed mental retardation, gait disturbance,

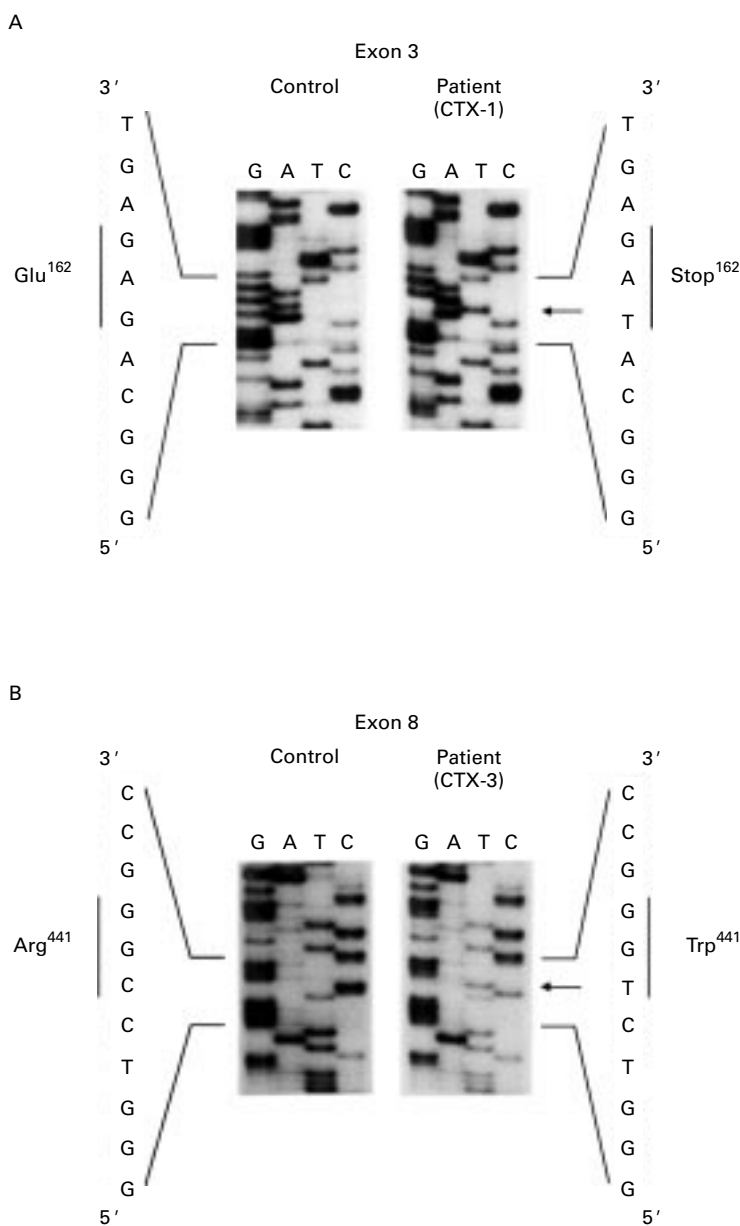


Figure 1 Partial nucleotide sequences of the amplified *CYP27* genomic DNA confirming single base substitution in exon 3 (A) patient CTX-1, and exon 8 (B) patient CTX-3. Arrows indicate the positions of single base substitutions.

cataracts, and swellings of the Achilles tendon. When the patients were first admitted to the hospital, they showed mental disturbance, brisk tendon reflexes, cerebellar ataxia, juvenile cataracts, and Achilles tendon xanthomas. The patient (CTX-1) had an intelligence quotient (IQ) of 28 and showed bilateral 3 Hz to 4 Hz slow wave bursts on EEG. Serum cholestanol concentrations from (CTX-1) and (CTX-2) were raised to 47.1 and 11.8 $\mu\text{g/ml}$, respectively (normal, 2.4 (SD 0.7) $\mu\text{g/ml}$). They were diagnosed with CTX. Within 5 years, they developed parkinsonism with resting tremor, mild muscle rigidity, and hypokinesia as well as the previously evident clinical features and were readmitted to the hospital. T2 weighted MRI in both patients showed severe cerebral cortical and pontocerebellar atrophy, and also high intensity areas in the corona radiata, pos-

terior portion of the internal capsule, cerebral peduncle, and midbrain tegmentum. In CSF, homovanillic acid (HVA) from (CTX-1) and (CTX-2) was decreased to 17.4 and 13.6 ng/ml, respectively (normal, 33.2 (SD 5.1) ng/ml). Oral administration of levodopa (50 mg/day) and diphenylpyraline hydrochloride (10 mg/day) moderately improved the parkinsonism in both cases, whereas mental disturbances, pyramidal signs, and cerebellar ataxia were unimproved (table).

S family

Proband (CTX-3) was a 33 year old Japanese woman born from non-consanguineous parents. She sequentially developed mental retardation, generalised convulsions, cataracts, and spastic gait beginning at the age of 9 years. At age 15 years, an EEG showed spike and wave complexes; seizures came under good control with phenytoin and phenobarbital. When she was admitted to our hospital, cataracts, small tendon xanthomas, mental disturbances, spastic paraparesis, truncal ataxia, hypokinesia, and resting tremor of the right hand were noted. Her IQ was 52. Bilaterally diffuse 2 Hz to 7 Hz slow waves were evident on EEG. Brain MRI showed only mild cerebellar atrophy. Serum cholestanol was raised to 31.4 $\mu\text{g/ml}$, and HVA concentration in the CSF was decreased to 16.5 ng/ml (table). Treatment with CDCA (300 mg/day) resulted in improvement of bradykinesia and EEG abnormalities, an increased CSF HVA concentration (26.7 ng/ml), and decreased serum cholestanol concentration (17.9 $\mu\text{g/ml}$).

MUTATIONAL ANALYSIS OF *CYP27* GENE

Genomic DNA was extracted by standard methods from peripheral blood leucocytes of the three patients with CTX, their family members, and normal controls. The *CYP27* gene of normal subjects and the three patients were amplified separately in four segments: exon 1, exon 2, exons 3 to 5, and exons 6 to 9, using specific primers described by Leitersdorf *et al.*⁷ The polymerase chain reaction (PCR) products were sequenced directly using Δ Tth DNA polymerase with [α -³⁵S]dCTP as a tracer (Toyobo Co Ltd, Osaka, Japan).

RESTRICTION FRAGMENT LENGTH POLYMORPHISM (RFLP) ANALYSIS OF THE FAMILY MEMBERS

The genomic DNA containing exon 3 and a part of intron 3 of the *CYP27* gene from members in the T family and a normal control was amplified using specific primers 5 (sense, 5':tcgactggaccagctgcatgca; antisense, 5':gag-cacaacctctccctgaccatt) to detect creation of an *Eco*T22 I site in the mutant DNA. The genomic DNA containing exon 8 of the *CYP27* gene from members in the S family and a normal control was amplified with specific primers (sense, 5':accagttgtgtctgccaat; antisense, 5':aatcctggggcccaggcatggcc) to detect creation of an *Msc* I site in the mutant DNA. Amplification was carried out for 30 cycles. Each cycle consisted of denaturation for 30 seconds at 94°C, annealing for 30 seconds at 56°C, and extension for 1 minute at 72°C. The PCR

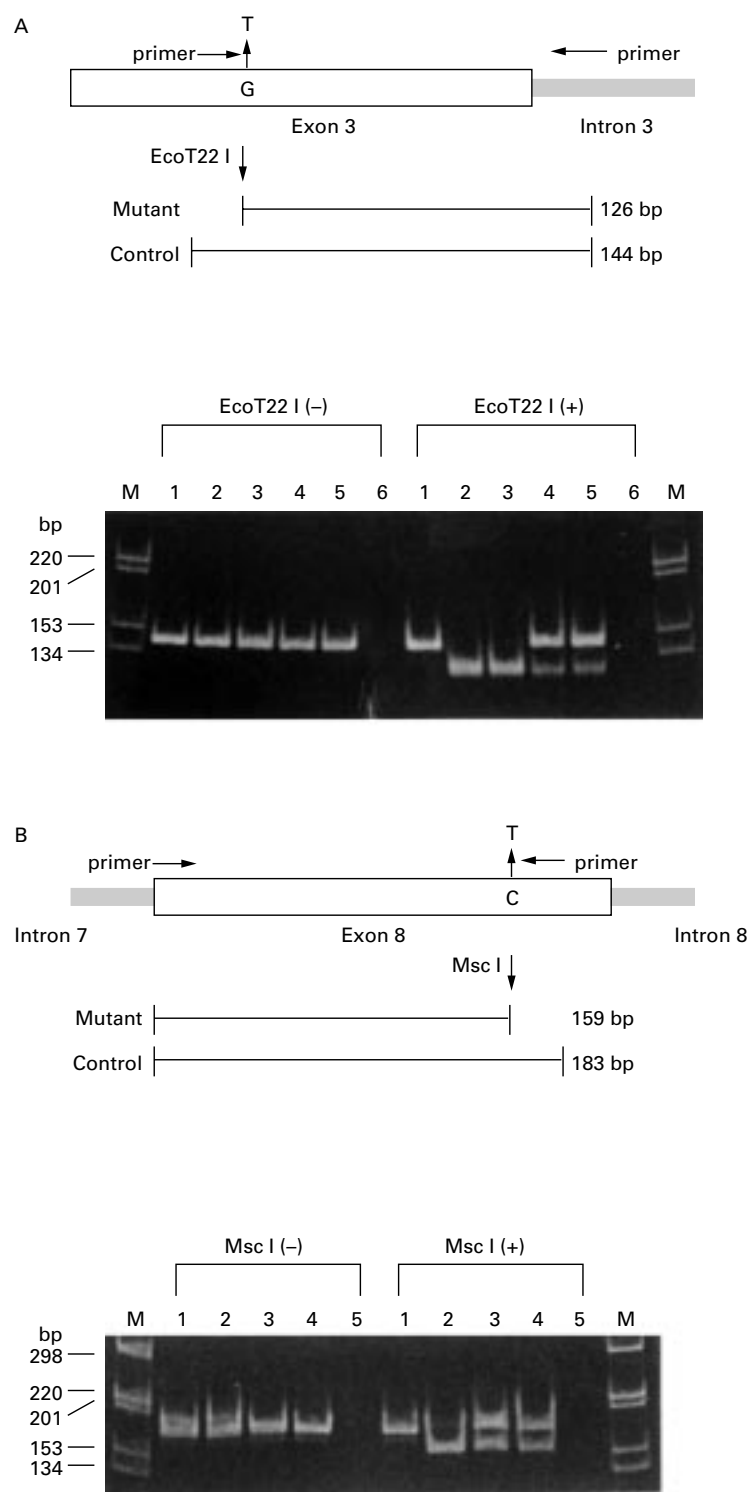


Figure 2 Screening for base transitions. (A) G→T transition in exon 3. The genomic DNA of the members in the T family as well as a normal control were amplified using the specific primers located in exon 3 and intron 3. The diagram indicates the position of the *EcoT22 I* site and the size of fragments produced after *EcoT22 I* digestion of the PCR product of normal control and patient DNA. The *EcoT22 I*-digested PCR products (+) as well as undigested PCR products (-) were run through 8% polyacrylamide gels. Lane 1 is the PCR product from a normal control; lane 2, from patient CTX-1; lane 3, from patient CTX-2; lane 4, from the patients' mother; and lane 5, from the patients' brother. Lane 6 is a water blank. The sizes of the fragments are indicated on the left. (B) C→T transition in exon 8. The genomic DNA of members in the S family as well as a normal control were amplified using the specific primers located in exon 8. The *Msc I* digested PCR products (+) as well as undigested PCR products (-) were run through 8% polyacrylamide gels. Lane 1 is the PCR product from a normal control; lane 2, from patient CTX-3; lane 3, from the patient's father; and lane 4, from the patient's mother. Lane 5 is a water blank.

products were digested with *EcoT22 I* or *Msc I*, electrophoresed on 8% polyacrylamide gels, and stained with ethidium bromide.

Results

IDENTIFICATION OF MUTATIONS IN THE *CYP27* GENE

The nucleotide sequences of all exons, splice junctions, and parts of introns of the *CYP27* gene was determined by direct sequencing of PCR products for the two patients, CTX-1 and CTX-3, and a normal control. Patient CTX-1 (T family) was found to have a homozygous substitution of codon 162 that changed glutamate (GAG) to a stop codon (TAG) (fig 1 A). The mutation in patient CTX-3 (S family) was a nucleotide substitution that changes an arginine residue (CGG) to a tryptophan (TGG) at codon 441 (fig 1B).

DETECTION OF THE DISEASE MUTATION BY RFLP

To determine whether the mutations we identified also appeared in patients' family members, we established diagnostic tests for the mutations by examining *EcoT22 I* or *Msc I* digested products after PCR amplification of surrounding sequences. In the T family, *EcoT22 I* digestion of the two patients' genomic DNA disclosed only a 126 bp fragment derived from a mutant allele carrying Glu162Stop, whereas *EcoT22 I* digestion of DNA from the patients' mother and brother disclosed both a 126 bp and a 144 bp fragment. The result suggests that the patients are homozygous for the mutation, which is compatible with the consanguineous marriage of the parents (fig 2 A). In the S family, the patient was confirmed as homozygous and the parents were heterozygous for Arg441Trp (fig 2 B).

Discussion

We report here three Japanese patients with CTX associated with parkinsonism. In CTX, tendon xanthomas, juvenile cataracts, spasticity, cerebellar dysfunction, and mental disturbance are the most common clinical features, whereas parkinsonian features such as resting tremor, rigidity, and hypokinesia are rare.¹ When Kuriyama *et al*² reviewed the clinical and laboratory findings in 136 patients with CTX, parkinsonism was found in only three cases including their own case.⁸ Ten missense mutations,⁹⁻¹⁷ two nonsense mutations,¹⁷⁻¹⁹ four frameshift mutations,^{7 20-22} and five splice junction mutations^{7 23-25} have been described in the *CYP27* gene in patients with CTX. To determine whether our patients manifesting parkinsonism had any of the previously identified mutations, we analysed the *CYP27* gene for mutations by PCR amplification and direct sequencing. The mutation in the S family, Arg⁴⁴¹→Trp (CGG→TGG), occurred at the most common mutation site of the *CYP27* gene seen in Japanese patients with CTX.¹⁵ As this codon is located in two amino acids ahead of the heme ligand binding site (Cys443), the patient with CTX caused by the previously described homozygous Arg441Trp mutation had drastically reduced enzyme activity (2% of control).¹⁵ The other mutation, in the T family,

represents a newly identified nonsense mutation, Glu¹⁶²→stop (GAG→TAG), in exon 3; a protein carrying this mutation most likely is non-functional. These results are compatible with the finding of more severe clinical features, and more advanced brain MRI findings, in the T family, than in the S family. Thus, a truly functionally null genotype may be associated with the more severe phenotype in the T family, and the 2% activity associated with Arg441Trp in the S family may give some minimal amelioration of phenotype. However, the findings that the patients with CTX carrying a functionally null genotype^{7, 18, 19} did not present parkinsonism suggest that parkinsonism is not related to the severity of the disease in patients. This diversity suggests that not only CYP27 gene mutations but also unknown factors, possibly environmental in nature, can influence the clinical features of CTX. Indeed, the patients carrying the homozygous Arg441Trp mutation reportedly show dramatically variable clinical features ranging from those of the severe late infantile form¹⁶ of CTX to a milder adult form^{2, 15} in Japanese patients. In this paper, our patient shows parkinsonism.

Fiorelli *et al*²⁶ reported a patient with CTX showing mild dementia, spastic tetraparesis, and extrapyramidal signs. From the findings of brain MRI, they concluded that parkinsonism may have resulted from disturbances of the globus pallidus and substantia nigra. In our patients, abnormal intensity was also demonstrated by MRI in the pyramidal tract and midbrain. In patients in the T family, disturbance involving the substantia nigra is the most likely reason for their parkinsonism. In patient CTX-3 we did not find any areas of abnormal intensity in the basal ganglia or midbrain by MRI. Yet, the improvement of parkinsonism and rise in a previously decreased CSF HVA concentration on administration of CDCA show her parkinsonism to be a clinical manifestation of CTX rather than a primary form. Thus, MRI is not always able to demonstrate the pathological basis of parkinsonism. Brain PET study may demonstrate the pathological region of patients with CTX presenting with parkinsonism.

We are grateful to Dr Roy A Gravel (Montreal Children's Hospital Research Institute) for helpful discussions of this manuscript. These studies were supported by grants from the Tsubaki Memorial Neuroscience Research Foundation (to NW) and from the Ministry of Health and Welfare of Japan (Research Grant 8A-2 for Nervous and Mental Disorders, to HK).

- 1 Björkhem I, Boberg KM. Inborn errors in bile acid biosynthesis and storage of sterols other than cholesterol. In: Scriver CR, Beaudet AL, Sly WS, *et al*, eds. *The metabolic and molecular bases of inherited disease*. 7th ed. New York: McGraw-Hill, 1995;2073-99.
- 2 Kuriyama M, Fujiyama J, Yoshidome H, *et al*. Cerebrotendinous xanthomatosis: clinical and biochemical evaluation of eight patients and review of the literature. *J Neurol Sci* 1991;102:225-32.
- 3 Berginer VM, Salen G, Shefer S. Long-term treatment of cerebrotendinous xanthomatosis with chenodeoxycholic acid. *N Engl J Med* 1984;311:1649-52.
- 4 Mondelli M, Rossi A, Scarpini C, *et al*. Evoked potentials in cerebrotendinous xanthomatosis and effect induced by chenodeoxycholic acid. *Arch Neurol* 1992;49:469-75.
- 5 Nakamura T, Matsuzawa Y, Takemura K, *et al*. Combined treatment with chenodeoxycholic acid and pravastatin improves plasma cholestanol levels associated with marked regression of tendon xanthomas in cerebrotendinous xanthomatosis. *Metabolism* 1991;40:741-6.
- 6 Cali JJ, Russell DW. Characterization of human sterol 27-hydroxylase. A mitochondrial cytochrome P-450 that catalyzes multiple oxidation reactions in bile acid biosynthesis. *J Biol Chem* 1991;266:7774-8.
- 7 Leitersdorf E, Reshef A, Meiner V, *et al*. Frameshift and splice-junction mutations in the sterol 27-hydroxylase gene cause cerebrotendinous xanthomatosis in Jews of Moroccan origin. *J Clin Invest* 1993;91:2488-96.
- 8 Fujiyama J, Kuriyama M, Yoshidome H, *et al*. Parkinsonism in cerebrotendinous xanthomatosis. *Japanese Journal of Medicine* 1991;30:189-92.
- 9 Cali JJ, Hsieh C-L, Francke U, *et al*. Mutations in the bile acid biosynthetic enzyme sterol 27-hydroxylase underlie cerebrotendinous xanthomatosis. *J Biol Chem* 1991;266:7779-83.
- 10 Reshef A, Meiner V, Berginer VM, *et al*. Molecular genetics of cerebrotendinous xanthomatosis in Jews of North African origin. *J Lipid Res* 1994;35:478-83.
- 11 Nakashima N, Sakai Y, Sakai H, *et al*. A point mutation in the bile acid biosynthetic enzyme sterol 27-hydroxylase in a family with cerebrotendinous xanthomatosis. *J Lipid Res* 1994;35:663-8.
- 12 Okuyama E, Tomita S, Takeuchi H, *et al*. A novel mutation in the cytochrome P450₂₇ (CYP27) gene caused cerebrotendinous xanthomatosis in a Japanese family. *J Lipid Res* 1996;37:631-9.
- 13 Chen W, Kubota S, Nishimura Y, *et al*. Genetic analysis of a Japanese cerebrotendinous xanthomatosis family: identification of a novel mutation in the adrenodoxin binding region of the CYP 27 gene. *Biochim Biophys Acta* 1996;1317:119-26.
- 14 Chen W, Kubota S, Kim K-S, *et al*. Novel homozygous and compound heterozygous mutations of sterol 27-hydroxylase gene (CYP27) cause cerebrotendinous xanthomatosis in three Japanese patients from two unrelated families. *J Lipid Res* 1997;38:870-9.
- 15 Kim K-S, Kubota S, Kuriyama M, *et al*. Identification of new mutations in sterol 27-hydroxylase gene in Japanese patients with cerebrotendinous xanthomatosis (CTX). *J Lipid Res* 1994;35:1031-9.
- 16 Nagai Y, Hirano M, Mori T, *et al*. Japanese triplets with cerebrotendinous xanthomatosis are homozygous for a mutant gene coding for the sterol 27-hydroxylase (Arg441Trp). *Neurology* 1996;46:571-4.
- 17 Watts GF, Mitchell WD, Bending JJ, *et al*. Cerebrotendinous xanthomatosis: a family study of sterol 27-hydroxylase mutations and pharmacotherapy. *Q J Med* 1996;89:55-63.
- 18 Meiner V, Marais DA, Reshef A, *et al*. Premature termination codon at the sterol 27-hydroxylase gene causes cerebrotendinous xanthomatosis in an Afrikaner family. *Hum Mol Genet* 1994;3:193-4.
- 19 Ahmed MS, Afsar S, Hentati A, *et al*. A novel mutation in the sterol 27-hydroxylase gene of a Pakistani family with autosomal recessive cerebrotendinous xanthomatosis. *Neurology* 1997;48:258-60.
- 20 Leitersdorf E, Safadi R, Meiner V, *et al*. Cerebrotendinous xanthomatosis in the Israeli Druze: molecular genetics and phenotypic characteristics. *Am J Hum Genet* 1994;55:907-15.
- 21 Verrips A, Steenbergen Spanjers GC, Luyten JA, *et al*. Two new mutations in the sterol 27-hydroxylase gene in two families lead to cerebrotendinous xanthomatosis. *Hum Genet* 1996;98:735-7.
- 22 Segev H, Reshef A, Clavey V, *et al*. Premature termination codon at the sterol 27-hydroxylase gene causes cerebrotendinous xanthomatosis in a French family. *Hum Genet* 1995;95:238-40.
- 23 Garuti R, Lelli N, Barozzini M, *et al*. Cerebrotendinous xanthomatosis caused by two new mutations of the sterol-27-hydroxylase gene that disrupt mRNA splicing. *J Lipid Res* 1996;37:1459-67.
- 24 Chen W, Kubota S, Seyama Y. Alternative pre-mRNA splicing of the sterol 27-hydroxylase gene (CYP 27) caused by a G to A mutation at the last nucleotide of exon 6 in a patient with cerebrotendinous xanthomatosis (CTX). *J Lipid Res* 1998;39:509-17.
- 25 Chen W, Kubota S, Teramoto T, *et al*. Silent nucleotide substitution in the sterol 27-hydroxylase gene (CYP 27) leads to alternative pre-mRNA splicing by activating a cryptic 5' splice site at the mutant codon in cerebrotendinous xanthomatosis patients. *Biochemistry* 1998;37:4420-8.
- 26 Fiorelli M, Di Piero V, Bastianello S, *et al*. Cerebrotendinous xanthomatosis: clinical and MRI study (a case report). *J Neurol Neurosurg Psychiatry* 1990;53:76-78.