

# Clinical and MRI study of brain stem and cerebellar involvement in Japanese patients with multiple sclerosis

Ichiro Nakashima, Kazuo Fujihara, Naoshi Okita, Sadao Takase, Yasuto Itoyama

## Abstract

**Objectives**—To investigate the clinical and MRI features of brain stem and cerebellar lesions in Japanese patients with multiple sclerosis.

**Methods**—A retrospective study of 66 consecutive Japanese patients with multiple sclerosis (42 women and 24 men) was done by reviewing the medical records and MRI films. Forty nine patients were diagnosed as having clinically definite multiple sclerosis and 17 patients as having clinically probable multiple sclerosis according to Poser's criteria. Prevalence rates of each brain stem and cerebellar manifestation and frequency and distribution of MRI lesions in these patients were studied.

**Results**—Forty three patients (65%) had one or more infratentorial manifestations. Cranial nerves were clinically involved in 28 patients (42%), and most of the lesions were identified by MRI. Among them, manifestations of facial, trigeminal, and abducens nerves were relatively common. Cerebellar ataxia was found in 20 patients (30%). The MRI study showed that the lesions responsible for ataxia in these patients were mainly found in the cerebellar peduncles, but cerebellar hemispheric lesions were detected in only four patients (6.4%).

**Conclusion**—The low frequency (6.4%) of the cerebellar MRI lesions in these patients is in sharp contrast with the figures reported for white patients with multiple sclerosis (50%-90%). Racial and genetic differences may have an influence on the susceptibility of each part of the CNS to demyelination in multiple sclerosis.

(J Neurol Neurosurg Psychiatry 1999;67:153-157)

**Keywords:** multiple sclerosis; magnetic resonance imaging; Japanese; cerebellum

There has been a line of evidence suggesting epidemiological and clinical differences between white and oriental patients with multiple sclerosis. It is well known that the prevalence of multiple sclerosis is much lower in Asian countries than in western countries,<sup>1,2</sup> whereas the optic-spinal form of multiple sclerosis (OS-MS), which is characterised by selective involvement of the optic nerves and spinal cord and by rare involvement of other parts of the CNS, is relatively common in oriental patients with multiple sclerosis.<sup>1</sup> These findings have been well studied in Japan.

Brain stem and cerebellar involvement is common in white patients with multiple sclerosis.<sup>3,4</sup> For example, in a study of 1271 patients by Poser *et al*, 81.6% of their patients were thought to have brain stem or cerebellar symptomatology.<sup>5</sup> In other studies, infratentorial MRI lesions were detected in more than half of white patients with multiple sclerosis.<sup>6-13</sup> By contrast, it has been reported that cerebellar symptoms are less common in Japanese patients with multiple sclerosis.<sup>1,2</sup> However, correlative studies on the clinical features and MRI findings of infratentorial involvement in Japanese patients are lacking. In the present study, we analysed the symptomatology and MRI findings of brain stem and cerebellar lesions in 66 Japanese patients with multiple sclerosis.

## Patients and methods

We retrospectively reviewed the medical records of a total of 66 consecutive Japanese patients with multiple sclerosis (42 women and 24 men) who were admitted to Tohoku University Hospital and its affiliated hospitals from 1988 to 1997. According to the criteria of Poser *et al*,<sup>14</sup> 49 patients had clinically definite multiple sclerosis and 17 patients had clinically probable disease. Neurological manifestations and MRI findings of these patients were analysed.

## MAGNETIC RESONANCE IMAGING

In each case, all of the available MRI films taken since the onset of the illness were examined. More than 90% of the scans were created with 7 mm or 5 mm thick slices either by 0.5 Tesla or 1.5 Tesla scanners and a few were made by 0.5 Tesla scanners with 10 mm thick slices. Two neurologists—one of the authors and a blinded neuroradiologist—evaluated each scan. T2 weighted sequences produce images in which CSF is bright white and multiple sclerosis plaques are well visualised as hyperintense lesions. Any T2 hyperintense areas in the brain stem and cerebellum which appeared on each T2 weighted image with a moderately long repetition time of 2000-3000 ms and an echo time of 60-100 ms, were considered abnormal. Therefore, both acute and chronic multiple sclerosis lesions were included in this study.

We defined the boundaries of the pons, cerebellar peduncles, and cerebellar hemispheres as follows. Lateral margins of the trigeminal nerves were the boundary between the pons and cerebellar hemispheres. The boundary

Department of  
Neurology, Tohoku  
University School of  
Medicine, 1-1  
Seiryomachi,  
Aoba-ku, Sendai,  
Japan  
I Nakashima  
K Fujihara  
Y Itoyama

Department of  
Neurology, Kohnan  
Hospital, 4-20-1  
Nagamachiminami,  
Taihaku-ku, Sendai,  
Japan  
N Okita  
S Takase

Correspondence to:  
Dr Ichiro Nakashima,  
Department of Neurology,  
Tohoku University School of  
Medicine, 1-1 Seiryomachi,  
Aoba-ku, Sendai 980-8574,  
Japan. Telephone 0081 22  
717 7189; fax 0081 22 717  
7192; email ichiro@mail.cc.  
tohoku.ac.jp

Received 12 October 1998  
and in revised form  
25 January 1999  
Accepted 23 February 1999

*Clinical manifestations of 43 patients with multiple sclerosis and brainstem/cerebellar symptoms and signs*

Symptoms	No of cases
Oculomotor nerve palsy	6
Trochlear nerve palsy	4
Trigeminal nerve dysfunction	10
Facial neuralgia	1
Facial hypaesthesia	5
Facial paraesthesia	6
Abducens nerve palsy	10
Facial nerve palsy	14
Alternating hemiparesis	3
Hearing impairment	5
Vertigo	2
Bulbar palsy	5
Internuclear ophthalmoplegia	6
Nystagmus	19
Cerebellar ataxia	20
Limb ataxia	14
Truncal ataxia	12
Ataxic dysarthria	6

between the cerebellar peduncles and cerebellar hemispheres was defined as the line connecting the ventral border of cerebellar cortical folds and the midpoint of the lateral wall of the fourth ventricle.

CORRELATION OF NEUROLOGICAL MANIFESTATIONS AND MRI FINDINGS

We analysed neurological manifestations and their correlation with MRI findings in our patients. The infratentorial MRI lesions of each patient were carefully traced on schematic drawings of axial views of the medulla, lower pons, middle pons, upper pons, and midbrain. Transparencies of the traced lesions (each lesion being shaded at a density of 15%) were overlaid on each section by a computer program to show the relative frequency of the lesions by the degree of shading.

**Results**

CLINICAL FEATURES OF MULTIPLE SCLEROSIS

Among the 66 patients, 43 (65%) had one or more brain stem or cerebellar manifestations (BsCbll-MS). Fourteen patients (21%) had only manifestations of optic neuropathy and myelopathy (OS-MS) and the rest (10 patients) were classified as "other". The age of onset of these 43 BsCbll-MS patients, ranging from 6 to 55 (mean (SD) 25.0 (10.4)), was significantly younger than that of OS-MS patients (34.1 (13.6)) ( $p=0.014$ ). The mean duration of the disease in the BsCbll-MS patients was 4.4 (4.5) years and their mean annual recurrence rate was 0.75. Oligoclonal IgG bands (OB) were positive in 42% of the BsCbll-MS patients and 14% of the OS-MS patients

The details of the manifestations in the 43 BsCbll-MS patients are shown in the table. The most common manifestations were cerebellar ataxia (51%), diplopia (49%), and nystagmus (44%) followed by facial weakness (33%), visual disturbance (29%), facial sensory disturbance (26%), and hearing disturbance (12%).

FREQUENCY AND DISTRIBUTION OF MRI LESIONS

The frequency and distribution of MRI lesions in the brain of the 66 patients with multiple sclerosis were as follows (fig 1): 62% in the cer-

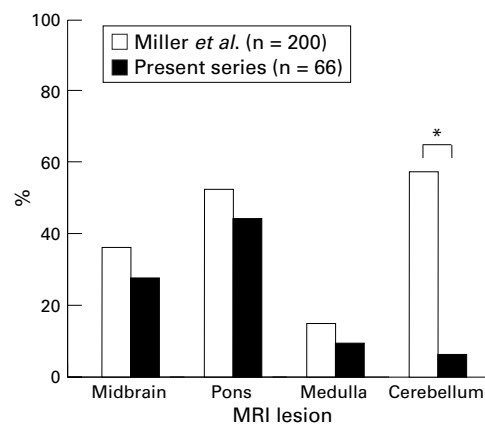


Figure 1 Comparison of frequency of lesions in each brain stem region on MRI between British patients (Miller<sup>2</sup>) (n=200) and Japanese patients with multiple sclerosis (present series) (n=66). The lesions in the cerebellar peduncles were included in the pontine lesions in the present series. Cerebellar hemispheric lesions were much less common in Japanese patients. \* $p<0.0001$ .

ebal white matter, 27% in the midbrain, 46% in the pons, 9% in the medulla, 18% in the middle cerebellar peduncles, and 6% in the cerebellar hemisphere. No lesions were found by brain MRI in nine patients (14%). Compared with the MRI data on British patients with multiple sclerosis reported by Miller *et al*,<sup>12</sup> cerebellar hemispheric lesions were much less common in our patients.

The boundary between the pons and the cerebellum was not clearly shown in the previous reports in white patients with multiple sclerosis,<sup>12</sup> and thus cerebellar peduncular lesions might have been counted as cerebellar lesions in those studies. For this reason, we also analysed the data by including the cerebellar peduncles in the cerebellum. As a result, even if the lesions in the cerebellar peduncles were included in cerebellar lesions, the percentage of cases with cerebellar lesions increased only to 23%, which is still much lower than that of white patients.

Among the 43 BsCbll-MS patients, 27 (63%) had at least one infratentorial MRI lesion and 15 had two or more infratentorial MRI lesions. These lesions varied in size and contour. We traced all the infratentorial MRI lesions of each BsCbll-MS patient (fig 2). Lesions were distributed throughout the brain stem on both sides and no specific regions seemed to be spared, although the intramedullary portions of the trigeminal roots and the cerebral peduncles were the most commonly involved regions (fig 2). In one patient, a T2 hyperintense lesion occupied nearly a half of the middle pontine section. None of the brain stem lesions in these patients were transverse. Among the 27 patients with infratentorial MRI lesions, 23 also had multiple cerebral white matter lesions and seven had spinal lesions on MRI. On the other hand, brain stem MRI lesions were hardly detected in 16 patients with BsCbll-MS.

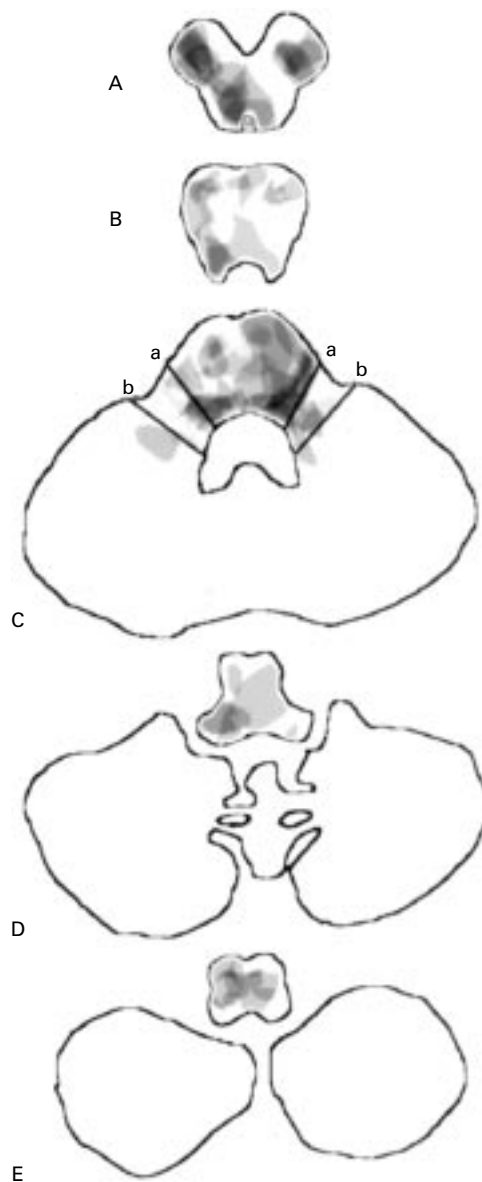


Figure 2 Schematic drawing of infratentorial MRI lesions in the 66 Japanese patients with multiple sclerosis. Transparencies of the traced lesions (each lesion being shaded at a density of 15%) were overlaid on each axial brain stem section (A: midbrain, B: upper pons, C: middle pons, D: lower pons, E: medulla) sliced at a thickness of 10 mm. Solid lines a and b show the boundaries between the pons and the cerebellar peduncles, and between the cerebellar peduncles and the cerebellar hemispheres, respectively. The intramedullary portion of the trigeminal nerve root and the cerebral peduncles were commonly involved. The cerebellum was only rarely involved in the present study.

#### CORRELATION OF NEUROLOGICAL MANIFESTATIONS AND MRI FINDINGS

Neurological manifestations of cranial nerve involvement were seen in about 70% of the patients with BsCbl-MS. The facial, trigeminal, and abducens nerves were commonly involved. In about 60% of the patients with cranial nerve involvement, the responsible brain stem lesions were identified on MRI; these correlations were relatively high in the cases of abducens, trigeminal, and facial nerve involvement. On the other hand, hardly any lesions related to bulbar palsy were detected on MRI.

Cerebellar manifestations were found in 20 patients. Fourteen patients had limb ataxia, 12 had truncal ataxia, and six had slurred and explosive speech. Most of the patients had nystagmus and pontine cranial nerve manifestations. Among these 20 patients, the lesions shown by MRI to be probably responsible were located in the brain stem in 11 patients (in the cerebellar peduncles in seven) and in the cerebellum in three; five patients had no infratentorial lesions on MRI. The patients who had MRI lesions in the cerebellar peduncles or in the cerebellum showed relatively severe ataxia.

#### Discussion

We studied clinical and MRI findings of the brain stem and cerebellar involvement in 66 Japanese patients with multiple sclerosis. As a result, 43 patients (65%) were found to have one or more brain stem or cerebellar manifestations, and cerebellar involvement was seen in 20 patients (30%). Correlative MRI studies showed that the cerebellar manifestations were mainly related to cerebellar peduncular lesions. Cerebellar hemispheric lesions were seen in only 6.4% of the patients. To our knowledge, this is the first precise study on neurological and MRI findings of the brain stem and cerebellar involvement in Japanese patients with multiple sclerosis.

In white patients with multiple sclerosis, cerebellar symptoms and signs are commonly seen (50%-80%).<sup>2, 15-17</sup> On the other hand, a nationwide survey of Japanese patients with the disease showed that only 34% of the patients had cerebellar manifestations.<sup>1</sup> Shibasaki *et al* also showed that the percentage of cerebellar involvement was lower in oriental patients with multiple sclerosis (38%) than in white patients (71%) by their survey in Hawaii.<sup>15</sup> Their additional study also showed that cerebellar involvement was significantly less common in Japanese patients (20%) than in British patients (76%),<sup>16</sup> even though other neurological manifestations related to optic nerve, spinal cord, and brain stem involvement were not different between the two racial groups. Together with our findings, it is strongly suggested that cerebellar involvement is less common in Japanese patients than in white patients (fig 3). However, correlative studies of neurological manifestations and MRI findings have not been done in oriental patients with multiple sclerosis.

MRI is a highly sensitive method to detect lesions in patients with multiple sclerosis.<sup>18, 19</sup> In white patients, brain stem and cerebellar lesions have been well studied using MRI.<sup>6-13</sup> Ormerod *et al*<sup>6</sup> analysed the MRI findings of 114 white patients with multiple sclerosis and found brain stem lesions in 77 (68%) and cerebellar lesions in 56 (49%). Brainin *et al*<sup>10</sup> found cerebellar MRI lesions in 88% of patients with multiple sclerosis. In the British national hospital series by Miller,<sup>12</sup> among 314 patients, MRI lesions in the brain stem were seen in 209 (67%) and in the cerebellar white matter in 169 (54%). Thus cerebellar lesions, verified by MRI examination, were found in

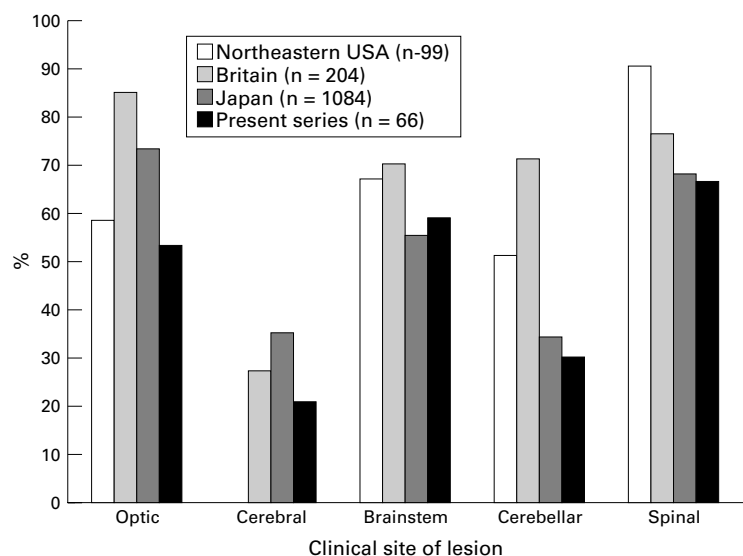


Figure 3 Comparison of clinically determined sites of lesions in our series with other reported series (Northeastern USA: Bansil *et al*<sup>7</sup>; Britain: Shibasaki *et al*<sup>6</sup>; Japan: Kuroiwa *et al*<sup>24</sup>). Cerebellar symptomatology was less common in Japanese patients than in white patients.

half or more of the white patients with multiple sclerosis. In the present study on Japanese patients, cerebellar hemispheric lesions were detected in only four (6.4%, fig 1).

In the present study we included patients with clinically probable multiple sclerosis. However, the percentage was still lower even among 49 clinically definite patients (cerebellar hemispheric lesions in 6.1% and cerebellar hemispheric and/or cerebellar peduncular lesions in 22%).

This low frequency of cerebellar hemispheric lesions on MRI in Japanese patients has never been reported. In our series, about 20% of the patients are thought to have OS-MS, which is characterised by a relatively selective involvement of the optic nerves and spinal cord as well as infrequent involvement in other parts of the CNS, including the cerebellum and brain stem. The prevalence of OB in OS-MS is said to be very low,<sup>1,2</sup> which is unusual in multiple sclerosis of western countries. In fact, OB was positive in only 14% of OS-MS patients, whereas it was positive in 42% of BsCbl-MS patients in our series. None of the OS-MS patients in our series had infratentorial MRI lesions. However, even if patients with OS-MS were excluded in this analysis, the rate of cerebellar lesions was still quite low (9.3%). Moreover, as we used the same or higher MRI resolution in the present study compared with other series, the low frequency of the cerebellar MRI lesions in Japanese multiple sclerosis cannot be attributable to low sensitivity of MRI examination. However, further comparative and controlled evaluation of cerebellar lesions by MRI in Japanese and white patients with multiple sclerosis is needed.

Recently, Kira *et al* suggested a heterogeneity in the genetic background between two subtypes of Japanese patients with multiple sclerosis, the Asian type (OS-MS) and the western type.<sup>20</sup> The DRB1\*1501 allele which is

strongly associated with white multiple sclerosis is significantly frequent in Japanese patients with the western type of multiple sclerosis, but such an association was not found in Japanese patients with OS-MS. This finding suggests the importance of a specific HLA allele in the development of multiple sclerosis, regardless of race. Recent studies on the linkage analysis of familial white patients with multiple sclerosis, however, have suggested that multiple loci including an HLA locus are associated with susceptibility to the disease.<sup>21-23</sup> Thus genetic differences other than HLA may influence the distribution and the frequency of multiple sclerosis lesions in white patients and Japanese patients. In fact, epidemiological studies have shown that OS-MS, which is characterised by the selective involvement of the optic nerves and spinal cord, is more commonly seen in Asian countries than in western countries.<sup>1</sup> The present study suggests that cerebellar involvement might be less common in Japanese patients than in white patients with multiple sclerosis even if OS-MS is excluded.

In conclusion, brain stem and cerebellar involvement was seen in about 65% of Japanese patients with multiple sclerosis. This figure compared with that in western countries. On the other hand, the most striking finding of the present study is that MRI-verified cerebellar hemispheric lesions were uncommon in Japanese patients. This suggests that genetic differences between orientals and white people may have an influence on the frequency and distribution of these multiple sclerosis lesions. Further comparative genetic analyses of these two different racial groups are needed to clarify the pathomechanisms of the disease.

This work was supported by a grant in aid for General Scientific Research (09470150) from the Ministry of Education, Science and Culture, a grant from the Neuroimmunological Research Committee, and a research subsidy from the Japan Foundation for Neuroscience and Mental Health.

- 1 Kuroiwa Y. *Multiple sclerosis in Asia*. Japan: University of Tokyo Press, 1976.
- 2 Shibasaki H, Kubo N, Nishitani H, *et al*. Nationwide survey of multiple sclerosis in Japan: reappraisal of clinical features. *Journal of Tropical and Geographical Neurology* 1992;2:73-82.
- 3 Matthews WB, Compston A, Allen IV, *et al*. *McAlpine's multiple sclerosis*. 2nd ed. Edinburgh: Churchill Livingstone, 1991.
- 4 Miller AE. Clinical features. In: Cook SD, ed. *Handbook of multiple sclerosis*. 2nd ed, revised and expanded. New York: Marcel Dekker, 1996:201-21.
- 5 Poser S, Wikstrom J, Bauer HJ. Clinical data and the identification of special forms of multiple sclerosis in 1271 cases studied with a standardized documentation system. *J Neurol Sci* 1979;40:159-68.
- 6 Comi G, Filippi M, Martinelli V, *et al*. Brain stem magnetic resonance imaging and evoked potential studies of symptomatic multiple sclerosis patients. *Eur Neurol* 1993;33:232-7.
- 7 Ormerod IEC, Bronstein A, Rudge P, *et al*. Magnetic resonance imaging in clinically isolated lesions of the brain stem. *J Neurol Neurosurg Psychiatry* 1986;49:737-43.
- 8 Stone LA, McFarland HF, Frank JA. Neuroimaging in multiple sclerosis. In: Cook SD, ed. *Handbook of multiple sclerosis*. 2nd edition, revised and expanded. New York: Marcel Dekker, 1996:347-76.
- 9 Ormerod IEC, Miller DH, McDonald WI, *et al*. The role of NMR imaging in the assessment of multiple sclerosis and isolated neurological lesions. A quantitative study. *Brain* 1987;110:1579-616.
- 10 Brainin M, Reisner T, Neuhold A, *et al*. Topological characteristics of brainstem lesions in clinically definite and clinically probable cases of multiple sclerosis: an MRI-study. *Neuroradiology* 1987;29:530-4.
- 11 Capra R, Mattioli F, Vignolo LA, *et al*. Lesion detection in multiple sclerosis patients with and without clinical

- brainstem disorders: magnetic resonance imaging and brainstem auditory evoked potentials compared. *Eur Neurol* 1989;29:317-22.
- 12 Miller DH. Spectrum of abnormalities in multiple sclerosis. In: Miller DH, Kesselring J, McDonald WI, *et al*, eds. *Magnetic resonance in multiple sclerosis*. Cambridge: Cambridge University Press, 1997:31-62.
  - 13 Bogousslavsky J, Fox AJ, Carey LS, *et al*. Correlates of brain-stem oculomotor disorders in multiple sclerosis. Magnetic resonance imaging. *Arch Neurol* 1986;43:460-3.
  - 14 Poser CM, Paty DW, Scheinberg L, *et al*. New diagnostic criteria for multiple sclerosis: guidelines for research protocols. *Ann Neurol* 1983;13:227-31.
  - 15 Shibasaki H, Okihira MM, Kuroiwa Y. Multiple sclerosis among orientals and caucasians in Hawaii: a reappraisal. *Neurology* 1978;28:113-18.
  - 16 Shibasaki H, McDonald WI, Kuroiwa Y. Racial modification of clinical picture of multiple sclerosis: comparison between British and Japanese patients. *J Neurol Sci* 1981;49:253-71.
  - 17 Bansil S, Singhal BS, Ahuja GK, *et al*. Comparison between multiple sclerosis in India and the United States: a case-control study. *Neurology* 1996;46:385-7.
  - 18 Goodkin DE, Rudick RA, Ross JS. The use of brain magnetic resonance imaging in multiple sclerosis. *Arch Neurol* 1994;51:505-16.
  - 19 Jacobs L, Kinkel WR, Polachini I, *et al*. Correlations of nuclear magnetic resonance imaging, computerized tomography, and clinical profiles in multiple sclerosis. *Neurology* 1986;36:27-34.
  - 20 Kira J, Kanai T, Nishimura Y, *et al*. Western versus Asian types of multiple sclerosis: immunogenetically and clinically distinct disorders. *Ann Neurol* 1996;40:569-74.
  - 21 Sawcer S, Jones HB, Feakes R, *et al*. A genome screen in multiple sclerosis reveals susceptibility loci on chromosome 6p21 and 17q22. *Nat Genet* 1996;13:464-8.
  - 22 Haines JL, Ter-Minassian M, Bazyk A, *et al*. A complete genomic screen for multiple sclerosis underscores a role for the major histocompatibility complex. *Nat Genet* 1996;13:469-71.
  - 23 Ebers GC, Kukay K, Bulman DE, *et al*. A full genome search in multiple sclerosis. *Nat Genet* 1996;13:377-8.
  - 24 Kuroiwa Y, Igata A, Itahara, *et al*. Nationwide survey of multiple sclerosis in Japan. Clinical analysis of 1084 cases. *Neurology* 1975;25:845-51.