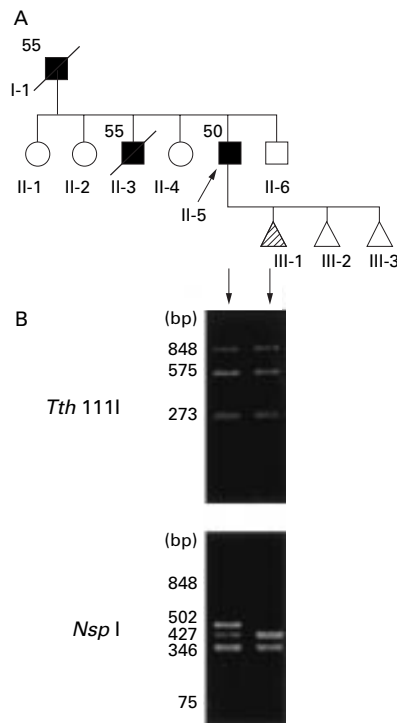


LETTERS TO THE EDITOR

Familial Creutzfeldt-Jakob disease with D178N-129M mutation of PRNP presenting as cerebellar ataxia without insomnia

Fatal familial insomnia (FFI) is a prion disease clinically characterised by progressive insomnia and dysautonomia, and associated with an aspartic acid to asparagine mutation at the codon 178 (D178N) of the prion protein gene (*PRNP*).¹ This mutation is also associated with familial Creutzfeldt-Jakob disease (CJD). These phenotypes have been held to depend on the polymorphism at the codon 129. FFI and CJD phenotypes are associated with methionine (129M) and valine (129V) polymorphisms, respectively.² However, the diverse phenotypes can be associated with D178N-129M genotype.^{3,4} We here report on a Japanese family with D178N-129M genotype presenting cerebellar ataxia without overt insomnia.

The pedigree of this family is depicted in the figure. Patient 1 (II-5), a 50 year old man, a proband, noted an unsteady gait in October 1997 and difficulty in speech in December



Pedigree of the family and genotypes. (A) Pedigree of the family. Squares, males; circles, females; triangles, either sex (to protect the confidentiality of the family, the sexes of these people are not shown). Filled symbols, affected; shaded symbols, genotype only examined; slashed symbols, deceased; numbers, ages of onset. (B) *Tth* 1111 and *Nsp* I restriction analyses of the 848 bp open reading frame of *PRNP*. The *Tth* 1111-non-digested band of 848 bp indicates D178N mutation. The *Nsp* I-non-digested band of 502 bp indicates 129V polymorphism and the 427 bp band 129M polymorphism. The 75 bp band is too thin to be visible.

1997. These symptoms worsened rapidly. He had no episodes of insomnia, hallucination, or involuntary movement. On admission, he was normal in general condition, well oriented, and cooperative, but slightly restless. The Wechsler adult intelligence scale revised (WAIS-R) score was normal (verbal IQ 108 and performance IQ 95). He showed saccadic ocular movements and nystagmoid movements on lateral gaze. His speech was explosive and scanning. Myoclonus was not evident. The muscle tone and strength were normal. He presented moderate bilateral limb ataxia. He could barely stand and walk on a wide base, and tandem gait was impossible. The deep tendon reflexes were normal in his arms and mildly brisk in his legs without Babinski's sign. Sensory examination was normal. Autonomic signs were absent. Routine laboratory and CSF examinations were normal. An EEG showed a background of 9 Hz α activities spreading to the anterior regions without periodic synchronous discharges (PSDs). The sleep EEG overnight for 3 days showed a normal sleep pattern in which spindles, K complexes, slow activities, and REM sleep were seen. Brain MRI showed mild cerebellar atrophy. Single photon emission CT (SPECT) using [^{99m}Tc]-HMPAO showed hypoperfusion in the bilateral frontal lobe and left parietal region, and left striatum. One year after the onset, he still did not develop either dementia or myoclonus.

In July 1995, patient 2 (II-3), an elder brother of patient 1 developed an ataxic gait and forgetfulness at the age of 55 years followed by dysarthria within a month. He had limb ataxia in his arms. The deep tendon reflexes were normal in his arms and mildly brisk in his legs without Babinski's sign. In November 1995, EEG showed diffuse intermittent slow activities without PSDs. In January 1996, he developed akinetic mutism and myoclonic jerks. Brain CT demonstrated moderate cerebellar atrophy. He presented a decorticate posture and died of respiratory failure 7 months after the onset.

Patient 3 (I-1), the father of patient 1, developed an ataxic gait and dementia at the age of 55. He died of an unknown cause after a clinical course of 12 months.

The 848 bp open reading frame of *PRNP* was amplified by polymerase chain reaction (PCR) using peripheral leucocyte DNA. The mutation at the codon 178 and the polymorphism at the codon 129 were screened by restriction analyses with *Tth* 1111 and *Nsp* I as described elsewhere.⁵ The D178N mutation abolishes a *Tth* 1111 site. The restriction analysis of the PCR product shows a non-digested 848 bp fragment in the mutant allele and 575 and 273 bp ones in the normal allele. As shown in the figure, the *Tth* 1111 digestion generated three fragments of 848, 575, and 273 bp in patient 1 and his child (III-1), indicative of both having a heterozygous D178N mutation. The 129V polymorphism abolishes one of the two *Nsp* 1 sites in the PCR product. The restriction analysis shows 502 and 346 bp fragments in the 129V allele, and 427, 346, and 75 bp ones in the 129M allele. Four fragments were detected in patient 1 and three smaller fragments in his child, which indicated that patient 1 was heterozygous for 129V and 129M and that his child was homozygous for 129M. The sequencing of PCR products demonstrated that D178N mutation and 129M polymorphism were on the same allele in patient 1.

Rapidly progressive cerebellar ataxia was present in two generation of this family. Patient 2 presented progressive dementia and

myoclonus, which suggested a diagnosis of familial CJD. The FFI mutation on the 129M allele was found in the examined members of this family. All the patients, however, lacked insomnia clinically, and EEG showed a normal sleep pattern in patient 1. Although pathological findings were not assessed, SPECT in patient 1 did not disclose abnormalities in the thalamus, usually involved in FFI. The phenotype in this family was clearly different from that of FFI. Thus, the supposed dependence of the phenotypes with the FFI mutation on the polymorphism at the codon 129 was not true of the present family. It was already reported in white people that the clinical presentations associated with the FFI genotype are diverse, including cerebellar ataxia, dementia, and autonomic abnormalities with or without insomnia.^{3,4} Our findings support the notion that the phenotypic variability in the FFI genotype exists throughout various ethnic backgrounds, and emphasises the heterogeneity of inherited prion disease.

Y TANIWAKI
H HARA

Department of Neurology, Neurological Institute,
Faculty of Medicine, Kyushu University, Japan

K DOH-URA

Department of Neuropathology

I MURAKAMI

Department of Neurology

H TASHIRO

Department of neuropathology

T YAMASAKI

H SHIGETO

K ARAKAWA

E ARAKI

T YAMADA

Department of Neurology

T IWAKI

Department of neuropathology

J KIRA

Department of Neurology,

Correspondence to: Dr Yoshihide Taniwaki, Department of Neurology, Neurological Institute, Graduate School of Medical Sciences, Kyushu University, 3-1-1 Maidashi, Higashi-ku, Fukuoka 812-8582, Japan
email taniwaki@enjoy.ne.jp

- Medori R, Tritschler HJ, LeBlanc A, et al. Fatal familial insomnia, a prion disease with a mutation at codon 178 of the prion protein gene. *N Engl J Med* 1992;326:444-9.
- Goldfarb LG, Petersen RB, Tabaton M, et al. Fatal familial insomnia and familial Creutzfeldt-Jakob disease: disease phenotype determined by a DNA polymorphism. *Science* 1992;258:806-8.
- McLean CA, Storey E, Gardner RJM, et al. The D178N (cis-129M) "fatal familial insomnia" mutation associated with diverse clinicopathologic phenotypes in an Australian kindred. *Neurology* 1997;47:1326-8.
- Zerr I, Giese A, Windl O, et al. Phenotypic variability in fatal familial insomnia (D178N-129M) genotype. *Neurology* 1998;51:1398-405.
- Furukawa H, Doh-ura K, Kikuchi H, et al. A comparative study of abnormal prion protein isoforms between Gerstmann-Sträussler-Scheinker syndrome and Creutzfeldt-Jakob disease. *J Neurol Sci* 1998;158:71-5.

Postmalaria neurological syndrome: a case of acute disseminated encephalomyelitis?

We report on a 30 year old woman presenting with neurological dysfunction 8 weeks after complete recovery from *Plasmodium falciparum* malaria. Magnetic resonance imaging during her illness showed multifocal white matter abnormalities. She made a full recov-