

# Neuronal metabolic changes in the cortical region after subcortical infarction: a proton MR spectroscopy study

Dong-Wha Kang, Jae-Kyu Roh, Yong-Seok Lee, In Chan Song, Byung-Woo Yoon, Kee-Hyun Chang

## Abstract

**Objectives**—To investigate whether proton magnetic resonance spectroscopy (<sup>1</sup>H MRS) can detect neuronal metabolic changes in the cortical region in patients with cortical dysfunction after subcortical infarction.

**Methods**—Fifteen patients with subcortical large (diameter ≥20 mm) infarcts were studied; nine patients with cortical dysfunction (group A), and six without (group B). Seven patients with lacunar infarction served as controls. Infarct volume was measured on T2 weighted images with an image analyser. <sup>1</sup>H MRS data were obtained in three regions; high signal intensity area on T2 weighted image, overlying cortex with a normal T2 MRI appearance, and contralateral homologous cortical region.

**Results**—Infarct volume was not different between groups A and B. N-acetylaspartate (NAA)/creatine+phosphocreatine (Cr) ratios in the cortical region overlying subcortical infarcts in group A were significantly lower than those in group B and the control group (p=0.002). The NAA/Cr ratios in the overlying cortex were significantly lower than those in the contralateral normal cortex in group A on the initial (p=0.015) and follow up (p=0.028) <sup>1</sup>H MRS, but these differences were not found in group B and the control group.

**Conclusions**—The results support the idea that the cerebral cortex is a responsible location for cortical dysfunction after subcortical infarctions. <sup>1</sup>H MRS can be used as a sensitive method for the detection of a neuronal metabolic damage, which is not demonstrated by conventional MRI.

(J Neurol Neurosurg Psychiatry 2000;69:222-227)

Keywords: cerebral infarction; magnetic resonance spectroscopy; metabolism

Cortical dysfunction such as aphasia or neglect after subcortical infarction involving the striatum or the internal capsule has been known for a long time and ranges from 30% to 80%,<sup>1</sup> but the mechanism is still controversial. Four mechanisms have been stressed as explanations for cortical dysfunction after subcortical ischaemic infarcts<sup>1-4</sup>: (1) the participation of the striatum or internal capsule in language

processing or spatial attention as a component of specific corticosubcortical circuits<sup>3-7</sup>; (2) the disruption of connecting fibres between cortical centres<sup>8-9</sup>; (3) the functional deactivation of cortical centres by the subcortical lesion (“diaschisis”)<sup>10-11</sup>; and (4) selective neuronal loss (“elective parenchymal necrosis” or “incomplete infarction”) of the cortex caused by critical hypoperfusion with the preservation of a structural shape.<sup>12-13</sup>

Recently, localised water suppressed proton magnetic resonance spectroscopy (<sup>1</sup>H MRS) has opened up a new field for pathophysiological studies of cerebral ischaemia and infarction, and it can non-invasively measure various metabolites in the human brain, including N-acetylaspartate (NAA), creatine including phosphocreatine (Cr), choline containing phospholipids (Cho), and lactate (Lac). N-Acetylaspartate is a compound localised exclusively in neurons and neuronal processes,<sup>14-15</sup> thus it is used as a neuronal marker to study the number of viable neurons in brain tissue. In stroke, the decrease of NAA in the infarcted area is well known,<sup>16-20</sup> but the change was found in the region with a normal MRI appearance in other neurological disorders.<sup>21-23</sup>

We hypothesised that <sup>1</sup>H MRS could detect the neuronal metabolic changes which were not demonstrated by conventional MRI, if neuronal damage occurred in the cortical region of patients with cortical dysfunction after subcortical infarction. Therefore, we performed this study to determine whether there was a change in NAA resonance intensity within the cortex overlying subcortical infarcts.

## Patients and methods

### SELECTION AND EVALUATION OF PATIENTS

In this prospective study, 15 consecutive patients with large (diameter ≥20 mm) subcortical infarcts on initial MRI were included. Neuropsychological tests for cortical symptoms or signs including aphasia, neglect, agnosia, cortical sensory loss, or Gerstmann's syndrome were performed. We divided the patients into two groups: group A comprised nine patients (six men and three women, mean age (SD), 59.8 (9.4) years) who presented with aphasia (n=5) or neglect (n=4); group B comprised six patients (two men and four women, mean age (SD), 64.2 (13.8) years) without cortical symptoms or signs.

All patients underwent MRI/MR angiography and diffusion weighted imaging on a 1.5 T system with echoplanar imaging capabil-

Department of  
Neurology, College of  
Medicine, Seoul  
National University,  
28 Yongon-dong,  
Chongno-gu, Seoul  
110-744, Korea  
D-W Kang  
J-K Roh  
Y-S Lee  
B-W Yoon

Department of  
Radiology  
I C Song  
K-H Chang

Correspondence to:  
Dr Jae-Kyu Roh  
rohjk@snu.ac.kr

Received 12 October 1999  
and in revised form  
20 March 2000  
Accepted 12 April 2000

ity (Signa Horizon, Echosped; General Electric Medical Systems). Conventional MRI consisted of transverse T2 weighted sequences (repetition time (TR)/echo time (TE), 4000/98) and sagittal T1 weighted sequences (TR/TE, 450/10) with 5 mm thick slices. Diffusion weighted imaging was obtained in the transverse plane using a single shot echoplanar spin echo pulse sequence with 6500/107, one excitation, and two  $b$  values (0 and 1000 s/mm<sup>2</sup>). The diffusion gradient pulse duration was 31 ms with a gradient separation of 33 ms and a gradient strength of 2.16 g/cm. Diffusion gradients were applied simultaneously along the three axes ( $x, y, z$ ).

In groups A and B, all patients had single large (diameter  $\geq 20$  mm) subcortical infarcts in the territory of the lenticulostriate arteries or centrum semiovale sparing the cortex. In group A, six patients had occlusion or severe stenosis of the middle cerebral artery (MCA); two had internal carotid artery (ICA) occlusion; and the remaining one showed normal angiographic findings. In group B, five patients had normal MR angiographic findings, and only one showed severe stenosis of the MCA. Seven patients (six men and one woman, mean age (SD), 59.7 (15.5) years) with lacunar infarcts (diameter  $\leq 15$  mm) in the territory of the lenticulostriate arteries, who showed no cortical symptoms or signs, served as controls. In the control group, all had normal intra/extracranial arteries on MR angiography. No patient in any group had additional cortical ischaemic lesions on diffusion weighted imaging.

Infarct volumes were calculated from the T2 weighted images using image analyser (TINA version 2.10 g) as follows; infarct volume (cm<sup>3</sup>) = the sum total of infarct area on each MRI slice (cm<sup>2</sup>)  $\times$  (slice thickness (0.5 cm) + gap between each slice (0.25 cm)).

Brain single photon emission computed tomography (SPECT) was performed on selected patients of groups A and B. Consecutive Tc-99m-HMPAO brain perfusion SPECT studies were done before and after acetazolamide administration (20 mg/kg acetazolamide; Tc-99m-HMPAO 555 MBq before acetazolamide, 1110 MBq after acetazolamide).

#### <sup>1</sup>H MRS EVALUATION

All <sup>1</sup>H MRS examinations were performed on a 1.5 T MR unit, the circular polarised head coil being used for imaging and spectroscopy. To define voxels of interest (VOIs), T2 weighted MR imaging preceded the spectroscopy. Spectroscopic data were obtained in three VOIs: (1) subcortical region containing high signal intensity on T2 weighted image; (2) overlying cortex with a normal T2 signal intensity; and (3) contralateral homologous cortical region (fig 1). The size of VOI as determined on MRI was 2  $\times$  2  $\times$  2 cm<sup>3</sup> in all cases. At follow up examinations great care was taken to place the VOI in the same location as before, guided by anatomical landmarks in the images. The homogeneity of the magnetic field over VOIs was optimised with the spatially selective PRESS sequence by observing the proton MR signals of tissue water. Water suppression was

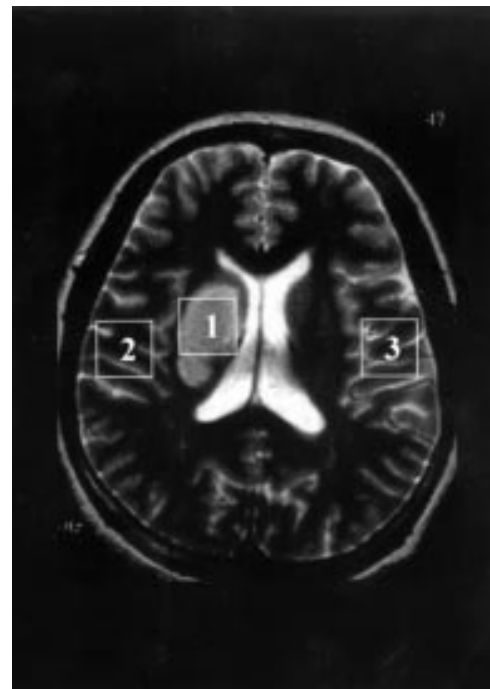


Figure 1 Axial T2 weighted MRI slice of patient 6 with right striatocapsular infarction. The voxels of interest for the spectroscopy (white rectangle) are shown superimposed on MR imaging; (1) infarcted area with T2 high signal intensity, (2) overlying cortex with a normal T2 signal intensity, and (3) contralateral homologous cortical region.

performed by using the presaturation method (CHESS). Typical full widths at half maximum of 4–8 Hz were achieved. TEs of 272 ms and 136 ms, and TR of 2 seconds were used, which resulted in a total acquisition time of 4 minutes 16 seconds for 128 scans. After the zero filling of 4096 points in all free induction decay data, an exponential line broadening (centre: 0 ms, half time: 150 ms) was applied before Fourier transformation, and zero order phase correction was applied to all spectra. Interactive baseline correction carried out by calculating the second order polynomial of the manually defined baseline re-established a flat baseline in those spectra with large residual water signal. Identification of resonances detected on all MR spectra was made (NAA (2.02 ppm), Cho (3.20 ppm), Cr (3.0 ppm), and Lac doublet (1.33 ppm)). Spectral intensities were defined as the peak heights determined from flat baselines on MR spectra. To avoid operator bias, three spectral intensities were measured after correcting the baseline and phase of MR spectra each time, and the resultant mean values were used for the analysis performed in the present study. The Cr signal was used as a stable internal reference, and all of the spectra were scaled to Cr equivalently. As we were unable to calculate absolute metabolic concentrations, concentrations were expressed as the ratio between peak intensities (Cho/Cr, NAA/Cr, and Lac/Cr ratios) in proton MR spectra of three VOIs. The decrease in NAA/Cr ratio was interpreted in terms of neuronal damage.

We performed <sup>1</sup>H MRS studies in acute or early subacute stage (mean (SD), 5.9 (2.5) days, 2–10 days after stroke onset) in all patients. We also obtained <sup>1</sup>H MRS data in the

Table 1 Clinical, MRI, and angiographical characteristics of patients with subcortical large infarction

No/sex/age	Cortical symptoms (duration)	Lesion on MRI	Angiography	SPECT
Patients with cortical symptoms after large subcortical infarctions (group A):				
1/M/65	Global aphasia→motor aphasia (persistent*)	Lt CR, SC	Lt ICA occlusion	↓ P and R in Lt MCA territory
2/M/58	Mild global aphasia (5 days)	Lt SC	Lt MCA severe stenosis	↓ P and R in Lt MCA territory
3/M/69	Visual neglect, sensory extinction (4 days)	Rt CR, SC	Rt MCA inferior occlusion	—
4/M/71	Visual and sensory neglect (10 days)	Rt CR	Rt MCA occlusion	↓ P and R in Rt MCA territory
5/F/61	Global aphasia→motor aphasia (persistent*)	Lt CR	Lt MCA severe stenosis	—
6/F/47	Mild asomatognosia (3 days)	Rt SC	Rt MCA occlusion	—
7/M/63	Anomic aphasia† (7 days)	Rt SC	WNL	↓ P in Rt MCA territory
8/M/61	Global aphasia (persistent*)	Lt SC, CR	Lt ICA occlusion	—
9/F/43	Asomatognosia (3 days)	Rt SC	Rt MCA occlusion	—
Patients without cortical symptoms after large subcortical infarctions (group B):				
10/M/54	—	Rt SC	WNL	↓ P in Rt inferior F lobe
11/F/72	—	Rt SC	WNL	—
12/F/75	—	Rt SC	Rt MCA severe stenosis	—
13/F/53	—	Lt SC	WNL	↓ P in Lt F-P lobes
14/F/49	—	Lt SC	WNL	—
15/M/82	—	Lt SC	WNL	—

SPECT=single photon emission computed tomography; P=perfusion; R=reserve; ↓=decreased; SC=striatocapsular; CR=corona radiata; WNL=within normal limits; ICA=internal carotid artery; MCA=middle cerebral artery; F=frontal; F-P=frontoparietal.

\*These patients had persistent cortical dysfunctions at their latest follow up.

†Left handed person.

late subacute or chronic stage (mean (SD), 41.3 (42.1) days, 22–163 days after stroke onset) in 11 patients (seven in group A, two in group B, and two in the control group) to investigate whether the changes of intensity ratio were persistent or not. The operator was blind to patients' clinical information.

#### STATISTICAL ANALYSIS

Firstly, we compared infarct volumes between groups A and B by Mann-Whitney *U* test. Secondly, we compared intensity ratios of Cho/Cr, NAA/Cr, and Lac/Cr in the infarcted area and overlying cortical region between groups A and B by Mann-Whitney *U* test and among three groups by Kruskal-Wallis test. Thirdly, we

compared Cho/Cr and NAA/Cr ratios of overlying cortex ( $NAA/Cr_{\text{overlying}}$ ) and those of the contralateral cortex ( $NAA/Cr_{\text{contralateral}}$ ) in each group by Wilcoxon signed ranks test. A *p* value < 0.05 was considered statistically significant.

## Results

#### CLINICAL FEATURES

Table 1 summarises the sex, age, cortical symptoms, location of infarctions, and angiographic and SPECT findings. The duration of cortical symptoms was transient in six patients and persistent during the follow up period in three patients. All but one of group A had severe stenosis or occlusion of the MCA or

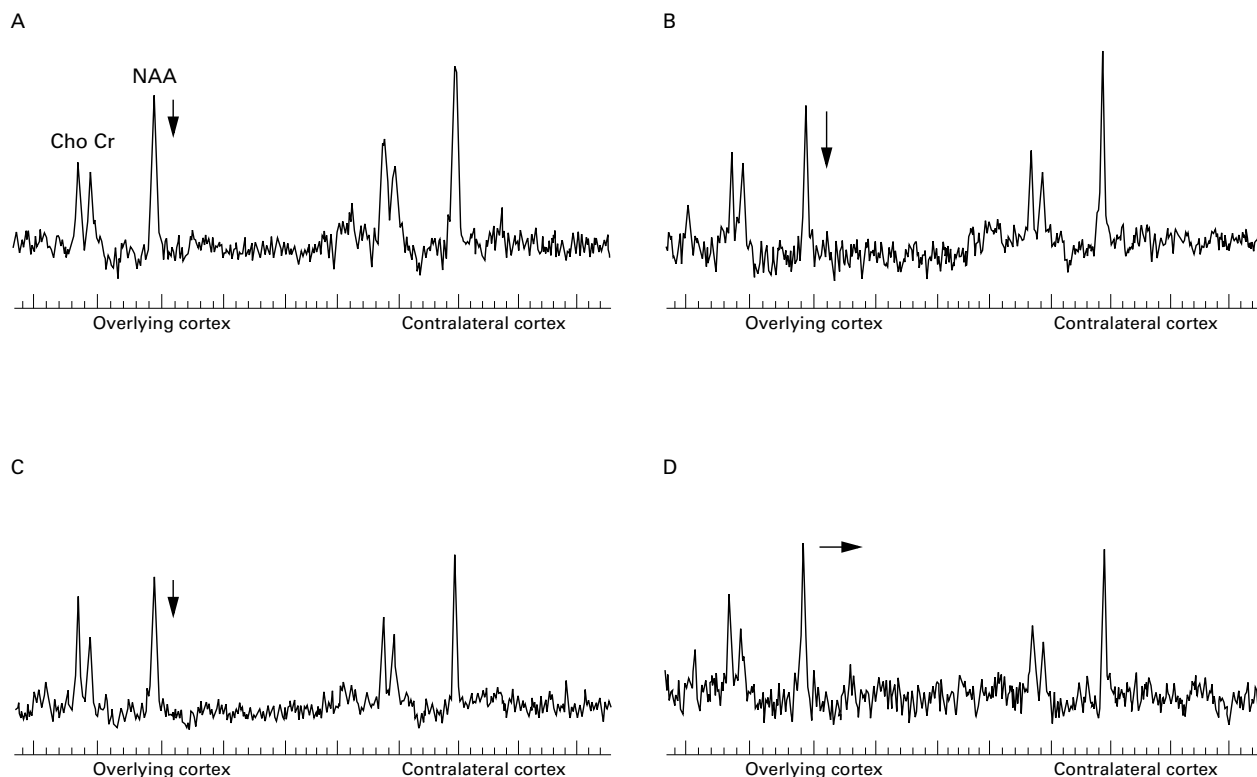


Figure 2  $^1\text{H}$  MR spectra from two patients with cortical dysfunction. In patient 6 (A) decreased NAA/Cr ratio in the cortex overlying the subcortical infarct on initial examination (B) was persistent on follow up examination. (C) In patient 3 a decrease in NAA/Cr in overlying cortex on initial examination (D) was reversible on follow up examination.

Table 2 Group comparisons of intensity ratios of Cho/Cr, NAA/Cr, and Lac/Cr in infarcted area and overlying cortical region among three groups

Ratios	Group A	Group B	Control
Initial study (infarcted area):			
Cho/Cr*	1.43 (0.28)	1.27 (0.28)	1.25 (0.24)
NAA/Cr*	1.00 (0.24)	1.10 (0.18)	1.80 (0.28)
Lac/Cr*	2.02 (0.68)	1.52 (0.64)	0.79 (0.70)
Initial study (overlying cortex):			
Cho/Cr	1.16 (0.20)	1.21 (0.34)	1.18 (0.12)
NAA/Cr†	1.88 (0.18)	2.21 (0.26)	2.37 (0.19)
Lac/Cr	0 (0)	0 (0)	0 (0)
Follow up study (infarcted area)‡:			
Cho/Cr	2.13 (0.47)	1.72 (0.70)	2.32 (0.83)
NAA/Cr	1.20 (0.38)	1.49 (0.34)	1.47 (0.11)
Lac/Cr	1.44 (1.20)	0.34 (0.48)	1.15 (0.68)
Follow up study (overlying cortex)‡:			
Cho/Cr	1.21 (0.24)	0.93 (0.16)	1.37 (0.12)
NAA/Cr	1.75 (0.30)	2.15 (0.10)	2.39 (0.18)
Lac/Cr	0 (0)	0 (0)	0 (0)

Values are mean (SD).

\*Not significantly different between Groups A and B (Mann-Whitney *U* test).

†Significantly lower in Group A than in Group B and control group ( $p=0.002$ , Kruskal-Wallis test).

‡Statistical analysis was not done because of small sample size in Group B and control group.

ICA, and only one of group B had severe MCA stenosis. Brain SPECT was performed in four patients of group A, and showed decreased perfusion and reserve capacity in ipsilateral MCA territory to subcortical infarcts. Brain SPECT findings in two patients of group B showed mildly decreased perfusion in ipsilateral frontal or frontoparietal cortex to subcortical infarcts.

#### GROUP COMPARISONS

Infarct volumes in patients of group A (mean (SD), 9.42 (2.47) cm<sup>3</sup>) did not differ from those in patients of group B (mean (SD), 9.86 (3.13) cm<sup>3</sup>) by Mann-Whitney *U* test.

Representative MR spectroscopic data in two patients with cortical dysfunction are shown (fig 2). Metabolite intensity ratios of Cho/Cr, NAA/Cr, and Lac/Cr in the infarcted area were compared between groups A and B and no differences were found. Cho/Cr, NAA/Cr, and Lac/Cr ratios in overlying cortex were

compared among the three groups. Only NAA/Cr<sub>overlying</sub> was significantly different ( $p=0.002$ , Kruskal-Wallis test, table 2). On the initial <sup>1</sup>H MRS study, NAA/Cr<sub>overlying</sub> in group A (mean (SD), 1.88 (0.18)) was significantly lower than those in group B (mean (SD), 2.21 (0.26)) ( $p=0.021$ , Mann-Whitney *U* test). Compared with the control group (mean (SD), 2.37 (0.19)), NAA/Cr<sub>overlying</sub> of group A was significantly lower ( $p=0.001$ , Mann-Whitney *U* test). However, such a difference was not found in NAA/Cr<sub>overlying</sub> between group B and control subjects.

#### INDIVIDUAL GROUP COMPARISONS AND TEMPORAL CHANGES OF NAA/Cr<sub>OVERLYING</sub>

Cho/Cr, NAA/Cr, and Lac/Cr ratios of overlying and contralateral cortex were compared for each group. In group A, only NAA/Cr<sub>overlying</sub> (mean (SD), 1.88 (0.18)) was significantly lower than NAA/Cr<sub>contralateral</sub> (mean (SD), 2.36 (0.25)) on the initial MRS examination ( $p=0.015$ , Wilcoxon signed ranks test). This difference remained significant in follow up examination (mean (SD), 1.75 (0.30) *v* 2.41 (0.27)) ( $p=0.028$ , Wilcoxon signed ranks test). These differences, however, were not found in patients of group B and the control group (fig 3).

The follow up <sup>1</sup>H MRS studies were performed in seven patients of group A. Five patients (1, 2, 4, 5, and 6) of group A showed more decreased NAA/Cr<sub>overlying</sub> in the follow up studies than those on the initial studies (fig 2 (A), (B)), and these patients had severe stenosis or occlusion of the MCA or ICA. Brain SPECT was performed in three of them, and demonstrated decreased perfusion and reserve capacity in the ipsilateral MCA territory to subcortical infarcts. The other two patients (3 and 7) of group A showed relatively normal NAA/Cr<sub>overlying</sub> values on follow up studies (fig 2 (C), (D)); they also showed improvement of cortical dysfunction. Patient 3 had inferior divisional occlusion of the MCA with good collaterals, and patient 7 showed normal angiographic findings with

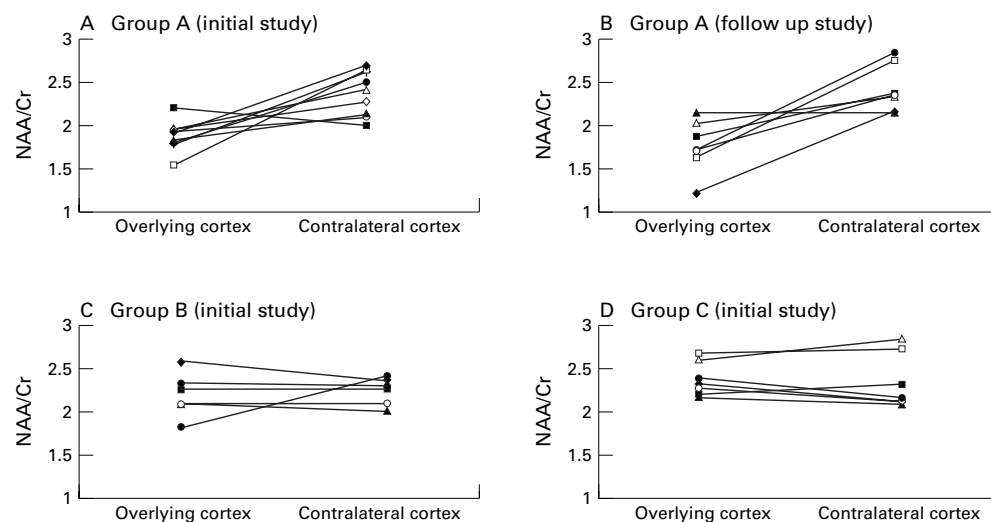


Figure 3 Comparison between NAA/Cr ratios of overlying cortex and those of the contralateral homologous region: the patients with cortical dysfunction show decreased NAA/Cr ratios in overlying cortex compared with those in the contralateral cortex on (A) initial and (B) follow up studies. There is no significant difference in NAA/Cr ratios between overlying cortex and contralateral cortex in (C) the patients without cortical dysfunction and (D) control subjects.

decreased perfusion in the MCA territory on SPECT. Two patients in group B had follow up  $^1\text{H}$  MRS studies; Patient 9 showed mildly decreased perfusion in the inferior frontal lobe on SPECT, and showed decreased NAA/Cr<sub>overlying</sub> on the initial study and a normal value at follow up. The other patient in group B and two patients in the control group did not show significant temporal changes of NAA/Cr values in overlying cortex.

### Discussion

Several mechanisms have been put forward as explanations for aphasia or neglect after subcortical lesions. Previously, it was hypothesised that the occurrence of cortical symptoms was directly attributed to subcortical structures.<sup>5,6</sup> Later, Weiller *et al*<sup>2</sup> showed that no particular subcortical structure was predominantly infarcted in patients with cortical symptoms. We also could not find any difference in Cho/Cr, NAA/Cr, and Lac/Cr ratios in the infarcted area between the patients with and those without cortical dysfunction. Instead, our results showed that NAA/Cr ratios in the overlying cortex in the patients with cortical dysfunction decreased. Neuronal damage as determined by the relative NAA resonance intensity extends beyond the regions of abnormality seen on conventional T2 weighted images in patients with aphasia or neglect after subcortical infarction in our study. These patients showed decreased NAA/Cr values in the cortex with a normal T2 signal intensity overlying subcortical infarcts on the initial and follow up  $^1\text{H}$  MRS studies. Some of them showed impaired perfusion or reserve capacities in the ipsilateral cortex on brain SPECT. Therefore, these results support the idea that the cerebral cortex may be responsible for the occurrence of cortical dysfunction after subcortical infarction.

N-Acetylaspartate, which is located almost entirely within neurons and their axons, is reduced in many diseases, suggesting neuronal injury or death. N-Acetylaspartate has been considered a neuronal marker, thus decreases have been taken to indicate a neuronal loss. In our patients with cortical dysfunction, NAA signals in the overlying cortex decreased in the acute or early subacute stage and remained decreased in the late subacute or chronic stage of ischaemic infarctions. All but one of them had occlusion or severe stenosis of the ICA or MCA, resulting in reduced cortical perfusion and reserve capacity. This cortical perfusion may not be sufficient to keep cortical neurons alive. Consequently, there may be selective neuronal loss in the cortex leading to cortical dysfunction, despite preserved cortical structural shape. From this point of view, neuronal metabolic changes in the cortical region after subcortical infarcts can be explained in terms of "incomplete infarction".<sup>12</sup> Incomplete infarction is characterised by the selective loss of individual neurons with preservation of other cells,<sup>24</sup> and can be quantified with the application of a specific radioligand for the central benzodiazepine receptor.<sup>25</sup> Selective neuronal loss is the consequence of either a short term or

permanent arterial occlusion accompanied by ischaemia of moderate severity. During the acute and subacute stages of an ischaemic stroke, the loss of a limited number of neurons does not result in structural changes discernible by conventional MRI.<sup>12</sup>

Cortical symptoms or signs were transient in six patients in our study, even though decreases in NAA/Cr<sub>overlying</sub> persisted in late subacute or chronic stages in patients with cortical dysfunction. The restitution of cortical function despite persistent cortical damage implies a functional reorganisation. Sparing portions of the subcorticocortical neural network supports the recovery of cortical symptoms through a functional reorganisation.<sup>26</sup> According to the concept of incomplete infarction, the number of destroyed cortical neurons may determine the potential for functional recovery.

The decrease of NAA was interpreted as a sign of irreversible neuronal loss. However, NAA can reflect a neuronal function as well as the number of residual neurons. The fall in NAA/Cr in our study tended to recover in follow up  $^1\text{H}$  MRS studies in two patients of group A and in one of group B. They showed normal angiographic findings or only inferior divisional occlusion of MCA with good collaterals, and two of them had decreased perfusion in the superficial MCA territory with preserved reserve capacity on SPECT. This reversible component of a decrease in relative NAA signal intensity was recently reported in several studies. Van der Grond *et al*<sup>23</sup> reported that the NAA/Cho ratio in the symptomatic hemisphere with no infarcts significantly increased after carotid endarterectomy in some patients with severe stenosis of the proximal ICA. They thought that a neuronal loss was irreversible, and changes in phospholipid metabolism, which resulted in the changes of Cho, might cause the increase in NAA/Cho after endarterectomy. A decrease in NAA was also reported to be reversible in demyelinating lesions or mitochondrial encephalopathies.<sup>27,28</sup> Furthermore, Hugg *et al*<sup>29</sup> demonstrated normalisation of NAA/Cr in unoperated contralateral tissue after the surgical elimination of a seizure focus, in patients with bilateral temporal lobe epilepsy. Cendes *et al*<sup>21</sup> reported that decreases in NAA could be reversible in both ipsilateral and contralateral temporal lobes after the successful control of seizures by surgical removal. They suggested that functional changes in neurons affecting oxidative metabolism might give rise to reversible changes in NAA resonance intensity. Therefore, a decrease in NAA may be not only the result of neuronal loss but also the dynamic marker of physiological or pathological dysfunction.<sup>21</sup> In our study, three patients with a tendency of reversible NAA/Cr might have functional deactivation ("diaschisis") of the cerebral cortex. Data on MRS signal intensity of diaschitic tissue are scarce. Fulham *et al*<sup>30</sup> reported that there was a marked reduction in NAA in a patient with a longstanding diaschitic cerebellar hemisphere. The reversibility of the NAA signal, however, was not documented in that study. The tempo-

ral changes in NAA resonance intensity in diaschitic tissue need to be verified in the future.

There are some limitations in our study. Firstly, we used the single voxel  $^1\text{H}$  MRS technique, which could analyse metabolites only in limited areas. Thus we could not quantify the metabolic status of other cortical regions, and could not exactly delineate the extent and severity of cortical neuronal damage. Furthermore, voxel placement was hard to control precisely. Secondly, we did not perform SPECT studies on follow up  $^1\text{H}$  MRS studies. If we had, we could have more definitely defined whether the reversibility of NAA signals had relied on functional deactivation.

In conclusion, our results of  $^1\text{H}$  MRS in combination with conventional MRI support the idea that direct involvement of the cerebral cortex more conclusively explains the pathogenesis of cortical dysfunction after subcortical infarcts;  $^1\text{H}$  MRS may be a sensitive method for evaluating neuronal damage in the cortex with a normal T2 MRI appearance in subcortical infarction.

- 1 Weiller C. Striatocapsular infarcts. In: Donnan GA, Norris B, Bamford J, *et al*, eds. *Lacunar and other subcortical infarctions*. Oxford: Oxford University Press, 1995:103–16.
- 2 Weiller C, Willmes K, Reiche W, *et al*. The case of aphasia or neglect after striatocapsular infarction. *Brain* 1993;116:1509–25.
- 3 Corbett A, Bennett H, Kos S. Cognitive dysfunction following subcortical infarction. *Arch Neurol* 1994;51:999–1007.
- 4 Crosson B. Subcortical functions in language: a working model. *Brain Lang* 1985;25:257–92.
- 5 Damasio AR, Damasio H, Rizzo M, *et al*. Aphasia with non-hemorrhagic lesions in the basal ganglia and internal capsule. *Arch Neurol* 1982;39:15–20.
- 6 Naeser MA, Alexander MP, Helm-Estabrooks N, *et al*. Aphasia with predominantly subcortical lesion sites. *Arch Neurol* 1982;39:2–14.
- 7 Vallar G, Perani D, Cappa SF, *et al*. Recovery from aphasia and neglect after subcortical stroke: neuropsychological and cerebral perfusion study. *J Neurol Neurosurg Psychiatry* 1988;51:1269–76.
- 8 Alexander MP, Naeser MA, Palumbo CL. Correlations of subcortical CT lesion sites and aphasia profiles. *Brain* 1987;110:961–91.
- 9 Alexander MP. Speech and language deficits after subcortical lesions of the left hemisphere: a clinical, CT, and PET study. In: Vallar G, Cappa SF, Wallesch CW, eds. *Neuropsychological disorders associated with subcortical lesions*. Oxford: Oxford University Press, 1992:455–77.
- 10 Metter EJ, Riege WH, Hanson WR, *et al*. Comparison of metabolic rates, language, and memory in subcortical aphasias. *Brain Lang* 1983;19:33–47.
- 11 Perani D, Vallar G, Cappa SF, *et al*. Aphasia and neglect after subcortical stroke. A clinical/cerebral perfusion correlation study. *Brain* 1987;110:1211–29.
- 12 Garcia JH, Lassen NA, Weiller C, *et al*. Ischemic stroke and incomplete infarction. *Stroke* 1996;27:761–5.
- 13 Weiller C, Ringelstein EB, Reiche W, *et al*. The large striatocapsular infarct: a clinical and pathophysiological entity. *Arch Neurol* 1990;47:1085–91.
- 14 Moffett JR, Nambodiri MAA, Cangro CB, *et al*. Immunohistochemical localization of N-acetylaspartate in rat brain. *Neuroreport* 1991;2:131–4.
- 15 Simmons ML, Frondoza CG, Coyle JT. Immunocytochemical localization of N-acetyl-aspartate with monoclonal antibodies. *Neuroscience* 1991;45:37–45.
- 16 Federico F, Simone IL, Conte C, *et al*. Prognostic significance of metabolic changes detected by proton magnetic resonance spectroscopy in ischemic stroke. *J Neurol* 1996;243:241–7.
- 17 Felber SR, Aichner FT, Sauter R, *et al*. Combined magnetic resonance imaging and proton magnetic resonance spectroscopy of patients with acute stroke. *Stroke* 1992;23:1106–10.
- 18 Gillard JH, Barker PB, van Zijl PC, *et al*. Proton MR spectroscopy in acute middle cerebral artery stroke. *Am J Neuroradiol* 1996;17:873–86.
- 19 Graham GD, Blamire AM, Howseman AM, *et al*. Proton magnetic resonance spectroscopy of cerebral lactate and other metabolites in stroke patients. *Stroke* 1992;23:333–40.
- 20 Houkin K, Kamada K, Kamiyama H, *et al*. Longitudinal changes in proton magnetic resonance spectroscopy in cerebral infarction. *Stroke* 1993;24:1316–21.
- 21 Cendes F, Andermann F, Dubeau F, *et al*. Normalization of neuronal metabolic dysfunction after surgery for temporal lobe epilepsy. *Neurology* 1997;49:1525–33.
- 22 Hu MT, Taylor-Robinson SD, Chaudhuri KR, *et al*. Evidence for cortical dysfunction in clinically nondemented patients with Parkinson's disease: a proton MR spectroscopy study. *J Neurol Neurosurg Psychiatry* 1999;67:20–6.
- 23 van der Grond J, Balm R, Klijn CJ, *et al*. Cerebral metabolism of patients with stenosis of the internal carotid artery before and after endarterectomy. *J Cereb Blood Flow Metab* 1996;16:320–6.
- 24 Garcia JH, Liu KF, Ye ZR, *et al*. Incomplete infarct and delayed neuronal death after transient middle cerebral artery occlusion in rats. *Stroke* 1997;28:2303–10.
- 25 Nakagawara J, Sperling B, Lassen NA. Incomplete brain infarction of reperfused cortex may be quantitated with iomazenil. *Stroke* 1997;28:124–32.
- 26 Weiller C, Chollet F, Friston KJ, *et al*. Functional reorganization of the brain in recovery from striatocapsular infarction in man. *Ann Neurol* 1992;31:463–72.
- 27 Davie CA, Hawkins CP, Barker GJ, *et al*. Serial proton magnetic resonance spectroscopy in acute multiple sclerosis lesions. *Brain* 1994;117:49–58.
- 28 DeStefano N, Mattews PM, Arnold DL. Reversible decreases in N-acetylaspartate after acute brain injury. *Magn Reson Med* 1995;34:721–7.
- 29 Hugg JW, Kuzniecky RI, Gilliam FG, *et al*. Normalization of contralateral metabolic function following temporal lobectomy demonstrated by  $^1\text{H}$  magnetic resonance spectroscopic imaging. *Ann Neurol* 1996;40:236–9.
- 30 Fulham MJ, Dietz MJ, Duyn JH, *et al*. Transsynaptic reduction in N-acetyl-aspartate in cerebellar diaschisis: a proton MR spectroscopic imaging study. *J Comput Assist Tomogr* 1994;18:697–704.