

SHORT REPORT

Peripheral facial palsy and dysfunction of the oropharynx

Y Seçil, I Aydoğdu, C Ertekin

J Neurol Neurosurg Psychiatry 2002;**72**:391–393

The facial nerve contributes to the oropharyngeal phase of deglutition via the buccinator, perioral, digastricus posterior, and stylohyoid muscles. The gustatory and salivatory functions of the facial nerve are also known to contribute to swallowing. The relation between peripheral facial nerve palsy (PFP) and swallowing dysfunction has never been studied systematically.

Forty four patients with unilateral Bell's palsy (acute or chronic stages) and 20 normal control subjects were investigated. In 66% of patients with PFP, oropharyngeal swallowing was disturbed as demonstrated electrophysiologically by the patients' dysphagia limit at or below 20 ml of water. In patients with PFP investigated within the first 2 weeks of the palsy, the dysphagia limit normalised during the period of recovery. Normalisation of the dysphagia limit is highly correlated with the recovery of PFP.

Thus, subclinical deglutition is very frequent in patients with PFP. The severity of abnormal deglutition increased with the severity of the PFP, especially with the involvement of the perioral and buccinator muscles.

The contribution of the facial nerve and its muscles to the oropharyngeal phase of swallowing is known and the difficulty in swallowing has been described in PFP.¹⁻³ However, a systematically designed study does not exist in the literature that concerns the effects of PFP on deglutition. Moreover, the disturbance of swallowing is often not evaluated in patients with PFP and may remain clinically underestimated.

The aim of this study was to investigate oropharyngeal function in patients with PFP (patients with Bell's palsy) using clinical and electrophysiological methods of measuring deglutition which have previously been described.⁴⁻⁷

PATIENTS AND METHODS

We investigated 44 patients with PFP (23 men, 21 women, mean age 35.7, age range 16–67). The patients were divided into two groups; the first (acute phase) group comprised the patients in the first 15 days after the onset of PFP (n=30). The second (chronic phase) group (n=14) comprised patients investigated later than 3 months after the onset of PFP. In the acute PFP group clinical examination, EMG, and deglutition studies were performed between 3 and 15 days of onset of the disease. Thirteen of the 30 patients with acute PFP were followed up until complete or partial clinical recovery. A control group comprised 20 healthy subjects (six men, 14 women, mean age 34.8, age range 19–66 years) in whom the same clinical and electrophysiological methods were applied.

The diagnosis of PFP was supported by electrodiagnostic studies including facial nerve stimulation and needle EMG applied to facial muscles. Apart from a standard neurological examination, the oral and pharyngeal structures were particularly examined and functionally evaluated. The examination included saliva accumulation in the mouth, the change of voice after drinking water, head and neck posture

during swallowing, any abnormality in laryngeal elevation, the quality of voluntary cough, the position of the uvulae at rest and during phonation, palatopharyngeal reflexes, tongue movements, and control of the bolus. The tactile sensation of the intraoral cavity and anterior part of the tongue was carefully tested by probing with a spatula. The perioral muscles of the facial nerve and their functions were examined by various clinical manoeuvres. Any drooling from the paretic side was noted while the mouth was full of water. Taste function was assessed by specifically asking the patient.

Electrophysiological methods**Orbicularis oris EMG**

The orbicularis oris EMG was recorded by concentric needle electrodes (Medelec, disposable needle electrode DMC-37; diameter 0.46 mm, recording area 0.07). The motor unit potentials, recruitment and spontaneous denervation activity, and evoked M responses were measured (Medelec Mystro MS-20 or Medelec Synergy).

According to the EMG pattern of the orbicularis oris muscle, the degree of PFP was classified as follows: (1) Interference pattern with some neurogenic motor unit changes; (2) mixed pattern; (3) single oscillation; (4) no voluntary EMG activity

Sensory and motor conduction

Sensory and motor conduction studies in the median, ulnar, and accessory nerves were performed in all patients and control subjects.

Electrophysiological methods

Electrophysiological methods for evaluation of oropharyngeal swallowing⁴⁻⁸; patterns of deglutition were evaluated while drinking 3 ml of water from the midline, paretic, and non-paretic sides separately, and the results were compared between patients with PFP and normal subjects.

Dysphagia limit

The dysphagia limit technique has been developed to objectively diagnose neurogenic dysphagia.^{5-7,9} All subjects were given 3, 5, 10, 15, and 20 ml water. Any multiple swallowing at or below 20 ml water was taken as the "dysphagia limit" and was regarded as a sign of dysphagia. The dysphagia limit procedure was repeated for three sides of the oral cavity. Firstly, the patient tried to collect the water on the midline of mouth and swallowed, this test was repeated from paretic and non-paretic sides of the oral cavity.

A descriptive analysis method, Mann-Whitney *U* test, and *t* test (independent and paired) were used as statistical analysis methods of the study.

RESULTS

There were some clinical abnormalities indicating a "silent" swallowing disorder in patients with PFP. The main complaint

Abbreviations: PFP, peripheral facial nerve (Bell's) palsy; DL, dysphagia limits; SM-EMG, submental EMG recordings

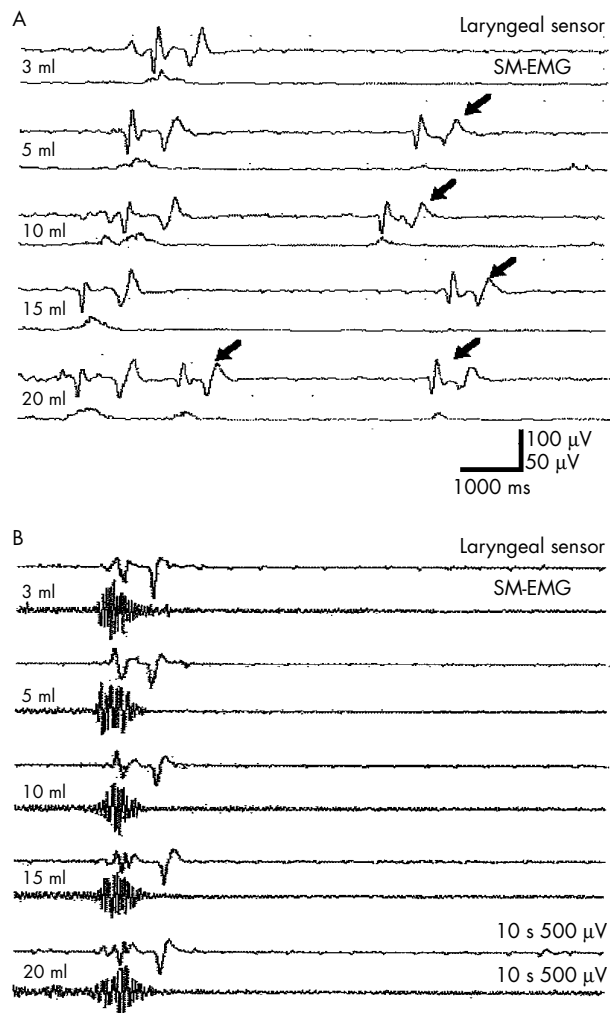


Figure 1 (A) Patient with acute PFP on the 4th day showed an abnormal dysphagia limit of 5 ml from paretic left sided swallowing (arrows denote second swallows). (B) Two months later, during left sided swallowing the patient's dysphagia limit was in the normal range and coincided with clinical recovery (in both A and B first lines represent laryngeal sensor recordings and second lines represent submental EMG recordings (SM-EMG), rectified and integrated EMG were used in the first record).

was difficulty in controlling a bolus in the mouth in 79% (25/30 in acute group, 10/14 in chronic group) and a decreased ability to taste in 39% (14/30 in acute group, 2/14 in chronic group). The most interesting finding was the decrease of tactile sensation on the mucosae of the cheek and tongue on the paretic side in 43% of patients. In the acute patient group, the intraoral hypaesthesia was combined with hypogusia or agusia on the same side in 71% of the patients.

The dysphagia limit of the patient group was found at a level of 20 ml water or below, and was significantly lower than in normal healthy subjects ($p < 0.05$). Swallowing from the paretic side produced double or multiple swallowing with 20 ml or less of water. After recovery from the PFP the dysphagia limit returned to the normal value (fig 1). In the acute phase of PFP, the dysphagia limit was abnormal not only on the paretic side but also swallowing from the midline or non-paretic side was recorded as repetitive swallows within 8 seconds. The dysphagia limit was abnormal in 55% of all patients from the paretic side, in 44% from the midline, and 28% from the non-paretic side of swallowing. The abnormalities in dysphagia limit were more apparent from the paretic side of swallowing (fig 2). Severe motor unit loss in the

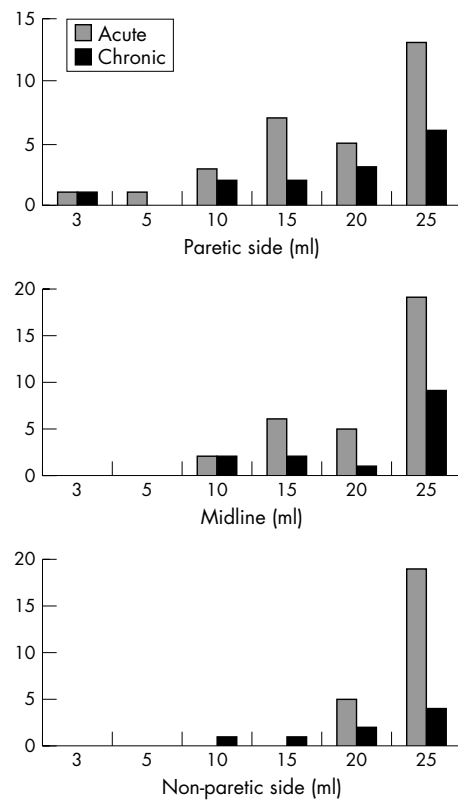


Figure 2 Bar histograms of dysphagia limits of patients with acute or chronic PFP from paretic sides, non-paretic sides, and from the midline. Number of patients is shown on the y axis

orbicularis oris muscle was associated with the pathological dysphagia limits in 57% of patients, although this was not statistically significant. There was no correlation between deglutition limit and sensory loss in the mouth ($p > 0.05$).

All nerve conduction studies, including median, ulnar, and accessory nerves were normal.

DISCUSSION

Difficulty in controlling a bolus in the mouth was found in 79% of all patients and a dysphagia limit was encountered in 55% of them. Their recovery coincident with clinical improvement indicates that there is a benign swallowing disorder in PFP and this disorder was related to the oral phase of swallowing.

Why does the swallowing disorder occur? The answer may be sought in motor, sensory, taste, and parasympathetic innervations related to deglutition.

Two suprahyoid muscles (posterior digastric and stylohyoid muscles) situated behind the mandible are innervated by the facial nerve. They are probably inactive during swallowing¹⁰ although the contrary view has also been proposed.¹¹ Orbicularis oris and buccinator muscles seem to be very important for the oral phase of swallowing. These muscles firmly close the mouth to prevent food escaping, flatten the cheeks, and hold the food in contact with the teeth.¹⁰ Their contraction and muscle tone acts as a valve mechanism.¹² In PFP, the paretic orbicularis oris and buccinator muscles cannot prevent the accumulation of food in the anterior and posterior sulci. As a result, food, especially liquids, drools from the paretic side to the outside. Liquids can also accumulate in the posterior sulcus between the cheek and teeth. This material can remain and later on the remaining liquid material can slide down into pharyngeal cavity and second swallowing occurs. This may be one of the explanations of the abnormalities of the dysphagia limit in our patients. Because the sensory-motor integration of

the larynx and the cough reflexes remain normal in unilateral PFP, penetration into the airway would be rare and aspiration would not be encountered. In normal deglutition and in its disorders, the clinical effect of taste sensation has never been clearly understood although a change in bolus taste has been shown to affect swallowing physiology.¹ We could not find any relation between hypoagusia and the incidence of swallowing disorders in PFP.

The submandibular and sublingual glands are innervated by the parasympathetic fibres of the facial nerve and a reduction in salivary secretion may have a dramatic effect on swallowing. However, in a unilateral facial palsy, salivary glands and parotid glands on the other side may easily compensate for this defect.

Our method of investigating the sensory loss in the face and mouth was subjective and gross but the sensory loss was clearly described by our patients. We speculate that this sensory loss is due to a cranial neuropathy or trigeminal afferent involvement.^{13, 14} These sensory findings did not correlate with the dysphagia limit abnormalities in our patients. Furthermore, the accessory, median, and ulnar nerve conduction study results were normal as was the standard neurological examination.

Why are the swallowing abnormalities more spread in the oral cavity and even bilateral in some patients? The answer may be the physiological bilaterality of swallowing function. Pharyngeal swallowing is represented bilaterally in the cortex^{8, 15-17} and in the bulbar centres.^{8, 18, 19} In acute unilateral facial palsy, the abnormalities of the paretic side cannot be compensated for within the first few days or weeks and the non-paretic side can also be affected by the paresis of the opposite side. The asymmetry of motor function can also affect the other side negatively. All swallowing disorders in the oral phase improved together with the clinical recovery.

Our findings are not only of academic interest but may be of help in clinical practice. Especially, elderly patients and patients with some systemic diseases such as diabetes or pulmonary disorders with weak cough reflexes who develop unilateral facial palsy can be at risk from dysphagia.

Authors' affiliations

Y Seçil, I Aydoğdu, C Ertekin, Department of Neurology and Clinical Neurophysiology, Ege University Medical School Hospital, 35100, Bornova, Izmir, Turkey

Correspondence to: Professor C Ertekin, Göncü Apt Talatpaşa Bulvarı No 12, Daire 3, 35220 Alsancak, Izmir, Turkey; yseçil@hotmail.com

Received 27 April 2001

In final revised form 19 October 2001

Accepted 25 October 2001

REFERENCES

- 1 Logemann JA. *Evaluation of treatment of swallowing disorders*. Texas: Austin TX Pro-ed, 1998.
- 2 Perlman AL, Christensen J. Topography and functional anatomy of the swallowing structures. In: Perimen AL, Schulze-Delrieu KS, eds. *Deglutition and its disorders*. London, UK: Singular Publishing Group, 1997;15-42.
- 3 Haerer AF. *DeJong's the neurologic examination*. Philadelphia: Lipincott-Raven, 1992.
- 4 Ertekin C, Pehlivan M, Aydoğdu I, et al. An electrophysiological investigation of deglutition in man. *Muscle Nerve* 1995;18:1177-86.
- 5 Ertekin C, Aydoğdu I, Yuçeyar N. Piecemeal deglutition and dysphagia limit in normal subjects and in patients with swallowing disorders. *J Neurol Neurosurg Psychiatry* 1996;61:491-6.
- 6 Ertekin C, Aydoğdu I, Yuçeyar N, et al. Electrodiagnostic methods for neurogenic dysphagia. *Electroencephalogr Clin Neurophysiol* 1998;109:331-40.
- 7 Ertekin C, Aydoğdu I, Yuçeyar N, et al. Pathophysiological mechanisms of oropharyngeal dysphagia in amyotrophic lateral sclerosis. *Brain* 2000;123:125-40.
- 8 Ertekin C, Kiylioglu N, Tarlaci S, et al. Voluntary and reflex influences on the initiation of swallowing reflex in man. *Dysphagia* 2001;16:40-7.
- 9 Ertekin C, Yuçeyar N, Aydoğdu I. Clinical and electrophysiological evaluation of dysphagia in myasthenia gravis. *J Neurol Neurosurg Psychiatry* 1998;65:848-56.
- 10 Perlman AL, Christenson J. Topography and functional anatomy of the swallowing structures. In: Perlman AL, Schulze-Delrieu KS, eds. *Deglutition and its disorders*. San Diego: Singular Publication Group, 1997:15-42.
- 11 Broniatowski M, Sonies BC, Rubin JS, et al. Current evaluation and treatment of patients with swallowing disorders. *Otolaryngol Head Neck Surg* 1999;120:464-73.
- 12 Logemann JA. Screening, diagnosis and management of neurogenic dysphagia. *Semin Neurol* 1996;16:319-27.
- 13 Mattox DE. Clinical disorders of the facial nerve. In: Cummings CW, Frederickson JM, Harker LA, et al. *Otolaryngology head and neck surgery*. St Louis: Mosley, 1998:2767-2784.
- 14 Adour KK. Current concepts in neurology: diagnosis and management of facial paralysis. *N Engl J Med* 1982;307:348-51.
- 15 Ertekin C, Turman B, Tarlaci S, et al. Cricopharyngeal sphincter muscle responses to transcranial magnetic stimulation in normal subjects and in patients with dysphagia. *Clin Neurophysiol* 2001;112:86-94.
- 16 Hamdy S, Aziz Q, Rothwell JC, et al. The cortical topography of human swallowing musculature in health and disease. *Nat Med* 1996;2:1217-24.
- 17 Aziz Q, Rothwell JC, Hamdy S, et al. The topographic representation of esophageal motor function on the human cerebral cortex. *Gastroenterology* 1996;111:855-62.
- 18 Jean A, Car A. Inputs to the swallowing medullary neurons from the peripheral afferent fibers and the swallowing cortical area. *Brain Res* 1979;78:567-72.
- 19 Doty RW, Richmond WH, Storey AT. Effect of medullary lesions on coordination of deglutition. *Exp Neurol* 1967;17:91-106.