

## SHORT REPORT

## Human T cell leukaemia virus type I associated neuromuscular disease causing respiratory failure

E T Littleton, W D Man, J L Holton, D N Landon, M G Hanna, M I Polkey, G P Taylor

*J Neurol Neurosurg Psychiatry* 2002;**72**:650–652

Polymyositis and inclusion body myositis have rarely been described in association with human T cell leukaemia virus type I (HTLV-I) infection. Most of such patients have coexisting HTLV-I associated myelopathy (HAM). Two patients with HTLV-I infection, myopathy, and respiratory failure are described. The muscle biopsy specimen of the first patient bore the histological features of inclusion body myositis and there was no evidence of concurrent myelopathy. The second patient had HAM, and her muscle biopsy showed non-specific myopathic and neuropathic changes. Both patients developed respiratory muscle weakness over eight years after diagnosis of myopathy, leading to hypercapnic respiratory failure requiring mechanical ventilatory support. Respiratory failure as a complication of HTLV-I associated myopathy has not previously been described.

Polymyositis and sporadic inclusion body myositis are well known inflammatory myopathies, with the latter being the more common when clinical onset is after the age of 50. Respiratory muscle weakness with ventilatory failure is a recognised complication of polymyositis, but is an extremely rare sequela of inclusion body myositis.<sup>1</sup> Both these types of myopathy have been reported in patients with human T cell leukaemia virus type I (HTLV-I) infection, in whom the virus may play a myopathogenic role.<sup>2–4</sup> However, ventilatory failure due to retroviral associated myopathy has not been reported.

HTLV-I infection is particularly prevalent in Caribbean and Japanese populations. Its most common neurological manifestation is tropical spastic paraparesis (TSP) or HTLV-I associated myelopathy (HAM), which has a predilection for the thoracic cord.<sup>5</sup> HTLV-I infection has less commonly been associated with changes in cerebral white matter,<sup>6</sup> anterior horn cell degeneration,<sup>7</sup> neuropathy,<sup>6,8</sup> and polymyositis.<sup>2,6,8</sup> It has previously been reported in association with inclusion body myositis in only two patients.<sup>3,4</sup> The same patient with HAM/TSP may concurrently be affected by one or more of these rarer pathologies, illustrating the broader neuromuscular syndrome in which this virus is implicated.

We describe the occurrence of ventilatory failure in two patients with HTLV-I associated myopathy.

## CASE 1

A 49 year old Jamaican born woman, resident in the United Kingdom since the age of 10, noticed difficulty climbing stairs and reaching above her head from the age of 39. There was no family history of note. She was hypertensive, for which she was taking amlodipine, atenolol, and chlorthalidone.

Her plasma creatine kinase was 1347 U/l, and a muscle biopsy showed scattered lymphocytic infiltrates and occasional rimmed vacuoles. She received prednisolone at doses up to 30 mg a day, and also two courses of intravenous pooled human immunoglobulin, plus courses of oral azathioprine,

methotrexate, and cyclosporin. Unfortunately her weakness never improved. Her symptoms of urinary frequency and urgency were well controlled with oxybutynin, and there was no bowel dysfunction.

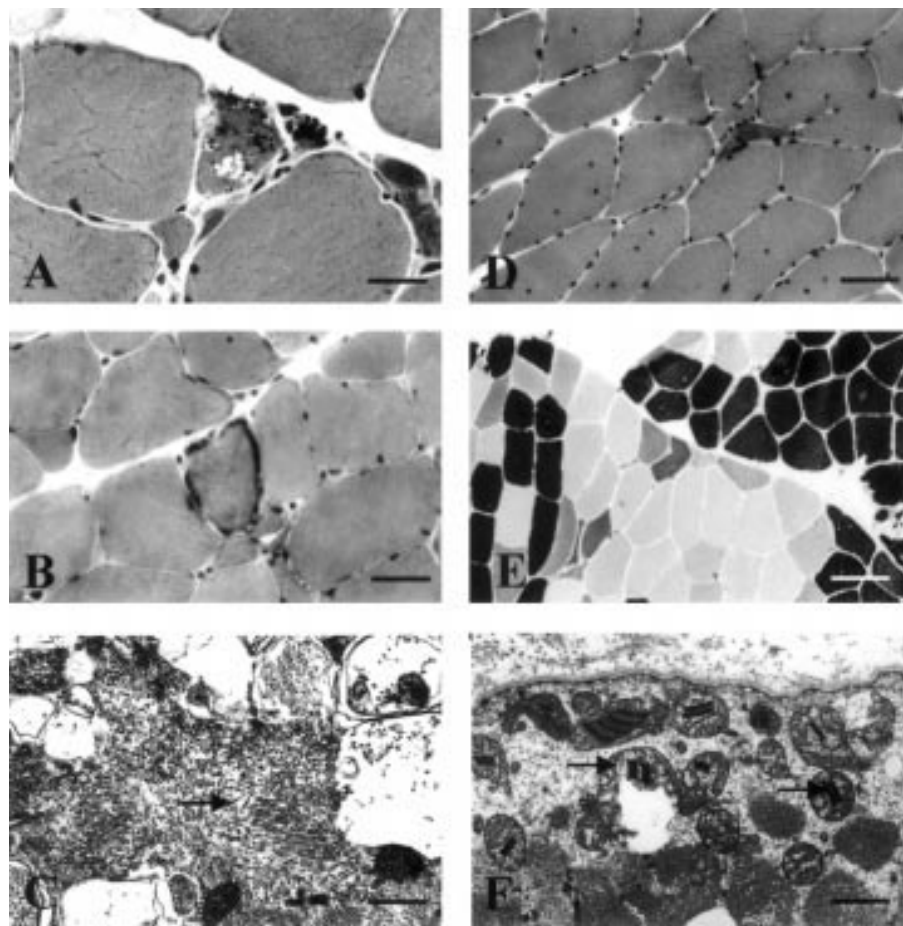
Serum antibodies to HTLV-I were detected and subsequently HTLV-I viraemia was confirmed and quantified by nested polymerase chain reaction of serially diluted DNA extracted from peripheral blood mononuclear cells (PBMCs).<sup>9</sup> Nine years after clinical onset, antiretroviral treatment was started using lamivudine 150 mg twice a day, added to her regular medication of prednisolone 10 mg and cyclosporin 300 mg a day. Although the proviral load fell from three copies per 100 PBMCs to 0.14 per 100 PBMCs over the next six months, there was no objective clinical benefit.

Ten years after onset, she noticed increasing breathlessness, morning headaches, and daytime somnolence. In retrospect, some degree of orthopnoea had been present for over a year. She became unable to walk, had a flapping tremor, but reported no dysphagia. On examination facial power was normal but neck flexion and extension were weak. Paradoxical abdominal movements with respiration were observed. There was considerable wasting and weakness of the shoulder girdle and quadriceps muscles (Medical Research Council grade 2), but distally power was relatively preserved (grade 4 to 4+). Selective weakness of the finger and wrist flexors relative to their antagonist muscle groups, a pattern sometimes observed in inclusion body myositis,<sup>10</sup> was not found. Biceps and supinator jerks were present, but triceps jerks were absent. Both knee jerks and right ankle jerk were present. Plantar responses were flexor. Sensory examination was normal.

Daytime arterial blood gas analysis on air showed type II (hypercapnic) respiratory failure (Paco<sub>2</sub>, 9.7 kPa; Pao<sub>2</sub>, 11.5 kPa; HCO<sub>3</sub><sup>-</sup>, 31 mmol/l). Chest radiograph and echocardiogram were normal. Vital capacity was reduced (27% of predicted) without evidence of airflow limitation, and reduction of both carbon monoxide gas transfer (28% of predicted) and transfer coefficient (85% of predicted) indicated global respiratory muscle weakness rather than purely diaphragmatic weakness.<sup>11,12</sup> Sniff nasal inspiratory pressure was 16 cm H<sub>2</sub>O (normal range > 70 cm H<sub>2</sub>O), consistent with profound inspiratory muscle weakness.

Creatine kinase was 93 U/l. Magnetic resonance imaging of the brain and spinal cord and nerve conduction studies were normal. Electromyography of the right deltoid and right tibialis anterior showed profuse fibrillations and positive sharp waves, polyphasic motor units of normal and short duration, and motor unit recruitment to a full interference pattern. Left triceps muscle biopsy (power grade 4) showed no active inflammation but many fibres contained rimmed vacuoles and

**Abbreviations:** HTLV-I, human T cell leukaemia virus type I; HAM, HTLV-I associated myelopathy; TSP, tropical spastic paraparesis; PBMC, peripheral blood mononuclear cell



**Figure 1** The pathology of each case is illustrated by light microscopy performed on frozen sections of skeletal muscle (A, B, D, E) and electron microscopy (C, F). Case 1 (A–C) shows variation in fibre diameter with a rimmed vacuole (A, haematoxylin and eosin. Bar = 30  $\mu$ m) and a ragged red fibre (B, Gomori trichrome. Bar = 40  $\mu$ m). Electron microscopy confirms the presence of tubulofilamentous inclusions (C, Bar = 580 nm). Case 2 (D–F) shows numerous internal nuclei and angular atrophic fibres (D, haematoxylin and eosin. Bar = 40  $\mu$ m). Fibre typing using ATPase histochemistry at pH 4.3 shows a disturbance of the normal mosaic pattern with a clear group of darkly staining type I fibres (E, Bar = 200  $\mu$ m). Electron microscopy shows the presence of abnormal mitochondria containing type 1 crystalline inclusions (F, Bar = 1.2  $\mu$ m).

there were occasional ragged red fibres. Tubulofilamentous inclusions, 15–20 nm in diameter and of the type commonly associated with inclusion body myositis were shown by electron microscopy in association with the rimmed vacuoles but not within myonuclei (fig 1A–C).

An initial sleep study with ventilatory support showed that her  $P_{aCO_2}$  could be maintained at between 3 and 5 kPa, but climbed to 10 kPa when support was withdrawn in the morning. After a period of rehabilitation, she was discharged with nocturnal domiciliary non-invasive positive pressure ventilation. At the three month follow up, she remained well, with a daytime arterial  $P_{aCO_2}$  of 6.4 kPa, and was off cyclosporin, reducing the prednisolone dose, and continuing to take lamivudine.

## CASE 2

A 57 year old Antiguan born woman, resident in the United Kingdom since the age of 15, first noticed difficulty walking at the age of 41. Within five years she was confined to a wheelchair, had upper limb weakness and urinary urgency necessitating indwelling catheterisation. She was hypertensive, requiring amlodipine, atenolol, and bendrofluazide.

On examination at age 49, her upper limbs were wasted and perceptibly weak proximally, but of normal tone and power distally. Lower limbs were spastic, with severe proximal wasting and weakness. All reflexes were present but both plantar responses were extensor. Sensory examination was normal.

Electromyography showed both myopathic and neurogenic changes proximally in upper and lower limbs. A muscle biopsy, reported at the time but not available for review, was said to show no evidence of inflammation but to show atrophy, with mostly polyhedral but some angulated muscle fibres. The distinction between myopathic and neurogenic atrophy could not be made. Magnetic resonance imaging showed an atrophic cervical cord. Creatine kinase was 630 U/l, antinuclear antigen antibodies weakly positive (speckled pattern), and serum anti-HTLV-I antibodies were detected. HAM/TSP together with HTLV-I associated myopathy (type unspecified) was diagnosed. Steroids were not given in view of the lack of inflammatory changes in the biopsy.

At age 53, she started taking lamivudine 150 mg twice a day. Proviral load remained constant for eight weeks but by 16 weeks had reached a nadir of 0.01 copies per 100 PBMCs. Thereafter the viral burden increased, returning to her baseline of 14 copies per 100 PBMCs by week 24. Lamivudine was discontinued after six months because of lack of clinical and virological improvement.

At age 57, she developed over a few weeks nocturnal restlessness, daytime somnolence, and morning headaches. She was admitted to hospital comatose, with severe hyponatraemia (112 mmol/l) thought to be secondary to intravascular volume depletion due to reduced oral fluid intake and the use of thiazide diuretics. Thyroid function and synacthen tests were normal. Arterial blood gas analysis on 10

litres/minute oxygen showed pH 7.27,  $P_{aCO_2}$ , 9.4 kPa;  $P_{aO_2}$ , 49.1 kPa;  $HCO_3^-$ , 32 mmol/l. She was intubated and ventilated, and her metabolic abnormalities were corrected over the next four days. On withdrawal of sedation, she regained consciousness but continued to require ventilation.

Paradoxical abdominal movements with respiration were noted and fluoroscopic screening showed impaired diaphragmatic movements. Right triceps muscle biopsy showed angular atrophic fibres and fibre type grouping indicative of denervation with reinnervation. In addition, there were split fibres, increased internal nuclei, actively regenerating fibres, and two necrotic fibres. There was no lymphocytic infiltrate. Electron microscopy showed increased glycogen and the presence of mitochondria containing type 1 crystalline inclusions in a number of fibres. There were no rimmed vacuoles and no filamentous inclusions, either nuclear or sarcoplasmic (fig 1D–F). Unfortunately she died unexpectedly because of haemorrhage from her tracheostomy site, which resulted in fatal aspiration of blood.

## DISCUSSION

The first patient showed clear evidence of respiratory muscle weakness as the cause of her respiratory failure. Diaphragmatic weakness was indicated by her orthopnoea.<sup>13</sup> Her poor maximal sniff nasal inspiratory pressure was a more direct measure of muscle weakness than was her reduced vital capacity. The reliability and validity of the maximal sniff nasal inspiratory pressure has been documented in patients with amyotrophic lateral sclerosis,<sup>14</sup> as it can still be performed to a technically adequate standard in patients with advanced global weakness. Further evidence of already advanced respiratory muscle involvement was provided by her symptoms of early morning headache and excessive daytime somnolence, indicative of nocturnal hypoventilation. Hypercapnia, when due to purely neuromuscular causes, does not occur until inspiratory muscle strength has fallen to less than 30% normal.<sup>15</sup> The second patient displayed similar symptoms of hypercapnia, and, although formal pulmonary function testing could not be performed, there was evidence of impaired diaphragmatic function from clinical and radiological assessment.

Both patients had a myopathic basis for their respiratory muscle weakness. The first case was well characterised histologically as inclusion body myositis. The second case had myopathic features, including evidence of mitochondrial dysfunction seen on electron microscopy, but there was no inflammatory component. Mitochondrial dysfunction can be a consequence of antiretroviral treatment,<sup>16</sup> although this patient's myopathy clearly predated her course of lamivudine and her respiratory failure occurred some years after stopping this drug. The biopsies indicated that there may have been a concurrent denervating process in this patient, consistent with previous reports of neuropathy<sup>6,8</sup> and anterior horn cell disease<sup>7</sup> associated with HTLV-I infection.

The myopathogenic mechanism underlying the association with HTLV-I infection is not proven, but has previously been supported by the detection of the virus within inflammatory cells invading muscle tissue in patients with polymyositis<sup>2,17</sup> and inclusion body myositis.<sup>3,4</sup> Our first patient is only the third reported case of HTLV-I associated inclusion body myositis. Furthermore, our two patients are the first reported cases to suggest that HTLV-I infection can cause disease of the proximal and respiratory muscles of such severity as to cause ventilatory failure.

## ACKNOWLEDGEMENTS

We thank Dr S Patel (St Helier Hospital, Carshalton, Surrey, UK), Dr P Rudge, Dr R Howard, Professor D Kullman, and Dr N Hirsch (The National Hospital for Neurology and Neurosurgery), who were involved in the care of the patients described in this report, and members of the Department of Neuropathology, Institute of Neurology for their kind assistance.

## Authors' affiliations

**E T Littleton, W D Man, M G Hanna**, The National Hospital for Neurology and Neurosurgery, University College London Hospitals NHS Trust, Queen Square, London, UK

**J L Holton, D N Landon**, Department of Neuropathology, Institute of Neurology, Queen Square, London, UK

**W D Man, M I Polkey**, Respiratory Muscle Laboratories, Department of Respiratory Medicine, Royal Brompton Hospital, Sydney Street, London, UK

**G P Taylor**, Department of Genito-Urinary Medicine and Communicable Diseases, Imperial College School of Medicine, Norfolk Place, London, UK

Correspondence to: Dr Taylor, Department of Genito-Urinary Medicine and Communicable Diseases, Imperial College School of Medicine, Norfolk Place, London W2 1PG, UK

Received 3 July 2001

In revised form 26 November 2001

Accepted 13 December 2001

## REFERENCES

- Cohen R**, Lipper S, Dantzer DR. Inclusion body myositis as a cause of respiratory failure. *Chest* 1993;**104**:975–7.
- Leon-Monzon M**, Illa I, Dalakas MC. Polymyositis in patients infected with human T-cell leukemia virus type 1: the role of the virus in the cause of the disease. *Ann Neurol* 1994;**36**:643–9.
- Cupler EJ**, Leon-Monzon M, Miller J, et al. Inclusion body myositis in HIV and HTLV-I infected patients. *Brain* 1996;**119**:1887–93.
- Ozden S**, Gessain A, Gout O, et al. Sporadic inclusion body myositis in a patient with human T-cell leukemia virus type-1-associated myelopathy. *Clin Infect Dis* 2001;**32**:510–14.
- Gessain A**, Barin F, Vernant JC, et al. Antibodies to human T-lymphotropic virus type-1 in patients with tropical spastic paraparesis. *Lancet* 1985;**ii**:407–10.
- Doen AG**, Pringle CE, Guberman A. Human T-cell lymphotropic virus type-1 myositis, peripheral neuropathy, and cerebral white matter lesions in the absence of spastic paraparesis. *Arch Neurol* 1997;**54**:896–900.
- Corbin DO**, Mora CA, Garriques S, et al. Anterior horn cell degeneration in polymyositis associated with human T lymphotropic virus type-1 in patients from Barbados. *Am J Trop Med Hyg* 1996;**54**:625–8.
- Smadja D**, Bellance R, Cabre Ph, et al. Clinical characteristics of HTLV-I associated dermatomyositis. Seven cases from Martinique. *Acta Neurol Scand* 1995;**92**:206–12.
- Tosswill JHC**, Taylor GP, Clewley JP, et al. Quantification of proviral DNA load in human T-cell leukaemia virus type-1 infections. *J Virol Methods* 1998;**75**:21–6.
- Amato AA**, Gronseth GS, Jackson CE, et al. Inclusion body myositis: clinical and pathological boundaries. *Ann Neurol* 1996;**40**:581–6.
- Laroche CM**, Carroll N, Moxham J, et al. Clinical significance of severe isolated diaphragm weakness. *Am Rev Respir Dis* 1988;**138**:862–6.
- Hart N**, Cramer D, Ward SP, et al.  $K_{CO_2}$  depends on the distribution of respiratory muscle weakness [Abstract]. *Thorax* 2000;**55**(suppl 3):A52.
- Mier-Jedrzejowicz A**, Brophy C, Moxham J, et al. Assessment of diaphragm weakness. *Am Rev Respir Dis* 1988;**137**:877–83.
- Fitting JW**, Paillex R, Hirt L, et al. Sniff nasal pressure: a sensitive respiratory test to assess progression of amyotrophic lateral sclerosis. *Ann Neurol* 1999;**46**:887–93.
- Braun NMT**, Arora NS, Rochester DF. Respiratory muscle and pulmonary function in polymyositis and other proximal myopathies. *Thorax* 1983;**38**:616–23.
- Peters BS**, Winer J, Landon DN, et al. Mitochondrial myopathy associated with chronic zidovudine therapy in AIDS. *QJM* 1993;**86**:5–15.
- Higuchi I**, Hashimoto K, Matsuoka E, et al. The main HTLV-I-harboring cells in the muscles of viral carriers with polymyositis are not macrophages but CD4+ lymphocytes. *Acta Neuropathol* 1996;**92**:358–61.