

PAPER

Familial motor neurone disease with dementia: phenotypic variation and cerebellar pathology

T M Polvikoski, A Murray, P S Harper, J W Neal

J Neurol Neurosurg Psychiatry 2003;74:1516–1520

See end of article for authors' affiliations

Correspondence to:
Dr Alex Murray, Institute of Medical Genetics, University Hospital of Wales, Heath Park, Cardiff CF14 4XN, UK;
alex.murray@uhw-tr.wales.nhs.uk

Received 4 November 2002
In revised form
13 March 2003
Accepted 14 March 2003

Objectives: To characterise the neuropathological phenotypes of two affected individuals from a family with an unusual clinical phenotype resembling motor neurone disease and dementia.

Methods: Histological sections of cerebral cortex, basal ganglia, brain stem, cerebellum, and spinal cord were stained with haematoxylin-eosin, luxol fast blue, silver stains, anti-tau, anti-ubiquitin, anti- α -synuclein, and anti-neurofilament.

Results: Numerous ubiquitin positive, tau and α -synuclein negative intraneuronal inclusions were present in the cerebral cortex (particularly within the dentate gyrus), cerebellar cortex, brain stem, and spinal cord. The cerebellar ubiquitinated inclusions were located in the proximal dendrite of the Purkinje cells. Loss of Purkinje cells and occasional silver and neurofilament positive axonal swellings (torpedoes) were also seen within the cerebellar cortex. The main difference between the two cases was the severity of the spinal cord involvement: no significant pathology was present within one, but obvious motor neurone disease within the other.

Conclusions: The clinical and neuropathological findings in this family are best described as an example of familial motor neurone disease with dementia. Intraneuronal ubiquitin inclusions together with agyrophilic, neurofilament positive torpedoes were present within the cerebellar cortex, both previously unrecognised findings in this group of diseases.

Motor neurone disease is characterised clinically as a progressive disorder affecting both the upper and lower motor neurones.¹ The main histological change is the loss of motor neurones in the anterior horns of the spinal cord, the brain stem, and the motor cortex.² Ubiquitin containing intraneuronal inclusions are present in virtually all cases and can be found in the nuclei of upper and lower motor neurones.³

In 3–5% of cases of motor neurone disease, there is also dementia,⁴ particularly of the fronto-temporal type.⁵ Milder cognitive deficits, especially those related to language and fluency of speech, are more common.⁶ Motor neurone disease with fronto-temporal dementia is characterised pathologically by ubiquitinated intraneuronal inclusions within the hippocampal dentate fascia and fronto-temporal cortex, in addition to the typical findings of motor neurone disease.⁷ However, this type of cortical pathology may also be present in other neurological disorders.^{8–10} It has been suggested that neurological diseases with intraneuronal ubiquitin positive, tau and α -synuclein negative inclusions form a spectrum with overlapping pathological features.¹¹

We report a familial neurological disease associated with autosomal dominant inheritance, with a variable clinical and neuropathological phenotype manifesting clinically mainly as gait disturbance, repeated falls, cranial nerve involvement, and frontal lobe dysfunction. In affected individuals the disease progressed rapidly, with death in the forties or early fifties. In addition to the common pathological findings in individuals with motor neurone disease and dementia, the cerebellum appeared to be involved in this disease.

METHODS

Clinical characteristics

The clinical information was obtained from detailed clinical notes documenting the neurological signs and symptoms found in three generations of this family.

The six affected family members within three generations were all female (fig 1). The common features in all six family members suffering from the disease were difficulty in walking and repeated falls (table 1). Three cases had frontal lobe symptoms (emotional disinhibition, self neglect, or agitation), upper motor neurone symptoms (rigidity, spasticity, or brisk reflexes), and cranial nerve symptoms (swallowing problems or ophthalmoplegia) (table 1). Two cases showed lower motor neurone symptoms (muscle fasciculation, atrophy, or distal limb weakness) and Parkinsonism (table 1). Clinically noted dementia and cerebellar intention tremor each occurred in one case (table 1).

The age of onset varied from 41 to 52 years (mean 44 years). The disease progressed very rapidly: five of the six family members suffering from the disease died within two years of the onset of symptoms.

The two subjects who had necropsy and a neuropathological examination were cases 5 and 6 (see fig 1 and tables 1 and 2).

Histology

The brains and spinal cords were fixed in 10% formalin before being cut and processed for paraffin embedding. Histological preparations from the cerebral cortex, basal ganglia, brain stem, cerebellum, and various levels of the spinal cord were stained with haematoxylin and eosin (H&E), Luxol fast blue, Bielschowsky and Gallay's stains, anti-tau (1/500, Dako), anti-ubiquitin (1/250, Dako), anti- α -synuclein (1/80, Novocastra), anti-GFAP (1/1500, Dako), and two types of anti-neurofilament (Sigma: 200 kDa, phosphorylated and non-phosphorylated 1/800; ICN Pharmaceuticals: 70 kDa and 200 kDa 1/160). Professor J W Ironside, Department of Neuropathology, University of Edinburgh, kindly undertook staining with an anti-prion protein antibody in case 6.

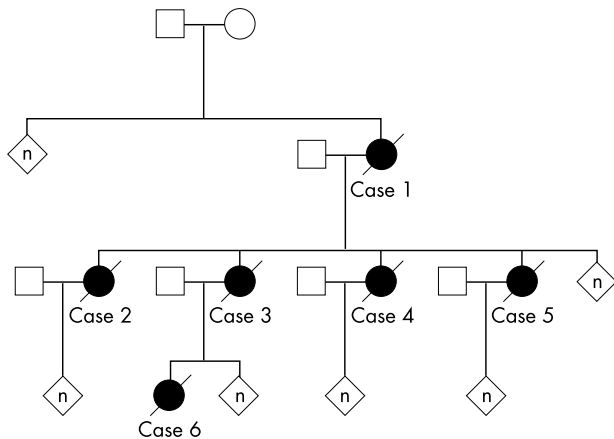


Figure 1 The family pedigree showing the affected family members (cases 1–6). All details of unaffected family members have been omitted.

Molecular genetics

Molecular analysis for a potential prion protein mutation was kindly done by Professor J Collinge, MRC Prion Unit, Department of Neurodegenerative Diseases, University College, Institute of Neurology, London (case 5). Superoxide dismutase mutation analysis was carried out and SCA 1 triplet repeat analysis performed in the Institute of Medical Genetics, Cardiff (case 6).

RESULTS

Macroscopic pathological findings

Case 5

The brain was atrophic, weighing only 800 g. There was atrophy of the cerebral cortex, in particular the frontal lobes. The cerebellar hemispheres also appeared to be atrophic. Coronal sections showed evidence of ventricular dilatation but the caudate and other nuclei of the basal ganglia were neither atrophic nor discoloured. The midbrain contained pigmented cells in the substantia nigra. The spinal cord on horizontal sectioning was significantly atrophic, as were the individual spinal nerves.

Table 2 The neuropathological findings of the cases 5 and 6

Anatomical site	Case number	
	5	6
Cerebral cortex		
Microvacuolar change		+
Intraneuronal inclusions ¹		
Temporal cortex	++	++
Dentate gyrus	+++	+++
Ubiquitinated neuritis	++	++
Substantia nigra		
Neurone loss	(+)	(+)
Intraneuronal inclusions ¹	-	-
Cerebellum		
Purkinje cell loss	++ (focal)	++ (focal)
Intraneuronal inclusions ¹	+	+
Axonal swellings (torpedoes)	+	+
Hypoglossal nucleus		
Intraneuronal inclusions ¹	++	+
Spinal cord		
Anterior horn neurone loss	+++	-
Intraneuronal inclusions ¹	+	(+)
Loss of myelin staining	++	-

¹Ubiquitin positive, tau and α -synuclein negative inclusions. (+), very mild pathology or uncertain finding; +, mild pathology; ++, moderate pathology; +++, severe pathology.

Case 6

The brain of weight 1350 g was of normal external appearance with little evidence of severe cortical or lobar atrophy. The cerebellar hemispheres were of a normal appearance and the midbrain contained a pigmented substantia nigra. Coronal sections showed no evidence of ventricular dilatation, and the caudate nuclei and basal ganglia were of normal appearance. The spinal cord was of normal transverse diameter, with no evidence of spinal nerve atrophy.

Microscopic pathological findings

These are shown in table 2.

Cerebral cortex

H&E stained sections showed mild microvacuolar change (spongiosis) within the frontal cortex, particularly in layers

Table 1 Clinical characteristics of the patients

Case number ^(a)	Age of onset (years)	Age at death (years)	Time interval from the age of onset to death (years)	Main clinical features
1	45	47	2	Problems with gait, speech, and swallowing
2	41	43	2	Problems with gait and repeated falls; "parkinsonism"
3	52	53	1	Difficulties with walking; black-outs; problems with swallowing and speech; loss of upward gaze and ptosis; bilateral facial weakness; tongue and muscle fasciculation with atrophy; emotional disinhibition
4	42	43	1	Repeated falls and dizziness; bilateral facial weakness and ptosis; brisk reflexes; distal limb weakness
5	41	47	6	Repeated falls; progressive spasticity with increasingly brisk reflexes; rigidity; tremor and bradykinesia; immobile face; self neglect; progressive cognitive decline
6	45	46	1.5	Unsteady gait; increased tone in all four limbs with cerebellar intention tremor; anorexia; agitation, paranoia, and depression

^(a)See fig 1.

II–III. No neuronal or glial inclusions were noted on sections stained with silver stains (Gallyas and Bielschowsky) and antibodies to ubiquitin, tau, and α -synuclein. Senile amyloid plaques and neurofibrillary tangles were absent from the neocortex and hippocampus. In case 6, anti-PrP staining did not reveal prion positive plaques. However, in both cases neurones with ubiquitin positive intraneuronal inclusions were present in the insular and temporal cortices and were especially numerous within the granular cells of the hippocampal dentate gyrus. Many ubiquitin positive cortical neurites were also present in the insular and temporal cortices of both cases. No significant abnormality was seen within the cortical white matter.

Brain stem

In both cases the substantia nigra and locus coeruleus were well preserved, with only an occasional focus of extraneuronal pigment and mild microvacuolar change. The sections of the medulla, pons, and midbrain stained with tau, neurofilament, or α -synuclein antibodies did not show intraneuronal inclusions. The olivary nuclei were not atrophic. However, in both cases (although more numerous in case 5), ubiquitin positive intraneuronal inclusions were present in the hypoglossal nuclei.

Cerebellum

Focal Purkinje cell loss was present in the cerebellar hemispheres of both cases as shown by anti-neurofilament staining (fig 2). Bielschowsky staining demonstrated axonal torpedoes within the granular layer of the cerebellum in both cases (fig 3). In case 6 the agyrophilic torpedoes were positively stained with two different monoclonal anti-neurofilament antibodies (70 kDa and 200 kDa). Anti-ubiquitin staining in both cases showed Purkinje cells

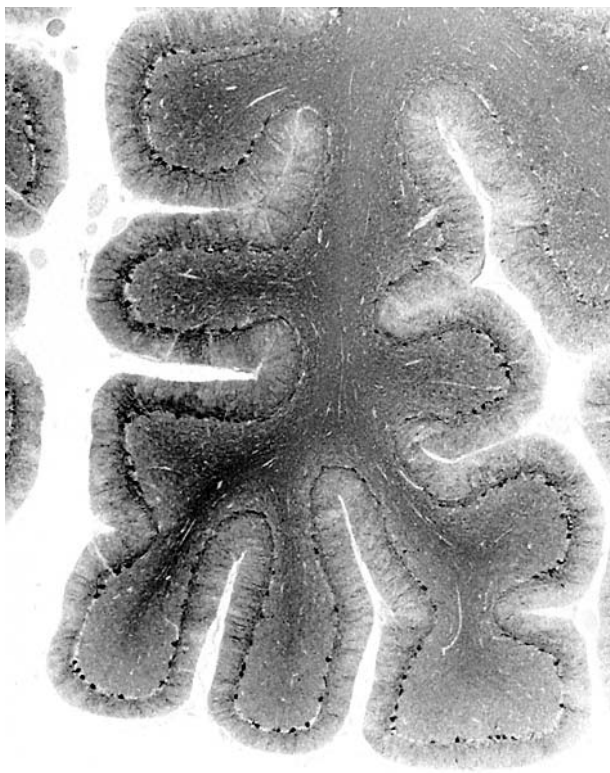

Figure 2 A coronal section through the hemisphere of the cerebellum (case 6) showing cortical atrophy and loss of individual Purkinje neurones stained with anti-neurofilament antibody.

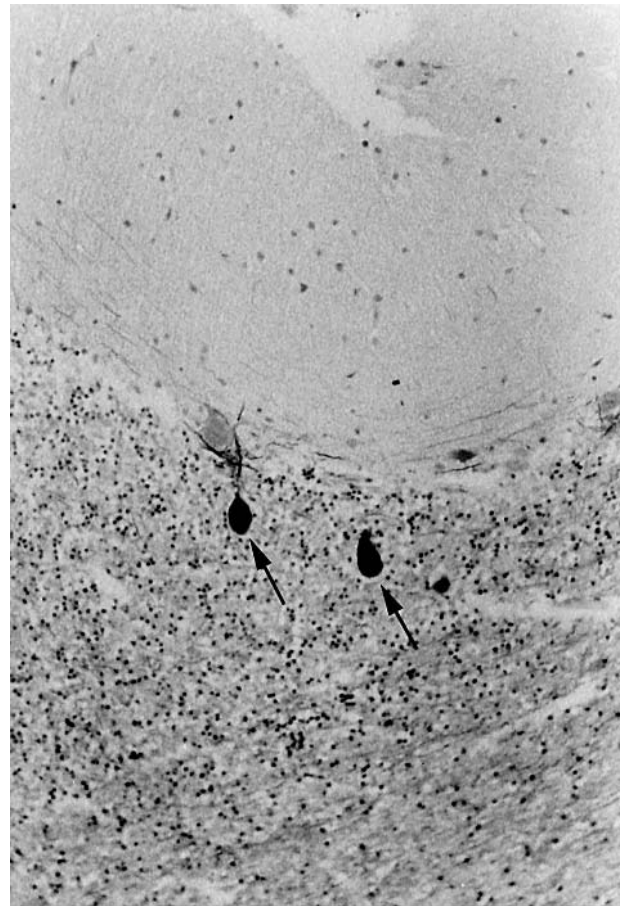


Figure 3 Cerebellar cortex (case 6) stained with Bielschowsky stain demonstrating axonal torpedoes (arrows) in the granular cortex.

containing ubiquitin positive skein-like inclusions within their proximal dendrites. Purkinje neurones containing these ubiquitin positive inclusions were present throughout the cerebellar cortex (fig 4). Bergmann gliosis, as demonstrated by anti-GFAP staining, was present in the molecular layer of the cerebellar cortex in both cases. There was no evidence for anti-tau or α -synuclein staining inclusions in the cerebellar cortex from either case.

Basal ganglia

The individual nuclei of the basal ganglia including the globus pallidus were free of ubiquitin positive intraneuronal inclusions.

Spinal cord

The spinal cord was significantly reduced in cross sectional diameter in case 5, and there was evidence of reduced staining for myelin in the corticospinal tracts at the level of the thoracic cord, with loss of neurones from the anterior horns. A few remaining neurones in the anterior horn contained globose ubiquitin positive inclusions. The neurones in the autonomic nuclei and Clarke's column were preserved. By contrast the spinal cord in case 6 was not significantly reduced in cross sectional diameter. No obvious anterior horn cell loss was present in the spinal cord and there was no myelin pallor seen in LFB stained sections. Multiple sections at different levels of the spinal cord were stained with anti-ubiquitin. Only one large neurone in the anterior horn contained a possible ubiquitin positive globose inclusion attached to the cell membrane.

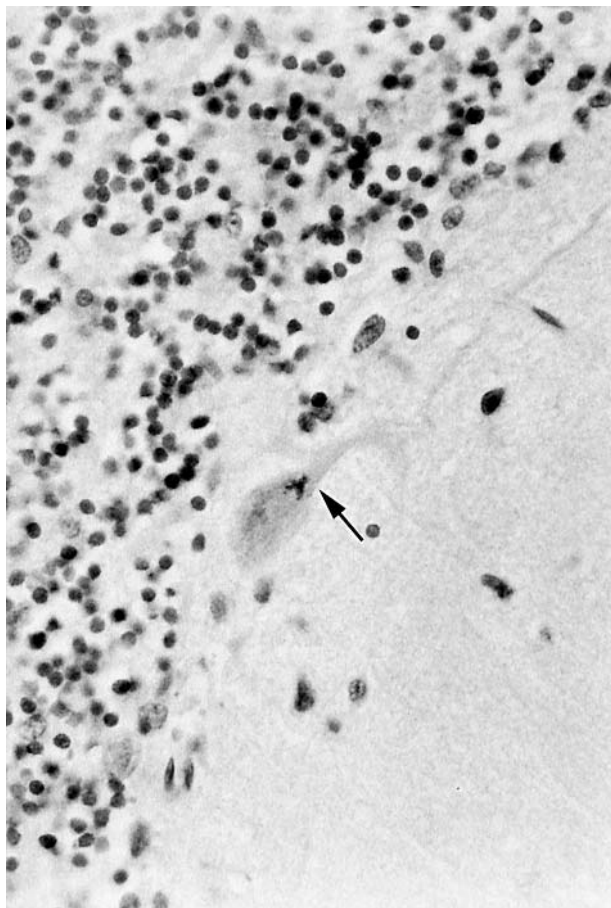


Figure 4 Purkinje neurone (case 6) containing a ubiquitin stained inclusion (arrow), located in the proximal dendrites.

Molecular genetics

There was no evidence of a SOD 1 mutation on superoxide dismutase mutation analysis. Only SCA 1 triplet repeat expansion analysis was carried out and no expansion was identified. There was also no evidence of a mutation in the prion protein gene on complete sequencing (case 6).

DISCUSSION

The family pedigree shows an autosomal dominant pattern of inheritance (fig 1) with death of affected family members occurring between 43 and 53 years of age (table 1). The clinical signs and symptoms were variable, the disease involved both lower and upper motor neurones, cranial nerves, cerebral cortex, and the cerebellum with varying clinical severity in different family members. The distribution of neuropathological changes within the brain in both cases was similar, but the severity differed, with marked neurone loss from the spinal cord in case 5 compared with case 6. The explanation for the marked brain and spinal cord atrophy in case 5 is not clear but it correlates with a six year survival from the onset of neurological signs (table 1). In case 6, neither the brain nor spinal cord was atrophic, reflecting the comparatively short survival interval of only 18 months in this individual.

The differential diagnosis included motor neurone disease with dementia, chromosome 17 linked fronto-temporal dementia with Parkinsonism, spinocerebellar degeneration, corticobasal degeneration, and multisystem atrophy (MSA). The rapid progression of the dementia also raised the possibility of a prion related disease. However, subsequent

neuropathological examination excluded the possibility of the tauopathies, α -synucleopathies, and MSA. Although some cortical microvacuolation was present in the superficial laminae of the frontal cortex, prion protein immunostaining (case 6) was negative, and molecular analysis of the prion protein gene failed to identify a mutation, excluding the possibility of familial Creutzfeldt-Jakob disease. In addition, screening of SCA1 and SOD 1 (case 6) did not detect any mutations.

Immunohistochemical staining for ubiquitin showed intraneuronal inclusions in the cerebral cortex, dentate gyrus of the hippocampus, hypoglossal nuclei, Purkinje cells (fig 4), and anterior horn cell neurones. There was little evidence for either neuronal loss or the presence of intraneuronal ubiquitin positive inclusions in the substantia nigra and basal ganglia nuclei from either case.

The neuropathological findings supported the diagnosis of familial motor neurone disease with dementia. Different names for this entity and its variants have been used in published reports—for example, “familial frontotemporal dementia with ubiquitin positive, tau negative inclusions”,¹² “motor neurone disease inclusion-dementia (MNDID)”,⁸ and “motor neurone disease inclusion body dementia”.¹³ The cortical variant (MNDID) is a dementing disorder with cortical intraneuronal ubiquitinated inclusions but without motor neurone disease, and seems to represent one possible phenotype of a disease involving the cerebral cortex and other areas of the central nervous system with varying severity.^{14 15} In the study of a family with MNDID, only one family member had this diagnosis confirmed at necropsy. The other members of the same family had clinical evidence consistent with motor neurone disease or motor neurone disease with dementia, which suggests that in this family the disease involved multiple areas of the central nervous system.⁸ The variation in the clinical phenotype was also present in the family that we describe (table 1), and this corresponded to the severity of the pathological involvement of the spinal cord in the two cases, as confirmed by neuropathological examination (table 2).

The genetic basis for familial motor neurone disease with dementia and MNDID is different from pure motor neurone disease because mutations in the superoxide dismutase (SOD 1) gene, which are the most common mutations causing motor neurone disease, very rarely exist with dementia or cortical intraneuronal inclusions.^{16 17} Similarly, no SOD 1 mutation was detected in the family we report. In addition, mutations in the tau gene on chromosome 17 have not been found to be associated with either familial motor neurone disease with dementia or cases with cortical intraneuronal ubiquitinated inclusions.¹² In contrast, familial motor neurone disease with dementia has been linked to the q21–22 region on chromosome 9,¹⁸ although other research groups have not confirmed this linkage. Unfortunately, the neuropathological information in this study was not sufficiently detailed to allow a comparison with the two cases we report.¹⁸

One interesting observation in cases 5 and 6 was the involvement of the cerebellar cortex. Although the spinocerebellar tracts can be affected in motor neurone disease,¹⁹ involvement of the cerebellar cortex is rarely mentioned, and cerebellar involvement is not described in motor neurone disease with dementia or in MNDID.^{12 14 15 20} This is somewhat surprising, because the cerebellar cortex is closely involved in the coordination of movement and extrapyramidal pathways that control muscle function. In the cases we report there was a significant but unevenly distributed loss of the Purkinje cells from the cerebellar cortex (fig 3). Furthermore, several Bielschowsky positive and neurofilament positive axonal torpedoes were present at the boundary between molecular and granular layers (fig 4), and occasional

remaining Purkinje cells contained skein-like ubiquitinated inclusions in their proximal dendrites (fig 4), similar to the inclusions described in the anterior horn motor neurones in motor neurone disease.² To our knowledge, there are no reports describing either ubiquitinated inclusions or the accumulation of neurofilament proteins in Purkinje cells in motor neurone disease with dementia. Aberrant accumulation of neurofilaments has been reported in motor neurone disease, especially in axons of motor neurones and perikarya of neurones, but this could represent a secondary effect rather than the cause for the neuronal degeneration.²¹

Conclusions

The clinical and neuropathological phenotype of familial motor neurone disease with dementia is variable, and the disease involves several functionally related regions within the central nervous system, including the cerebral cortex, cerebellar cortex, brain stem, and spinal cord.

Authors' affiliations

T M Polvikoski, J W Neal, Department of Histopathology, University Hospital of Wales, Heath Park, Cardiff, UK

A Murray, P S Harper, Institute of Medical Genetics, University Hospital of Wales

Competing interests: none declared

REFERENCES

- Brooks BR. El Escorial World Federation of Neurology criteria for the diagnosis of amyotrophic lateral sclerosis. *J Neural Sci* 1994;**124**(suppl):96–107.
- Lowe JS, Leigh N. Motor neuron disease. In: Graham DI, Lantos PL, eds. *Greenfield's neuropathology*, 7th ed. London: Arnold, 2002:372–83.
- Leigh PN, Whitwell H, Garafalo O, et al. Ubiquitin-immunoreactive intraneuronal inclusions in amyotrophic lateral sclerosis. *Brain* 1991;**114**:775–88.
- Al Chalabi A, Leigh PN. Recent advances in amyotrophic lateral sclerosis. *Curr Opin Neurol* 2000;**13**:397–405.
- Neary D, Snowden JS, Mann DMA, et al. Frontal lobe dementia and motor neuron disease. *J Neural Neurosurg Psychiatry* 1990;**53**:23–32.
- Rakowicz WP, Hodges JR. Dementia and aphasia in motor neuron disease: an underrecognised association? *J Neural Neurosurg Psychiatry* 1998;**65**:881–9.
- Wightman G, Anderson VER, Martin J, et al. Hippocampal and neocortical ubiquitin-immunoreactive inclusions in amyotrophic lateral sclerosis with dementia. *Neurosci Lett* 1992;**139**:269–74.
- Jackson M, Lennox G, Lowe J. Motor neuron disease inclusion-dementia. *Neurodegeneration* 1996;**5**:339–50.
- Rossor MN, Revesz T, Lantos PL, et al. Semantic dementia with ubiquitin-positive tau-negative inclusion bodies. *Brain* 2000;**123**:267–76.
- Kinoshita A, Tomimoto H, Tachibana N, et al. A case of primary progressive aphasia with abnormally ubiquitinated neurites in the cerebral cortex. *Acta Neuropathol* 1996;**92**:520–4.
- Ince PG, Lowe J, Shaw PJ. Amyotrophic lateral sclerosis: current issues in classification, pathogenesis and molecular pathology. *Neuropathol Appl Neurobiol* 1998;**24**:104–17.
- Kertesz A, Kawarai T, Rogaeva E, et al. Familial frontotemporal dementia with ubiquitin-positive tau-negative inclusions. *Neurology* 2000;**54**:818–27.
- Al-Sarraj S, Kibble MM, Everall I, et al. Ubiquitin-only intraneuronal inclusion in the substantia nigra is a characteristic feature of motor neuron disease with dementia. *Neuropathol Appl Neurobiol* 2002;**28**:120–8.
- Holton JL, Revesz T, Crooks R, et al. Evidence for pathological involvement of the spinal cord in motor neuron disease-inclusion dementia. *Acta Neuropathol* 2002;**103**:221–7.
- Grimes DA, Bergeron CB, Lang AE. Motor neuron disease-inclusions dementia presenting as cortical-basal ganglionic degeneration. *Mov Disord* 1999;**14**:674–80.
- Mase G, Gemma A, Bonfigli L, et al. ALS with variable phenotypes in a six-generation family caused by leu144phe mutation in the SOD1 gene. *J Neural Sci* 2001;**191**:11–18.
- Andersen P, Forsgren L, Binzer M, et al. Autosomal recessive adult-onset amyotrophic lateral sclerosis associated with homozygosity for Asp90Ala CuZn-superoxide dismutase mutation. A clinical and genealogical study of 36 patients. *Brain* 1996;**119**:1153–72.
- Hosler BA, Siddique T, Sapp PC, et al. Linkage of familial amyotrophic lateral sclerosis with frontotemporal dementia to chromosome 9q21–22. *JAMA* 2000;**284**:16664–9.
- Swash M, Scholz C, Vowks G, et al. Selective and asymmetrical vulnerability of corticospinal and spinocerebellar tracts in motor neuron disease. *J Neural Neurosurg Psychiatry* 1988;**51**:785–9.
- Hirano A, Kurland LT, Sayre GP. Familial amyotrophic lateral sclerosis. A subgroup characterized by posterior and spinocerebellar tract involvement and hyaline inclusions in the anterior horn cells. *Arch Neurol* 1967;**16**:232–43.
- Hand CK, Rouleau A. Familial amyotrophic lateral sclerosis. *Muscle Nerve* 2002;**25**:135–59.