

PHYSICAL SIGNS

The deep tendon and the abdominal reflexes

J P R Dick

The deep tendon reflexes (and the abdominal reflexes) are important physical signs which have a special place in neurological diagnosis, particularly in early disease when they alone may be abnormal. They act as "hard" signs in situations where clinical assessment is complicated by patient anxiety, and become more useful as clinical experience develops.

Eliciting the deep tendon reflexes is one of the main components of the clinical examination of the nervous system. It aids anatomical diagnosis, the essential first step in the neurological diagnostic process, and gives an important pointer to whether a patient's disorder arises from the central or peripheral nervous system. Taken in conjunction with the overall clinical picture they are useful but extremely variable and may be misleading if used on their own.

HISTORY

Robert Whytt (1763) noticed that muscle activation could be caused by stretch¹ and Erb and Westphal (1875) first emphasised their usefulness in identifying an abnormality of the central nervous system.² Gowers was the first to use the term knee jerk, and Sherrington (1897) coined the term synapse.³ By the turn of the last century, Sherrington³ had demonstrated the physiological anatomy of the monosynaptic reflex arc, of reciprocal inhibition, and of propriospinal neurones. Synaptic mechanisms themselves were subsequently analysed with extracellular and intracellular microelectrodes by Eccles.⁴ Parallel phenomena have been demonstrated in man using H reflex techniques.⁵

PHYSIOLOGY OF THE NORMAL REFLEX

Microneurography shows that the tendon "tap" evokes a relatively synchronous volley in the fastest conducting afferent fibres from the muscle spindles.⁶ There is a temporal dispersion of up to 20 ms in this afferent volley and a jitter of 5–6 ms in the timing of homonymous motor unit firing.⁶ Theoretically, this would be a sufficient time spread for motor neurone firing to be the consequence of several afferent signals (temporal summation) or even of disynaptic input.⁵ However, the 1a afferent fibres synapse directly onto the proximal dendrites and soma of the motor neurone, and latency measurements following intraspinal stimulation make it extremely likely that the tendon reflex is monosynaptic.⁵

The afferent volley evokes excitatory postsynaptic potentials in a variety of spinal neurones, largely in the interneurons at the relevant

J Neurol Neurosurg Psychiatry 2003;**74**:150–153

segmental level, but also in the motor neurones. A proportion of these (and some motor neurones at neighbouring levels) will be sufficiently close to their firing threshold for this phasic excitatory input to discharge them. That proportion will be determined by the interplay of descending reticulospinal, vestibulospinal, and corticospinal pathways.

The muscle activity evoked by a tendon "tap" differs from that evoked by a "stretch." The latter is more sustained while the former is really a vibratory stimulus; as such it is misleading to refer to the tendon jerks as stretch reflexes. Formally these two stimuli cause a phasic and a tonic stretch of muscle; thus the deep tendon reflexes should be known as phasic stretch reflexes. The tonic stretch reflex is appreciated clinically in the examination of tone.

In the physiological literature the phasic stretch reflex is called the short latency reflex to stretch (with a latency of ~25 ms to the hand). This distinguishes it from the long latency reflex to stretch (with a latency of ~50 ms to the hand). The long latency reflex to stretch is thought to be mediated through an oligosynaptic transcortical pathway.^{7–9}

The H reflex

The H reflex is the electrical equivalent of the tendon jerk, bypassing fusimotor drive and the potentially variable intrafusal muscle tension of the muscle spindle (fig 1). Physiological analysis of the monosynaptic reflex arc in man has relied on the use of the H reflex,¹⁰ though experimental models using a standard "tendon tap" have been devised.¹¹ Analysis of the difference in the behaviour of the H reflex and the tendon jerk has allowed a discussion of the role of fusimotor drive in spasticity, rigidity, and spinal shock.^{5 12 13} The role played by γ efferent activity in the generation of spasticity is probably less important than was at one time assumed by the servo theory of movement control, originally put forward by Eldred *et al.*¹³

As the afferent 1a fibres have a lower threshold for electrical stimulation than the α motor neurones, it is possible to evoke an H reflex with an electrical stimulus that is insufficient to evoke an M response (fig 1, top trace). Paired or conditioning stimuli are used to interrogate the excitability characteristics of a motor neurone pool and can demonstrate the effect of impulses arriving near simultaneously from supraspinal centres, antagonist muscles, or from other limbs.⁵ Such studies in man have contributed considerably to the understanding of interneurone behaviour, intraspinal reflex mechanisms (for example, presynaptic, reciprocal, and recurrent inhibition), and the role of the reticulospinal, vestibulospinal, and corticospinal pathways.

Correspondence to:
J P R Dick, Greater
Manchester Neuroscience
Centre, Hope Hospital,
Salford M8 6HD, UK;
jeremy.dick@
smuht.nwest.nhs.uk

Received 15 March 2002
In revised form 4
September 2002
Accepted 26 September
2002

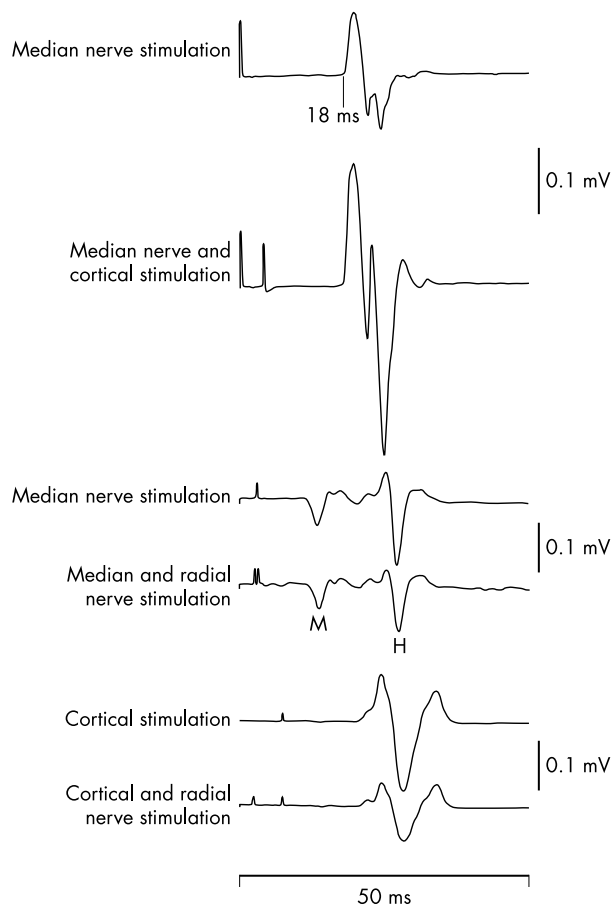


Figure 1 All traces represent muscle activity recorded from surface EMG electrodes over wrist flexor muscles in the medial forearm. The top four traces are H reflexes derived from single trials; the bottom two are equivalent sized EMG responses averaged over 10 trials from a single subject. The top trace shows an H reflex following median nerve stimulation in the cubital fossa (note no M wave) and the second trace shows the H reflex modulated by a subthreshold cortical stimulus (probably through a monosynaptic cortico-motoneuronal pathway). The third trace shows some background muscle activity and both an M wave and an H reflex following median nerve stimulation in the cubital fossa. In the fourth trace a radial nerve shock is given 0.5 ms earlier than the median nerve shock (see stimulus artefact). The resulting H reflex is partially inhibited. Similar inhibition is demonstrated in the fifth and sixth traces. A just suprathreshold cortical stimulus is given alternately, either alone (fifth trace) or with a preceding radial nerve shock (sixth trace) over 20 trials. The resulting average traces show radial nerve inhibition of forearm flexor motor neurones. This reciprocal inhibition is mediated by the "1a inhibitory interneurone." (Adapted with permission from Cowan *et al.*¹⁴ and Berardelli *et al.*¹⁵)

CLINICAL

The deep tendon reflexes—in contrast to the superficial cutaneously evoked reflexes (for example, the plantar response and the abdominal, anal, bulbocavernosus, and cremasteric reflexes)—are elicited by a short, sharp blow with a tendon hammer delivered to the tendon of a gently extended muscle.¹⁶ They are difficult to elicit from a contracting muscle (in an anxious patient) or from a flaccid muscle (limb in the wrong position). In their afferent arc they are carried by large myelinated sensory neurones, whereas the superficial reflexes use small diameter, slow conducting paths.

The tendon reflexes should be elicited in an identical fashion, with the patient relaxed using a soft tendon hammer.^{16, 17} For the biceps and brachioradialis jerks it is possible to use one's own finger to cushion the blow. This allows palpation of activity in the biceps tendon which might otherwise be invisible.

Tendon reflexes are brisk in the newborn (the plantar responses are extensor until 18 months of age), though they become more difficult to elicit over the following decade.¹¹ Primitive reflexes should have disappeared by four months of age, including the tonic neck reflex. In early neonatal life the excitatory 1a volley (as well as excitatory corticospinal activity) goes to many segmental motor neurone and interneurone pools, including direct connections to the antagonist muscles. During development there is a reorganisation of these synaptic inputs. For instance, the corticospinal input becomes restricted to synergistic muscles during the first four postnatal years, though it may not in patients who subsequently develop cerebral palsy.¹¹

In the adult neurological examination, it is customary to assess the tendon jerks of biceps brachii, brachioradialis (often called the supinator jerk¹⁶), triceps brachii, and the long finger flexors, reflecting successive spinal root levels. In the lower limb, the patellar reflex (quadriceps) and the ankle jerk (triceps surae) are examined. The jaw jerk is assessed as part of the cranial nerve examination. Phasic stretch reflexes can be obtained from other muscles, particularly when the patient has generally brisk reflexes (for example, thigh adductor, pectoralis, and deltoid muscles). These additional reflexes can be used for localising the level of a lesion in the spinal cord.^{18, 19}

VARIABILITY

Reflexes may be difficult to elicit in normal subjects owing to global hypoexcitability of ventral horn motor neurones. Under these circumstances, motor neurones may be rendered more excitable by the Jendrassik manoeuvre (reinforcement). This was originally thought to enhance fusimotor drive, though it is now thought to reflect a direct excitatory effect on the α motor neurones.^{20, 21}

It has been suggested that absent ankle jerks may not be abnormal in the elderly. However, only 6% of normal subjects over the age of 65 have absent ankle jerks.^{22, 23} A recent study has focused attention on the technique for eliciting the ankle jerk in elderly people, suggesting that plantar strike is more effective than tendon strike.²⁴

While the presence of pathologically brisk or completely absent deep tendon reflexes has clear significance, their natural variability can make interpretation difficult in day to day clinical practice. Thus a degree of asymmetry between each side is allowable²⁵ and can even be influenced by volition²⁶ or by the tonic neck reflex in the neonate. Equally, very brisk reflexes—even with a few beats of clonus and some spread to other synergistic motor neurone pools—can be seen in anxious individuals, as well as in hyperthyroidism (and in tetany).

It is customary, therefore, to interpret the significance of the reflex examination in the context of other physical signs, such as the muscle tone and the superficial reflexes. Thus a reflex may be either inappropriately dull (in comparison with other deep tendon reflexes) or pathologically brisk, when one would expect it to be associated with reflex spread to other motor neurone pools, increased muscular tone, and extensor plantar responses.

For research purposes the American Academy of Neurology (AAN) has defined five grades of reflex intensity: 0, absent; 1, present but small, may only be brought out by reinforcement; 2, present in the lower half of the normal range; 3, present in the upper half of the normal range; 4, reflex enhanced, including clonus which may be added as a verbal description. This grading has been criticised by Bradley,²⁷ who proposed six grades to give a better description of what is seen clinically: 0, absent; 1±, present only with reinforcement; 2, present but depressed; 3, normal; 4, increased; 5, sustained clonus. The AAN criteria have been validated^{28, 29} and are increasingly accepted.

EXAGGERATED REFLEXES

Physiology

Erb and Westphal showed that brisk deep tendon reflexes are the hallmark of overactive spinal reflex mechanisms. Sherrington suggested that this was mediated by inadequate supraspinal inhibition. Fellows *et al* demonstrated that phasic and tonic stretch reflexes are inhibited during normal gait, probably by presynaptic 1a inhibition. This inhibition is defective in patients with spasticity.³⁰ H reflex studies (using conditioning stimuli) have shown the emergence of excess reflex activity during a variety of voluntary movements.^{31–33}

It has been suggested that 1a monosynaptic excitation may be augmented in spasticity,⁵ perhaps because of exuberant axonal sprouting of the terminal arbor of the 1a sensory neurones following corticospinal tract denervation. However, Krenz and Weaver³⁴ showed that following thoracic cord section the majority of afferent sprouting occurs in Rexed's laminae III–V. This occurs simultaneously with the development of autonomic dyssynergia, a clinical correlate of recovery in the rat. They concluded that any alteration in input to the ventral horn motor neurones was likely to take place by way of spinal interneurons. This is more consistent with the physiological data which show that several of the inhibitory systems contribute to the overactivity of spastic and antagonist muscles during voluntary movement.³³

Clinical

Pathologically brisk deep tendon reflexes may be the earliest sign of a corticospinal tract disturbance. They become associated with sustained clonus and increased muscular tone as the pathology progresses. Awareness of their clinical significance is therefore paramount in neurological practice.

They can be evoked by a much smaller tendon tap than normal, occur at a slightly shorter latency, and reflex muscle activity is seen in neighbouring motor neurone pools (reflex irradiation, pathological spread). These other motor neurone pools are usually those of synergistic muscles. Thus with a tendon tap to biceps brachii there may be wrist pronation; with a tendon tap to triceps brachii, wrist extensors may be activated; with a tendon tap to quadriceps there may be ankle plantar flexion; with a tendon tap to triceps surae, ipsilateral (normal) and contralateral (abnormal) thigh adductor muscles may be activated. The mechanical disturbance from the tendon hammer blow is transmitted to the spindle afferents of distant muscles,³⁵ but synergistic muscles are activated preferentially, as their motor neurones are closer to threshold than those of the antagonist muscles. In routine practice, if biceps activation can be seen from tapping the radius, it is unnecessary to tap the biceps reflex separately as the integrity of that root has already been established.³⁵

ABSENT REFLEXES

Deep tendon reflexes may be absent when either the afferent volley is unable to access the spinal cord (sensory polyneuropathy, the spinocerebellar degenerations, root avulsion) or when the resulting efferent volley is unable to access the muscle (motor neuronopathy, radiculopathy, and certain neuromuscular junction disorders such as the Lambert Eaton myasthenic syndrome).

The distribution of absent reflexes will usually allow an anatomical diagnosis to be made, particularly if a radiculopathy is suspected. In large fibre neuropathies the ankle jerks are usually lost before the patellar and arm jerks, whereas in small fibre neuropathies (for example, in amyloid neuropathy) the deep tendon reflexes may be retained despite quite extensive peripheral sensory disturbance.

The quality of the deep tendon reflexes may be influenced by other disease processes. In hypothyroidism, hypothermia, or β blockade the relaxation phase of the ankle jerk may be prolonged, and in cerebellar disease the knee jerks evoked in

the sitting position are said to be pendular (reflecting hypotonia). In Huntington's disease, quick repetitive tapping of the patellar tendon may lead to the quadriceps muscle developing choreiform contractions, causing the so called "hung-up knee jerk."

In the Holmes Adie syndrome, absent deep tendon reflexes persist, even in the presence of spinal cord dysfunction. In the case reported by Swash and Earl³⁶ it was possible to access the α motor neurones through cutaneous sensory pathways (easily evoked flexor spasms) but not with stretch stimuli (absent reflexes, hypotonia). They suggested that there was an excess of presynaptic inhibition on afferent 1a input to ventral horn motor neurones.

In lesions of the cervical spinal cord—often caused by disease of the spinal column—one can see a combination of absent deep tendon reflexes at one anatomical level and brisk deep tendon reflexes at more caudal levels. Thus in multilevel cervical spondylotic myelopathy the deep tendon reflexes in the legs may be pathologically brisk while those in the arms may all be absent. In the presence of a single disc protrusion at C5/6, the triceps jerk may be pathologically brisk in the absence of biceps and brachioradialis jerks.¹⁷ Not infrequently, there is also an inverted supinator jerk (the inverted radial reflex), in which tapping the brachioradialis tendon causes finger flexion and occasionally some triceps activity³⁵ but no activity in brachioradialis, as there is ventral root disturbance at C6. With disc protrusions at C6/7 there is a "paradoxical triceps reflex" with forearm muscles acting to flex the elbow against no triceps resistance. With C8 root lesions, wrist extension may be seen when the radius is tapped (as the wrist flexors are rendered relatively inactive). Of these, the finger jerk in the "inverted supinator" is the most striking (and most clinically useful), as there is motor neurone disinhibition as well as an absence of antagonists because of the root lesion.

The localising usefulness of the reflexes is better established for cervical root lesions than for cervical cord lesions. In a retrospective study of 106 consecutive patients with a myelopathy caused by a single level cervical disc herniation,¹⁹ great variability in the neurological examination of apparently similar level lesions was found; however, when present the reflex changes were specific. With isolated C6/7 disc lesions it was uncommon to see brisk finger jerks (Hoffman's sign), and exaggerated biceps jerks were highly specific to a cord lesion from disc disease at C3/4 (or higher). Reliable clinical analysis required the combination of motor, sensory, and reflex signs.¹⁹

The combination of absent ankle jerks (or even generally depressed reflexes) and extensor plantar responses signifies a problem in both the peripheral and the central nervous systems. This may be seen in unrelated diseases (for example, longstanding bilateral S1 root lesion with more recent CNS pathology) or may signify a particular aetiology, such as vitamin B-12 deficiency, tabes dorsalis, Freiderich's ataxia, or syringomyelia.

ABDOMINAL REFLEXES

Although it is possible to evoke short latency responses in the abdominal muscles by tapping the pubic symphysis, one usually implies the cutaneously evoked, superficial abdominal reflex responses when referring to the abdominal reflexes. These can be demonstrated by scratching the skin in the plane of a dermatome from the outer abdomen towards the midline.¹⁶ They are difficult to elicit in anxious patients, in the elderly or the obese, and in multiparous women. They fatigue on repetitive testing and may be absent in 15% of normal individuals. They are more often asymmetric than the knee jerks.³⁷

By comparing the electromyographic response to an electric or scratch stimulus, Satomi *et al* showed that the clinically observed abdominal reflex was analogous to the late response of the electrically elicited blink reflex.³⁸

Abnormalities

Little clinical significance is attributed to brisk abdominal reflexes, though they are said to be brisk in congenital diplegia and in motor neurone disease.³⁹ Indeed, it is said that the loss of abdominal reflexes tends to occur late in motor neurone disease.³⁹

They are usually absent in upper motor neurone lesions and can be used for anatomical localisation in disorders of the thoracic spinal cord, though are less reliable than a sensory level to pin prick and the presence of muscle weakness.

Some pathological abnormality is implied if they are present on one side but entirely absent on the other, and they can be used by paediatric surgeons when assessing children with spinal scoliosis for a possible syrinx.⁴⁰ They may return after stroke.³⁹

Abdominal reflexes are absent in up to two thirds of patients with multiple sclerosis,⁴¹ and it has been suggested that their absence may provide a useful early sign of this disease, perhaps helping to differentiate an inflammatory from a degenerative myelopathy (for example, motor neurone disease). However, the initial reports in multiple sclerosis did not take into account the stage of the disease⁴¹ and prospective studies have not been done.

CONCLUSIONS

It can be seen from the above that the deep tendon reflexes (and the abdominal reflexes) test the integrity of a broad swathe of the neurological system (neuromuscular junction, peripheral nerve, nerve root, spinal cord, and certain supra-spinal centres) and are extremely useful in the practical task of anatomical diagnosis.

REFERENCES

- Pearce JM. Robert Whytt and the stretch reflex. *J Neurol Neurosurg Psychiatry* 1997;**62**:484.
- Louis ED, Kaufmann P. Erbs explanation for the tendon reflexes. *Arch Neurol* 1996;**53**:1187–9.
- Clarke E, O'Malley CD. *The human brain and spinal cord: a historical study illustrated by writings from antiquity to the twentieth century*, 2nd ed. San Francisco: Normal Publishing, 1996:355–82.
- Eccles JC. *The physiology of synapses*. Berlin; Springer 1964.
- Rothwell JC. *Control of human voluntary movement*, 2nd ed. London: Chapman Hall, 1994.
- Burke D, Gandevia SC, Mckeon B. The afferent volleys responsible for spinal proprioceptive reflexes in man. *J Physiol (Lond)* 1983;**339**:535–52.
- Matthews PBC. Long latency stretch reflexes of two intrinsic muscles of the human hand analysed by cooling the arm. *J Physiol (Lond)* 1989;**419**:519–38.
- Matthews PBC, Farmer SF, Ingram DA. On the localization of the stretch reflex of intrinsic hand muscles in a patient with mirror movements. *J Physiol (Lond)* 1990;**428**:561–77.
- Fellows SJ, Schwarz M, Topper R, et al. Stretch reflexes of the proximal arm in a patient with mirror movements: absence of bilateral long latency components. *Electroencephalogr Clin Neurophysiol* 1996;**101**:79–83.
- Matthews WB. The clinical implications of the H reflex and of other electrically induced reflexes. *Mod Trends Neurol* 1970;**5**:241–53.
- O'Sullivan MC, Miller S, Ramesh V, et al. Abnormal development of biceps brachii phasic stretch reflex and persistence of short latency heteronymous reflexes from biceps to triceps brachii in spastic cerebral palsy. *Brain* 1998;**121**:2381–95.
- Leis AA, Kronenberg MF, Stetkarova I, et al. Spinal motoneuron excitability after acute spinal cord injury in humans. *Neurology* 1996;**47**:231–7.
- Eldred E, Granit R, Merton PA. Supraspinal control of the muscle spindles and its significance. *J Physiol (Lond)* 1953;**122**:498–523.
- Cowan JMA, Day BL, Marsden C, et al. Percutaneous motor cortex stimulation. *J Physiol (Lond)* 1986;**377**:334–47.
- Berardelli A, Day BL, Marsden CD, et al. Evidence favouring presynaptic inhibition between antagonist muscle afferents in the human forearm. *J Physiol (Lond)* 1987;**391**:71–83.
- Swash M. *Hutchinson's clinical methods*, 19th ed. London: Balliere Tindall, 1989.
- Brazis PW, Masdeu JC, Biller J. *Localization in clinical neurology*, 3rd ed. Boston: Little Brown, 1996.
- Watson JC, Broaddus WC, Smith MM, et al. Hyperactive pectoralis reflex as an indicator of upper cervical spinal cord compression. Report of 15 cases. *J Neurosurg* 1997;**86**:159–61.
- Matsumoto M, Fujimura Y, Toyama Y. Usefulness and reliability of neurological signs for level of diagnosis in cervical myelopathy caused by soft disc herniation. *J Spinal Disord* 1996;**9**:317–21.
- Bussel B, Morin C, Pierrot-Deseilligny E. Mechanism of monosynaptic reflex reinforcement during Jendrassik manoeuvre in man. *J Neurol Neurosurg Psychiatry* 1978;**41**:40–4.
- Burke D, Mckeon B, Skuse NF. Dependence of the Achilles tendon reflex on the excitability of spinal reflex pathways. *Ann Neurol* 1981;**10**:551–6.
- Impallomeni M, Kenny RA, Flynn MD, et al. The elderly and their ankle jerks. *Lancet* 1984;**325**:670–2.
- Alvarez G, Idiaquez J. Differences in postural hypotension and ankle jerks in the elderly from two contrasting socio-economic levels. *Clin Auton Res* 1991;**1**:243–4.
- O'Keefe ST, Smith T, Valacio R, et al. The comparison of two techniques for ankle jerk assessment in elderly subjects. *Lancet* 1994;**344**:1619–20.
- Zabelis TN, Karandreas NT, Constantinidis TS, et al. The effect of Jendrassik manoeuvre on the latency, amplitude and left-right asymmetry of tendon reflexes. *Electromyogr Clin Neurophysiol* 1998;**38**:19–23.
- Stam J, Speelman HD, van Crevel H. Tendon reflex asymmetry by voluntary mental effort in healthy subjects. *Arch Neurol* 1989;**46**:70–3.
- Bradley WG. Myotatic reflex scale. *Neurology* 1994;**44**:1984.
- Litvan I, Mangone CA, Werden W, et al. Reliability of the NINDS myotatic reflex scale. *Neurology* 1996;**47**:969–72.
- Manschot S, van Passel L, Buskens E, et al. Mayo and NINDS scales for assessment of tendon reflexes: between observer agreement and implications for communication. *J Neurol Neurosurg Psychiatry* 1998;**64**:253–5.
- Fellows SJ, Ross HF, Thilmann AF. The limitations of the tendon jerk as a marker of pathological stretch reflex activity in human spasticity. *J Neurol Neurosurg Psychiatry* 1993;**56**:531–7.
- Nardone A, Galante M, Lucas B, et al. Stance control is not affected by paresis and reflex hyperexcitability: the case of spastic patients. *J Neurol Neurosurg Psychiatry* 2001;**70**:635–43.
- Aymard C, Katz R, Lafitte C, et al. Presynaptic inhibition and homosynaptic depression: a comparison between lower and upper limbs in normal human subjects and patients with hemiplegia. *Brain* 2000;**123**:1688–702.
- Morita H, Crone C, Christenhus D, et al. Modulation of presynaptic inhibition and disynaptic reciprocal Ia inhibition during voluntary movement in spasticity. *Brain* 2001;**124**:826–37.
- Krenz NR, Weaver LC. Sprouting of primary afferent fibers after spinal cord transection in the rat. *Neuroscience* 1998;**85**:443–58.
- Lance JW, McCleod JG. *A physiological approach to clinical neurology*. London: Butterworth Heinemann, 1981:73–99.
- Swash M, Earl CJ. Flaccid paraplegia: a feature of spinal cord lesions in Holmes Adie syndrome and tabes dorsalis. *J Neurol Neurosurg Psychiatry* 1975;**38**:317–21.
- Yngve D. Abdominal reflexes. *J Pediatr Orthop* 1997;**17**:105–8.
- Satomi K, Horai T, Hirakawa S. Electrophysiological study of superficial abdominal reflexes in normal men. *Electroencephalogr Clin Neurophysiol* 1993;**89**:113–19.
- Walton JN. *Brain's diseases of the nervous system*, 7th ed. Oxford: Oxford University Press, 1969.
- Zadeh HG, Sakka SA, Powell MP, et al. Absent superficial abdominal reflexes in children with scoliosis. An early indicator of syringomyelia. *J Bone Joint Surg Br* 1995;**77**:762–7.
- McAlpine D, Lumsden CE, Acheson ED. *Multiple sclerosis, a reappraisal*. London: Livingstone, 1965.