

SHORT REPORT

Two cases of quadriparesis following anterior cervical discectomy, with normal perioperative somatosensory evoked potentials

S J Jones, S Buonamassa, H A Crockard

J Neurol Neurosurg Psychiatry 2003;**74**:273–276

Two cases illustrate an uncommon failure of perioperative somatosensory evoked potential (SEP) monitoring to detect iatrogenic lesions causing temporary quadriparesis during straightforward cervical surgery. In both cases, anterior cervical discectomy at one or two levels was undertaken with bone graft and titanium implants, and cortical SEP were monitored to alternate stimulation of the left and right median or ulnar nerves. The SEP showed only minor changes during surgery, not considered pathologically significant, and were normal when recorded postoperatively. Both patients, however, experienced marked postoperative limb weakness or paralysis. Motor evoked potentials (MEP) recorded postoperatively to transcranial magnetic stimulation were absent. The clinical motor deficits resolved over the ensuing months. In spite of the normally low incidence of "false negatives," in these two cases SEP monitoring failed to detect a iatrogenic lesion causing moderate to severe, though temporary, motor impairment. Monitoring of MEP may be considered as an alternative to SEP during anterior cervical procedures, while combined monitoring of SEP and MEP may be the ideal.

were substantially unchanged.³ In a series of operations for thoracic vertebrectomy,⁴ the incidence of SEP false negatives was reported to be as high as 9%, suggesting that SEP monitoring may sometimes provide an inadequate safeguard.

There is still less information about the adequacy of SEP monitoring during surgery in the cervical region. In a series of 191 operations on the cervical spine,⁵ SEP monitoring identified all the defects that occurred at an appropriate level of the cord (in one case a defect attributable to a lesion at C8 segmental level was not detected by SEP to median nerve stimulation, and there were nine procedures in which SEP monitoring proved impossible owing to the severity of the pre-existing myelopathy). The incidence of quadriplegia following anterior cervical discectomy has been reported to be 0.46%,⁶ and in the past SEP monitoring has not generally been regarded as imperative. However, damage in the territory of the anterior spinal artery might theoretically occur without causing significant impairment of the dorsal sensory tracts, particularly when the spine is approached from the anterior side.

In this paper we report the occurrence of moderate to severe quadriparesis following two such procedures, while SEP showed only minor changes both perioperatively and postoperatively.

Over the past 20 years, somatosensory evoked potentials (SEP) have generally proved to be a reliable means of monitoring the integrity of the spinal cord during spine surgery. In a multicentre survey conducted by the Scoliosis Research Society (SRS) including more than 50 000 operations, mostly for the treatment of developmental deformities, the incidence of false negatives (patients in whom a postoperative neurological deficit occurred in spite of unchanged SEP) was calculated as 0.127% (64 cases), while true positives and false positives were much more frequent.¹ Some of these 64 patients might possibly have benefited from the use of additional or alternative monitoring methods. Although it is unclear how many cases of neurological deterioration were caused by a defect confined to the motor pathways of the cord, the specific question arises as to whether the incidence of false negatives can be reduced by the more widespread adoption of motor evoked potential (MEP) monitoring techniques.

The SRS survey¹ also did not consider the precise circumstances in which SEP monitoring proved insensitive to the iatrogenic defect. In the early spinal cord monitoring literature several false negatives were reported in detail,² but it is arguable that in some of these the failure to detect a defect may have resulted from technical deficiencies at a time when monitoring methods were less well developed. Recently, however, two cases of postoperative paraplegia have been reported in which perioperative recordings of mixed peripheral nerve action potentials to spinal cord stimulation—mainly if not entirely reflecting antidromic activation of sensory tracts—

CASE 1

A 67 year old woman had a 10 month history of severe neck pain extending to both shoulders and the right arm, including the first three digits. One month later the pain spread to the left arm in a similar distribution. After a further month she was treated with heparin for a pulmonary embolism. Preoperatively she complained of "heavy" legs, with reduced walking distance, general weakness, and difficulty in combing her hair. The preoperative neurological examination showed wasting around the shoulders and some spasms of the levator scapulae, particularly on the left. Reflexes were generally diminished but there was no sensory loss. Magnetic resonance imaging (MRI) of the cervical spine showed the C5/6 disc to be impinging on the spinal cord, without signal change. The C6/7 disc appeared large, with osteophytes in the canal both left and right.

She underwent surgery for anterior cervical discectomy at C5/6 and C6/7 with a bone graft from the iliac crest and a titanium implant (Rabea cage; Surgicraft, Redditch, UK). Anaesthesia was induced using fentanyl, propofol, and a muscle relaxant, and maintained using nitrous oxide (50%) and sevoflurane (1–1.5%). During the operation the vertebral bone was noted to be very soft. No untoward surgical events occurred, and the blood pressure was maintained at 100/70 mm Hg \pm 10 mm Hg. Throughout the operation cortical SEP were monitored to alternate stimulation of the left and right ulnar nerves. For stimulation, pairs of skin surface ECG electrodes were located over the ulnar nerve at either wrist, the

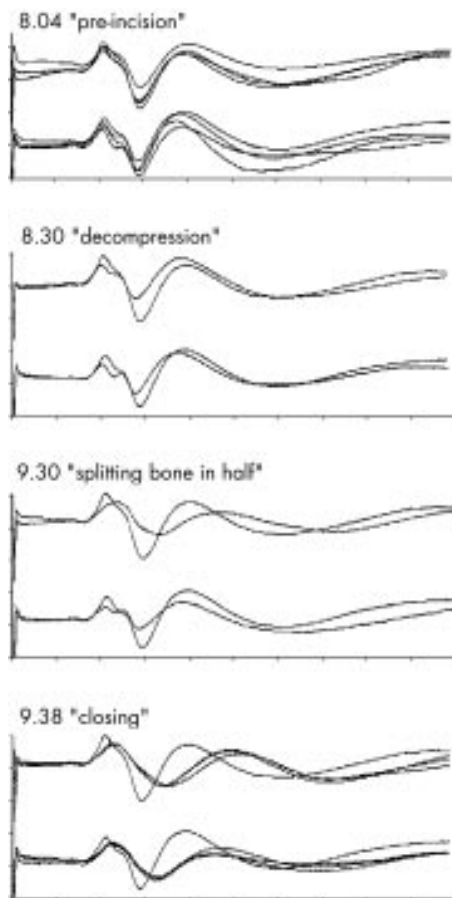


Figure 1 Case 1: C5/6 and C6/7 anterior cervical discectomy. Scale markings are 5 μ V (vertical) and 10 ms (horizontal). By 8.30 cortical sensory evoked potentials (SEP) to left (upper traces) and right (lower traces) ulnar nerve stimulation had undergone minor morphological changes, probably anaesthetic related. At 9.30 the latency of the left ulnar N20 peak (upgoing) increased fairly abruptly by approximately 2 ms, with a rounding of morphology (loss of the shoulder on the downslope) and greater delay of succeeding potentials. In view of the lack of parallel changes to the right ulnar response (recorded concurrently), this is unlikely to have resulted from anaesthetic factors, but at the time was not noted or considered to be of pathological significance. By 9.38 similar changes had occurred to the right ulnar response. No further changes were noted during the procedure.

cathode approximately 4 cm proximal to the anode. Scalp recording electrodes were located at C3' and C4' (approximately 2 cm posterior to 10-20 System sites C3 and C4) and the reference electrode was at Fz. The stimuli were delivered at a frequency of 3/s to either side, with an intensity sufficient to produce a moderate muscle twitch, and averages were made of 200 responses with a recording epoch of 100 ms after each stimulus delivery. The responses were initially within normal limits for a woman of this age, and no untoward changes were noted throughout the procedure (see, however, the legend to fig 1).

Postoperatively the patient was unable to move her limbs, apart from the toes of the right foot. She was also unable to move her shoulders or incline her head. She complained of generalised pain (effectively treated by a morphine infusion) but had no gross loss of bodily sensation. Computed tomography (CT) done within one hour of surgery showed correct positioning of the implant and bone graft. SEP recorded at the bedside to ulnar and posterior tibial nerve stimulation were within normal limits. Peripheral motor nerve conduction studies were normal in the right upper and lower limbs, but no

responses could be elicited to transcranial magnetic stimulation from the right abductor hallucis or abductor pollicis brevis muscles. It was also noted that magnetic stimulation elicited no twitching of the facial muscles.

A methylprednisolone infusion was given (30 mg in 50 ml normal saline over 24 hours), in addition to morphine (4 mg/h). One day after surgery, movement was present in all four limbs (grade 2/5) but there was no bladder sensation. On the second day MRI of the cervical spine showed no cord compression, haematoma, or pathological changes within the cord. After six days SEP were again found to be within normal limits. After two weeks her power had recovered to grade 4/5 in all four limbs and reflexes were absent in the upper limbs and brisk in the lower. Sensation to pinprick and light touch was reduced in both legs as well as on the upper surface of both arms and thumbs. Bladder sensation was almost fully recovered.

Eight months after surgery the patient had recovered almost completely from her quadriplegia but reported persisting bilateral neck, shoulder, and upper limb pain, worse on the right. The upper limb pain was in the distribution of the C7 root, and was exacerbated by extending the neck, raising the arm, and kneeling. Radiographs confirmed sound union at both operated levels of the spine, with no instability or movement.

CASE 2

A 64 year old woman had suffered a neck injury 12 years previously without neurological deficits. Recently she had suffered pain in the left arm, progressing to loss of sensation on the dorsum of the arm, plus shooting pains in both feet. A few months previously she had complained of chest pain. Medical examination at that time revealed hypertension for which she underwent a coronary angiogram which showed no evidence of stenosis. An echocardiogram showed mild abnormalities but it was considered that these changes did not constitute a contraindication for surgery. Neurological examination showed wasting of the left triceps and supinator (but no fasciculation), weak wrist extension, and impaired sensation on the dorsum of the left hand. Examination of the legs showed involuntary twitching and bilateral extensor plantar responses but normal tendon reflexes. Preoperative MRI of the cervical spine showed disc protrusion at C6/7, deforming the spinal cord and with signal change in the cord below this level.

Anaesthesia was induced using fentanyl, propofol, and a muscle relaxant, and maintained using nitrous oxide (50%) and sevoflurane (1–1.5%). An anterior cervical discectomy and osteophyctomy were undertaken at C5/6. A bone graft and a titanium implant (Rabea cage) were inserted. Cortical SEP were recorded to alternate stimulation of the left and right median nerves, using methods otherwise identical to those of case 1. The responses were initially within normal limits and showed no untoward changes apart from a latency increase of up to 0.9 ms on the left and 1.7 ms on the right (fig 2A). No untoward surgical events occurred, but for about 15 minutes during surgery a blood pressure elevation was noted, from 100/60 to 162/81 mm Hg.

Postoperatively the patient suffered marked motor weakness (grade 1/5) of all four limbs, particularly on the right. She was able to move her right shoulder but less easily the triceps, and was unable to raise her right leg against gravity. She reported an improvement of her presenting symptoms in the left hand, but numbness of the right arm and leg, plus tingling in the right arm and both legs and painful spasms in both legs. Immediate CT showed the cage to be centrally located in the disc space and no signs of cord compression. MRI of the brain and cervical cord showed patchy hyperintensity in the pons ventrally to the beginning of the motor decussation, but no compression, haematoma, or ischaemia of the cord. SEP obtained at the bedside were within normal limits from both

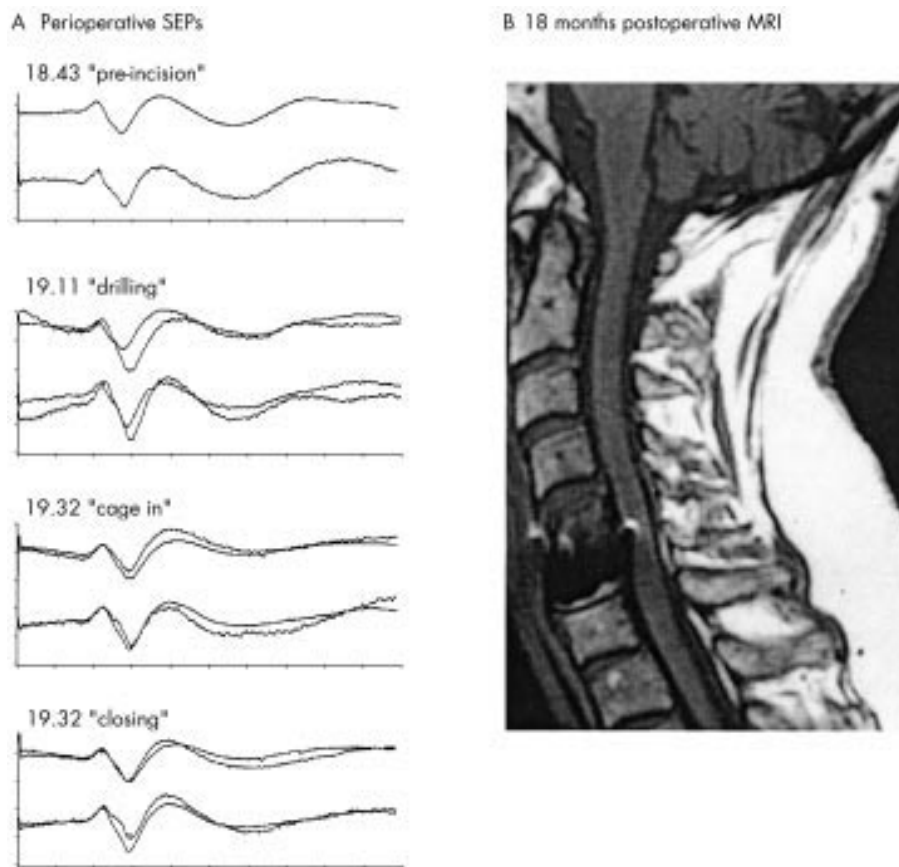


Figure 2 Case 2: C5/6 anterior cervical discectomy. Scale markings are 2.5 μ V (vertical) and 10 ms (horizontal). During the course of surgery the N20 latencies to left (upper traces) and right (lower traces) median nerve stimulation increased by up to 1.7 ms but there were no notable changes in amplitude or morphology. No cord lesion was evident in postoperative magnetic resonance imaging, but in the scan obtained 18 months later (illustrated) a small focus of high signal is evident at the level of surgery.

median and posterior tibial nerves. No response could be elicited to transcranial magnetic stimulation from the right tibialis anterior muscle.

On the first day following surgery she was able to lift her right leg against gravity but her right hand was still very weak. Four days after surgery neurological examination showed improvement in her presenting symptoms but moderate pyramidal weakness of the right arm, severe weakness of the right leg, brisk reflexes in the right arm, bilateral extensor plantar reflexes, and subjective reduction of sensation in the left leg which was not present preoperatively. The motor deficit and spasms improved progressively over the following days. After six weeks the patient was able to walk using sticks and was without sphincter disturbances. At this time there was mild weakness and sensory loss on the left, decreased selective control of the right limbs, mildly reduced balance sensation, increased fatigability, and reduced exercise tolerance. Ten weeks postsurgically a slight motor deficit persisted and she complained of distorted temperature sensation on the left side of the body. Follow up radiographs showed no instability and no deformity. Follow up MRI scans excluded any persisting cord compression, but in scans obtained 18 months after surgery there was a small intramedullary high signal focus at the level of the operation (fig 2B).

DISCUSSION

We report here the rare occurrence (the operative technique had previously been used more than 2000 times without similar problems) of postsurgical neurological deficits that were not detected by perioperative SEP monitoring. Two patients suffered quite severe slowly resolving deficits which might be

attributable to compromised spinal cord motor tracts adjacent to the site of surgery. Somewhat at variance with this conclusion, however, was the absence of immediate radiological or MRI signs of cord compromise. In case 1, the paresis apparently involved the muscles of the shoulder girdle and neck, although surgery was at the C5/6 vertebral level and below. The mechanism of injury also remains unclear. The gentle tapping of the implant into position might have been the cause of protracted neurapraxia. Another possibility might be compression of a radicular artery essential to the anterior spinal artery, although this would be expected to result in immediate MRI signal changes in the cord, which were in fact only observed 18 months later in one of the two cases. A further possibility may be that blood pressure changes in a situation of lost autoregulation, possibly also in association with minor malpositioning of the head, may have caused temporarily low focal perfusion of the spinal cord.

Our reasons for presenting these findings are twofold. First, the neurological risks associated with anterior cervical discectomy are generally considered to be low, but clearly are not negligible. Second, irrespective of the cause and level of the defect, it may be desirable to monitor motor pathway function during surgery which addresses the spine from the anterior side. Recently established techniques for recording compound muscle action potentials (CMAP) to multipulse transcranial electrical stimulation⁷⁻¹² render perioperative motor pathway monitoring feasible in most circumstances. In our own experience,⁹ CMAP can usually be recorded during anaesthesia maintained with propofol/nitrous oxide, and also under sevoflurane in moderate concentrations. Practical disadvantages of the technique are the generalised motor twitch (in

contrast to SEP monitoring which is entirely invisible to the surgeon) and constraints on the use of infused muscle relaxants and halogenated anaesthetic agents. However, with continuing improvements in the hardware and software of equipment used for perioperative monitoring, the combined monitoring of both sensory and motor responses has become a practical proposition.

Conclusions

SEP have not always been found to be an adequate technique for monitoring spinal cord function during anterior cervical surgery, although the proportion of defects that go undetected is still likely to be very low. For greater security, combined monitoring of SEP and MEP is advocated, although more experience is required to confirm whether iatrogenic defects detected by the latter are sufficiently reversible to prevent persistent neurological compromise.

.....

Authors' affiliations

S J Jones, S Buonamassa, H A Crockard, The National Hospital for Neurology and Neurosurgery, Queen Square, London, UK

Competing interests: none declared

Correspondence to: Dr S J Jones, Department of Clinical Neurophysiology, The National Hospital for Neurology and Neurosurgery, Queen Square, London WC1N 3BG, UK; sjjones@ion.ucl.ac.uk

Received 11 February 2002
In revised form 17 October 2002
Accepted 11 November 2002

REFERENCES

- 1 **Nuwer MR**, Dawson EG, Carlson LG, *et al*. Somatosensory evoked potential spinal cord monitoring reduces neurologic deficits after scoliosis surgery: results of a large multicenter survey. *Electroencephalogr Clin Neurophysiol* 1995;**96**:6–11.
- 2 **Lesser RP**, Raudzens P, Lueders H, *et al*. Postoperative neurological deficits may occur despite unchanged intraoperative somatosensory evoked potentials. *Ann Neurol* 1986;**19**:22–5.
- 3 **Minahan RE**, Sepkuty JP, Lesser RP, *et al*. Anterior spinal cord injury with preserved neurogenic "motor" evoked potentials. *Clin Neurophysiol* 2001;**112**:1442–50.
- 4 **Deutsch H**, Arginteanu M, Manhart K, *et al*. Somatosensory evoked potential monitoring in anterior thoracic vertebrectomy. *J Neurosurg* 2000;**92**(2 suppl):155–61.
- 5 **May DM**, Jones SJ, Crockard HA. Somatosensory evoked potential monitoring in cervical surgery: identification of pre- and intraoperative risk factors associated with neurological deterioration. *J Neurosurg* 1996;**85**:566–73.
- 6 **Clark CR**, ed. *The cervical spine*. Philadelphia: Lippincott-Raven, 1998.
- 7 **Calancie B**, Harris W, Broton JG, *et al*. "Threshold-level" multipulse transcranial electrical stimulation of motor cortex for intraoperative monitoring of spinal motor tracts: description of method and comparison to somatosensory evoked potential monitoring. *J Neurosurg* 1998;**88**:457–70.
- 8 **Deletis V**, Kothbauer K. Intraoperative neurophysiology of the corticospinal tract. In: Stalberg E, Sharma HS, Olsson Y, eds. *Spinal cord monitoring*. New York: Springer, 1998:421–44.
- 9 **Jones SJ**, Harrison R, Koh KH, *et al*. Motor evoked potential monitoring during spinal surgery: responses of distal limb muscles to transcranial cortical stimulation with pulse trains. *Electroencephalogr Clin Neurophysiol* 1996;**100**:375–83.
- 10 **Pechstein U**, Cedzich C, Nadstawek J, *et al*. Transcranial high frequency repetitive electrical stimulation for recording myogenic motor evoked potentials with the patient under general anesthesia. *Neurosurgery* 1996;**39**:335–43.
- 11 **Pelosi L**, Stevenson M, Hobbs GJ, *et al*. Intraoperative motor evoked potentials to transcranial electrical stimulation during two anaesthetic regimens. *Clin Neurophysiol* 2001;**112**:1076–87.
- 12 **Ubags LH**, Kalkman CJ, Been HD. Influence of isoflurane on myogenic motor evoked potentials to single and multiple transcranial stimuli during nitrous oxide/opioid anesthesia. *Neurosurgery* 1998;**43**:90–4.