

## PHYSICAL SIGNS

# False localising signs

A J Larner

Neurological signs have been described as "false localising" if they reflect dysfunction distant or remote from the expected anatomical locus of pathology, hence challenging the traditional clinicoanatomical correlation paradigm on which neurological examination is based. False localising signs occur in two major contexts: as a consequence of raised intracranial pressure, and with spinal cord lesions. Cranial nerve palsies (especially sixth nerve palsy), hemiparesis, sensory features (such as truncal sensory levels), and muscle atrophy, may all occur as false localising signs. Awareness that signs may be false localising has implications for diagnostic investigation.

The clinical examination of the nervous system is based on the premise of clinicoanatomical correlation, with a particular neurological sign indicating pathology at a specific locus or pathway within the nervous system.<sup>1</sup> Occasionally, however, this semiology "breaks down", in that neurological signs may reflect pathology distant from the expected anatomical locus.

The notion of "false localising signs" was first elucidated by James Collier in 1904: on the basis of clinical examination during life and subsequent postmortem studies, he noted false localising signs in 20 of 161 consecutive cases of intracranial tumour examined pathologically, most occurring in patients with supratentorial lesions.<sup>2</sup> Despite this high frequency (12.4%), Collier felt false localising signs were being observed less frequently because of the earlier diagnosis of tumours, a theme reiterated by later authors, implying that such signs are a late feature in the natural history of tumours.<sup>2</sup> Gassel noted false localising signs to be more common in patients with raised intracranial pressure.<sup>3</sup>

As there have been few previous reviews of false localising signs,<sup>3,4</sup> this article attempts a brief overview of these phenomena and their possible pathophysiology. It does not aim to provide an exhaustive review of publications on the subject, most of which are case reports or small case series rather than systematic studies. Rather, it selects illustrative examples, particularly where these elucidate possible pathophysiological mechanisms.

Structural brain imaging, particularly magnetic resonance imaging (MRI), affording as it does the opportunity to study pathological anatomy contemporaneous with clinical examination, has provided some new insights into the causes of these signs.

*J Neurol Neurosurg Psychiatry* 2003;**74**:415–418

### FALSE LOCALISING SIGNS ASSOCIATED WITH INTRACRANIAL LESIONS

#### Sixth nerve palsy

Sixth nerve palsy, either unilateral or bilateral, is the classic example of a false localising sign. It occurs in the context of raised intracranial pressure of whatever cause (supratentorial or infratentorial space occupying lesion, idiopathic intracranial hypertension, cerebral venous sinus thrombosis). It was the most common of the false localising signs observed by Collier (12/20) in cases of intracranial tumour.<sup>2</sup> In a retrospective review of 101 cases of idiopathic intracranial hypertension (IIH), Round and Keane noted 14 cases (11 unilateral, three bilateral).<sup>5</sup> IIH with sixth nerve palsy in the absence of papilloedema has also been reported.<sup>6</sup>

The pathophysiological mechanism of sixth nerve palsy with increased intracranial pressure has traditionally been said to be stretching of the nerve in its long intracranial course, or compression against the petrous ligament or the ridge of the petrous temporal bone. Collier, however, was "unable to accept this explanation", his view being that since the sixth nerve emerges straight forward from the brain stem, whereas other cranial nerves emerge obliquely or transversely, it is more liable to the mechanical effects of backward brain stem displacement by intracranial space occupying lesions.

#### Fifth and seventh nerve false localising signs

Dysfunction of the fifth and seventh cranial nerves has also been reported with raised intracranial pressure.<sup>2,7–16</sup> This dysfunction may be hypoactive or hyperactive, manifesting with negative or positive Jacksonian symptoms, respectively; hence there may be trigeminal neuropathy<sup>2,7–10</sup> or trigeminal neuralgia,<sup>11–13</sup> facial palsy of lower motor neurone type,<sup>2,9,14,15</sup> or hemifacial spasm.<sup>12,16</sup> Fifth and seventh nerve involvement has been recorded in the context of posterior fossa neoplasms<sup>2,7,9</sup> or more diffuse neoplastic disease,<sup>15</sup> and with IIH.<sup>8,10,14</sup> Reports of false localising seventh nerve palsies suggest they most often occur at the same time as, or after, the development of sixth nerve palsies.<sup>2,9,14</sup> Brain stem distortion resulting in traction on cranial nerves has been suggested as the pathophysiological mechanism in tumour associated cases,<sup>7</sup> but this seems a less compelling explanation for IIH cases.

Collier suggested that motor involvement preceded sensory features in fifth nerve palsy,<sup>2</sup> but the clinical features reported in subsequent cases

Dr A J Larner, Consultant Neurologist, Walton Centre for Neurology and Neurosurgery, Lower Lane, Fazakerley, Liverpool L9 7UJ, UK; a.larner@thewaltoncentre.nhs.uk

Received  
11 December 2002  
Accepted  
13 December 2002

**Abbreviations:** IIH, intracranial hypertension; MRI, magnetic resonance imaging

suggest sensory findings are more prominent.<sup>7-10</sup> Gassel found motor involvement in only two of eight patients with false localising fifth nerve involvement.<sup>3</sup> Arsava *et al* reported both clinical and electrophysiological evidence of left trigeminal neuropathy in a patient with ITH: examining the blink reflex, no response was elicited either ipsi- or contralaterally when stimulating the left supraorbital nerve, and although trigeminal motor function was clinically intact, no response was elicited from the left masseter muscle when measuring the latency of the jaw reflex.<sup>10</sup>

Unlike fifth and seventh nerve palsies, trigeminal neuralgia and hemifacial spasm have only been reported in the context of posterior fossa mass lesions, most usually tumours,<sup>11-13</sup> but also chronic calcified subdural haematoma. As with the idiopathic condition, there has been debate about the pathophysiology of trigeminal neuralgia associated with contralateral tumours. Some favour vascular compression of the nerve root as the proximate cause of paroxysmal ephaptic transmission,<sup>11</sup> whereas others implicate angulation and distortion of the nerve root entry/exit zone as a consequence of displacement of brain tissue caused by an expanding mass lesion in the posterior fossa.<sup>12</sup> In favour of the latter explanation, two cases have been reported in which trigeminal neuropathy was “converted” to trigeminal neuralgia (hence, a lesser degree of dysfunction) following removal of a contralateral posterior fossa tumour.<sup>12</sup> However, other cases have been presented in which trigeminal neuralgia did not resolve after tumour removal alone.<sup>13</sup> Matsuura and Kondo implicate adherence of arachnoid membrane to the nerve as a contributing factor and advocate its resection in order to straighten the nerve axis.<sup>12</sup>

Hemifacial spasm as a false localising sign of posterior fossa tumour seems altogether rarer than trigeminal neuralgia, indeed exceptional.<sup>12</sup> As with trigeminal neuralgia, the question of whether the false localising sign follows neurovascular compression or mechanical distortion remains open.

### Third nerve palsy and Kernohan’s notch phenomenon

Transtentorial herniation of the medial temporal lobe (uncus), as a consequence of shift of intracranial contents secondary to raised intracranial pressure, may be associated with third nerve palsy. Perhaps because of the intra-axial fascicular arrangement of fibres within the third nerve, the peripherally located pupilloconstrictor fibres are most vulnerable, such that unilateral mydriasis (“Hutchinson’s pupil”) may be the earliest sign. That the consequent fixed dilated pupil is ipsilateral to a supratentorial mass is axiomatic in neurosurgical practice, yet cases of pupillary dilatation contralateral to mass lesions (such as acute intraparenchymal haemorrhage), and in the absence of ipsilateral pupillary change, have been reported.<sup>17</sup> This may evolve to a complete, false localising, third nerve palsy before the ipsilateral third nerve becomes involved.<sup>17</sup>

The mechanism for this third nerve palsy has traditionally been ascribed to extrinsic compression of the third nerve on the margin of the tentorium. An alternative explanation, possibly relevant to false localising third nerve palsy, is that raised intracranial pressure causes kinking of the nerve over the clivus, just posterior to the clinoid.<sup>17</sup> Another suggestion is that a central mechanism might be responsible, supratentorial pressure causing the brain stem to buckle as it descends because of caudal tethering of the neuraxis at the first dentate ligament (“dynamic axial brain stem distortion”); however, the absence of brain stem signs early in the course of tentorial herniation may argue against this possibility. Different mechanisms might operate at different times.<sup>18</sup>

Herniation of the temporal lobe through the tentorial notch may successively compress the third nerve and the ipsilateral cerebral peduncle; since this is above the pyramidal decussation of corticospinal fibres, hemiparesis contralateral to the lesion as well as ipsilateral third nerve palsy results. However, on occasion, herniation may be associated with a false localising ipsilateral hemiparesis, known as the Kernohan notch

phenomenon (or, perhaps more correctly, the Kernohan-Woltman notch phenomenon), in which the free edge of the tentorium compresses the contralateral crus cerebri in the midbrain.<sup>19</sup> Acute subdural haematoma is a common cause. Homolateral hemiparesis and third nerve palsy, both ipsilateral to the lesion, may result,<sup>20</sup> although unilateral pupil dilatation is the earliest consistent sign of herniation.

### Other false localising signs reported with intracranial pathology

A number of other false localising signs have been reported in association with raised intracranial pressure. Trochlear nerve palsy has occasionally been described, along with the suggestion that it might be overlooked in cases in which other cranial nerves are affected (sixth, third) because the signs are subtle.<sup>21</sup> Although Collier observed no cases of trochlear nerve palsy, he denied the possibility that they had been overlooked clinically, on the grounds that they produce a distressing diplopia.<sup>2</sup> Unilateral hearing loss has been reported in ITH,<sup>22</sup> although tinnitus is the more common otological problem in this condition.<sup>5</sup>

Unilateral papilloedema may be described as false localising when associated with contralateral visual loss and optic atrophy due to subfrontal or middle cranial fossa *en plaque* meningioma (Foster-Kennedy syndrome).<sup>23</sup> Papilloedema resulting from high CSF protein concentration may initiate an inappropriate search for an intracranial mass lesion.

“Frontal ataxia”, a cerebellar type of ataxia resulting from lesions of the contralateral frontal cortex in which fibres of the corticopontocerebellar pathway are said to be interrupted, is also a false localising sign, but its frequency is uncertain. Round and Keane reported four patients in their series of 101 with ITH to have “ataxia”, meaning a transient postural giddiness with unsteadiness when beginning to walk<sup>5</sup>; whether this was “frontal ataxia” is not clear. Although functional imaging studies have shown reduced metabolism in the cerebellar hemisphere contralateral to a middle cerebral artery territory infarct (“crossed cerebellar diaschisis”),<sup>24</sup> this is not generally accompanied by clinical signs. Cerebellar ataxia contralateral to a posterior fossa mass lesion has been reported.<sup>7</sup>

Exceptionally, false localising ninth and tenth nerve palsies have been described with posterior fossa tumour.<sup>7</sup> All such reports predate modern structural brain imaging.

## FALSE LOCALISING SIGNS ASSOCIATED WITH SPINAL CORD LESIONS

### Foramen magnum and upper cervical cord lesions

Lesions at the level of the foramen magnum may produce, in addition to suboccipital and neck pain and upper motor neurone (long tract) signs, false localising signs: paraesthesia in the hands and lower motor neurone signs in the upper limbs.<sup>25</sup> The wasting (“remote atrophy”), weakness, and areflexia may suggest the involvement of cervical cord segments well below the level of the foramen magnum lesion, hence are false localising. Similarly, a syndrome of “numb and clumsy hands” has been described with midline cervical disc protrusions at the C3/C4 level; concurrent with numbness of fingertips and palms, there may be a tightening sensation at mid-thoracic level.<sup>26</sup> Cervical spinal cord lesions (cervical spondylosis, herniated disc) at or above the level of C4 in which finger and hand dysaesthesia with hand muscle atrophy preceded limb spasticity or gait disturbance have also been reported.<sup>27</sup>

There is currently no compelling pathophysiological explanation for these false localising signs, but three principal mechanisms have been invoked: arterial, venous, and mechanical.<sup>28</sup> The arterial hypothesis postulates that tumour in some way compromises descending anterior spinal artery blood supply to the lower cervical cord with resultant focal ischaemia. However, this would also seem to require insufficiency of

radicular spinal arteries entering intervertebral foramina to join anterior spinal artery. Moreover, there is some evidence that blood flows rostrally rather than caudally in the anterior spinal artery. Furthermore, the low pressure venous system would seem inherently more vulnerable to the effects of compression than the arterial system, with resultant tissue stasis and hypoxia perhaps causing the clinically observed neurological dysfunction. Mechanical stresses within the spinal cord, consequent perhaps on the conjunction of extrinsic compression with the anchoring of the spinal cord by the dentate ligaments, have also been suggested to account for remote signs. The paucity of pathological material has made it difficult to obtain direct evidence in support of any of these hypotheses. In all cases, the differential decussation of corticospinal tract fibres to fore and hind limbs and the lamination of sensory tracts may be prerequisites for the clinical features.<sup>28</sup>

### Lower cervical cord and upper thoracic cord lesions

Because of the anatomical decussation of spinothalamic tract fibres two or three segments above the level at which they enter the spinal cord from their respective dermatomes, it is not unusual for sensory levels two or three segments distant from the level of cord pathology to be observed clinically. However, more distant sensory and motor signs may be observed with cord pathology, whose explanation is altogether more challenging. Compressive cervical myelopathy may produce a false localising thoracic sensory level,<sup>29</sup> sometimes called a mid thoracic girdle sensation,<sup>30</sup> in addition to lower limb weakness and hyper-reflexia. Similarly, lumbar spinal disease may be simulated by more rostral pathology; for example, urinary retention, leg weakness, and lumbar sensory findings may be the presenting features of high thoracic cord compression, with clinicoradiological discrepancy of as much as 11 segments.<sup>31</sup>

As with foramen magnum and upper cervical cord lesions, opinion is divided as to the pathophysiological explanation for these observations. Comparing axial MR images of the cervical cord in 10 patients with compressive cervical myelopathy, five with girdle signs and five without, Ochiai *et al* noted that the midline ventral portion of the cervical cord was more markedly compressed in those with the false localising sensory level. This observation led them to suggest that ischaemia in the watershed zone of the anterior spinal artery, affecting the medial portion of the laminations of the spinothalamic tract, was the causative mechanism for the girdle sensation, rather than direct compression of spinothalamic fibres.<sup>30</sup> Jamieson *et al*, however, favoured venous obstruction with ensuing intramedullary stasis and hypoxia as the explanation for remote phenomena.<sup>31</sup> Of course, different cases may have different pathogenesis, and/or more than one mechanism may be operating in any one case.

### OTHER "FALSE LOCALISING" SIGNS

The "false localising" terminology has also been used in other contexts, for example to describe internuclear ophthalmoplegia, usually indicative of medial longitudinal fasciculus dysfunction, in patients with myasthenia gravis<sup>32</sup>; this "pseudo-internuclear ophthalmoplegia" has also been observed in dermatomyositis. Similarly, myasthenic nystagmus may suggest a brain stem lesion.

Other "pseudo-signs" are described which might be encompassed by the "false localising" rubric,<sup>1</sup> such as pseudo-(choreo)athetosis and pseudoastereognosis, which may occur with high cervical cord lesions rather than intracranial pathology. Signs traditionally thought to be of cortical origin, such as aphasia and inattention, may sometimes occur with exclusively subcortical pathology; conversely, exclusively cortical lesions may sometimes result in dysarthria. Sensory stimuli (tactile, visual) may be detected contralateral to the stimulated side (alloaesthesia, allochiria). "Pseudosyringomyelia"

has been used to describe a selective loss of pain and temperature sensation with relative preservation of vibration and position sense seen in amyloid polyneuropathy and Tangier disease, a small fibre sensory neuropathy, in the absence of any spinal cord pathology, and hence false localising.

### DISCUSSION

False localising neurological signs have presented significant challenges to clinical neurologists: in the era before neuroimaging, operations were sometimes performed on, and treatments administered to, the wrong side based on these signs.<sup>2</sup> Thankfully practice is now somewhat easier with the benefit of structural imaging, although confusion may still occur, and the appropriate part of the central nervous system may not be imaged.<sup>31</sup> For the practising neurologist, an awareness of the possibility of false localising signs, and knowledge of the situations in which they are most likely to occur, is necessary to heighten the index of clinical suspicion, so that the possible pathological import of false localising signs is not missed.

The pathophysiology of many false localising signs is still poorly, if at all, understood.<sup>18-28</sup> The preponderant association with extrinsic mass lesions, such as intracranial tumours (especially meningioma), subdural haematoma, and intervertebral disc prolapse, has long been noted, although intrinsic lesions may certainly be responsible on occasion.<sup>9-12</sup> Some of these pathologies exert their effects acutely, whereas for others (for example, meningiomas) it is their slow growth which is implicated. The possibility of multifactorial pathophysiology therefore seems likely.

After almost one hundred years use,<sup>2</sup> the term "false localising sign" is thoroughly ingrained in clinical teaching, although it is important to be aware that such signs are in no way "false". The practical implication of the name is that such signs cannot be relied on when assessing clinical localisation, which challenges traditional clinicoanatomical correlation. "Diaschisis" is a technical term for dysfunction distant from pathology, particularly familiar in the field of functional imaging.<sup>24</sup> However, it is associated with the notion of "transneuronal depression", which may not be relevant to the pathophysiology of these signs, besides being something of a mouthful for clinical practice. Perhaps "distant signs" or "remote signs" would fit the bill, though lacking any emotive resonance. Most importantly, since false localising signs may be indicative of serious, even life threatening, pathology within neural pathways, awareness of them and the situations in which they occur, will facilitate appropriate and timely investigation and management.

### ACKNOWLEDGEMENTS

Thanks are extended to Drs Alasdair Coles and Peter Enevoldson for commenting on earlier versions of the manuscript.

Conflict of interest: None.

### REFERENCES

- 1 Lamer AJ. *A dictionary of neurological signs*. Clinical neurosemiology. Dordrecht: Kluwer Scientific Publications, 2001.
- 2 Collier J. The false localising signs of intracranial tumour. *Brain* 1904;**27**:490-508.
- 3 Gassel MM. False localizing signs. A review of the concept and analysis of the occurrence in 250 cases of intracranial meningioma. *Arch Neurol* 1961;**4**:526-54.
- 4 Davis M, Lucatoro M. The false localizing signs of increased intracranial pressure. *J Neurosci Nursing* 1992;**24**:245-50.
- 5 Round R, Keane JR. The minor symptoms of increased intracranial pressure. 101 cases with benign intracranial hypertension. *Neurology* 1988;**38**:1461-4.
- 6 Krishna R, Kosmorsky GS, Wright KW. Pseudotumor cerebri sine papilloedema with unilateral sixth nerve palsy. *J Neuroophthalmol* 1998;**18**:53-5.
- 7 Maurice-Williams RS. Multiple crossed false localizing signs in a posterior fossa tumour. *J Neurol Neurosurg Psychiatry* 1978;**38**:1232-4.
- 8 Davenport RJ, Will RG, Galloway PJ. Isolated intracranial hypertension presenting with trigeminal neuropathy. *J Neurol Neurosurg Psychiatry* 1994;**57**:381.



- 9 **Ro LS**, Chen ST, Tang LM, *et al*. Concurrent trigeminal, abducens, and facial nerve palsies presenting as false localizing signs: case report. *Neurosurgery* 1995;**37**:322-4.
- 10 **Arsava EM**, Uluc K, Nurlu G, *et al*. Electrophysiological evidence of trigeminal neuropathy in pseudotumor cerebri. *J Neurol* 2002;**249**:1601-2.
- 11 **Michelucci R**, Tassinari CA, Plasmati R, *et al*. Trigeminal neuralgia associated with contralateral intracranial tumour: a false localizing sign caused by vascular compression? Report of two cases. *J Neurol Neurosurg Psychiatry* 1989;**52**:1202-3.
- 12 **Matsuura N**, Kondo A. Trigeminal neuralgia and hemifacial spasm as false localizing signs in patients with a contralateral mass of the posterior cranial fossa. *J Neurosurg* 1996;**84**:1067-71.
- 13 **Grigoryan YA**, Onopchenko CV. Persistent trigeminal neuralgia after removal of contralateral posterior cranial fossa tumor. Report of two cases. *Surg Neurol* 1999;**52**:56-60.
- 14 **Davie C**, Kennedy P, Katifi HA. Seventh nerve palsy as a false localizing sign. *J Neurol Neurosurg Psychiatry* 1992;**55**:510-11.
- 15 **Gutowksi NJ**, Gomez-Anson B, Torpey N, *et al*. Oligodendroglial gliomatosis cerebri: (1)H-MRS suggests elevated glycine/inositol levels. *Neuroradiology* 1999;**41**:650-3.
- 16 **Rapana A**, Guida F, Conti C, *et al*. Ependymoma of the fourth ventricle presenting with hemifacial spasm. *Rev Neurol (Paris)* 1999;**155**:309-11.
- 17 **Chen R**, Sahjpal R, Del Maestro RF, *et al*. Initial enlargement of the opposite pupil as a false localizing sign in intraparenchymal frontal haemorrhage. *J Neurol Neurosurg Psychiatry* 1994;**57**:1126-8.
- 18 **Marshman LAG**, Polkey CE, Penney CC. Unilateral fixed dilation of the pupil as a false-localizing sign with intracranial hemorrhage: case report and literature review. *Neurosurgery* 2001;**49**:1251-5.
- 19 **Kernohan JW**, Woltman HW. Incisura of the crus due to contralateral brain tumor. *Arch Neurol Psychiatry* 1929;**21**:274-87.
- 20 **Cohen AR**, Wilson J. Magnetic resonance imaging of Kernohan's notch. *Neurosurgery* 1990;**27**:205-7.
- 21 **Halpern JI**, Gordon WH. Trochlear nerve palsy as a false localizing sign. *Ann Ophthalmol* 1981;**13**:53-6.
- 22 **Dorman PJ**, Campbell MJ, Maw AR. Hearing loss as a false localizing sign in raised intracranial pressure. *J Neurol Neurosurg Psychiatry* 1995;**58**:516.
- 23 **Mariniello G**, Bonavolonta G, de Divitiis E. Papilledema as a "false" localizing sign. *Clin Neurol Neurosurg* 2002;**104**:69-71.
- 24 **Baron JC**, Boussier MG, Comar D, *et al*. Crossed cerebellar diaschisis in human supratentorial brain infarction. *Trans Am Neurol Assoc* 1980;**105**:459-61.
- 25 **Symonds CP**, Meadows SP. Compression of the spinal cord in the neighbourhood of the foramen magnum. *Brain* 1937;**60**:52-84.
- 26 **Nakajima M**, Hirayama K. Midcervical central cord syndrome: numb and clumsy hands due to midline cervical disc protrusion at the C3-4 intervertebral level. *J Neurol Neurosurg Psychiatry* 1995;**58**:607-13.
- 27 **Sonstein WJ**, LaSala PA, Michelsen WJ, *et al*. False localizing signs in upper cervical spinal cord compression. *Neurosurgery* 1996;**38**:445-8.
- 28 **Cohen L**. Tumors in the region of the foramen magnum. In: Vinken PJ, Bruyn GW, eds. *Handbook of clinical neurology, volume 17: Tumours of the brain and skull, Part II*. Amsterdam: North-Holland, 1974:719-30.
- 29 **Adams KK**, Jackson CE, Rauch RA, *et al*. Cervical myelopathy with false localizing sensory levels. *Arch Neurol* 1996;**53**:1155-8.
- 30 **Ochiai H**, Yamakawa Y, Minato S, *et al*. Clinical features of the localized girdle sensation of mid-trunk (false localizing sign) appeared in cervical compressive myelopathy patients. *J Neurol* 2002;**249**:549-53.
- 31 **Jamieson DR**, Teasdale E, Willison HJ. False localizing signs in the spinal cord. *BMJ* 1996;**312**:243-4.
- 32 **Bakheit AMO**, Behan PO, Melville ID. Bilateral internuclear ophthalmoplegia as a false localizing sign. *J R Soc Med* 1991;**84**:627.

## NEUROLOGICAL PICTURE

### Intracranial hypertension secondary to giant arachnoid granulations

We present a case of intracranial hypertension in a non-obese male in whom the only finding resulting from additional tests was the presence of giant arachnoid granulations in lateral sinuses.

A 51 year old man presented episodes of transient obscurations of vision in the left eye lasting a few seconds. On general physical examination, the patient was not obese (170 cm height, 70 kg weight) and no relevant findings were detected. During neurologic examination a complete left papilledema was detected. In the right optic disc a nasal effacement with peripapillary hemorrhages was observed. Campimetry was normal in the right eye; in the left eye an enlargement of the blind spot was observed. Visual acuity was normal. A lumbar puncture in lateral decubitus showed an opening pressure of 27 cm of water. Laboratory studies, cranial magnetic resonance imaging (MRI) and visual evoked potentials were normal or negative. A magnetic resonance venography showed a dominance of the right transverse sinus and filling defect in lateral sinuses. A cerebral digital subtraction angiography disclosed bilateral focal areas of nonflow signal protruding into the lumen of both sinuses at the transverse sinus-sigmoid sinus junction compatible with giant arachnoid granulations, and left transverse sinus hypoplasia.

Arachnoid granulations are present in a variable percentage of the population (0.3 B 24%) and very rarely do they produce any symptoms.<sup>1-4</sup> Their function is not wholly understood, although cerebrospinal fluid resorption seems the most likely.<sup>4</sup> They increase with age so that the granulations may protrude into the lumen of the venous sinus and, in theory at least, dilate it<sup>4</sup> and obstruct venous flow.<sup>5</sup> If this occurred it could result in intracranial hypertension,<sup>5</sup> as we suggest in our case.

**A Arjona**

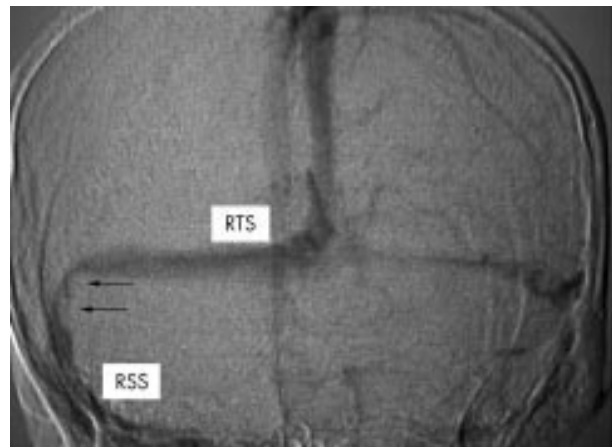
Seccion de Neurologia, Hospital Torrecardenas, Almeria, Spain

**F Delgado**

Servicio de Radiologia, Hospital Universitario Reina Sofia, Cordoba, Spain

**E Fernandez-Romero**

Servicio de Urgencias, Hospital Alto Guadalquivir, Andujar, Jaen, Spain



Venous phase from cerebral angiography, anteroposterior projection, shows left transverse sinus hypoplasia and two focal areas of nonflow signal protruding into sinus lumen in the right transverse sinus-sigmoid sinus junction (arrows). The two defects are round and have a diameter of 8 and 9 mm, respectively. RTS: right lateral sinus, transverse portion; RSS: right lateral sinus, sigmoid portion.

For correspondence: A Arjona, C/Violeta 70, E-04720 Aguadulce, Almeria, Spain; aarjonap@medynet.com

#### References

- 1 **Kuroiwa T**, Kajimoto Y, Ohta T, *et al*. Symptomatic hypertrophic pachionian granulation mimicking bone tumor: case report. *Neurosurgery* 1996;**39**:860-2.
- 2 **Rosenberg AE**, O'Connell JX, Ojemann RG, *et al*. Giant cystic arachnoid granulations: a rare cause of lytic skull lesions. *Hum Pathol* 1993;**24**:438-41.
- 3 **Beatty RM**, Hornig GW, Hanson J. Protruding arachnoid granulations mimicking dermoid cysts. *J Pediatr Surg* 1989;**24**:411-3.
- 4 **Roche J**, Warner D. Arachnoid granulations in the transverse and sigmoid sinuses: CT, MR, and MR angiographic appearance of a normal anatomic variation. *Am J Neuroradiol* 1996;**17**:677-83.
- 5 **Leach JL**, Jones BV, Tomsick TA, *et al*. Normal appearance of arachnoid granulations on contrast-enhanced CT and MR of the brain: differentiation from dural sinus disease. *Am J Neuroradiol* 1996;**17**:1523-32.