

SHORT REPORT

Reappraisal of early CT signs to predict the arterial occlusion site in acute embolic stroke

M Koga, Y Saku, K Toyoda, H Takaba, S Ibayashi, M Iida

J Neurol Neurosurg Psychiatry 2003;**74**:649–653

Objective: To elucidate the value of early computed tomographic (CT) signs of stroke in predicting the occlusion site in the cerebral arteries.

Patients: 105 consecutive patients with acute embolic stroke affecting the anterior circulation.

Methods: Four early signs were evaluated on cranial CT within six hours of stroke onset: loss of the insular ribbon (LIR); attenuation of the lentiform nucleus (ALN); hemispherical sulcus effacement (HSE); and the hyperdense middle cerebral artery sign (HMCAS). The arterial occlusion site was definitively identified on cerebral angiography within two hours of the CT examination.

Results: LIR was present in 55% of patients with internal carotid artery occlusion. ALN was present in 65% of patients with occlusion of the sphenoidal portion (M1) of the middle cerebral artery. HSE was present in 47% of patients with middle cerebral artery branch occlusion. LIR was related independently to internal carotid artery occlusion (odds ratio (OR) 2.8 (95% confidence interval, 1.2 to 6.8)), ALN to M1 occlusion (OR 2.9 (1.2 to 7.4)), and isolated HSE without ALN or LIR to branch occlusion (OR 12.8 (3.2 to 51.5)). The combined presence of the three signs was indicative of internal carotid artery occlusion ($p < 0.05$), and the presence of ALN and LIR without HSE was indicative of M1 occlusion ($p < 0.05$) by univariate analysis. HMCAS bore no relation to either arterial occlusion site.

Conclusions: LIR, ALS, HSE, and combinations of these were useful predictors of the arterial occlusion site.

Although combined diffusion and perfusion weighted imaging has played an important role in the evaluation of acute stroke in recent years, computed tomography (CT) is still an essential imaging mode for the initial diagnosis of acute brain ischaemia in most institutes round the world.^{1,2} In the first 24 hours after the onset of ischaemic stroke, CT does not reveal very much, but there are some important early abnormal signs, including loss of the insular ribbon (LIR),³ attenuation of the lentiform nucleus (ALN),^{4,5} hemispherical sulcus effacement (HSE),^{3,5} and the hyperdense middle cerebral artery sign (HMCAS).^{6,7} Following several studies on early CT signs in relatively small populations,^{3–7} Moulin *et al* verified a strong correlation between these signs and subsequent infarct location in a study of 100 consecutive patients.⁸

The arterial occlusion site influences the outcome of thrombolytic treatment in the acute phase of stroke. Thrombolysis fails to recanalise acute occlusions of the internal carotid artery, and may increase the risk of haemorrhagic transformation.^{9,10} However, intra-arterial infusion of recombinant prourokinase recanalised 66% of the middle cerebral artery occlusions, and improved the outcome of acute stroke caused by occlusions of that vessel.¹¹ Intravenous thrombolysis was also effective for middle cerebral artery occlusions occur-

ring at the bifurcation or in the peripheral branch.¹² Thus prediction of the site of arterial occlusion at the time of initial diagnosis is very important for deciding the appropriate treatment strategy in the hyperacute phase.

Our aim in this study was to determine the value of early CT signs in predicting the arterial occlusion site in ischaemic strokes involving the anterior circulation, recruiting a consecutive series of patients in appropriate numbers.

METHODS

Between 1989 and 2000, 162 consecutive patients with acute embolic stroke involving the anterior circulation were admitted to St Mary's hospital, Kurume, Japan, and underwent cranial CT within six hours of stroke onset. Embolic stroke was defined on the basis of the criteria for cardiogenic brain embolism established by the Cerebral Embolism Task Force.¹³ Fifty four patients who did not undergo cerebral angiography within two hours of their CT examination were excluded, as were three patients with isolated infarction in the territory of the anterior cerebral artery. Thus the final cohort included 105 patients.

Even in patients treated with intravenous thrombolysis, we generally carried out cerebral angiography. A cardiac or transcerebral embolic source was present in 86 patients. The remaining 19 had aortic or carotid arterial atheroma. Neurological deficits on admission were evaluated using the National Institutes of Health stroke scale (NIHSS).

Non-contrast cranial CT was done with a slice thickness of 10 mm, looking for infarcts or early CT signs (LIR, ALN, HSE, and HMCAS), according to definitions used in Moulin's previous study (fig 1).⁸ Briefly, LIR was defined as decreased precision in delineating the grey-white interface at the lateral margin of the insula; ALN was defined as a decrease in density involving the lentiform nucleus area, including loss of precise delineation of the area; HSE was defined as decreased contrast density inducing a loss of precise delineation of the grey-white interface at the margins of the cortical sulci, corresponding to a localised mass effect; and HMCAS was defined as spontaneous high contrast in the middle cerebral artery. The findings were agreed between two stroke neurologists blinded to the patients' clinical features and to the results of the arteriogram. Both were familiar with neuroradiology.

Conventional angiography ($n = 46$) or digital subtraction angiography ($n = 59$) was done using transfemoral catheterisation. We divided the patients into three groups according to the arterial occlusion site: internal carotid artery occlusion; occlusion of the sphenoidal portion of middle cerebral artery (M1 occlusion); and occlusion of the middle cerebral artery at the bifurcation or the peripheral branch (branch occlusion).

Abbreviations: ALN; attenuation of the lentiform nucleus; HMCAS, hyperdense middle cerebral artery sign; HSE, hemispherical sulcus effacement; LIR, loss of the insular ribbon; NIHSS, National Institutes of Health stroke scale

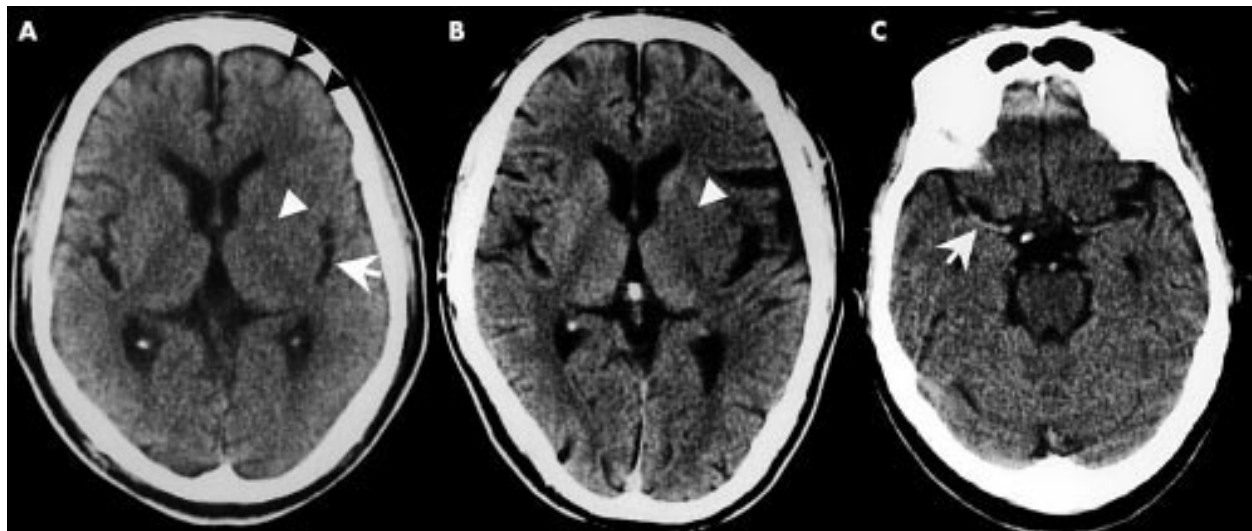


Figure 1 (A) Non-contrast brain computed tomography (CT) of a patient with embolic occlusion of the left internal carotid artery 2.5 hours after onset, showing loss of the insular ribbon (LIR, white arrow), attenuation of the lentiform nucleus (ALN, white arrowhead), hemispherical sulcus effacement (HSE, black arrowheads). (B) Non-contrast brain CT of a patient with embolic occlusion of the sphenoidal portion (M1) of left middle cerebral artery three hours after onset, showing ALN (white arrowhead). (C) Non-contrast brain CT of a patient with embolic occlusion of right M1 1.5 hours after onset, showing the hyperdense middle cerebral artery sign (HMCAS, white arrow).

Thrombolytic treatment was given to some patients within six hours of stroke onset.

We evaluated the following three indicators of therapeutic outcome in the patients: complete or partial recanalisation of the occluded artery documented on angiography one hour after thrombolysis; symptomatic or asymptomatic haemorrhagic transformation of the infarct documented on CT during the hospital admission; and modified Rankin scale score four weeks after stroke onset.

Statistics

Data are presented as mean (SD). In the univariate analysis, categorical variables were compared by the χ^2 test, continuous variables by an unpaired Student *t* test, and scoring variables by the Mann–Whitney U test. Multivariate analysis was done by logistic regression to identify the predictor variables for each arterial occlusion site. Differences were considered significant at a probability (*p*) value of < 0.05.

RESULTS

Sixty two men and 43 women aged 66 (10) years (range 42 to 80) were studied. Median NIHSS score on admission was 16 (range 3 to 30).

CT was undertaken at a mean of 112 (63) minutes (range 13 to 357) after stroke onset. ALN, LIR, or HSE, each indicating parenchymatous ischaemia, was present in 65 patients (62%). The prevalence of each of these three signs and their combinations is shown in table 1. HMCAS was present in 27 patients (26%), 23 of whom also had early parenchymatous signs. A fresh brain infarct was present in two patients (2%) and old infarcts in 32 (30.5%).

Angiography was done at a mean of 210 (68) minutes (range 55 to 410) after stroke onset (99 (48) minutes after CT). Internal carotid artery occlusion was present in 29 patients (28%), M1 occlusion in 34 (32%), and branch occlusion in 38 (36%).

LIR was the most frequent sign in patients with internal carotid artery occlusions (sensitivity 55%), ALN in those with

Table 1 Prevalence of early computed tomographic signs and their association with the site of arterial occlusion

Sign	n	Prevalence	ICA (n=29)	M1 (n=34)	Branch (n=38)	No occlusion (n=4)
LIR, ALN, or HSE	65	62%	18 (62%)	25 (74%)	22 (58%)	0
LIR	39	37%	16 (55%)	16 (47%)	7 (18%)	0
ALN	43	41%	15 (52%)	22 (65%)	6 (16%)	0
HSE	43	41%	12 (41%)	13 (38%)	18 (47%)	0
LIR + ALN + HSE	20	19%	10 (34%)	8 (24%)	2 (5%)	0
LIR + ALN	14	13%	3 (10%)	8 (24%)	3 (8%)	0
LIR + HSE	3	3%	2 (7%)	0	1 (3%)	0
ALN + HSE	3	3%	0	2 (6%)	1 (3%)	0
Isolated LIR	2	2%	1 (3%)	0	1 (3%)	0
Isolated ALN	6	6%	2 (7%)	4 (12%)	0 (0%)	0
Isolated HSE	17	16%	0	3 (9%)	14 (37%)	0
HMCAS	27	26%	10 (34%)	11 (32%)	6 (16%)	0
No sign	36	34%	10 (34%)	8 (24%)	14 (37%)	4 (100%)

Percentages in parentheses indicate sensitivity of early CT sign in each arterial occlusion group. ALN, attenuation of the lentiform nucleus; branch, middle cerebral artery branch occlusion; CT, computed tomography; HMCAS, hyperdense middle cerebral artery sign; HSE, hemispherical sulcus effacement; ICA, internal carotid artery; LIR, loss of insular ribbon; M1, sphenoidal portion of the middle cerebral artery.

Table 2 Predictive factors for arterial occlusion site

	Sensitivity	Specificity	Accuracy	Univariate analysis, p value	Multivariate analysis, OR (95% CI)
ICA occlusion					
Age ≥ 65 years	69%	34%	44%	NS	–
Male	59%	41%	46%	NS	–
NIHSS ≥ 16	62%	47%	51%	NS	–
LIR	55%	70%	66%	<0.05	2.8 (1.2 to 6.8)†
ALN	52%	63%	60%	NS	–
HSE	41%	59%	54%	NS	–
LIR+ALN+HSE	35%	87%	72%	<0.05	–
LIR+ALN	10%	86%	65%	NS	–
Isolated HSE	0%	78%	56%	<0.005*	–
HMCAS	35%	78%	66%	NS	–
M1 occlusion					
Age ≥ 65 years	62%	31%	41%	NS	–
Male	62%	42%	49%	NS	–
NIHSS ≥ 16	79%	56%	64%	<0.001	3.4 (1.2 to 9.4)†
LIR	47%	68%	61%	NS	–
ALN	65%	70%	69%	<0.001	2.9 (1.2 to 7.4)†
HSE	38%	58%	51%	NS	–
LIR+ALN+HSE	24%	83%	64%	NS	–
LIR+ALN	24%	92%	70%	<0.05	–
Isolated HSE	9%	80%	57%	NS	–
HMCAS	32%	78%	63%	NS	–
Branch occlusion					
Age ≥ 65 years	71%	36%	49%	NS	–
Male	58%	40%	47%	NS	–
NIHSS < 16	66%	67%	67%	<0.005	5.0 (1.6 to 10.0)†
LIR	18%	52%	40%	<0.005*	–
ALN	16%	45%	34%	<0.0001*	–
HSE	47%	63%	57%	NS	–
LIR+ALN+HSE	5%	73%	49%	<0.01*	–
LIR+ALN	8%	84%	56%	NS	–
Isolated HSE	37%	96%	74%	<0.0001	12.8 (3.2 to 51.5)‡
HMCAS	16%	69%	50%	NS	–

*Significantly lower than the other occlusion groups.

†p < 0.05, ‡p < 0.0005.

Variables in bold have significance.

ALN, attenuation of the lentiform nucleus; branch, middle cerebral artery branch occlusion; HMCAS, hyperdense middle cerebral artery sign; HSE, hemispherical sulcus effacement; ICA, internal carotid artery; LIR, loss of insular ribbon; M1, sphenoidal portion of the middle cerebral artery; NIHSS, National Institutes of Health stroke scale.

M1 occlusions (sensitivity 65%), and HSE in those with branch occlusions (sensitivity 47%). Among combinations of these three signs, LIR+ALN+HSE seemed to indicate internal carotid artery occlusion (34%) or M1 occlusion (24%), LIR+ALN to indicate M1 occlusion (24%), and isolated HSE without LIR or ALN to indicate branch occlusion (37%). HMCAS seemed to indicate internal carotid artery occlusion (34%) or M1 occlusion (32%).

Possible predictive factors for arterial occlusion site were identified by univariate analysis for age, sex, NIHSS score, and the presence of each of the early signs alone or in combination (table 2). After multivariate analysis using the factors as independent variables, LIR was related independently to internal carotid artery occlusion (odds ratio (OR), 2.8 (95% confidence interval (CI), 1.2 to 6.8)); NIHSS score ≥ 16 (OR 3.4 (1.2 to 9.4)) and ALN (OR 2.9 (1.2 to 7.4)) to M1 occlusion; and NIHSS score < 16 (OR 5.0 (1.6 to 10.0)) and isolated HSE (OR 12.8 (3.2 to 51.5)) to branch occlusion. HMCAS, either alone or in combination with other signs, was not an independent indicator of any arterial occlusion site.

Thrombolytic treatment during the hyperacute stage of stroke was given in 81 patients, 52 intra-arterially and 29 intravenously; 25 were given tissue plasminogen activator (tPA) and 56 were given urokinase. Among these treated patients, 34 (42%) showed recanalisation of the occluded artery, 44 (54%) showed haemorrhagic infarction, and 29 (36%) showed good functional prognosis corresponding to a

modified Rankin scale score of between 0 and 2. Arterial recanalisation was documented less often in patients with than without LIR (p < 0.03, table 3). Haemorrhagic infarction was more often found in patients with LIR (p < 0.03), ALN (p < 0.02), HMCAS (p < 0.05), or combinations of these signs (p < 0.02) than in patients without those signs. None of the CT signs was significantly correlated with good functional prognosis. The site of arterial occlusion in these 81 patients was internal carotid artery in 18 (62% of all patients with internal carotid artery occlusion), M1 in 32 (94%), and the middle cerebral artery branch in 31 (82%). Arterial recanalisation was documented in 22% of patients with internal carotid artery occlusion, in 44% of those with M1 occlusion, and in 52% of those with branch occlusion (p > 0.1); haemorrhagic infarction occurred in 72%, 69%, and 29%, respectively (p < 0.001); a good functional outcome was likely in 11%, 41%, and 45%, respectively (p < 0.05).

DISCUSSION

This is the first study on early CT signs as predictors of the arterial occlusion site in embolic stroke using a relatively large population. All parenchymatous signs and their combinations were useful for predicting internal carotid artery, M1, or branch occlusions. Our results assessing the vascular lesions causing infarction make a good contrast with those of Moulin *et al.*,⁸ who assessed subsequent infarcts.

Table 3 Correlation of early computed tomographic signs with therapeutic outcome

Early CT signs	n	Recanalisation (n=34)	Haemorrhagic infarction (n=44)	mRS 0-2 (n=29)
LIR	31	24% v 49% (p<0.03)	50% v 24% (p<0.03)	28% v 44% (NS)
ALN	36	32% v 53% (0.05<p<0.1)	57% v 30% (p<0.02)	38% v 48% (NS)
HSE	36	47% v 37% (NS)	52% v 35% (NS)	45% v 44% (NS)
LIR, ALN, or HSE	53	38% v 50% (NS)	64% v 36% (p<0.02)	36% v 36% (NS)
HMCAS	27	32% v 46% (NS)	36% v 16% (<0.05)	21% v 31% (NS)

Percentage of each therapeutic outcome between patients with and without CT signs.

ALN, attenuation of the lentiform nucleus; CT, computed tomography; HMCAS, hyperdense middle cerebral artery sign; HSE, hemispherical sulcus effacement; LIR, loss of insular ribbon; mRS, modified Rankin scale.

Loss of insular ribbon

The strong correlation between LIR and internal carotid artery occlusion in our present study is not in agreement with the suggestion in the original study³ that LIR might result from middle cerebral artery occlusion distal to the lateral striate arteries. In contrast, the dominant appearance of extended infarcts in the middle cerebral artery territory in patients with LIR in Moulin's later study⁸ appears to support our results to some extent. LIR hardly ever appeared alone in the present study, and more than half the patients with LIR also had ALN and HSE. The concomitant presence of these three signs also seemed to indicate internal carotid artery occlusion. After the European cooperative acute stroke study (ECASS) trial first indicated that hypoattenuation in more than 33% of the middle cerebral artery territory was a predictor of fatal outcome with thrombolytic treatment,¹⁴ subsequent studies stressed this major early finding and paid little attention to LIR.^{2 15 16} In contrast, the rt-PA stroke study group of the National Institute of Neurological Disorders and Stroke (NINDS) indicated that patients treated with tPA had a favourable outcome even if they had hypoattenuation in more than 33% of the middle cerebral artery territory.¹⁷ Thus the diagnostic significance of this major early finding in relation to the use of thrombolysis is in dispute. Based on the present results, a combination of LIR and > 33% hypoattenuation of the middle cerebral artery territory may be a promising warning sign against the use of thrombolysis.

Attenuation of the lentiform nucleus

In the original studies,^{4 5} all the acute stroke patients with angiographically proven internal carotid artery or M1 occlusion had ALN, presumably because the lentiform nucleus is fed by lenticulostriate arteries from M1 without collateral flow from cortical anastomoses. In the present study, ALN was also highly predictive of M1 occlusion, but was not present in all patients with this type of lesion. This might reflect the timing of CT. The presence of ALN in 16% of patients with branch occlusions appeared to result from variation in the lenticulostriate arteries, which arise from the middle cerebral artery branch in around 20% of cases.¹⁸

Hemispherical sulcus effacement

In contrast to LIR or ALN, HSE reflects cortical ischemia. Isolated HSE without LIR or ALN was highly indicative of branch occlusion in this study, and of a partial superficial infarct in the middle cerebral artery territory in the previous study.⁸ Thus isolated HSE in stroke patients seems to be a good indication for intravenous thrombolysis.¹²

Treatment

Thrombolytic treatment was selected on the basis of the angiographic findings in this study. Many patients with internal carotid artery occlusion did not undergo thrombolysis. In spite of this selection bias, there were some interesting correlations between early CT signs and therapeutic outcome. Patients with LIR had poor arterial recanalisation, presumably because patients with internal carotid artery occlusion have a

poor recanalisation rate and LIR has a strong correlation with internal carotid artery occlusion. Patients with HSE did not often have haemorrhagic infarction, presumably because patients with branch occlusion also did not often have haemorrhagic infarction, and HSE was strongly correlated with branch occlusion. The relatively small patient population related to the above mentioned selection bias may be the reason why early CT signs did not predict functional outcome in the chronic stage.

Limitations

Patients with high NIHSS scores on admission often failed to get their angiography within two hours after CT and so were excluded from the study. Internal carotid artery occlusion might well be the leading vascular lesion in these excluded patients, because this often causes large and fatal infarction in the middle cerebral artery territory.¹⁹ Thus the exclusion of such patients may have affected our results with respect to internal carotid artery occlusion. The strong correlation of a high NIHSS score with M1 occlusion, but not with internal carotid artery occlusion, seems to be a reflection of this possible bias. Another limitation of our results was that the sensitivity of each early ischaemic sign is rather low. In practical clinical situations, combining the information obtained from CT with, for example, carotid ultrasonography seems to be important for decisions about treatment in acute stroke. The CT analysts in this study were stroke specialists who were familiar with neuroradiology. However, even for experienced stroke specialists, there is considerable lack of agreement in recognising and qualifying the early CT changes.²⁰ Improvements in diagnostic methods for identifying early CT signs are expected. Finally, we should bear in mind that CT equipment upgrades over the 11 year period of the study may have introduced some differences in image quality that could have influenced our results.

Conclusions

A combination of early parenchymatous CT signs is important in predicting the arterial occlusion site in the acute stage of ischaemic stroke.

Authors' affiliations

M Koga, Y Saku, H Takaba, Division of Cerebrovascular Disorders, St Mary's Hospital, Kurume, Fukuoka, Japan
S Ibayashi, M Iida, Department of Medicine and Clinical Science, Graduate School of Medical Sciences, Kyushu University, Fukuoka
K Toyoda, Department of Cerebrovascular Disease, National Kyushu Medical Centre, Fukuoka

Competing interests: none declared

Correspondence to: Dr Kazunori Toyoda, Department of Cerebrovascular Disease, National Kyushu Medical Centre, 1-8-1 Jigyohama, Chuo-ku, Fukuoka 810-8563, Japan; toyoda@qmed.hosp.go.jp

Received 26 April 2002
In revised form 9 October 2002
Accepted 15 January 2003

REFERENCES

- 1 Barber PA, Demchuk AM, Zhang J, *et al*. Validity and reliability of a quantitative computed tomography score in predicting outcome of hyperacute stroke before thrombolytic therapy. ASPECTS Study Group. Alberta Stroke Programme Early CT Score. *Lancet* 2000;**355**:1670–4.
- 2 Grund M, von Kummer R, Sobesky J, *et al*. Early x-ray hypoattenuation of brain parenchyma indicates extended critical hypoperfusion in acute stroke. *Stroke* 2000;**31**:133–9.
- 3 Truwit CL, Barkovich AJ, Gean-Marton A, *et al*. Loss of the insular ribbon: another early CT sign of acute middle cerebral artery infarction. *Radiology* 1990;**176**:801–6.
- 4 Tomura N, Uemura K, Inugami A, *et al*. Early CT finding in cerebral infarction: obscuration of the lentiform nucleus. *Radiology* 1988;**168**:463–7.
- 5 Bozzao L, Bastianello S, Fantozzi LM, *et al*. Correlation of angiographic and sequential CT findings in patients with evolving cerebral infarction. *Am J Neuroradiol* 1989;**10**:1215–22.
- 6 Gács G, Fox AJ, Barnett HJ, *et al*. CT visualization of intracranial arterial thromboembolism. *Stroke* 1983;**14**:756–62.
- 7 Pressman BD, Tourje EJ, Thompson JR. An early CT sign of ischemic infarction: increased density in a cerebral artery. *Am J Roentgenol* 1987;**149**:583–6.
- 8 Moulin T, Cattin F, Crépin-Leblond T, *et al*. Early CT signs in acute middle cerebral artery infarction: predictive value for subsequent infarct locations and outcome. *Neurology* 1996;**47**:366–75.
- 9 Jansen O, von Kummer R, Forsting M, *et al*. Thrombolytic therapy in acute occlusion of the intracranial internal carotid artery bifurcation. *Am J Neuroradiol* 1995;**16**:1977–86.
- 10 Jahan R, Duckwiler GR, Kidwell CS, *et al*. Intraarterial thrombolysis for treatment of acute stroke: experience in 26 patients with long-term follow-up. *Am J Neuroradiol* 1999;**20**:1291–9.
- 11 Furlan A, Higashida R, Wechsler L, *et al*. Intra-arterial prourokinase for acute ischemic stroke. The PROACT II study: a randomized controlled trial. Prolyse in acute cerebral thromboembolism. *JAMA* 1999;**282**:2003–11.
- 12 del Zoppo GJ, Poeck K, Pessin MS, *et al*. Recombinant tissue plasminogen activator in acute thrombotic and embolic stroke. *Ann Neurol* 1992;**32**:78–86.
- 13 Cerebral Embolism Task Force. Cardiogenic brain embolism. *Arch Neurol* 1986;**43**:71–84.
- 14 Hacke W, Kaste M, Fieschi C, *et al*. Intravenous thrombolysis with recombinant tissue plasminogen activator for acute hemispheric stroke. The European Cooperative Acute Stroke Study (ECASS). *JAMA* 1995;**274**:1017–25.
- 15 von Kummer R, Allen KL, Holle R, *et al*. Acute stroke: usefulness of early CT findings before thrombolytic therapy. *Radiology* 1997;**205**:327–33.
- 16 Kucinski T, Koch C, Grzyska U, *et al*. The predictive value of early CT and angiography for fatal hemispheric swelling in acute stroke. *Am J Neuroradiol* 1998;**19**:839–46.
- 17 Patel SC, Levine SR, Tilley BC, *et al*. Lack of clinical significance of early ischemic changes on computed tomography in acute stroke. *JAMA* 2001;**286**:1830–8.
- 18 Jain KK. Some observations on the anatomy of the middle cerebral artery. *Can J Surg* 1964;**7**:134–9.
- 19 Heinsius T, Bogousslavsky J, van Melle G. Large infarcts in the middle cerebral artery territory: etiology and outcome patterns. *Neurology* 1998;**50**:341–50.
- 20 Grotta JC, Chiu D, Lu M, *et al*. Agreement and variability in the interpretation of early CT changes in stroke patients qualifying for intravenous tPA therapy. *Stroke* 1999;**30**:1528–33.

NEUROLOGICAL STAMP

Egas Moniz (1874–1955)

Moniz had a distinguished political career before beginning serious neurological investigation at what some would consider the advanced age of 51. He was named Antonio Caetano de Abreu Freire Egas Moniz. His godfather added Egas Moniz and Moniz took this name when a student in Pamplona—Egas Moniz was a hero of the Portuguese resistance in the Portuguese wars against the Moors in the 12th century. Moniz graduated in 1899 from the University of Coimbra. He soon became professor of internal medicine with a special interest in diseases of the nervous system. Early fame was achieved following a scandalous book on sexology, written in 1901. In 1911 he became professor of neurology in Lisbon until his retirement in 1944. He was also pursuing a successful political career. Moniz supported a republican form of government, breaking with his family's traditional support for the monarchy. His political beliefs led to several brief periods in jail, twice as a student for participating in demonstrations and later when, as Dean of the Medical School in Lisbon, he prevented police from entering the campus to quell student protest. In 1900 he was elected to parliament and was re-elected several times over the next 15 years. During the first world war he was Ambassador to Spain and after the war, Minister of External Affairs. He represented Portugal at the 1918 Versailles Peace Conference. Moniz retired from politics in 1926 following a coup d'état that brought Antonio de Oliveira Salazar to power.



This stable dictatorship ended liberal democracy in Portugal for the rest of Moniz's life. In 1926, aged 51, he began his work on cerebral angiography. In collaboration with Almeida Lima he injected radio-opaque dyes into arteries, which enabled the cerebral vessels to be photographed. By 1927 it was possible to show that displacement in the cerebral circulation could infer the presence and location of brain tumours. A detailed account of the technique was published in 1931. Moniz became better known for his introduction, in 1935, of the operation of prefrontal leukotomy. It was for this work, described by the Nobel authorities as "one of the most important discoveries ever made in psychiatric medicine" that they awarded him the 1949 Nobel Prize for physiology or medicine. The operative technique was suggested to Moniz after hearing an account by John Fulton and Carlyle Jacobsen in 1935 of a refractory chimpanzee who

became less aggressive after its frontal lobes had been excised. Moniz invented a eukotome, which was a wire snare that passed into the posterior aspect of each frontal lobe and rotated in order to cut the white matter. He used the leukotome on December 27 1935, on two patients with paranoid schizophrenia. He named the procedure prefrontal leukotomy. Moniz had hoped that his pioneering work on angiography would be recognised with a Nobel Prize. He was nominated twice for the prize in 1928 and 1933.

Gambling was one of Moniz's interests, and he wrote a treatise on the history of playing cards. He prepared several biographies, including one of Pope John XXI, or Petrus Hispanus, the only physician ever to become Pope. In 1974, on the centenary of his birth, his portrait, the leukotome, and angiogram were shown in stamps issued by Portugal (Stanley Gibbons no 1558–1560, Scott no 1241–1243).

L F Haas