

## SHORT REPORT

## Pseudosubarachnoid haemorrhage in subdural haematoma

A A Rabinstein, S J Pittock, G M Miller, J J Schindler, E F M Wijdicks

*J Neurol Neurosurg Psychiatry* 2003;74:1131-1132

Two patients with large bilateral subdural haematomas with patterns of non-enhanced brain computed tomography (CT) falsely suggesting coexistent subarachnoid haemorrhage are presented. The CT images showed marked effacement of the basal cisterns with hyperdense signal along the tentorium, sylvian fissure, and the perimesencephalic cisterns. In both cases, the suspicion of subarachnoid haemorrhage led to the performance of angiographic studies to rule out vascular lesions. Thus, recognition of this radiological feature is important to avoid unnecessary testing and treatment delay.

The typical clinical presentations of subdural haematoma (SDH) and subarachnoid haemorrhage (SAH) are distinctly different, but acute exacerbations of SDH can sometimes show overlapping features. In such cases and when a reliable history is unavailable, the differentiation between these two entities relies on the computed tomography (CT) scan findings. In addition, SDH and SAH can coexist in traumatic brain injury and, exceptionally, after aneurysmal rupture.<sup>1</sup>

Although CT scan is a very sensitive and specific technique for diagnosing SAH, non-enhanced CT scans can occasionally appear to display subarachnoid blood when none is actually present. However, pseudosubarachnoid haemorrhage is not universally known as a radiological pitfall and is barely mentioned in the neurology, neurosurgical, and emergency medicine literature. Misleading CT images have been described in anoxic-ischaemic encephalopathy with brain swelling,<sup>2</sup> purulent meningitis, venous sinus thrombosis, and after angiography.<sup>3</sup> Additionally, false impression of blood exclu-

sively along the tentorium and falx has been reported in patients with brain masses, methanol poisoning, and even in healthy children and adults.<sup>4</sup>

We describe two patients with large bilateral SDHs and two CT scan patterns falsely suggesting coexistent SAH, resulting in the performance of cerebral angiographic studies to exclude underlying vascular anomalies.

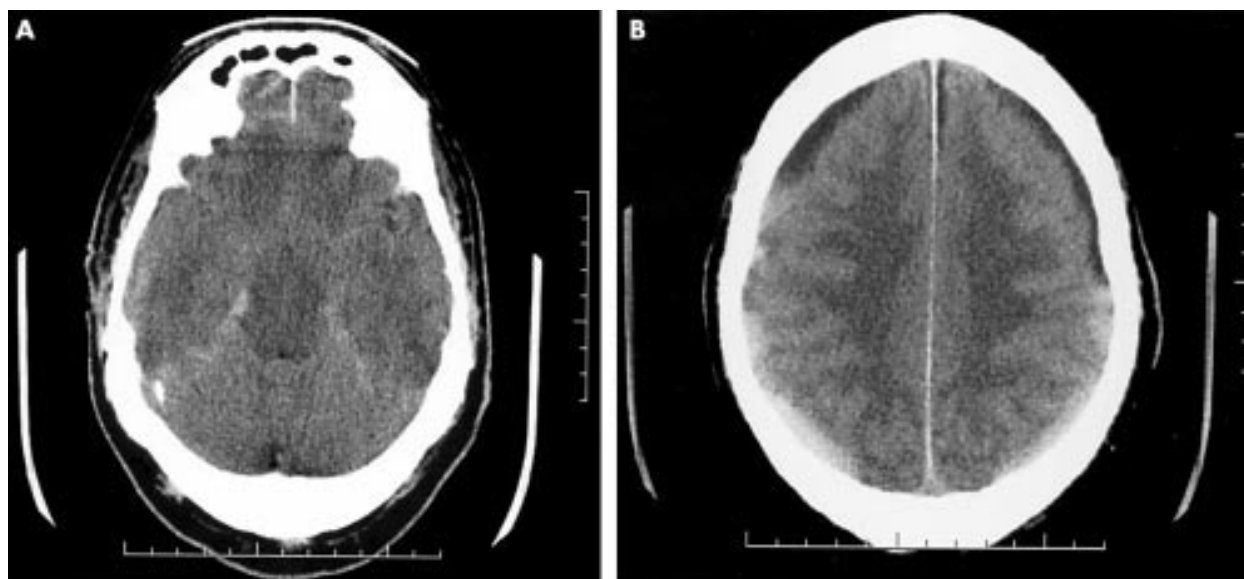
**PATIENT 1**

A 68 year old man with prior cardiac arrhythmias requiring pacemaker and long standing anticoagulation presented with increasing headaches and progressive dullness for two weeks. Neither he nor his wife could recall any head injury. Head CT scan showed bilateral chronic and subacute SDHs, marked effacement of basilar cisterns and third ventricle, and increased density along the tentorium interpreted as blood (fig 1). Progressive decline in his level of consciousness prompted the performance of a CT angiogram that was unremarkable. On transfer to our hospital, the patient was drowsy but able to follow simple commands intermittently. His speech was unintelligible, and he had brisk reflexes but no focal weakness. Surgical evacuation of the subdural collections through bilateral burr holes was followed by frank clinical improvement.

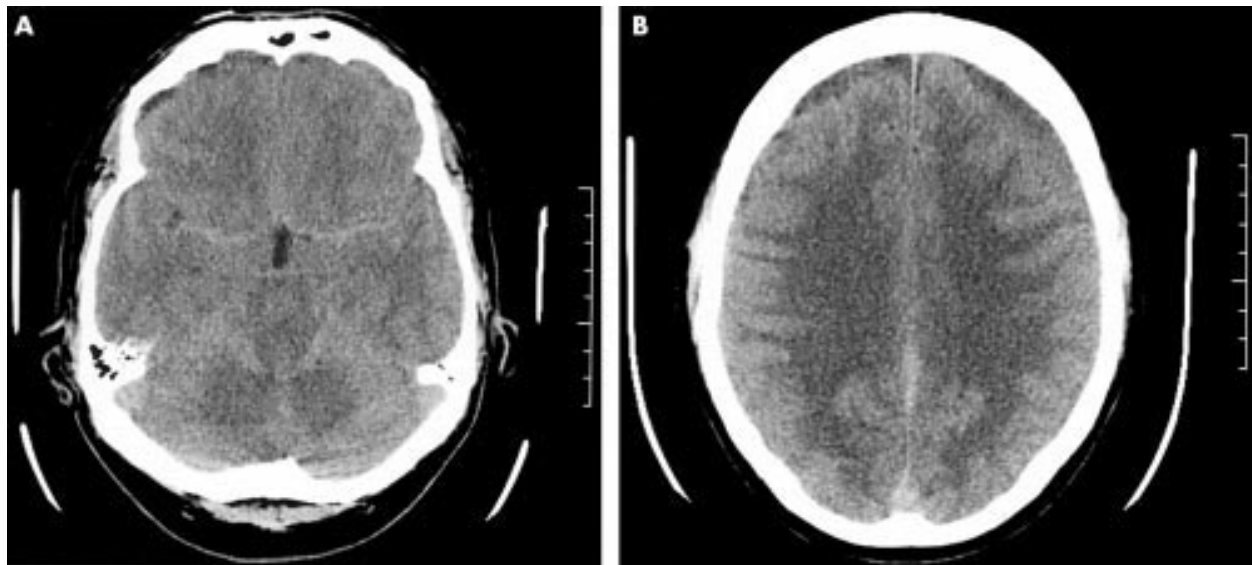
**PATIENT 2**

A 52 year old man developed severe head and neck pain while working on his yard. Over the next few days, the pain became

**Abbreviations:** CT, computed tomography; MRI, magnetic resonance imaging; SAH, subarachnoid haemorrhage; SDH, subdural haematoma



**Figure 1** Non-enhanced head CT scan showing increased density along the tentorium with pronounced effacement of basilar cisterns (left) and, in a higher cut, bilateral chronic and subacute subdural haematomas exerting mass effect (right).



**Figure 2** Non-enhanced head CT scan displaying increased density in basilar cisterns and Sylvian fissures (left) and, at a higher level, bilateral isodense to hypodense subdural haematomas with mass effect (right).

disabling. He was admitted to a local hospital where he was noted to be abulic but oriented and severely distressed by headache and nausea. Examination revealed slight bilateral papilloedema, and bilateral hyperreflexia and Babinski signs. Head CT scan showed bilateral subacute SDHs with mass effect, basilar cistern effacement, slit-like ventricles, and hyperdensity in the basal subarachnoid space (fig 2). A conventional cerebral angiogram was normal. Brain magnetic resonance imaging (MRI) confirmed the presence of the SDHs producing diffuse mass effect. The patient was transferred to our hospital for treatment, and his bilateral subdural collections were drained through multiple burr holes. The symptoms markedly improved after surgery.

## DISCUSSION

Non-enhanced CT scans in our patients showed bilateral large SDHs producing effacement of sulci and basilar cisterns and the false impression of blood in the subarachnoid space and the tentorium. Neither patient had been exposed to intravascular contrast before the CT scans. In both cases, the interpretation of the CT scan findings prompted the performance of angiographic studies. Evacuation of the subdural collections resulted in clinical improvement and rapid resolution of the CT hyperdensities in the subarachnoid space.

Although the true frequency of false SAH in patients with bilateral SDH is difficult to establish, this finding has remained largely unnoticed in the literature.<sup>5,6</sup> Its occurrence is probably a reflection of prominent mass effect. Increased volume in the supratentorial compartment produces compression and effacement of the subarachnoid spaces that, combined with the ensuing vascular congestion, could result in increased density on CT scan.<sup>6</sup> Resolution of the mass effect can lead to disappearance of regional hyperdensities.<sup>6</sup>

Using MRI with fluid attenuated inversion recovery (FLAIR) sequences has been reported to increase the sensitivity of the radiological diagnosis of SAH.<sup>7</sup> It is possible that timely MRI could prevent unnecessary angiographic studies, and it should be considered before proceeding with more invasive tests. Xanthochromic cerebrospinal fluid is diagnostic of SAH but performing lumbar puncture in patients with pronounced mass effect from SDH may be potentially dangerous. In addition, it remains essential to concentrate on the CT scan features that may help distinguish true SAH. Distribution of blood along the interhemispheric fissure and medial frontal sulci determines a rather irregular pattern of hyperdensity in

true SAH as opposed to the much smoother line often seen in other conditions.<sup>8</sup> More relevant to our cases, in true SAH, it would be highly unlikely to observe marked effacement of sulci and basal cisterns in the absence of thick layers of subarachnoid blood or an intraparenchymal haematoma.<sup>2</sup> Similarly, hydrocephalus would be expected, as opposed to slit-like ventricles, as a result of obstruction of cerebrospinal fluid reabsorption.

We think it is important to call attention to this neuroradiological feature that may lead away from the underlying disorder and result in unnecessary testing and treatment delay.

## Authors' affiliations

**A A Rabinstein, S J Pittock, E F M Wijdicks**, Department of Neurology, Saint Marys Hospital, Mayo Medical Center

**G M Miller**, Department of Radiology, Saint Marys Hospital, Mayo Medical Center

**J J Schindler**, Department of Neurosurgery, Saint Marys Hospital, Mayo Medical Center

Competing interests: none declared

Correspondence to: Dr E FM Wijdicks, Mayo Clinic, Department of Neurology, W8B, 200 First Street SW, Rochester, MN 55905, USA; wjide@mayo.edu

Received 23 September 2002

Accepted 4 February 2003

## REFERENCES

- 1 Weir B, Myles T, Kahn M, et al. Management of acute subdural hematomas from aneurysmal rupture. *Can J Neurol Sci* 1984;**11**:371-6.
- 2 Phan TG, Wijdicks EFM, Worrell GA, et al. False subarachnoid hemorrhage in anoxic encephalopathy with brain swelling. *J Neuroimaging* 2000;**10**:236-8.
- 3 Opekin K, Silberstein M. False positive diagnosis of subarachnoid hemorrhage on computer tomography scan. *J Clin Neurosci* 1998;**5**:382-6.
- 4 Spiegel SM, Fox AJ, Vinuela F, et al. Increased density of tentorium and falx: a false positive CT sign of subarachnoid hemorrhage. *J Can Assoc Radiol* 1986;**37**:243-7.
- 5 Tokuno T, Sato S, Kawakami Y, et al. Bilateral chronic subdural hematomas presented with subarachnoid hemorrhage: report of two cases. *No Shinkei Geka* 1996;**24**:573-7.
- 6 Huang D, Abe T, Ochiai S, et al. False positive appearance of subarachnoid hemorrhage on CT with bilateral subdural hematomas. *Radiat Med* 1999;**17**:439-42.
- 7 Noguchi K, Ogawa T, Seto H, et al. Subacute and chronic subarachnoid hemorrhage: diagnosis with fluid-attenuated inversion recovery MR imaging. *Radiology* 1997;**203**:257-62.
- 8 al-Yamany M, Deck J, Bernstein M. Pseudo-subarachnoid hemorrhage: a rare neuroimaging pitfall. *Can J Neurol Sci* 1999;**26**:57-9.