

<10); thyroid stimulating antibody 207% (normal <150)). Serological examination for antiganglioside antibodies revealed anti-GM1 IgG, and the titre was 25 900 (normal <800) by enzyme linked immunosorbent assay. No other antiganglioside antibodies were detected by thin layer chromatography immunoblotting. Antimyelin associated glycoprotein and antinuclear antibody were not detected. Cerebrospinal fluid (CSF) cell count was 4/mm<sup>3</sup> and protein level was 53 mg/dl (normal <45). Oligoclonal bands and myelin basic protein were not detected.

Motor nerve conduction velocities (MCV, m/sec) and distal compound muscle action potential amplitudes (CMAP, mV) were as follows: median nerve 52.5 (normal >49) and 0.4 (normal >5); ulnar nerve 45.5 (normal >48) and 2.7 (normal >4); tibial nerve 40.0 (normal >50) and 3.8 (normal >7); peroneal nerve 36.9 (normal >48) and 1.2 (normal >3), respectively. Conduction blocks were observed bilaterally in the ulnar and peroneal nerves at the common sites of entrapment. Sensory nerve conduction velocity was 37.8 m/sec (normal >48) in the median nerve and was not evoked in the sural nerve. The patient was diagnosed as having CIDP and Graves' disease. After treatment with thiamazole, thyroid function and levels of thyroid related autoantibodies normalised but the peripheral neuropathy remained. Muscle weakness and numbness improved following treatment with prednisolone at 50 mg/day and pulse intravenous methyl prednisolone 1 g/day for three days in June 1999 but his symptoms exacerbated again after five months. Diabetes and hyperthyroidism were well controlled, but anti-GM1 IgG titre was elevated to between 11 900 and 40 700. Despite intravenous immunoglobulin (IVIg) therapy, he suddenly had convulsions and consciousness disturbance on 11 May 2000. CSF examination showed a normal cell count, but the protein level was increased to 121 mg/dl. Nerve conduction studies revealed further reduction in CMAP amplitude with conduction block and delayed MCVs. Brain magnetic resonance imaging (MRI) demonstrated slightly high intensity signals in frontal white matter on T2-weighted image (fig 1A, arrow). Intra-arterial angiography showed no evidence of a cerebrovascular accident. His consciousness disturbance responded partially to treatment with pulse methyl prednisolone, IVIg, and plasma exchange. However, a T2-weighted MRI in June 2000 showed large high intensity signals in the right frontal cortex and white matter (fig 1B). Some of the lesions were enhanced with Gd-DTPA on a T1-weighted image. In July 2000, the lesions were enlarged in the cerebral cortex and white matter (fig 1C). Despite repeated immunomodulating therapies, he died on 17 August 2000. An autopsy of the brain showed disseminated multiple plaques in the pons and bilaterally in the cerebral white matter (fig 1D), corresponding to demyelination and axonal loss (fig 1E(1)). Haemorrhagic transformations with mild infiltration of inflammatory cells in the vascular and perivascular regions were observed in the temporal cortex (fig 1E(2)) and cerebellar hemisphere. Peripheral nerve roots obtained from the lumbar plexus exhibited vasculitic occlusion of small epineurial and endoneurial vessels with inflammatory cell infiltration (fig 1E(3)) and demyelination and axonal degeneration (fig 1E(4)). Immunohistochemical study revealed intense signals for IgG, C3, and C4

in vessels from the temporal cortex, white matter, and peripheral nerve root (fig 1F), but the signals were unremarkable in specimens of unaffected regions. Vasculitis was not evident except for in the nervous system.

## Discussion

The present patient showed chronic sensorimotor polyneuropathy similar to CIDP. However, the most prominent feature was lethal encephalopathy and isolated vasculitis in the nervous system. The brain lesions mainly consisted of demyelinating changes in the white matter, but the lesions in the temporal cortex and peripheral nerve roots indicated vasculitis. Immune deposits of IgG and complements were detected in the vascular regions only in the affected regions of the nervous system. The immune deposits may be associated with vascular damage resulting in cortical haemorrhagic transformation. To the best of our knowledge, this is the first report of histopathological analysis of CNS involvement in vasculitic neuropathy with no evidence of systemic collagen disease.

Anti-GM1 antibody is occasionally detected in patients with CIDP or systemic collagen disease with neurological manifestations.<sup>2</sup> However, it has not been studied in patients with non-systemic vasculitic neuropathy. Brain endothelial cells and endoneurial cells share GM1 ganglioside antigens with peripheral nerve tissues, and anti-GM1 antibody facilitates leakage in the blood-nerve barrier.<sup>3</sup> These findings indicate that anti-GM1 antibody might have induced demyelinating change and vascular damage in both the PNS and CNS of the present patient. It is noteworthy that CNS white matter lesions have been detected in patients with CIDP.<sup>4</sup> Interestingly, anti-asialo-GM1 antibody has been frequently detected in patients with Graves' disease or Hashimoto's thyroiditis.<sup>5</sup> Although Graves' disease may have contributed to the development of the encephalopathy, lethal encephalopathy is an extremely unusual outcome not only in non-systemic vasculitic neuropathy but also in thyrotoxic autoimmune encephalopathy.<sup>6</sup>

In conclusion, vasculitic neuropathy seemed to have resulted in the development of lethal encephalopathy in the present patient. Furthermore, a common autoimmune mechanism mediated by anti-GM1 antibody similar to that in CIDP may have been involved in the lesions in the CNS as well as PNS.

## Acknowledgements

We would like to thank Drs Y Oshima and Y Sato for their clinical assistance, Dr H Yoshino, Kohnodai Hospital, National Center of Neurology and Psychiatry, for his extensive analysis of antiglycosphingolipid antibodies, and Dr T Komori, Tokyo Metropolitan Institute for Neuroscience, for his helpful comments.

### Y Sumitomo, M Kunishige

Department of Medicine and Bioregulatory Sciences, University of Tokushima Graduate School of Medicine, Tokushima, Japan

### N Satake

Department of Molecular and Environmental Pathology, University of Tokushima Graduate School of Medicine, Tokushima, Japan

### K Shinno

Department of Neurosurgery, University of Tokushima Graduate School of Medicine, Tokushima, Japan

### M Kawashima, T Matsumoto, T Mitsui

Department of Medicine and Bioregulatory Sciences, University of Tokushima Graduate School of Medicine, Tokushima, Japan

Correspondence to: Dr M Kunishige, Department of Medicine and Bioregulatory Sciences, University of Tokushima Graduate School of Medicine, 3-18-15 Kuramoto-cho, Tokushima 770-8503, Japan; kuni@clin.med.tokushima-u.ac.jp

doi: 10.1136/jnnp.2003.031997

Competing interests: none declared

## References

- Collins MP, Periquet MI, Mendell JR, *et al*. Nonsystemic vasculitic neuropathy: insights from a clinical cohort. *Neurology* 2003;**61**:623-30.
- Hirano T, Miyajima H, Taniguchi O, *et al*. Anti-asialo GM1 antibody detected in the patients' sera from systemic lupus erythematosus and Behçet's diseases with neurological manifestations. *Jpn J Med* 1988;**27**:167-71.
- Kanda T, Iwasaki T, Yamawaki M, *et al*. Anti-GM1 antibody facilitates leakage in an in vitro blood-nerve barrier model. *Neurology* 2000;**55**:585-7.
- Mendell JR, Kalkin S, Kissel JT, *et al*. Evidence for central nervous system demyelination in chronic inflammatory demyelinating polyradiculoneuropathy. *Neurology* 1987;**37**:1291-4.
- Sawada K, Sakurami T, Imura H, *et al*. Anti-asialo-GM1 antibody in sera from patients with Graves' disease and Hashimoto's thyroiditis. *Lancet* 1980;**ii**:198.
- Seo SW, Lee BI, Lee JD, *et al*. Thyrotoxic autoimmune encephalopathy: a repeat positron emission tomography study. *J Neurol Neurosurg Psychiatry* 2003;**74**:504-6.

## Acute combined central and peripheral inflammatory demyelination

Generally, inflammatory demyelinating diseases selectively affect either the central or peripheral myelin. Here we report a case of a severe combined central and peripheral demyelination, each of which contributed equally to the clinical syndrome.

## Case report

A 32 year old female was admitted to a general district hospital with a 3 day history of aches in the legs, fever (38 °C), urinary retention and leg weakness. Neurological examination revealed a flaccid tetraparesis with abolished abdominal and ankle reflexes, diminished knee reflexes, bilateral extensor plantar responses, and sensory level at T12. The patient was given high dose intravenous prednisone (1 g) for 5 consecutive days. She became bedridden with complete paraplegia of the legs and was referred to our department. Upon admission, in addition to a flaccid tetraparesis (strength 1/5 in the legs and 4/5 to 4 ± 5 in the arms, MRC grade) with abolished abdominal, knee and ankle reflexes, extensor plantar responses, and sensory level at T5, a bilateral gaze evoked nystagmus was detected. Urodynamic examination revealed an atonic bladder. Lumbar puncture revealed a pleocytosis (34/mm<sup>3</sup>; 84% lymphocytes) and a cerebrospinal fluid (CSF) protein of 132 mg/dl. Neither intrathecal immunoglobulin synthesis nor oligoclonal bands were detected. Complete microbiological and virological investigations on CSF and blood specimens were negative. Further negative findings included serum angiotensin converting enzyme, anti-nuclear antibodies, anti-neutrophil cytoplasmic antibodies, and

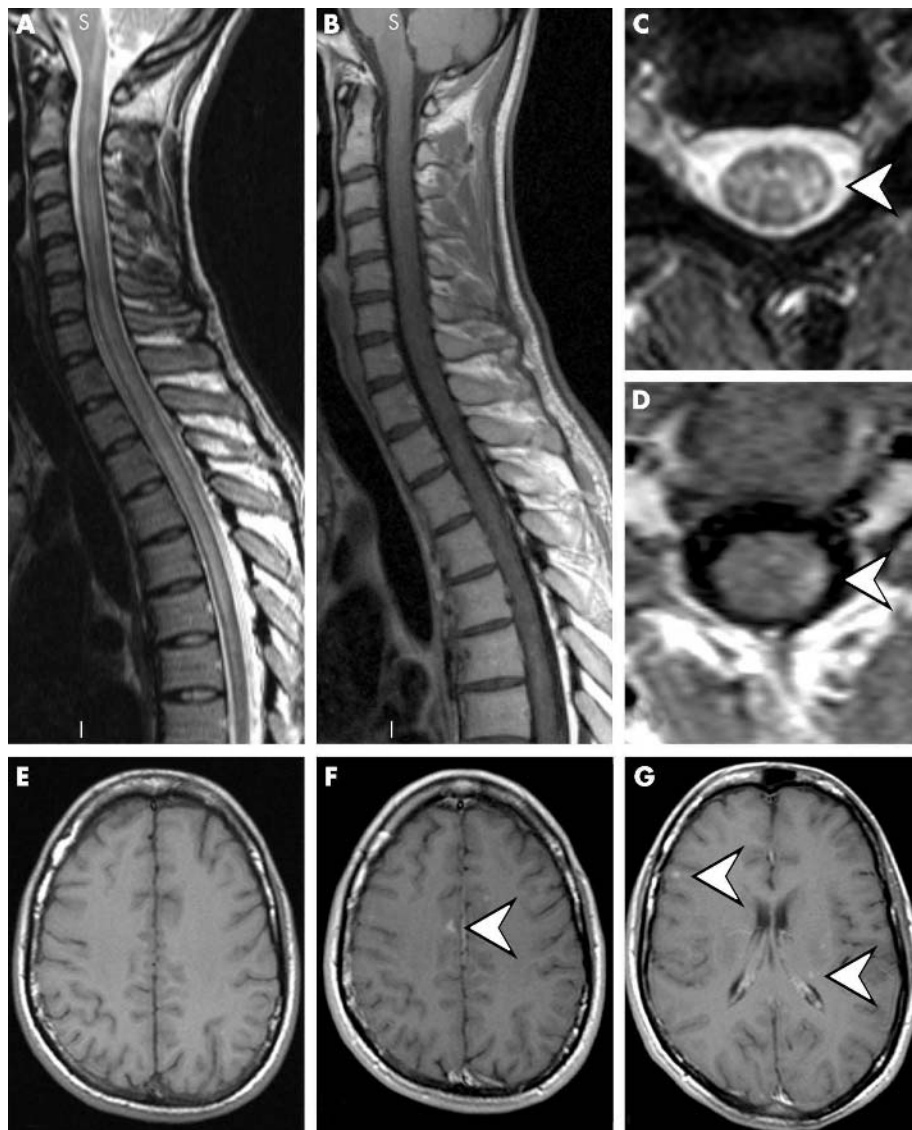
onconeuronal antibodies. Serological testing for anti-ganglioside antibodies (Ganglio-combi test; Bühlmann Laboratories) showed elevated titres for asialo-GM1 (4283 Bühlmann titre units (BTU); normal<1700), GM1 (2855 BTU; normal<1700) and GQ1b (4117 BTU; normal<1700). Magnetic resonance imaging (MRI) of the spinal cord depicted an extensive cervicothoracic myelopathy (fig 1A–D). On MR images of the brain, multiple dot-like cortical and subcortical lesions were delineated, predominantly located in the frontoparietal gray and white matter (fig 1E–G). Electrodiagnostic studies indicated a severe symmetrical demyelinating neuropathy with reduced motor conduction velocities (right peroneal nerve 12.8 m/s, right tibial nerve 16.0 m/s, and right median 44 m/s), prolonged distal latencies (right peroneal nerve 17.1 ms, right tibial nerve 14.5 ms, and right median 5.3 ms), and prolonged or absent F waves, with MUAP displaying temporal dispersion and diminished amplitudes, and with electromyographic signs of acute denervation. The sensory action potentials and conduction velocities were normal.

A whole body computed tomography scan, a salivary gland scintigraphy scan, and a lip biopsy were completely unremarkable. A diagnosis of a combination of acute disseminated encephalomyelopathy (ADEM) and demyelinating polyradiculoneuritis was made. The patient was given 30 g of intravenous immunoglobulin for 5 consecutive days (total 150 g). By day 10 after the start of the immunoglobulin treatment, the patient could stand upright for several seconds with support. As there was no further improvement during the following 2 weeks, the therapy was increased and the patient was treated with a total of six plasma exchanges on alternate days. Five days after the final plasma exchange, the patient could make her first steps with a walker. Six weeks after the final plasma exchange, MRI of the brain and spinal cord showed dramatic regression of the T2 hyperintensities. On follow-up 1 month later, the patient could walk 250 metres with a walker. On examination, no gaze evoked nystagmus was detected. Arm strength was normal. Internal rotation of the hips, hip and knee flexors, and knee extensors were 4/5 on the right and 5/5 on the left; ankle flexors and

extensors and toe dorsiflexors were 4/5 bilaterally. The knee reflexes were sluggish and the ankle reflexes absent. Six months later the patient was able to walk 1000 metres without walking aids. The neurological examination revealed brisk knee and ankle reflexes. The 1 year follow-up showed a patient with normal leg strength and mild ataxia on heel to toe gait. The electrophysiological studies showed improvement of motor conduction velocities (right peroneal nerve 24.1 m/s, right tibial nerve 33.1 m/s, and right median 46.6 m/s) and distal latencies (right peroneal nerve 10.4 ms, right tibial nerve 9.5 ms, and right median 3.4 ms).

**Discussion**

Our patient presented an acute demyelinating disorder affecting the central and peripheral nervous system simultaneously. After exclusion of other causes, the central nervous system involvement resembled the clinical and radiological characteristics of ADEM with long segmental spinal cord lesion. The peripheral nervous system involvement displayed the clinical, electrodiagnostic, CSF,



**Figure 1** T2 (A, C) and T1 (B, D) weighted, contrast enhanced MR studies of the cervicothoracic spine. Confluent hyperintensities covering all imaged spinal segments are depicted (A), some of which show patchy enhancement (arrows) subsequent to gadolinium administration, predominantly affecting the spinal column dorsolaterally. T1 weighted MR images pre (E) and post (F, G) contrast. Small dot-like cortical and subcortical lesions are seen, showing contrast enhancement (arrows).



and serological features of a demyelinating polyradiculoneuropathy.

Documented overlap of acquired acute central and peripheral system demyelination is very rare. Gamstrop and Blennow used the descriptive diagnosis of encephalomyelorradiculoneuropathy to designate paediatric cases of Guillain-Barré syndrome with presumed CNS involvement.<sup>1</sup> Again in children, Amit *et al.* coined the entity of acute severe combined demyelination for cases in which central and peripheral nervous system pathology equally contributed to the overall clinical picture.<sup>2</sup> An acute or subacute combined central and peripheral myelinopathy has been very rarely reported in adults,<sup>3,4</sup> with no successful treatment regimens being documented.

In our patient, no improvement was seen after high dose intravenous prednisone therapy (5 g), but she dramatically improved on intravenous immunoglobulin and plasma exchange therapy. This finding extends the previous reports of the effectiveness of this therapeutic strategy in the patients with central or peripheral inflammatory demyelination who failed to respond to high dose steroid therapy. Even a delayed treatment (7 weeks after onset of the symptoms) with immunoglobulin induced a significant remission. Further clinical improvement was achieved with subsequent plasma exchange. Our finding supports the concept of immunomodulation using immunoglobulin and plasma exchange in steroid resistant combined central and peripheral inflammatory myelinopathy.

Acute demyelinating diseases are often preceded by an infection or vaccination and considered to be immune mediated. This case of a severe unrestricted demyelinating syndrome encourages the concept that an immunological attack can be directed against central and peripheral myelin in susceptible individuals.

**J Katchanov, J D Lünemann, F Masuhr, D Becker, M Ahmadi, J Bösel, R Zschenderlein**

Departments of Neurology, University Hospital Charité, Humboldt-University, Schumannstr. 20/21, 10117 Berlin, Germany

**S Bamborschke**

Department of Neurology, Brandenburg-Klinik, Brandenburgallee 1, 16321 Bernau-Waldsiedlung, Germany

**R Klingebiel**

Department of Radiology, Neuroradiology Section, University Hospital Charité, Humboldt-University, Schumannstr. 20/21, 10117 Berlin, Germany

Correspondence to: Dr J Katchanov, Klinik fuer Neurologie, Campus Charité Mitte, Schumannstr. 20/21, D-10117 Berlin; juri.katchanov@charite.de

doi: 10.1136/jnnp.2004.037572

Competing interests: none declared

## References

- Blennow G, Gamstorp I, Rosenberg R. Encephalo-myelo-radiculo-neuropathy. *Dev Med Child Neurol* 1968;**10**:485–90.
- Amit R, Glick B, Itzchak Y, *et al.* Acute severe combined demyelination. *Childs Nerv Syst* 1992;**8**:354–6.
- Nadkarni N, Lisak RP. Guillain-Barré syndrome (GBS) with bilateral optic neuritis and central white matter disease. *Neurology* 1993;**43**:842–3.
- Kinoshita A, Hayashi M, Miyamoto K, *et al.* Inflammatory demyelinating polyradiculitis in a patient with acute disseminated encephalomyelitis (ADEM). *J Neurol Neurosurg Psychiatry* 1996;**60**:87–90.

## Miller Fisher syndrome associated with *Pasteurella multocida* infection

Miller Fisher syndrome is characterised by ataxia, areflexia, and ophthalmoplegia and was first described by Charles Miller Fisher in 1956 as an unusual variant of acute idiopathic polyneuritis. There is frequently an antecedent illness<sup>1</sup> and the syndrome is associated with a high titre of anti-GQ1b antibodies in approximately 90% of cases.<sup>1,2</sup> *Pasteurella multocida* is a Gram negative bacteria, commonly found in the saliva of animals, particularly cats.<sup>3</sup>

We present the case of a 70 year old lady who developed Miller Fisher syndrome with positive anti-GQ1b antibodies 11 days after *P. multocida* was cultured from a blood sample. Miller Fisher syndrome associated with *P. multocida* infection has not, to our knowledge, been described previously.

## Case report

A 70 year old lady presented with a one day history of a painful left hip, fever, sweats, and lethargy following a bite from her pet cat on her left leg on the preceding day. She reported no other recent illnesses. She had had a total left hip replacement four years previously. On examination she was hypotensive and pyrexial with local tenderness of her left hip and decreased range of movement. She had puncture marks on her left shin from the cat bite with surrounding erythema tracking proximally to the groin. Initial blood cultures revealed heavy growth of *P. multocida* sensitive to penicillin. Intravenous benzylpenicillin (1.2 g four times daily) was administered.

The patient's pyrexial illness improved over the next 11 days but then she developed diplopia. The attending orthopaedic surgeon recorded that the cranial nerve examination was normal. By the following day the patient had also become ataxic, and she was referred for a neurological opinion. Examination at this stage revealed marked truncal ataxia and complete internal and external ophthalmoplegia with bilateral ptosis. Limb examination revealed areflexia and ataxia although limb power and sensation were normal. The patient was unable to stand.

A computed tomography brain scan was normal. Magnetic resonance imaging was precluded by claustrophobia. The cerebrospinal fluid was clear, containing 0.5 g/l protein, 3.3 mmol/l glucose, no white cells/mm<sup>3</sup>, and 255 red cells/mm<sup>3</sup>. No organisms were seen or cultured. There was no clinical response to pyridostigmine and acetylcholine receptor antibodies were negative. A sample of blood taken seven days after the onset of neurological symptoms was positive for anti-GQ1b antibodies at a titre of 1:1600 using enzyme-linked immunosorbent assay (ELISA). The testing laboratory considered a titre above 1:100 to be positive for anti-GQ1b antibodies. Other antiganglioside antibodies and follow up anti-GQ1b antibodies were not tested.

A diagnosis of Miller Fisher syndrome was made and intravenous immunoglobulin

(0.4 g/kg daily for five days) was administered with gradual improvement in symptoms and signs over the next six weeks leading to the patient's discharge. At follow up five months later she had fully recovered.

## Discussion

This patient developed the typical neurological symptoms of Miller Fisher syndrome with positive anti-GQ1b antibodies 11 days after *P. multocida* was cultured from a blood sample. To our knowledge this is the first reported case of any form of Guillain-Barré syndrome associated with *P. multocida* infection.

*P. multocida* is a small Gram negative coccobacillus<sup>4</sup> and is an important animal and human opportunistic pathogen. In humans it can cause soft tissue, respiratory, urinary tract, and meningeal infections. The mechanisms by which *P. multocida* might cause Miller Fisher syndrome (we are assuming causation and accept we have only demonstrated temporal association) are unknown but molecular mimicry is a possibility. There is considerable evidence supporting the theory of molecular mimicry between lipopolysaccharide (LPS) from *Campylobacter jejuni* and the GQ1b ganglioside.<sup>5</sup> As *P. multocida* is Gram negative, its capsule similarly has LPS. However, we were unable to find any research specifically suggesting a similarity between the *P. multocida* LPS and the GQ1b ganglioside. *P. multocida* has previously been reported in association with acute disseminated encephalomyelitis<sup>4</sup> but not, to our knowledge, with any other diseases with a presumed autoimmune basis.

Although an antecedent illness has frequently been noted before the onset of Miller Fisher syndrome the causative agents are not as well described as in Guillain-Barré syndrome.<sup>5</sup> While *C. jejuni* has been implicated in the pathogenesis of Miller Fisher syndrome following enteritis, a recent study<sup>1</sup> of 50 patients with the syndrome found that 76% had respiratory symptoms in the month preceding onset of the syndrome compared with only 4% with gastrointestinal symptoms. *Haemophilus influenzae*, *Staphylococcus aureus*, *Mycoplasma pneumoniae*, *Coxiella burnetii*, cytomegalovirus, Epstein-Barr virus, varicella zoster, and mumps virus have also been reported as antecedent agents in Miller Fisher syndrome. However, a statistical correlation with Miller Fisher syndrome has only been shown for *M. pneumoniae*<sup>5</sup>—serological evidence of recent infection was found in 7% of Miller Fisher patients compared with 2% of patients with Guillain-Barré syndrome.

From the above discussion it is clear that the antecedent illness in Miller Fisher syndrome commonly takes the form of a respiratory infection of unknown aetiology. *P. multocida* can cause respiratory infection. It is often difficult to isolate this organism from sputum samples<sup>3</sup> and it has been reported as causing indolent and asymptomatic pulmonary infection,<sup>3</sup> including asymptomatic lung abscess. For these reasons *P. multocida* infection is possibly underdiagnosed. Therefore, while we believe this is the first reported case of an association between Miller Fisher syndrome and *P. multocida* we believe it highly unlikely to be unique.

**L P Bennetto**

Institute of Clinical Neurosciences, University of Bristol, Glial Cell Research Laboratory, Frenchay Hospital, Bristol, UK