

## SHORT REPORT

## Autopsy proven sporadic frontotemporal dementia due to microvacuolar-type histology, with onset at 21 years of age

J S Snowden, D Neary, D M A Mann

*J Neurol Neurosurg Psychiatry* 2004;75:1337–1339. doi: 10.1136/jnnp.2003.028498

We describe the clinical, neuropsychological, and neuropathological features of a 21 year old woman with frontotemporal dementia (FTD). The early presentation was of florid behavioural change involving hyperactivity and disinhibition. Magnetic resonance imaging and single photon emission computed tomography of the brain revealed atrophy and severe functional abnormalities of the frontal and temporal lobes, respectively. Electroencephalogram was normal. At autopsy, there was gross frontotemporal brain atrophy and the underlying histology was of a microvacuolar-type degeneration; no tau or ubiquitin immunoreactive, intraneuronal inclusions were seen. There was no family history of dementia and no mutation in the *tau* gene. We believe this patient represents the youngest (so far) recorded case of FTD associated with this particular histological form of the disorder.

Frontotemporal lobar degeneration (FTLD) is the second commonest cause of degenerative dementia with onset before 65 years.<sup>1</sup> Most FTLD patients suffer clinically from frontotemporal dementia (FTD). Onset is typically between 40 and 60 years, although it has been observed in younger people—two brothers with familial FTD with onset at 21 and 25 years have been reported.<sup>2,3</sup> Sporadic FTD has been described in a 27 year old woman,<sup>4</sup> a 27 year old man<sup>5</sup> and a 25 year old woman.<sup>6</sup> Interestingly, autopsy, when possible, has shown a histological picture of tau immunoreactive swollen cells (Pick cells) and intraneuronal inclusions (Pick bodies) within the cerebral cortex and hippocampus. We report the case of a woman with sporadic FTD with onset at 21 years, although in this instance, the underlying histology was that of tau negative, ubiquitin negative microvacuolar-type histology (also known as dementia lacking distinctive histology, DLDH). We believe this woman to be the youngest patient to be affected by this histological form of the disorder.

## CASE REPORT

At 21 years of age our patient became restless, lacking in concentration, and inefficient, which resulted in dismissal from work. She displayed stereotyped behaviours, such as repeated hand rubbing and became obsessed with time. She neglected self-care and became gluttonous. She showed no emotional feelings towards others and avoided social contact. Her restlessness led to an increasingly itinerant existence, and she was found living alone in a state of gross neglect.

Solvent abuse was initially suspected but could not be substantiated. A psychiatric referral led to a diagnosis of psychosis. However, she was unresponsive to neuroleptic medication and electroconvulsive therapy. On neurological examination four years after the onset of symptoms she was profoundly restless, overactive, disinhibited and distractible.

She would pick up objects within reach and showed frank utilisation behaviour, turning light switches and taps on and off repeatedly and opening and closing blinds. She would place inedible substances in her mouth. When seated she rocked backwards and forwards in a stereotyped manner and engaged in bouts of screaming. Her affect was bland, fatuous and unconcerned.

There was no history of change in language, perceptuo-spatial skills, or memory, and she had no neurological symptoms. Her previous medical history was unremarkable. There was no family history of psychiatric disease or dementia. Both her parents are alive and well.

Neurological and neuropsychological examinations were severely compromised by her restless, rapid pacing, and inattention, however, she appeared physically well. Her responses were rapid, impulsive, and economical, and her speech was dominated by repetitive, stereotyped utterances. However, articulation was normal and she made no grammatical or paraphasic errors. She showed good understanding at a single word and simple sentence levels. However, she made no attempt to respond to complex commands. She named a series of line drawings rapidly without naming errors. She read aloud effortlessly and wrote with an untidy script with perseveration of strokes. She identified objects, line drawings, and famous faces suggesting an absent perceptual disorder. Moreover, spatial skills appeared preserved. She localised objects and towns on a map of Great Britain. Her copies of line drawings showed preserved spatial relationships and she reproduced block designs accurately. There was no apraxia. She reproduced gestures and action pantomimes accurately. She was oriented in time and place and could describe recent personal events. Performance on executive tasks was profoundly impaired. She did not complete any groupings on Weigl's blocks test and made no attempt to carry out a picture sequencing task. The profound attentional and executive disturbances in the absence of primary deficits in language, perception, spatial function, and praxis indicated circumscribed impairment of function in the anterior hemispheres.

These findings were complemented by magnetic resonance imaging (MRI) that revealed atrophy of the frontal and temporal lobes, and single photon emission computed tomography (SPECT) that showed severe functional abnormalities in the frontotemporal lobes. An electroencephalogram was normal.

The clinical picture fulfilled the criteria<sup>7</sup> for FTD, which despite the patient's young age appeared to be sporadic.

Over the next two years her restlessness and purposeless overactivity increased but thereafter gave way to apathy and inertia. She showed more frequent utilisation behaviour and her hyperoral tendencies increased so that she crammed objects indiscriminately into her mouth. However, with the

**Abbreviations:** DLDH, dementia lacking distinctive histology; FTD, frontotemporal dementia; FTLD, frontotemporal lobar degeneration

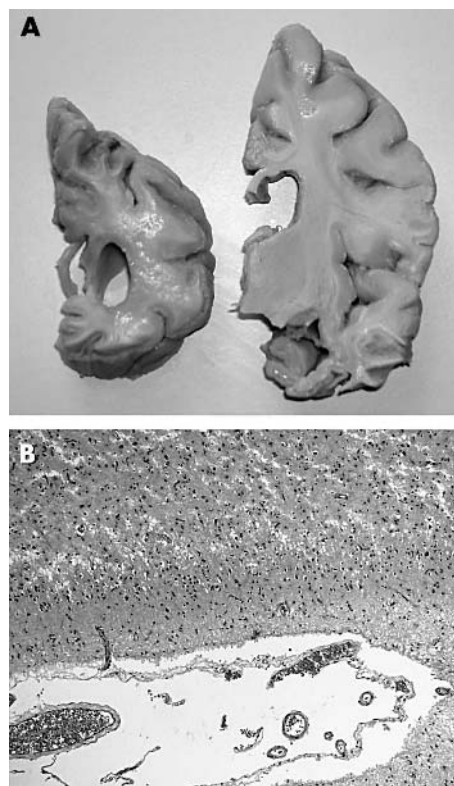
increasing apathy she began to ignore objects. There was a gradual diminution in her propositional speech, which was substituted by echolalia, grunting, and ultimately, seven years after onset of symptoms, mutism. Formal neuropsychological examination was impossible. However, she negotiated the environment with ease and found her way around the nursing home where she was resident, suggesting preserved spatial skills. Her family and care staff felt that she recognised them. She remained physically well, with neurological signs confined to strong bilateral grasp reflexes. However, latterly limb rigidity began to emerge.

During the final three years of her life she was doubly incontinent, inert and avolitional. She died of bronchopneumonia at the age of 30, nine years after the onset of symptoms.

At post mortem, the brain weighed 878 g. There was gross bilateral atrophy of the frontal and temporal lobes, particularly inferior and middle temporal gyri (fig 1A), and anterior parietal lobe although the premotor, motor, and somatosensory cortices and the occipitoparietal lobe were only moderately atrophic. The cerebellum and brain stem appeared small. The major cerebral arteries were normal. On section, the lateral ventricle was grossly enlarged, as was the temporal horn extension (fig 1A). The frontal, anterior parietal, and anterior temporal lobes showed much loss of both grey and white matter (fig 1A), the latter being softened with a brownish discoloration. The orbitofrontal cortex was more severely affected than the convex cortex. The middle and inferior temporal gyri were affected throughout the anterior-posterior extent, whereas the superior temporal gyrus was relatively preserved. The posterior parietal and the occipital cortices were moderately atrophied, and the distinction between grey and white matter was well maintained. The hippocampus, amygdala, putamen, and caudate nucleus were all grossly atrophic, the latter being reduced to a thin ribbon of concave tissue (fig 1A). The globus pallidus and thalamus were moderately shrunken. The substantia nigra and locus caeruleus displayed no pigmentation.

Histologically, the frontal, temporal, anterior parietal, cingulate, and insular cortices all showed extensive microvacuolation of the outer cortical layers with subtotal loss of nerve cells, leading to complete loss of normal cytoarchitecture and collapse of the cortical ribbon (fig 1B). There was extensive transcortical astrocytosis with widespread loss of myelin and axons from the deep white matter. The superior temporal gyrus, posterior parietal cortex, and occipital cortex were relatively preserved showing mild astrocytosis, subpial and at the junction of the grey and white matter; microvacuolation was not present in these regions. There was complete loss of nerve cells from areas CA1 and subiculum of the hippocampus, with extensive astrocytosis, although other hippocampal regions, including the dentate gyrus granule cells, appeared normal. The caudate nucleus and putamen showed virtually complete loss of nerve cells with severe astrocytosis. There was moderate diffuse astrocytosis throughout the globus pallidus and thalamus. There was almost total loss of nerve cells from the substantia nigra with astrocytosis, although no Lewy bodies or pale bodies were present.

Immunohistochemistry using a battery of anti-tau antibodies (AT8, AT180, AT270 (Innogenetics, Antwerp, Belgium), PHF-1, CP13 (gifts from Dr P Davies), 12E8T (gift from Dr P Seubert)) revealed no tau positive nerve cells or tau positive inclusions (Pick bodies, neurofibrillary tangles) in any part of the brain. Similarly, anti-amyloid  $\beta$  protein immunostaining showed no amyloid plaques to be present. Immunostaining with antibodies against ubiquitin, neurofilament, and  $\alpha$ -synuclein proteins was likewise uninformative.



**Figure 1** (A) Coronal section of the brain showing extensive atrophy of the frontal and anterior temporal cortices, and the caudate nucleus, with ventricular dilatation. (B) The underlying histological change within the frontal and temporal cortex is that of microvacuolar degeneration (also known as dementia lacking distinctive histology) with widespread reactive astrocytosis. No tau or ubiquitin immunoreactive intraneuronal inclusions were present in any part of the brain.

## DISCUSSION

The clinical, neuropsychological, and radiological features in this patient were consistent with published diagnostic criteria for FTD.<sup>7</sup> However, the patient's youth and the striking behavioural change, in the setting of preserved memory, and spatial and linguistic skills, led to the initial misdiagnosis of solvent abuse and atypical psychosis. The underlying histology was that of microvacuolar-type degeneration.<sup>1</sup> No tau positive, Pick body-type inclusions, or Alzheimer-type neurofibrillary tangles were seen. Ubiquitin inclusions of the type associated with FTD with motor neurone disease (motor neurone disease inclusion dementia) were absent, as were amyloid plaques and Lewy bodies. We believe this patient represents the youngest recorded case of FTD with microvacuolar-type histology. This particular histological profile has repeatedly failed to demonstrate tau positive inclusions by immunohistochemistry (see reference 8) and has been termed "non-tau" FTLD. The cause of the neurodegeneration in such "non-tau" cases remains elusive, although it has been suggested<sup>9,10</sup> that these might represent a disorder of soluble tau. The present case formed part of a study (case no 29 of reference 8) investigating soluble tau levels in FTLD in relationship to other indices of neuronal function. Soluble tau levels in frontal cortex were reduced to less than 10% of normal,<sup>8</sup> not unexpected given the prolonged duration of disease and severe degeneration of the frontal lobes. However, there were similar losses of a neuronal nuclear marker protein (NeuN), tubulin, and MAP5 proteins with relative preservation of  $\alpha$ -synuclein.<sup>8</sup> Loss of tau in this

patient, as in other non-tau FTLD cases, may therefore be part of a wider process of neurodegeneration that sweeps away many other neuronal proteins from nerve cells whose perikarya and processes are principally within affected cortical regions while relatively sparing other proteins (for example  $\alpha$ -synuclein) that are present within projecting axons emanating largely from preserved cortical regions.

Despite the absence of family history, we sequenced the open reading frame of *tau* but no mutation was present.<sup>11</sup> Non-paternity was likewise excluded. Nonetheless, it remains possible that the underlying cause is genetic. There may be variable penetrance of an autosomal dominant mutation within other regions of the *tau*, or within a gene other than *tau*. Alternatively, a recessive mode of gene transmission may have been operating.

#### ACKNOWLEDGEMENTS

We wish to thank Ms Andrea McDonagh for technical assistance. Dr Stuart Pickering-Brown performed the *tau* gene sequencing, and Dr Sayuri Taniguchi the tau biochemistry for this case, the results of which have been published elsewhere but are referred to in the present paper.

#### Authors' affiliations

**J S Snowden, D Neary, D M A Mann**, Neuroscience Research Group, University of Manchester, Greater Manchester Neurosciences Centre, Hope Hospital, Salford, UK

Competing interests: none declared

Correspondence to: David M A Mann, Clinical Neuroscience Research Group, Greater Manchester Neurosciences Centre, Hope Hospital, Stott Lane, Salford, M6 8HD, UK; david.mann@man.ac.uk

Received 17 September 2003

In revised form 15 December 2003

Accepted 21 December 2003

#### REFERENCES

- 1 **Snowden JS**, Neary D, Mann DMA. *Fronto Temporal Lobar Degeneration*. Edinburgh: Churchill Livingstone, 1996.
- 2 **Lawenberg K**, Boyd DA, Salon DD. Occurrence of Pick's disease in early adult years. *Arch Neurol Psychiatr* 1939;**41**:1004–20.
- 3 **Malamud N**, Waggoner RW. Genealogic and clinicopathologic study of Pick's disease. *Arch Neurol Psychiatr* 1943;**50**:288–303.
- 4 **Jacob J**, Revesz T, Thom M, et al. A case of sporadic Pick disease with onset at 27 years. *Arch Neurol* 1999;**56**:1289–91.
- 5 **Stewart JT**, Ware MR, Bauer RM, et al. A case of early-onset Pick's disease. *J Clin Psychiatry* 1992;**53**:380.
- 6 **Coleman LW**, Digre KB, Stephenson GM, et al. Autopsy proven, sporadic Pick disease with onset at age 25 years. *Arch Neurol* 2002;**59**:856–9.
- 7 **Neary D**, Snowden JS, Gustafson L, et al. Frontotemporal lobar degeneration: a consensus on clinical diagnostic criteria. *Neurology* 1998;**51**:1546–54.
- 8 **Taniguchi S**, McDonagh AM, Pickering-Brown SM, et al. The neuropathology of frontotemporal lobar degeneration with respect to the cytological and biochemical characteristics of tau protein. *Neuropathol Appl Neurobiol* 2004;**30**:1–8.
- 9 **Zhukareva V**, Vogelsberg-Ragaglia V, Van Deerlin VMD, et al. Loss of brain tau defines novel sporadic and familial tauopathies with frontotemporal dementia. *Ann Neurol* 2001;**49**:165–75.
- 10 **Zhukareva V**, Sundarraj S, Mann D, et al. Selective reduction of soluble tau proteins in sporadic and familial frontotemporal dementias: an international follow-up study. *Acta Neuropathol* 2003;**105**:469–76.
- 11 **Hutton M**, Lendon CL, Rizzu P, et al. Coding and 5' splice mutations in tau associated with inherited dementia (FTDP-17). *Nature* 1998;**393**:702–5.