

## SHORT REPORT

# Long duration asymmetrical postural tremor is likely to predict development of Parkinson's disease and not essential tremor: clinical follow up study of 13 cases

K Ray Chaudhuri, M Buxton-Thomas, V Dhawan, R Peng, C Meilak, D J Brooks

See Editorial Commentary, p 9

*J Neurol Neurosurg Psychiatry* 2005;76:115–117. doi: 10.1136/jnnp.2004.046292

**Background:** Patients presenting with asymmetrical postural tremor with or without mild rest tremor may be diagnosed as having essential tremor (ET), although there is considerable diagnostic uncertainty as to the long term outcome of these patients.

**Objective:** In this study, retrospective observations were made on 13 patients presenting originally with asymmetrical postural tremor, initially thought to have ET based on tremor characteristics, alcohol responsiveness, and family history but who subsequently met the criteria of Parkinson's disease (PD).

**Methods:** The patients were observed and followed up clinically with ancillary imaging using dopamine transporter SPECT scan or levodopa challenge tests in some cases. The diagnosis at original presentation with postural tremor was made with retrospective case note review.

**Results:** After a variable and long latent period all patients developed additional signs suggesting a clinical diagnosis of PD although picking up an initial label of ET.

**Conclusions:** We suggest exercising caution regarding a diagnosis of ET in patients presenting with late onset asymmetrical postural tremor even if there is no rest tremor. Alcohol sensitivity of tremor, family history of tremor, or responsiveness to  $\beta$  blockers may not be helpful in diagnosing ET in these cases and some may develop PD in the long term.

Currently, confusion still exists with regard to the diagnosis in patients presenting with later onset unilateral or asymmetrical dominantly postural tremor, and these cases are often labelled as atypical essential tremor (ET). It is known that ET is a heterogeneous disorder, and some workers have suggested that in some cases Parkinson's disease (PD) overlaps with the presentation of essential tremor—so called "ETPD" cases.<sup>1 2</sup>

In PD, a 4–8 Hz action tremor is as prevalent as the classic 3–5 Hz rest tremor and the two generally coexist. The postural tremor of PD may be alcohol or  $\beta$  blocker responsive, and relatives of probands with tremor dominant PD may manifest ET.<sup>3–6</sup> Diagnosis of asymmetrical predominantly postural tremor, with or without rest tremor therefore, remains confusing.<sup>7 8</sup> Here, we report a clinical follow up study of 13 patients with a history of postural tremor with asymmetry present for at least 10 years, initially labelled as ET, who developed an additional rest tremor in the same arm during follow up resulting in a final diagnosis of tremor dominant PD. To our knowledge this is the first longitudinal clinical study of such a cohort.

## METHODS

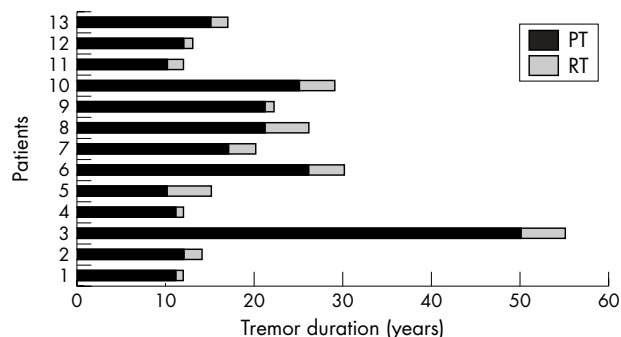
From a clinical database of patients with tremor attending our regional movement disorders clinic, we identified 13 patients with a history of postural tremor with asymmetry >10 years and no rest tremor who had an initial diagnosis of probable ET but a final diagnosis of tremor dominant or mixed pattern PD satisfying the UK PD brain bank criteria.<sup>9</sup> The database is continually updated and currently holds records of 480 patients with a diagnosis of PD. Patients with a history of neuroleptic or vestibular sedative use were excluded.

All 13 patients were examined by KRC and A Forbes (PD nurse specialist) and followed up in PD clinics. As our movement disorders clinic also offers surgical therapy with deep brain stimulation and has an active interest in the treatment of disorders with tremor, most patients with ET are not discharged but followed up at intervals of 6–12 months. Assessments at the time of original referral were ascertained retrospectively by examining case records and patient/caregiver interviews. Five of the 13 patients had striatal dopamine transporter (DAT) binding measured using  $\beta$ -CIT single photon emission computed tomography (SPECT), and all had trials of levodopa/dopamine agonists. Five patients underwent a levodopa challenge test using a standard protocol.<sup>10</sup>

## RESULTS

A total of 13 patients (10 men, three women; mean age at diagnosis of PD 69.8 years, range 51–87) presenting with asymmetrical postural tremor and subsequent development of rest tremor and parkinsonism with a tremor duration of 19.2 years (range 10–50) were included in the study. The duration of tremor could have been skewed by the tremor duration of 50 years in one patient. When this patient was excluded, the mean duration of tremor to final diagnosis was 15.9 years (range 10–26). Mean age at the time of original presentation with asymmetrical postural tremor was 50.6 years (range 36–69). Historical interviews suggested that the tremor pattern had changed from an asymmetrical postural tremor to express additional rest tremor and other signs of parkinsonism for a mean period of 2.5 years (range 1–5) before final presentation to our clinic (fig 1). All patients now had an 8–10 Hz postural tremor and a slower 3–5 Hz rest tremor in addition to bradykinesia and cogwheeling. The patients responded to dopaminergic treatment with levodopa and/or levodopa and dopamine agonist (n = 7), dopamine agonists (n = 5) and benzhexol (n = 1). Patients 9 and 13 were given a trial of dopamine agonists in spite of strongly positive levodopa challenge (table 1) because of their

**Abbreviations:**  $\beta$ -CIT SPECT, 2- $\beta$ -carbomethoxy-3- $\beta$ -(4-[<sup>123</sup>I]iodophenyl)tropane single photon emission computed tomography; ET, essential tremor; PD, Parkinson's disease



**Figure 1** Duration of postural tremor (PT) and subsequent development of rest tremor (RT) in the 13 patients reported in this paper.

relatively young age; Hoehn and Yahr stage at the time of diagnosis of PD was 2 (range 1.5–3). The levodopa challenge test was positive in all five patients (20–60% improvement).  $\beta$ -CIT SPECT ( $n = 5$ ) revealed reduced uptake of  $\beta$ -CIT in the striatum contralateral to the dominantly affected arm. Cerebral magnetic resonance imaging or computed tomography brain scans were normal in all.

Historically, 6/13 patients were documented to have alcohol induced attenuation of postural tremor while a family history (in first degree relatives) of tremor/parkinsonism was present in 8/13. At initial presentation with postural tremor, all were tried on  $\beta$  blockers (propranolol) with variable response. At follow up and after re-presentation with parkinsonism only one patient continues on propranolol in addition to dopaminergic treatment.

## DISCUSSION

This clinical observational study has highlighted the following facts:

- Late onset isolated unilateral or asymmetrical postural tremor may be a predictor of future expression of tremulous PD.
- There may be a long and variable latent period (up to 50 years in our series) before there is a phenotypic alteration suggesting the development of PD.
- Alcohol sensitivity and family history, thought to be useful as a diagnostic aid to ET, may also be present in patients with PD presenting initially with postural tremor.

These conclusions are supported by the fact that the patients reported in this study presented with an asymmetrical postural tremor without rest tremor and were initially diagnosed as having ET, and all subsequently developed tremulous PD after a variable period averaging 15.9 years after exclusion of one case with a latent period of 50 years. The mean period of change in tremor characteristics and distribution prior to the final diagnosis of PD was 2.5 years and included the development of rest tremor in the arm affected by postural tremor and other signs of parkinsonism. Development of PD was supported by additional  $\beta$ -CIT changes in some patients, positive levodopa challenge test in others, and sustained response to dopaminergic treatment in all.

It may be argued that these patients represent coincidental development of PD in cases of ET, the so called ETPD phenotype as has been suggested by Jankovic,<sup>1</sup> or the condition of ET with isolated rest tremor as suggested by Louis and Jurewicz.<sup>5</sup> However, the latter is unlikely in our patients as all expressed global signs of parkinsonism and not just rest tremor. Furthermore, development of PD with rest tremor occurring in arms affected by postural tremor is also unlikely to be wholly coincidental in 13 cases from a database sample of 480, although there is the inevitable bias in the ascertainment of these cases from a specialist movement disorders clinic database. We also acknowledge the fact that it is not possible to predict from this study what percentage of people with asymmetrical postural tremor will develop PD in the long term as we did not study a similar group of people with asymmetrical postural tremor who did not develop PD.

An overlap of parkinsonism and ET has been suggested previously by many workers and, more recently, electrophysiological means such as H-reflex recovery curves have been put forward as means to distinguish between ET, tremulous PD, and ET with PD although the pathophysiological basis of ET remains unclear.<sup>11–12</sup> Overlap of ET and PD is also supported by the findings that occasionally parkinsonian tremors may respond to  $\beta$  blockers, may be attenuated by alcohol intake (as evident in several of our patients) and a recent description of the PARK4 locus in chromosome 4p in an autosomal dominant family (the Iowa kindred) with parkinsonism and postural tremor suggestive of ET with a good levodopa response.<sup>13–15</sup> Yahr and colleagues recently reported a large kindred with co-occurrence of ET and PD.<sup>16</sup> Three patients developed signs of ET at an early age but signs of PD became evident only in their fifties. The authors proposed a specific genetic mutation/clustering linking ET

**Table 1** Clinical details of the 13 patients included in the study

Patient	Postural tremor	Resting tremor	Final diagnosis	Asymmetry	Family history	Alcohol responsive	L-dopa % +ve	$\beta$ -CIT	Treatment
1	R+L	R+L	TPD	R	Sister TPD	No			L-dopa, DA
2	R+L	R	TPD	R	Son T	No			DA
3	L	L	TPD	L	Mother T	Yes			L-dopa
4	L	L→R	Mixed	L	–	No	20%	Y	L-dopa
5	R	R→L	Mixed	R	–	No	30%		L-dopa
6	L<R	L	Mixed	L	Mother/Uncle T	Yes			L-dopa
7	L	L→R	Mixed	L	Aunt T	Yes	35%	Y	L-dopa
8	R	R	Mixed	R	–	Yes			DA
9	R	R→L	TPD	R	–	No	50%	Y	DA
10	L	L→R	TPD	L	Mother/GM T	No		Y	DA
11	L	R+L	TPD	R	ET/PD	Yes		Y	Anti-cholinergics
12	R	R	TPD	R	–	No			L-dopa
13	R	R→L	TPD	R	Father T	Yes	60%		DA

→: denotes progression to other side.

$\beta$ -CIT: 2- $\beta$ -carbomethoxy-3- $\beta$ -(4-[<sup>123</sup>I] iodophenyl)tropane SPECT scan performed.

L-dopa %: levodopa challenge test (% positive)

DA, dopamine; GM, grandmother; mixed, tremor+akinetic pattern PD; T, tremor; TPD, tremor dominant PD; Y, impaired CIT uptake.

with PD. In the present study, 61.5% of patients had a family history of tremor/parkinsonism and thus the genetic basis of this problem needs further exploration.

In conclusion, we have presented a clinical case series of 13 patients, all presenting with an asymmetrical postural tremor with or without a family history of tremor/parkinsonism and who after an initial diagnosis of ET and a variable period averaging 19.2 years developed signs of tremulous PD. The final diagnosis of PD was supported by a positive levodopa challenge test/successful dopaminergic treatment in all and supportive  $\beta$ -CIT SPECT in some cases. We suggest that caution regarding a diagnosis of ET should be exercised in patients presenting with late onset asymmetrical postural tremor even if there is no rest tremor. Alcohol sensitivity of tremor, family history of tremor or responsiveness to  $\beta$  blockers may not be helpful in such cases while dopamine transporter or fluordopa imaging with SPECT or positron emission tomography may be useful in predicting which patients will develop PD although prospective studies are required to validate this observation. Our clinical study would suggest such cases develop PD after a variable and often a long latent period. Whether this phenotype represents an overlap of ET and PD or whether isolated postural tremor is a marker for tremulous PD remains unclear.

#### ACKNOWLEDGEMENTS

The authors thank Mrs A Forbes and Dr S Pal for their help with recruiting and examining patients.

#### Authors' affiliations

**K Ray Chaudhuri, V Dhawan, R Peng**, Regional Movement Disorders Unit, King's College Hospital, London, UK

**K Ray Chaudhuri, V Dhawan**, University Hospital Lewisham, Lewisham, UK

**K Ray Chaudhuri, M Buxton-Thomas, C Meilak**, Guy's, King's and St Thomas' School of Biomedical Medicine, King's College, London, UK

**M Buxton-Thomas**, Department of Nuclear Medicine, King's College Hospital, London, UK

**D J Brooks**, MRC Clinical Sciences Centre, Faculty of Medicine, Hammersmith Hospital, London, UK

Competing interests: none declared

Correspondence to: Dr K Ray Chaudhuri, Department of Neurology, King's College Hospital, Denmark Hill, London, SE5 9RS, UK; Ray.chaudhuri@uhl.nhs.uk

Received 24 May 2004

In revised form 30 August 2004

Accepted 1 September 2004

#### REFERENCES

- 1 **Jankovic J**. Essential tremor: a heterogenous disorder. *Mov Disord* 2002;**17**:638–44.
- 2 **Jankovic J**. Essential tremor: clinical characteristics. *Neurology* 2000;**54**(suppl 4):S21–S25.
- 3 **Sethi KD**. Tremor. *Curr Opin Neurol* 2003;**16**:481–5.
- 4 **Louis ED**, Levy G, Majia-Santana H, *et al*. Risk of action tremor in relatives of tremor-dominant and postural instability gait disorder PD. *Neurology* 2003;**61**:931–6.
- 5 **Louis ED**, Jurewicz EC. Olfaction in essential tremor patients with and without isolated rest tremor. *Mov Disord* 2003;**18**:1387–9.
- 6 **Findley LJ**, Gresty MA, Halmagyi GM. Tremor, the cogwheel phenomenon and clonus in PD. *J Neurol Neurosurg Psychiatry* 1981;**44**:534–6.
- 7 **Rajput AH**, Rozdlsky B, Ang L, *et al*. Significance of parkinsonian manifestations in essential tremor. *Can J Neurol Sci* 1993;**20**:114–17.
- 8 **Brooks DJ**, Playford ED, Ibanez V, *et al*. Isolated tremor and disruption of the nigrostriatal dopaminergic system: an  $^{18}\text{F}$ -dopa PET study. *Neurology* 2002;**42**:1554–60.
- 9 **Hughes AJ**, Daniel SE, Kilford L, *et al*. Accuracy of clinical diagnosis of idiopathic Parkinson's disease: a clinico-pathological study of 100 cases. *J Neurol Neurosurg Psychiatry* 1992;**55**:181–4.
- 10 **Albanese A**, Bonuccelli U, Brefel C, *et al*. Consensus statement on the role of acute dopaminergic challenge in Parkinson's disease. *Mov Disord* 2001;**16**:197–201.
- 11 **Sabbahi M**, Etyre B, Al-Jawayed L, *et al*. H-relex recovery curves differentiate essential tremor, Parkinson's disease and the combination of essential tremor Parkinson's disease. *J Clin Neurophysiol* 2002;**19**:245–51.
- 12 **Deuschl G**, Bergman H. Pathophysiology of nonparkinsonian tremors. *Mov Disord* 2002;**17**(suppl 3):S41–S48.
- 13 **Bain PG**, Findley LJ, Thompson PD, *et al*. A study of hereditary essential tremor. *Brain* 1994;**117**(Pt 4):805–24.
- 14 **Koller WC**, Busenbark K, Miner K. The relationship of essential tremor to other movement disorders: report on 678 patients. Essential Tremor Study Group. *Ann Neurol* 1994;**35**:717–23.
- 15 **Farrer M**, Gwinn-Hardy K, Muentner M, *et al*. A chromosome 4p haplotype segregating with Parkinson's disease and postural tremor. *Hum Mol Genet* 1999;**8**:81–5.
- 16 **Yahr MD**, Orosz D, Purohit DP. Co-occurrence of essential tremor and Parkinson's disease: clinical study of a large kindred with autopsy findings. *Parkinsonism Relat Disord* 2003;**9**:225–31.