

# Repeat microvascular decompression for hemifacial spasm

J A Engh, M Horowitz, L Burkhart, Y-F Chang, A Kassam

*J Neurol Neurosurg Psychiatry* 2005;76:1574–1580. doi: 10.1136/jnnp.2004.056861

See end of article for authors' affiliations

Correspondence to:  
Dr Amin Kassam,  
University of Pittsburgh  
Medical Center, Center for  
Cranial Nerve Disorders,  
Suite B-400, 200 Lothrop  
Street, Pittsburgh, PA  
15213, USA; kassamab@  
upmc.edu

Received 23 October 2004  
Revised version received  
22 February 2005  
Accepted 30 March 2005

**Objective:** To report our experience with repeat microvascular decompression (MVD) for hemifacial spasm (HFS) in patients who have failed their first operation.

**Methods:** The authors describe 41 redo MVDs for HFS in 36 patients performed over a 3 year period. Seven patients underwent early re-operation after an aborted seventh nerve decompression. Eight patients underwent early re-operation for clinical failure. Eighteen patients underwent late re-operation for spasm recurrence long after their original MVD. Eight MVDs were performed on patients who had already undergone at least two prior operations.

**Results:** Twenty four patients experienced complete spasm resolution (70.6%), eight patients had near total resolution (23.5%), and two patients failed re-operation (5.9%). Two patients were lost to follow up (5.6%). A favourable outcome was reported by 82.4% of patients at a mean follow up interval of 18 months. A total of 91.7% of patients 50 years of age or younger were cured at follow up versus 59.1% of patients older than 50 ( $p=0.04$ ). Patients undergoing early re-operation were significantly more likely to be cured or improved than patients undergoing late re-operation ( $p=0.03$ ).

**Conclusions:** Repeat MVD for HFS is effective in experienced hands. Younger patients respond better to repeat MVD. Late repeat MVD for HFS is a reasonable treatment option, although results are less favourable than for early re-operation.

Hemifacial spasm (HFS) is an infrequent disorder with an estimated yearly incidence of approximately 1 per 10 000.<sup>1</sup> Although HFS is painless and benign in its course, the social stigma of the disease often causes significant patient distress. No effective medical therapy for HFS exists. Although botulinum toxin type A (Botox, Allergan, Irvine, CA) injections are minimally invasive, the benefits are temporary and the treatment is potentially disfiguring. Four decades ago, Gardner demonstrated that HFS is a surgically treatable condition.<sup>2–3</sup> More than three decades ago, Jannetta began to popularise microvascular decompression (MVD) of the seventh nerve to treat HFS. This procedure has since evolved into the treatment of choice, with operative morbidities of <10% and high rates of success reported in the literature. In experienced hands, spasm resolution rates immediately after MVD are greater than 90%.<sup>4–8</sup> Over a 10 year follow up period, a 91% excellent or partial success rate has been reported.<sup>4</sup> However, patients who fail after MVD present a difficult clinical problem: having undergone a major operation, these patients nevertheless continue to suffer from HFS. A possible alternative for these patients is re-exploration and MVD, but the results of this operation are not well documented. This study represents our clinical experience with this relatively uncommon patient group.

## METHODS

### Study population

Over a 3 year period from January 2000 until December 2002, 39 patients underwent repeat MVD for HFS at the University of Pittsburgh Medical Center (UPMC). Of the 39 patients, 36 underwent procedures performed by the two senior authors (AK, MH); the remaining three patients were excluded from the study. Five of the 36 patients underwent more than one repeat MVD within the interval of the study, for a total of 41 operations. None of the 36 patients had HFS secondary to a mass lesion. No patients with facial myokymia, blepharospasm, or Meige syndrome were included. All patients had typical HFS characterised by symptoms originating from the

orbicularis oculi and differing degrees of spread to the other periorbital and lower facial muscles.<sup>4–9</sup> One patient had bilateral HFS. Sixteen patients had their first operation at UPMC, and 20 patients were referred to UPMC after prior operations elsewhere.

### Operative technique

A previously described approach utilising lateral decubitus positioning, intraoperative microscopy, and Teflon pledgets for nerve decompression was employed.<sup>10</sup> The treatment method of the two senior authors includes monitoring of brainstem auditory evoked responses and motor evoked potentials of the facial nerve by a specialised neurophysiology team. Following careful exposure of the seventh nerve-eighth nerve complex, any offending arteries or veins compressing the facial nerve anywhere from the brainstem to beyond the root exit zone are treated. The operation is complete when the nerve no longer demonstrates any visible evidence of vascular compression. In addition, ephaptic impulse transmission along the facial nerve must be obliterated in order to confirm an adequate decompression. Ephaptic transmission is judged to be eliminated once the "lateral spread" of impulses from one motor branch of the facial nerve to another is gone and cannot be elicited despite intraoperative facial nerve stimulation.<sup>11</sup>

Due to expected scarring of the subarachnoid cisterns among the late re-operation patients, a lumbar drain was placed pre-operatively to facilitate egress of cerebrospinal fluid as needed before and after dural opening. All patients had formal audiograms both pre- and post-operatively, and any patient with hoarseness or dysphagia had an endoscopic swallowing test and vocal cord evaluation prior to hospital discharge.

**Abbreviations:** AICA, anterior inferior cerebellar artery; EMG, electromyography; HBS, House-Brackmann score; HFS, hemifacial spasm; MVD, microvascular decompression; PICA, posterior inferior cerebellar artery; SAT, speech awareness threshold; UPMC, University of Pittsburgh Medical Center

**Table 1** Grading of quality of life measures after repeat MVD for HFS

Grade	Ability to read with affected eye	Lifestyle restrictions	Social comfort
1	No difficulty	No restrictions	No discomfort
2	Mild difficulty	Less restriction than pre-op	Less discomfort than pre-op
3	Same as pre-op	Same as pre-op	Same as pre-op

### Clinical follow up

All intraoperative findings, surgical complications, and patient outcomes were recorded at the time of hospital discharge. Patients were brought back for a post-operative check up within 10 days and were carefully inspected for any evidence of residual spasm. Furthermore, all complications including cerebrospinal fluid leak, wound infection, facial weakness, hearing loss, and vocal cord dysfunction were recorded and treated. All patients were later contacted either by telephone or by electronic mail to complete a questionnaire regarding their clinical status. Neither of the senior operating surgeons was involved in the acquisition of long term follow up data. Data included presence or absence of residual spasm and overall quality of life since the operation. Patients with no residual spasm were deemed "cured". Patients with 25% or less of their pre-operative level of spasm were considered "improved". All patients with greater than 25% of their pre-operative level of spasm or hemifacial paresis of 4 or greater on the House-Brackmann scale<sup>12</sup> were regarded as "failed". Quality of life was determined by patients' ability to read with the affected eye, ability to work or maintain an active lifestyle, and level of comfort in social situations. In order to generate long term outcome measures, each of these variables was stratified according to patients' responses and given one of three grades as explained in table 1. This strategy was used in order to quantify overall patient outcomes, balancing degree of spasm with complication severity.

Using the criteria in table 1, patients were stratified into one of four outcome groups: excellent, good, fair, or poor. The "excellent" group was reserved for those patients who had no restrictions in any of the quality of life categories (that is, grade 1 in all four categories) following MVD. The "good" group consisted of those patients who were partially restricted in only one category (that is, grade 2 in one category, grade 1 in the others). The "fair" group was those patients who had suboptimal scores in multiple categories, but still retained better scores in all three categories. The "poor" group was those patients who were not improved in any or all of the three categories.

### Statistical methods

All clinical data were evaluated for statistical significance. Each of the four patient groups was analysed separately, as well as all 36 patients as a whole. Categorical variables were analysed using  $\chi^2$  testing. Continuous variables were analysed using ANOVA testing. p values of 0.05 or less were considered significant. Patients lost to follow up were excluded from clinical data analysis.

### RESULTS

The 36 patients fell into the following groups. The first group consisted of those patients who had neurophysiological monitoring abnormalities during their first MVD which were significant enough to necessitate abortion of the procedure. These patients underwent a second stage operation within a

**Table 2** Patient stratification according to timing of re-operation

Patient group	Number of patients	Number of procedures
Group 1: early re-operation after first procedure aborted	7	7
Group 2: early re-operation for failure	8	8
Group 3: late re-operation for failure	18	18
Group 4: more than two operations	7 (4 patients also listed in group 3)	8
Total	36	41

Four patients are members of both group 3 and group 4. One patient in group 4 underwent both a third and a fourth MVD during the study period. This resulted in 41 operations for 36 patients.

week of their original MVD. The second group of patients had significant post-operative spasm immediately following their first procedure or a significant recurrence in the immediate post-operative period. These patients underwent re-operation within 1 month of their original decompression. The third group of patients had recurrence of spasm more than 1 month after their original operation. Nearly all of these patients had their original procedure at another institution. The interval to repeat MVD ranged from 4 months to 12 years. The fourth group of patients required a third or fourth MVD during the study period; four of these seven patients were already part of group 3. Grouping of patients is summarised in table 2.

### Early re-operation after aborted MVD (group 1)

Group 1 consisted of seven patients in whom the first MVD had been aborted due to repeated neurophysiological monitoring abnormalities. Such abnormalities included amplitude reduction of brainstem auditory evoked responses by >50% or signal latency of >2 ms on three separate occasions. In the experience of the senior authors, these patients are at high risk of hearing loss if a fourth insult occurs during the same operation. All original operations and re-explorations for this group were performed by the senior authors (AK, MH). The MVD was not complete at the time of the monitoring abnormalities in any of the original operations. However, all patients had undergone some amount of arachnoidal dissection and Teflon felt deposition without a significant decrease in the lateral spread of impulses along the facial nerve. Therefore, these patients were brought back to the operating room within 1 week of the first procedure for a repeat attempt at MVD, that is, a second stage operation. None of the seven patients had a complication of their first procedure which necessitated delay of the second stage operation. Results for these patients are summarised in table 3.

The vascular pathology listed in table 3 refers to blood vessels partially decompressed during the first MVD and completely decompressed during the second stage procedure. All patients demonstrated complete obliteration of the lateral spread phenomenon at the conclusion of the second MVD.

The patients in the first group ranged from 39 to 63 years of age, with a mean age of 48.4 years. Four of the patients were female (57.2%). Five of the seven patients were cured (71.4%), and the other two patients had a near total resolution of spasm. One patient suffered a unilateral vocal cord paralysis. There were no operative deaths. There was no significant correlation between patient age and rate of spasm resolution in group 1 ( $p = 0.69$ ). In addition, there was no significant correlation between patient sex and rate of spasm resolution ( $p = 0.14$ ).

**Table 3** Intraoperative findings and outcomes of MVD for HFS in patients whose first operation was aborted due to neurophysiological monitoring abnormalities

ID	Age	Sex	Vessel(s) treated	Spasm result	Quality of life	Complications
1	63	F	PICA	Cured	Excellent	None
2	50	M	AICA	Improved	Good	None
3	48	F	PICA	Cured	Excellent	None
4	43	M	Two veins	Cured	Excellent	Unilateral vocal cord paralysis
5	51	M	Vertebral artery	Improved	Good	None
6	45	F	AICA, vein	Cured	Excellent	None
7	39	F	PICA	Cured	Excellent	None

All offending vessels are listed in the order in which they were treated. AICA, anterior inferior cerebellar artery; HFS, hemifacial spasm; MVD, microvascular decompression; PICA, posterior inferior cerebellar artery.

### Early re-operation for failure (group 2)

Eight of the patients in this study underwent early re-operation for clinical failure. All eight of these patients had obliteration of the lateral spread of facial nerve impulses confirmed by neurophysiological monitoring during their first MVD. Nonetheless, all of these patients had significant post-operative spasm noted following their original procedure. All patients undergoing re-exploration demonstrated at least 20% of their original level of lateral spread of impulse transmission along the facial nerve on diagnostic electromyography (EMG) prior to repeat MVD. The interval between operations ranged from 4 to 19 days. None of the eight patients had a complication of their first MVD necessitating delay of the second operation. Intraoperative findings and clinical results for these eight patients are listed in table 4.

The age range for group 2 was 27–80 years, with a mean age of 52.9 years. All but one of the patients were female (87.5%). Five of the eight patients (62.5%) demonstrated complete post-operative resolution of their HFS, and the other three patients demonstrated significant improvement. One patient demonstrated mild increased hemifacial paresis (12.5%). Two patients suffered unilateral hearing reduction (25%). Two patients described mild balance difficulties following their operation (25%), but both ambulate without assistance. One patient developed transient diplopia as a result of a sixth nerve paresis. Patient 15 suffered an inadvertent vertebral artery sacrifice during exposure and wound dissection, but developed no subsequent neurological dysfunction. Despite these complications, six of the eight patients (75%) reported either an excellent or a good long term result. There were no operative deaths. In group 2, there was no significant correlation between patient age and cure rate ( $p=0.66$ ), or between patient sex and cure rate ( $p=1.00$ ). There was no significant difference in rate of spasm resolution between group 1 and group 2 ( $p=0.76$ ).

During the first MVD, all patients had either anterior inferior cerebellar artery, posterior inferior cerebellar artery, or the vertebral artery identified as the source of compres-

sion. Patient 15 had an unspecified vessel decompressed during the first operation. During the second operation, patients 14 and 15 had some modification of their original decompression to achieve resolution of lateral spreads. The remaining 75% of patients had other vessels decompressed. Coagulation and division of veins compressing the seventh nerve was performed in all but one case at re-exploration (87.5%). There were no negative re-explorations.

### Late re-operation for failure (group 3)

Eighteen patients underwent late re-operation for HFS between 4 months and 12 years after the original MVD. Ten of the patients (55.5%) had suffered a recurrence of spasm following cure or near resolution, seven patients (38.8%) had never experienced relief following the first MVD, and for one patient the information was unavailable. All but one of these patients had their first MVD at another institution; patient 21 had been treated at UPMC prior to the time interval of this study. Age range was 37–74 years, with a mean age of 52.9 years. Thirteen of the patients were women (72.2%). One patient was lost to follow up. The decision to re-operate on these patients was made on the basis of clinical presentation; no diagnostic EMG was performed. Results are summarised in table 5.

After late re-operation, 11 patients were cured (64.7%). Two additional patients had a significant decrease in their degree of spasm (11.8%). A total of 76.5% of the patients were cured or significantly improved. Ten of the patients had an excellent outcome and two had a good outcome, accounting for 70.6% of the patients. Four patients (23.5%) required a third operation for refractory symptoms. Patient 33 suffered an extracranial vertebral artery injury during the second operation which necessitated endovascular sacrifice of the vertebral artery. No intracranial opening was made. As a result of the vertebral artery sacrifice, the patient developed a lateral medullary syndrome with unilateral swallowing dysfunction, hoarseness, and facial numbness. The patient was maintained on anti-platelet therapy for 3 months and

**Table 4** Outcomes of early repeat MVD for HFS in patients with persistent spasm following their first operation

ID	Age	Sex	Vessel(s) treated at first MVD	Additional vessel(s) treated at second MVD	Spasm result	Quality of life	Complications
8	47	F	AICA	Vein	Improved	Good	HBS increased from 2 to 3
9	80	F	AICA	Vein	Cured	Poor	Balance disorder, transient diplopia
10	50	F	Vertebral artery	AICA	Improved	Fair	Unquantified partial hearing loss, balance disorder
11	69	F	PICA	Two veins	Cured	Excellent	None
12	43	F	AICA	Vein, labyrinthine artery	Cured	Excellent	SAT increased from 18 to 33 dB
13	27	M	AICA	Small artery, vein	Cured	Excellent	None
14	54	F	PICA with associated arterial perforator	PICA, vein	Cured	Excellent	None
15	53	F	Unspecified artery	Unspecified artery, vein	Improved	Good	Vertebral artery sacrifice

All offending vessels are listed in the order in which they were treated. AICA, anterior inferior cerebellar artery; dB, decibels; HBS, House-Brackmann score; HFS, hemifacial spasm; MVD, microvascular decompression; PICA, posterior inferior cerebellar artery; SAT, speech awareness threshold.

**Table 5** Outcomes of late repeat MVD for HFS

ID	Age	Sex	Interim to second MVD	Findings at second MVD	Spasm result	Quality of life	Complications
16	53	F	6 years (recurrence)	Distal felt migration along PICA loop	Improved	Fair	Wound infection debrided 1 month post-operatively
17	65	M	5 years (unknown)	Distal felt migration along PICA loop	Lost to follow up	Lost to follow up	None known
18	56	F	7 months (failure)	AICA, PICA, significant arachnoidal scarring, no felt visualised	Cured	Good	HBS increased from 2 to 3
19	48	F	17 months (failure)	AICA, PICA, no felt visualised	Cured	Excellent	None
20	50	F	22 months (failure)	Felt partially migrated along PICA loop	Failed	Underwent third operation	None
21	54	F	5 months (recurrence)	Vein decompressed, felt in place on PICA	Improved	Good	Balance disorder
22	56	F	18 months (recurrence)	AICA decompression augmented, 2 veins treated	Failed	Underwent third operation	None
23	50	F	12 months (recurrence)	PICA loop with felt in place, augmented with more pledgets	Failed	Underwent third operation	None
24	57	M	4 months (failure)	Felt too distal on AICA	Cured	Excellent	None
25	48	F	10 months (recurrence)	Felt well placed on AICA and PICA. 2 veins and 1 arterial perforator divided	Cured	Excellent	Unilateral vocal cord paralysis
26	56	F	8 years (failure)	Vertebral artery and PICA compressing CN 7 (no felt visualised)	Cured	Excellent	None
27	71	M	3 years (recurrence)	Felt well placed on AICA, vein divided	Cured	Excellent	None
28	37	M	11 months (recurrence)	Felt too distal on AICA (repaired), vein divided	Cured	Excellent	None
29	39	F	6 years (failure)	Unidentified artery compressing CN 7, felt within 7–8 complex	Cured	Excellent	None
30	74	F	2 years (recurrence)	Felt worn thin on AICA, vein divided	Cured	Excellent	HBS increased from 2 to 3
31	37	F	1 year (failure)	Felt augmented on PICA	Cured	Excellent	None
32	56	M	7 years (recurrence)	Arachnoidal scar involving PICA dissected, no felt visualised	Cured	Excellent	HBS increased from 2 to 3; SAT increased from 15 to 52 dB
33	52	F	12 years (recurrence)	No intracranial opening	Failed	Underwent third operation	Extracranial vertebral artery injury requiring endovascular sacrifice and 3 months' anti-coagulation

For patients with less than a 2 year interim between operations, the time period is rounded to the nearest month; otherwise, the interval is rounded to the nearest year. Patient 16 had bilateral HFS which was more severe on the treated side. Patient 21 was the only patient originally treated at UPMC. Findings at second MVD include visualisation of old felt pledgets and persistent offending vessels. AICA, anterior inferior cerebellar artery; CN 7, facial nerve; dB, decibels; HBS, House-Brackmann score; HFS, hemifacial spasm; MVD, microvascular decompression; PICA, posterior inferior cerebellar artery. SAT, speech awareness threshold.

then underwent another retromastoid craniotomy, which is discussed in the results for group 4.

Of the 17 patients who had an intracranial opening, six patients (35%) demonstrated a misplaced or migrated pledget, seven patients required augmentation of a well placed pledget (41%), and in four patients no felt was visualised (24%). There were no negative re-explorations. Complication rates in the late re-operation group were as follows. Three patients had higher House-Brackmann facial paresis scores at follow up (17.6%). None of these scores were greater than House-Brackmann 3. One patient suffered unilateral hearing reduction on audiometry (5.9%). One patient developed a balance disorder (5.9%) and one developed unilateral vocal cord paralysis (5.9%). One patient developed a post-operative wound infection which required open debridement 1 month later (5.9%). There were no procedure related deaths. Within group 3, there was no significant correlation between age and rate of spasm resolution ( $p = 0.97$ ). Additionally, there was no correlation between sex and rate of spasm resolution ( $p = 0.24$ ). Finally, no correlation was noted between the interval to re-operation and the rate of spasm resolution ( $p = 0.59$ ).

### Third MVD for HFS (group 4)

Group 4 consisted of three patients referred from outside institutions following two failed MVDs for HFS and four

patients from group 3 of this report. The results for this rare patient group are summarised in table 6. For the sake of brevity, intraoperative findings are not included.

One patient in this group was lost to follow up. Among the other patients, two had an excellent outcome, one had a good outcome, one had a fair outcome, and two had a poor outcome. Three patients were cured (50.0%). There was no significant correlation between age or sex and rate of spasm resolution in this group. There were no operative deaths or negative re-explorations.

### Comprehensive results and complication rates

A total of 41 procedures were performed on 36 patients. Age range was 27–80 years, with a mean of 52.3 years. Twenty six of the patients were females (72.2%). Twenty three of the patients had left sided spasm (63.9%) and one patient (2.8%) treated for left sided spasm had concomitant right sided spasm. Two patients were lost to follow up. A total of 61.5% of all procedures resulted in complete resolution of spasm, and 20.5% of all procedures resulted in partial resolution of spasm. Of 34 patients, 24 were cured at follow up (70.6%), eight patients were improved (23.5%), and two patients (5.9%) were considered operative failures. A total of 94.1% of all patients had significant improvement of their HFS at a mean follow up interval of 18 months. Complication rates were as follows: unilateral partial hearing reduction 12.8%,

increased facial weakness 15.4%, balance disorder 10.3%, cerebrospinal fluid leak 2.6%, sixth nerve palsy 5.1%, unilateral vocal cord paralysis 12.8%, wound infection 2.6%, and vertebral artery sacrifice 5.1%. There were no operative deaths.

Among all subjects, using patient age as a continuous variable, no correlation was found between patient age and rate of spasm resolution ( $p = 0.97$ ). However, when patients 50 years old or younger were compared to patients older than 50, a significant correlation was discovered between young age and good outcome. At the end of the study, 11 of 12 patients who were 50 years of age or younger were cured (91.7%). In contrast, 13 of 22 patients (59.1%) more than 50 years of age were cured at follow up. This difference was statistically significant, indicating a positive correlation between younger age and cure rate after repeat MVD ( $p = 0.036$ ). In contrast, six of nine men (66.7%) demonstrated complete spasm resolution versus 18 of 25 women (72.0%). This difference was not statistically significant ( $p = 1.00$ ).

The four patient subgroups were compared to determine if there were any significant differences among them in patient outcomes, as delineated in table 7. The rate of spasm resolution was 71.4% in group 1, 62.5% in group 2, 64.7% in group 3, and 50.0% in group 4. None of these differences were statistically significant ( $p = 0.76$ ). In addition, group 1 was compared to groups 2 and 3 collectively to see if patients undergoing a second MVD after procedural abortion were more likely to be improved than patients undergoing a second MVD for failure; no significant difference was found ( $p = 0.55$ ). Moreover, group 3 was compared to groups 1 and 2 collectively to see if late re-operation was less likely to be successful than early re-operation; all 15 early re-operations resulted in cure or significant improvement at follow up (100%) versus 17 of 24 late re-operations (70.8%). This difference was statistically significant ( $p = 0.03$ ). However, there was no significant difference in overall complication rates among the four patient groups ( $p = 0.146$ ), nor was there any significant difference in complication rates between any two specific groups compared directly to each other.

## DISCUSSION

Much has been published regarding the high efficacy of MVD for HFS, with cure rates ranging anywhere from approximately 82 to 92%,<sup>4-8</sup> and excellent long term results 10 years after MVD in 84% of patients.<sup>4</sup> However, little has been published regarding repeat MVD for HFS in those patients who fail their initial operation. Unlike patients with trigeminal neuralgia who have failed after MVD, these patients receive no relief from medications, percutaneous rhizotomy, or radiosurgery. As a result, these patients have three options: live with their disease, undergo Botox therapy, or undergo repeat MVD. For those who undergo repeat MVD,

it appears that early re-explorations are more often successful than late re-explorations. In a brief correspondence from Fukushima, resolution of recurrent HFS is reported in 79 of 96 patients (82%) after early re-operation for failure.<sup>13</sup> In a more detailed analysis, Barker *et al* reported excellent results for 10 of 11 patients who had early re-operation for failure (91%), but only 61% of 49 patients who had late re-operation for failure, including 10 patients who required a third operation.<sup>4</sup> Finally, Kureshi and Wilkins reported complete relief in two of eight patients and partial relief in four of eight patients undergoing late re-exploration for HFS.<sup>14</sup> The implication of these reports is that late repeat MVD is less effective than early repeat MVD. This was confirmed in our study: all early re-operations were successful versus 70.8% of late re-operations.

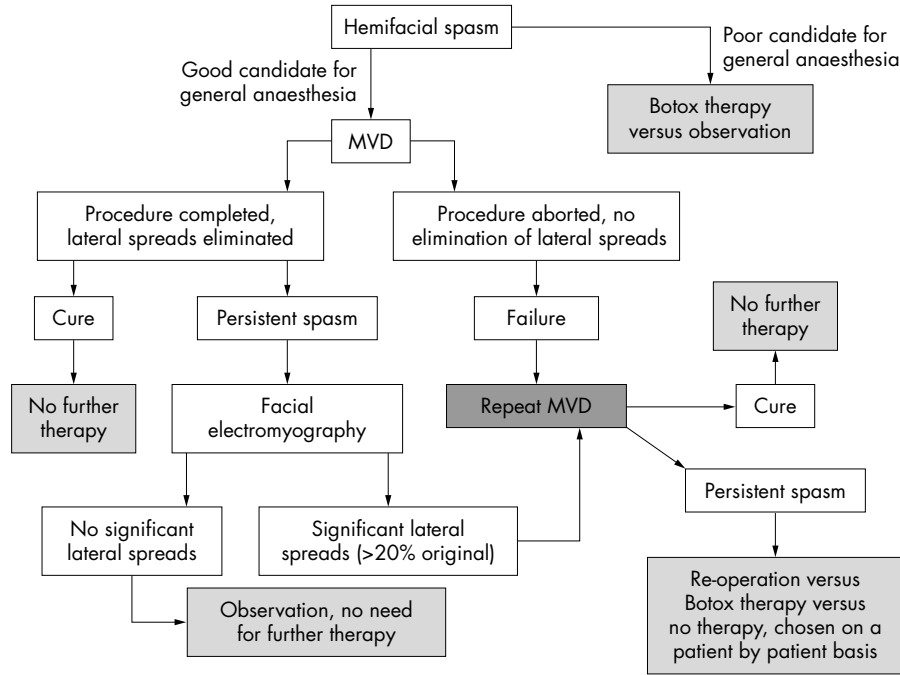
Despite the evidence that early repeat MVD is more effective than late repeat MVD, extreme caution should be taken prior to recommending re-operation for failure. Despite the high response rate among the patients in this study, over half the patients in this group suffered an operative complication. In addition, there is evidence that patients with persistent spasm after MVD improve with observation. Ishikawa *et al* reported that 90% of patients with residual post-operative spasm had resolution of their symptoms within 8 months.<sup>15</sup> In addition, Gotu *et al* described immediate cure following MVD in 76.5% of cases, and a 91.6% cure rate at 1 year.<sup>16</sup> Shin *et al* achieved an "excellent" result in 61.1% of patients 1 week after MVD, and in 82.7% of patients 6 months after MVD.<sup>17</sup> Finally, Samii *et al* noted that 59% of patients were spasm free at discharge, and 92.3% were spasm free 6 months after MVD.<sup>8</sup> Clearly, there is strong evidence that patients not immediately cured following MVD are likely to be cured within a year without additional operations. The problem with this approach is that the patient has to accept refractory symptoms in the interim. Many patients have tremendous difficulty with this concept, since eventual cure cannot be guaranteed. In the practice of the senior authors (MH, AK), those patients with significant post-operative spasm who are uncomfortable with observational management undergo facial EMG. If the post-operative EMG shows absent or markedly reduced lateral spread of responses from the facial nerve (<20% of original lateral spread), the patient is not offered a repeat MVD. If the post-operative lateral spread phenomenon is significant, we usually offer re-exploration, provided that the patient is well aware of the high risk of complications. There is no indication to immediately re-explore a patient with significant post-operative spasm and a markedly improved EMG.

An additional patient group described in this report is the patients who undergo early re-operation following procedural abortion, that is, a two stage MVD. The results for this group are favourable, including a 71.4% cure rate and a 100% rate of symptom improvement, with only one complication. The two

**Table 6** Outcomes for patients undergoing a third MVD for recurrent HFS

ID	Age	Sex	Spasm result	Quality of life	Complications
20	50	F	Lost to follow up	Lost to follow up	None known
22	57	F	Cured	Excellent	Transient sixth nerve palsy, CSF leak
23	50	F	Cured	Good	Unilateral vocal cord paralysis
33	53	F	Grade 5 facial paresis (failed)	Poor	House-Brackmann 5 facial paresis, unilateral deafness, balance disorder
34	62	F	Cured	Excellent	Unilateral hearing reduction
35	57	M	Grade 6 facial paresis (failed)	Poor	Underwent fourth MVD, developed right facial paralysis
36	49	F	Improved	Fair	None

Patient 35 underwent both a third and a fourth MVD during the interval of the study. CSF, cerebrospinal fluid; HFS, hemifacial spasm; MVD, microvascular decompression.



**Figure 1** Treatment algorithm for HFS emphasising the role of repeat MVD. Botox, botulinum toxin; MVD, microvascular decompression. Treatment endpoints are delineated in light grey shaded boxes.

stage approach provides a relatively safe alternative to persistent manipulation of the eighth nerve during a difficult first time MVD; following the second operation, none of these patients exhibited a post-operative auditory deficit. There is no role for pre-operative EMG in this group, and observation is not effective. A summary of the treatment algorithm of the authors for patients with early spasm following MVD is summarised in fig 1.

For patients who have late recurrences of HFS, re-operation is often successful, though significantly less effective than early re-operation ( $p = 0.03$ ). Nevertheless, 76.5% of such patients were cured or improved in this report. Therefore, repeat MVD is a reasonable option in these patients. These operations demonstrate a high incidence of arachnoidal adhesions along the previously manipulated cranial nerves, which may account for the decreased efficacy of the procedure compared to early repeat MVD.

Age has not been found to be a significant predictor of outcome after MVD in previous large studies of HFS.<sup>4,6</sup> However, this study indicates that age is a predictor of outcome after re-operation: among the 36 patients in this study, 91.7% of those who were 50 years of age or younger were cured at follow up versus 59.1% of those older than 50 years of age. The reason for this finding is unclear; perhaps older patients who have failed MVD are more likely to have chronic, irreversible neuropathy of the seventh nerve

than younger patients. A post mortem study of patients with a history of HFS might be of value in answering this question. Of note, male sex was found to be a predictor of positive outcomes in a prior study,<sup>4</sup> but no such correlation was found in this review.

One of the weaknesses of this report is the relatively short follow up period, an average of 18 months. However, the frequency of post-operative spasm recurrence tends to decrease over time. It has been reported that patients who do not recur within 2 years of primary MVD have <1% chance of having a recurrence at any time.<sup>18</sup> For second MVDs, the results are less promising; a previous study reported that 61% of results were excellent immediately after re-operation but only 50% of results were excellent after 5 years, including 20% of the patients who required a third operation in the interim.<sup>4</sup> Thus, the long term recurrence rates of patients who have undergone repeat MVD for HFS are probably higher than the recurrence rates of patients who have been cured by their first operation. Further research is required to determine the long term results of repeat MVD for HFS.

In conclusion, repeat MVD for HFS can be an effective procedure, although complication rates are probably higher than for first time procedures. Younger patients are significantly more likely to benefit from re-exploration. Patients who undergo early re-exploration are significantly more

**Table 7** Comparison of patient outcomes as a function of operative group

	Number of patients	% Cured	% Cured or improved spasm	% Excellent or good outcome
Group 1: early repeat MVD for procedural abortion	7	71.4%	100%	100%
Group 2: early repeat MVD for clinical failure	8	62.5%	100%	75%
Group 3: late repeat MVD for clinical failure	17	64.7%	76.5%	70.6%
Group 4: third or fourth MVD for HFS	6	50.0%	62.5%	50.0%

HFS, hemifacial spasm; MVD, microvascular decompression. Patients lost to follow up are not included.

likely to be cured or improved than patients who undergo late re-exploration. A second MVD following an aborted first MVD is safe and effective. Patients experiencing early clinical failure should usually not undergo re-exploration, especially when improvement is seen on post-operative EMG.

.....

**Authors' affiliations**

**J A Engh, M Horowitz, L Burkhart, Y-F Chang, A Kassam**, University of Pittsburgh Medical Center, Pittsburgh, PA, USA

Competing interests: none declared

**REFERENCES**

- 1 **Auger RG**, Whisnant JP. Hemifacial spasm in Rochester and Olmsted County, Minnesota, 1960 to 1984. *Arch Neurol* 1990;**47**:1233-4.
- 2 **Gardner WJ**. Concerning the mechanism of trigeminal neuralgia and hemifacial spasm. *J Neurosurg* 1962;**19**:947-58.
- 3 **Gardner WJ**, Sava GA. Hemifacial spasm—a reversible pathophysiologic state. *J Neurosurg* 1962;**19**:240-7.
- 4 **Barker FG**, Jannetta PJ, Bissonette DJ, et al. Microvascular decompression for hemifacial spasm. *J Neurosurg* 1995;**82**:201-10.
- 5 **Fukushima T**. Microvascular decompression for hemifacial spasm: results in 2870 cases. In: Carter LP, Spetzler RF, eds. *Neurovascular surgery*. New York: McGraw-Hill, 1995:1133-45.
- 6 **Huang CI**, Chen IH, Lee LS. Microvascular decompression for hemifacial spasm: analyses of operative findings and results in 310 patients. *Neurosurgery* 1991;**30**:53-6.
- 7 **Loeser JD**, Chen J. Hemifacial spasm: treatment by microsurgical facial nerve decompression. *Neurosurgery* 1983;**13**:141-5.
- 8 **Samii M**, Gunther T, Iaconetta G, et al. Microvascular decompression to treat hemifacial spasm: long-term results for a consecutive series of 143 patients. *Neurosurgery* 2002;**50**:712-8.
- 9 **Jannetta PJ**, Abbasy M, Maroon JC, et al. Etiology and definitive microsurgical treatment of hemifacial spasm: operative techniques and results in 47 patients. *J Neurosurg* 1977;**47**:321-8.
- 10 **McLaughlin MR**, Jannetta PJ, Clyde BL, et al. Microvascular decompression of cranial nerves: lessons learned after 4400 operations. *J Neurosurg* 1999;**90**:1-8.
- 11 **Moller AR**, Jannetta PJ. Monitoring facial EMG responses during microvascular decompression operations for hemifacial spasm. *J Neurosurg* 1987;**66**:681-5.
- 12 **House JW**, Brackmann DE. Facial nerve grading system. *Otolaryngol Head Neck Surg* 1985;**93**(2):146-7.
- 13 **Fukushima T**. See "Comments" section of journal. *Neurosurgery* 1996;**38**:690.
- 14 **Kureshi SA**, Wilkins RH. Posterior fossa reexploration for persistent or recurrent trigeminal neuralgia or hemifacial spasm: surgical findings and therapeutic implications. *Neurosurgery* 1998;**43**:1111-7.
- 15 **Ishikawa M**, Nakanishi T, Takamiya Y, et al. Delayed resolution of residual hemifacial spasm after microvascular decompression operations. *Neurosurgery* 2001;**49**:847-54.
- 16 **Gotu Y**, Matsushima T, Natori Y, et al. Delayed effects of the microvascular decompression on hemifacial spasm: a retrospective study of 131 consecutive operated cases. *Neural Res* 2002;**24**:296-300.
- 17 **Shin JC**, Chung UH, Kim YC, et al. Prospective study of microvascular decompression in hemifacial spasm. *Neurosurgery* 1997;**40**:730-5.
- 18 **Payner TD**, Tew JM. Recurrence of hemifacial spasm after microvascular decompression. *Neurosurgery* 1996;**38**:686-90.