

without a known history of arterial hypertension. Neuropsychological deficits were prominent in impaired semantic, visual-spatial, and episodic memory, and in deterioration in cognitive speed. Concentration and mathematical problem solving were also reduced, indicating severe cognitive impairment. Initial cranial computed tomography revealed a haemorrhage of 20 mm diameter in the left cerebellar hemisphere. Subsequent magnetic resonance imaging (MRI) with T2* gradient echo (GE) showed more than 25 small haemorrhages distributed over the entire brain. T2 weighted scans showed white matter lesions with periventricular emphasis (fig 1). Serum markers for vasculitis and coagulation indices were normal, as was the cerebrospinal fluid. An ophthalmological examination showed hypertensive changes. Ultrasound sonography of the extracranial and intracranial vessels revealed arteriosclerotic vessel walls but no stenosis. Electronmicroscopic examination of a skin biopsy showed granular osmiophilic material (GOM) in the basal lamina of small arterioles, establishing the diagnosis of CADASIL. Direct bidirectional sequencing of all exons coding for epidermal growth factor (EGF)-like repeat domains (exons 2 to 24) of *notch3* did not reveal any mutation.

After stepwise normalisation of arterial blood pressure, the patient gradually improved over the following weeks. Headaches, ataxia, and dysarthria resolved gradually, but severe neuropsychological deficits remained, rendering her unable to take care for herself. A follow up examination three months after discharge showed further amelioration of gait without any other focal neurological symptoms. The neuropsychological deficits had improved slightly, but there were still severe memory deficits. The patient was aware of these deficits and she reacted in a depressive manner. Activities of daily life were moderately impaired. Follow up MRI showed no new lesions.

Comment

The clinical course of this case with intracerebral bleeding in combination with excessive blood pressure values was consistent with hypertensive intracerebral haemorrhage. Although there was no history of known arterial hypertension, the changes of the retina supported this diagnosis. Hypertension is the most common cause of intracerebral haemorrhage, accounting for 50–70% of cases. Hypertensive bleeding into the cerebellum, however, is relatively rare (<10%). The finding of numerous cerebral microbleeds on T2*-GE MRI led to the suspicion of amyloid angiopathy, a common cause of intracerebral haemorrhage in the elderly. On the other hand, the relatively young age of the patient and the family history (mother and two sisters suffering from migraine; father died at 47 years from unknown cause) was compatible with an autosomal dominantly inherited condition, for example, CADASIL. The finding of GOM in the basal lamina of small vessels is pathognomonic of this disease and confirmed the diagnosis. Mutations in exons 2 to 24 of the *notch3* gene are found in approximately 95% of patients, but were not detected in this case.²

While transient ischaemic attacks and ischaemic strokes, along with the development of vascular dementia, are common, major intracerebral haemorrhages are not a

common feature of CADASIL. There have been sporadic reports of intracerebral haemorrhages,^{4,5} but the significance of these observations remains unclear, given the absence of intracerebral haemorrhage in large patient series.^{6,7} In a recent study with GE T2* weighted scans, microbleeds (up to 22 in a single subject) ranging from 2 to 10 mm in diameter were found in 69% of CADASIL patients examined, but no major ICH was found.⁸ Another study found microbleeds in 31% of all CADASIL patients examined, and an increased risk of intracerebral haemorrhage was predicted. The presence of microbleeds correlated with age and the use of antiplatelet drugs.⁹ CADASIL leads to degeneration of small arterioles, thus increasing the probability of vessel rupture in arterial hypertension. Compared with the patients in the studies cited above, our patient showed even more microbleeds (25), possibly indicating a greater risk of intracerebral haemorrhage in patients with CADASIL in combination with arterial hypertension. While the white matter pathology in our patient may appear relatively sparse, lesions in the external capsule and the temporal lobe typical of CADASIL were present.

We conclude that CADASIL should be considered in patients with cerebral haemorrhage, and careful blood pressure management is particularly important in CADASIL patients, as the risk of vessel rupture and subsequent intracerebral haemorrhage appears to be further increased compared with patients with arterial hypertension alone. While there is no effective treatment for CADASIL, control of arterial hypertension could at least slow the rate of deterioration in this disabling and dementing disorder.

A Ragoschke-Schumm, H Axer, O W Witte, S Isenmann

Department of Neurology, Hans-Berger-Kliniken, Friedrich-Schiller-University Jena, Jena, Germany

C Fitzek

Department of Diagnostic and Interventional Radiology, Friedrich-Schiller-University Jena

M Dichgans, N Peters

Department of Neurology, Klinikum Grosshadern, Ludwig-Maximilians-University, Munich, Germany

J Mueller-Hoecker

Department of Pathology, Ludwig-Maximilians-University

Correspondence to: Dr med Andreas Ragoschke-Schumm, Department of Neurology, Friedrich-Schiller-University Jena, Erlanger Allee 101, D-07747 Jena, Germany; andreas.ragoschke-schumm@med.uni-jena.de

doi: 10.1136/jnnp.2004.059212

Competing interests: none declared

References

- 1 Tournier-Lasserre E, Joutel A, Melki J, et al. Cerebral autosomal dominant arteriopathy with subcortical infarcts and leukoencephalopathy maps to chromosome 19q12. *Nat Genet* 1993;3:256–9.
- 2 Peters N, Opherk C, Bergmann T, et al. Spectrum of mutations in biopsy-proven CADASIL: implications for diagnostic strategies. *Arch Neurol*, (in press).
- 3 Joutel A, Corpechot C, Ducros A, et al. Notch3 mutations in CADASIL, a hereditary adult-onset disease condition causing stroke and dementia. *Nature* 1996;383:707–10.
- 4 Baudrimont M, Dubas F, Joutel A, et al. Autosomal dominant leukoencephalopathy and subcortical ischemic stroke: a clinicopathological study [abstract]. *Stroke* 1993;24:122–5.
- 5 Sourander P, Walinder J. Hereditary multi-infarct dementia: morphological and clinical studies of a new disease. *Acta Neuropathol (Berl)*, 1977;39:247–54.
- 6 Dichgans M, Mayer M, Utner I, et al. The phenotypic spectrum of CADASIL: clinical findings in 102 cases. *Ann Neurol* 1998;44:731–9.
- 7 Chabriat H, Vahedi K, Iba-Zizen MT, et al. Clinical spectrum of CADASIL: a study of 7 families: cerebral autosomal dominant arteriopathy with subcortical infarcts and leukoencephalopathy. *Lancet* 1995;346:934–9.
- 8 Dichgans M, Holtmannspötter M, Herzog J, et al. Cerebral microbleeds in CADASIL. A gradient-echo magnetic resonance imaging and autopsy study. *Stroke* 2002;33:67–71.
- 9 Lesnik Oberstein SAJ, Van den Boom R, Van Buchem MA, et al. Cerebral microbleeds in CADASIL. *Neurology* 2001;57:1066–70.

Catastrophic primary antiphospholipid syndrome presenting as status epilepticus

Antiphospholipid syndrome (APS) is defined as the occurrence of arterial or venous thrombosis or recurrent miscarriage, with raised titres of antiphospholipid antibodies, namely lupus anticoagulant (LA) or anticardiolipin antibodies (aCL). An accelerated form of APS is catastrophic antiphospholipid syndrome (CAPS) or Asherson's syndrome. Proposed diagnostic criteria for definite CAPS are: multiorgan failure, development of manifestations within 1 week, demonstration of antiphospholipid antibodies and histopathological evidence of microthrombosis (positive predictive value 99.4%).¹ Precipitants include infection, surgery, and childbirth. Patients typically develop widespread thrombotic vasculopathy with marked thrombocytopenia. Clinically apparent cerebral infarction occurs much less frequently than in uncomplicated APS but the major pathological manifestation of CAPS is cerebral microthrombosis at postmortem examination.

CASE REPORT

A 30 year old woman delivered her first child following a full term uncomplicated pregnancy. Three weeks later, she developed headache and transient hemiparesis. The following day she had an episode of speech arrest, bit her tongue, and held both arms stiffly in the air for about 1 minute. On admission to hospital, she was pyrexial and developed generalised tonic clonic seizures. There was no relevant previous medical history and she was not taking any medication. Blood tests, including erythrocyte sedimentation rate (ESR) and C reactive protein (CRP), were normal. Computed tomography scan of the brain and analysis of the cerebrospinal fluid (CSF) were normal. Gynaecological examination showed no retained products of conception. The seizures proved refractory to treatment with intravenous lorazepam. She was transferred to a specialist neurological centre that day.

On arrival she was agitated, disorientated and pyrexial (38°C). Generalised tonic clonic seizures continued. Neurological examination was normal except that all limb reflexes were pathologically brisk and plantar responses were extensor. General examination was unremarkable. Despite being given "loading" doses of phenytoin, phenobarbitone, and magnesium sulphate, the seizures continued. She was anaesthetised and intubated, and mechanical ventilation was introduced.

Treatment with high dose intravenous aciclovir for presumed viral encephalitis was commenced.

Investigations revealed a normal full blood count and film with a platelet count of $267 \times 10^9/l$. ESR and CRP were mildly raised at 46 mm/h (normal 1–20) and 28.7 mg/l (normal 0–5). Serial measurements of platelet count, ESR, and CRP did not show any significant change throughout the illness. All other blood tests including coagulation screen were normal or negative.

Magnetic resonance imaging of the brain was normal with no evidence of venous sinus thrombosis, cerebral infarction or haemorrhage. A second lumbar puncture revealed an opening pressure of 30 cm H₂O. CSF analysis showed clear colourless fluid with 4 lymphocytes/mm³, a red cell count of $<1/mm^3$, total protein of 0.36 g/l and a CSF:plasma glucose ratio of 4.4:8.9 mmol/l. CSF and serum oligoclonal bands were negative. Multiplex PCR for CSF herpes was negative.

EEG confirmed a diffuse encephalopathic process with unequivocal epileptiform activity over the frontal regions bilaterally with some periodic complexes more prominent on the left. A thrombophilia screen was performed during her illness but results were not available until after her death, and revealed the presence of lupus anticoagulant. Immunological assay for aCL was negative.

Whenever anaesthesia was reduced, seizure activity returned and her pyrexia persisted with no identifiable microbiological source. On day 7 her condition suddenly deteriorated with marked acidosis (base deficit of -14), renal failure, and haemodynamic instability. She received inotropic support and haemofiltration for presumed septic shock. She suffered a cardiac arrest <24 hours later and died despite prolonged efforts at resuscitation.

A postmortem examination revealed small vessel fibrin thrombi in the brain (fig 1). There was no evidence of large vessel cerebral thrombosis. The heart showed multifocal haemorrhages with surrounding muscle degeneration, and the lungs showed widespread small vessel thrombosis and shock lung. There was acute tubular necrosis of the kidneys, bilateral adrenal haemorrhage, and hepatic centriacinar degeneration.

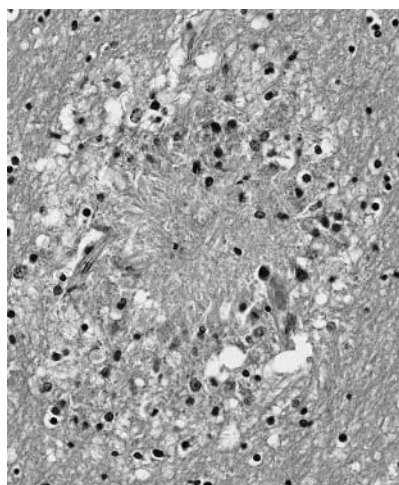


Figure 1 Cerebral white matter small vessel showing necrosis and perivascular microgliosis following occlusion by thrombus.

DISCUSSION

This patient developed a thrombotic microangiopathy (TMA) 1 month after a normal term delivery. The premortem laboratory investigations and postmortem examination revealed she was suffering from APS. The alternative postpartum TMA diagnosis of thrombotic thrombocytopenic purpura was excluded by the fibrin nature of the thrombi and the normal platelet count.

CAPS occurs in $<1\%$ of patients with APS.² However, it is vital to be aware of the diagnosis as patients rapidly develop severe multisystem failure. A review of the pathogenesis of 80 cases of CAPS noted an excess of women (79%) with an average age at onset of 37 years.³ The majority with multiorgan failure had secondary APS, mostly associated with systemic lupus erythematosus. Obstetric complications are recognised precipitants of CAPS, probably because of increases in levels of natural clotting factors. Two cases of CAPS occurring in the postpartum period have been reported, both following fetal loss.^{4,5}

Cerebral involvement has been reported in around 60% of cases of CAPS.³ However, there are no previous reports of primary antiphospholipid syndrome presenting with status epilepticus. The case was unusual in several other respects. There was no previous diagnosis of APS and no history of miscarriages or thrombotic events. The patient presented with isolated neurological symptoms with no evidence of other organ involvement until 7 days later. Daily blood tests did not raise the suspicion of thrombophilia or blood dyscrasia and, in contrast to a series of 80 patients in whom 98% had high aCL titres,³ this patient had negative aCL.

The optimal treatment for CAPS is uncertain but the rationale is to prevent ongoing thrombosis with anticoagulation and to prevent production of mediators that generate the hypercoagulable state by immunosuppression. A review of data from the international CAPS registry found that patients who received the combination of anticoagulation plus steroids plus plasma exchange or intravenous immunoglobulin had the best survival rate (63%).¹

This case emphasises that CAPS may present as an apparently isolated cerebral disorder. It is important to maintain a high degree of suspicion of antiphospholipid syndrome in critically unwell patients, particularly with known precipitating factors for CAPS such as during the postpartum period. Early treatment with anticoagulation and immunosuppression gives the best chance of improving the $>50\%$ mortality rate of the condition.

L J Coward, D M Kullmann

Institute of Neurology, University College London, Queen Square, London, WC1N 3BG, UK

L J Coward, N P Hirsch, R S Howard

Harris Neuromedical Intensive Care Unit, National Hospital for Neurology and Neurosurgery, Queen Square, London, WC1N 3BG, UK

S B Lucas

GKT/GST Dept of Pathology, St Thomas' Hospital, Lambeth Palace Road, London, SE17EH, UK

Correspondence to: Dr R S Howard, Box 33 Medical Intensive Care Unit, National Hospital for Neurology and Neurosurgery, Queen Square, London WC1N 3BG; robin.howard@talk21.com

doi: 10.1136/jnnp.2005.066746

Competing interests: none

REFERENCES

- 1 **Cervera R**, Font J, Gomez-Puerta JA, Espinosa G, Cucho M, Bucciarelli S, Ramos-Casals M, Ingelmo M, Piette JC, Shenfeld Y, Asherson RA, members of the CAPS Registry Project Group. Validation of the preliminary criteria for the classification of catastrophic antiphospholipid syndrome. *Ann Rheum Dis*. 2005; doi: 10.1136/ard.2004.025759 (Epub)..
- 2 **Asherson RA**, Espinosa G, Cervera R, et al. Catastrophic antiphospholipid syndrome. Proposed guidelines for diagnosis and treatment. *J Clin Rheumatol* 2002;**8**:157–65.
- 3 **Asherson RA**, Cervera R, Piette JC, et al. Catastrophic antiphospholipid syndrome: clues to the pathogenesis from a series of 80 patients. *Medicine (Baltimore)* 2001;**80**:355–77.
- 4 **Hochfeld M**, Druzin ML, Maia D, et al. Pregnancy complicated by primary antiphospholipid syndrome. *Obstet Gynecol* 1994;**83**:804–5.
- 5 **Kupferminc MJ**, Lee MJ, Green D, et al. Severe postpartum pulmonary, cardiac and renal syndrome associated with antiphospholipid antibodies. *Obstet Gynecol* 1994;**83**:806–7.

Use of mirror dystonia as guidance for injection of botulinum toxin in writing dysfunction

The successful application of botulinum toxin (BTX) injections in the treatment of focal hand dystonia is largely dependent on careful evaluation and selection of muscles to be injected.¹ It has been suggested that patients should be examined for abnormal postures at rest and while carrying out the affected task in question as well as other tasks (such as using a cup or a comb).² Simple techniques such as the localisation of subjective pain and fatigue accompanied by palpation of the area of discomfort can also be used.²

Mirror dystonia consists of dystonic postures and movements of the dominant hand while writing or performing other tasks with the non-dominant hand.³ We present a series of six patients who were successfully injected with BTX using mirror dystonia as an additional tool for muscle evaluation.

We carried out a retrospective review of the case records of consecutive patients with writing dysfunction (writer's cramp and writing tremor) who had been injected with BTX type A (Botox®, Allergan Pharmaceuticals, Irvine, California, USA) between November 2000 and October 2002 at our movement disorders clinic. Our study was limited to patients with writing dysfunction who displayed mirror dystonia while writing with their non-dominant hand. We specifically examined patients for mirror dystonia by asking them to write with their non-dominant hand while resting the dominant hand on the ulnar side of the forearm (unaware of our focus on the detection of mirror dystonia of the resting limb). Patients were injected under EMG guidance, using an Allergan® EMG needle. We recorded the muscles injected and the dose each muscle received. Peak effect was defined as the maximum benefit obtained from the injection. It was rated on a 0 to 3 global impression scale (0 = no effect; 1 = mild improvement; 2 = moderate improvement; 3 = marked improvement). The presence and severity of adverse events was also recorded. We also looked at the concordance between observation of the dominant limb in the action of writing and