

Diabetic ketoacidosis precipitated by thyrotoxicosis

A Bhattacharyya, P G Wiles

Summary

We report two patients with type 1 diabetes mellitus, previously well controlled with good compliance, presenting with unexplained diabetic ketoacidosis. Following initial correction of the metabolic disorder, persisting tachycardia lead to the diagnosis of thyrotoxicosis. In both cases, treatment with propranolol and carbimazole helped in the stabilization of their metabolic states. Although thyrotoxicosis is known to destabilise diabetes control, we can find no reports of it precipitating diabetic ketoacidosis.

Keywords: diabetic ketoacidosis; thyrotoxicosis

Diabetic ketoacidosis (DKA) is a major acute complication of type 1 diabetes mellitus and may have devastating consequences if not managed promptly and effectively. Effective management includes identifying and managing any precipitating factor. We report two cases of DKA precipitated by thyrotoxicosis.

Case reports

Case 1

A 30-year-old man with well-controlled type 1 diabetes mellitus for 20 years (HbA1c <8%, normal range 5.5–7.7%), and no episodes of DKA, became generally unwell for one month with worsening glycaemic control. He had no tissue complications of diabetes, smoked 25 cigarettes daily but consumed no alcohol. He denied urinary symptoms, flu, chest infection or diarrhoea. He was dehydrated and shocked with blood pressure 100/70 mmHg and heart rate 130 beats/min, but apyrexial. He had heavy glycosuria and ketonuria, capillary blood glucose 28 mmol/l, HbA1c 11.8%, arterial blood pH 7.17, bicarbonate 8 mmol/l (24–26 mmol/l). Full blood count, liver and renal function, serum electrolytes (potassium 5.1 mmol/l), chest X-ray, and electrocardiogram were all normal. Blood cultures and urine culture were sterile. DKA was diagnosed and treated conventionally with intravenous fluids and insulin, and antibiotics empirically. Improvement was slow, requiring 180 units insulin in the first 24 hours (usually 56 units/day). Tachycardia (120–130 beats/min) remained; fine tremor and grade 2/4 goitre were noted. The suspicion of thyrotoxicosis was confirmed biochemically, thyroid-stimulating hormone (TSH) was <0.06 mU/l, total thyroxine 252

nmol/l (60–156 nmol/l). Thyroid microsomal antibody was positive. Carbimazole 40 mg orally with 80 mg propranolol daily was started on the third day. He improved quickly and went home after 10 days.

Case 2

A 23-year-old woman had had well-controlled type 1 diabetes mellitus for 8 years (HbA1c <7.5% throughout and no episodes of DKA). She smoked 20 cigarettes daily but rarely consumed alcohol. Twelve months previously she presented with typical symptoms of thyrotoxicosis and worsening glycaemic control for 2 months, TSH was <0.06 mU/l, total thyroxine 196 mmol/l and thyroid microsomal antibody positive. Following carbimazole treatment, she regained glycaemic control and continued euthyroid on 10 mg daily.

She was admitted after one week of fatigue, palpitation and worsening glycaemic control despite compliance with insulin and diet. She was dehydrated, hypotensive (90/70 mmHg), tachycardic (120 beats/min), but apyrexial and denied symptoms of respiratory or urinary tract infection. She had heavy glycosuria, ketonuria, capillary blood glucose 24 mmol/l, arterial pH 7.26, bicarbonate 12 mmol/l. Full blood count, liver enzymes, renal function, serum electrolytes (potassium 4.8 mmol/l), chest X-ray and electrocardiogram were all normal. Blood and urine culture were sterile. However, TSH was suppressed with raised plasma thyroxine (192 nmol/l). She then confessed to stopping carbimazole 10 weeks previously, whilst on holiday. She was treated with intravenous fluids, insulin and oral propranolol and carbimazole (30 mg daily). She improved remarkably and went home after 5 days.

Discussion

Diabetic ketoacidosis is characterised by severe alteration in the metabolism of carbohydrate, protein and lipid, mainly as a result of lack or ineffectiveness of insulin with concomitant elevation of counter-regulatory hormones (glucagon, catecholamines and cortisol). A precipitating factor is not always found. In the absence of any other factors appearing after thorough investigation, we believe thyrotoxicosis was responsible for worsening glycaemic status and development of ketoacidosis in both our patients.

Changes in intermediary metabolism are well known in thyrotoxicosis. Plasma glucose and

Diabetes Centre,
North Manchester
General Hospital,
Crumpsall,
Manchester
M8 5RB, UK
A Bhattacharyya
P G Wiles

Correspondence to
Dr Wiles

Accepted 16 November 1998

insulin responses are usually normal in non-diabetic individuals although as many as one-third may show impaired glucose tolerance and inadequate insulin response to a glucose load.¹ In thyrotoxicosis, both glucose absorption and production from glycogen, lactate, glycerol and amino acids are increased. Deterioration of diabetic control with thyrotoxicosis could be due to enhancement of basal hepatic glucose production and its reduced suppressibility by insulin.² Other mechanisms include increased peripheral insulin resistance and insulin clearance. The insulin resistance in thyrotoxicosis may be a consequence of increased hepatic glucose output rather than a post-receptor defect because euglycaemic insulin clamp studies suggest insulin responsiveness, clearance and basal insulin delivery rate increase in thyrotoxicosis.³ Nijs⁴ demonstrated increased insulin clearance in patients with insulin-dependent diabetes mellitus and thyrotoxicosis, which becomes normal with amelioration of the thyrotoxic state. Thus, insulin secretion, hepatic glucose output, its suppressibility by insulin, peripheral tissue insulin responsiveness and insulin degradation may all be compromised in thyrotoxicosis, but probably to a different extent in different individuals.

Thyroid hormones appear to stimulate virtually all aspects of lipid metabolism, including synthesis, mobilisation and degradation. Thyroid hormone excess increases lipolysis (thereby increasing circulating free fatty acids) both by a direct effect through the ade-

Learning points

- in every case of DKA, attempts should be made to identify precipitating factor(s)
- persistent tachycardia following correction of dehydration in aseptic patients with DKA should raise the possibility of thyrotoxicosis
- thyrotoxicosis can precipitate DKA

nylate cyclase–cyclic AMP system and by sensitising adipose tissue to other lipolytic agents such as catecholamines, growth hormone, gly-cocorticoids and glucagon. Oxidation of free fatty acids is also increased and may account for some of the calorogenic action of thyroid hormones.⁵ Metabolism of ketone bodies, however, appears normal, at least in rats.⁶

We can find no reported case of DKA precipitated by thyrotoxicosis. Rolald *et al*⁷ reported one case of DKA with thyrotoxicosis (with normal serum triiodothyronine) but the precipitating factor of DKA was omission of insulin for two days. Our cases emphasise the importance of a thorough search for precipitating factors in cases of DKA once common causes such as infection and omission of insulin are excluded. Although thyrotoxicosis is apparently a very rare precipitant for DKA, persistent tachycardia in aseptic patients with DKA should raise the possibility of thyrotoxicosis, even when other features are absent.

1 Maxon HR, Kreius KW, Goldsmith RE, Knowles HC. Long term observation of glucose tolerance in thyrotoxic patients. *Arch Intern Med* 1975;135:1477–80.

2 Bratusch-Marrain PR, Konjati M, Waldhausl WK. Glucose metabolism in non-insulin dependent diabetic patients with experimental hyperthyroidism. *J Clin Endocrinol Metab* 1985;60:1063–8.

3 Barzilai N, Cohen P, Barilai D, Karnieli E. Increased insulin responsiveness and clearance in thyrotoxicosis. *Isr J Med* 1985;21:722–6.

4 Nijs HG, Radder JK, Foolich M, Krans HM. Increased insulin action and clearance in hyperthyroid newly diagnosed IDDM patient. Restoration to normal with antithyroid treatment. *Diabetes Care* 1989;12:319–24.

5 Stakkestad JA, Bremer J. The outer carnitine palmitoyl transferase and regulation of fatty acid metabolism in rat liver in different thyroid states. *Biochim Biophys Acta* 1983;750:244–52.

6 Ikeda T, Ishimura M, Terasawa H, *et al*. Uptake of ketone bodies in perfused hind quarter and kidney of starved, thyrotoxic and diabetic rats. *Proc Soc Exp Biol Med* 1993;203:55–9.

7 Rolald KM, Julius S, John AC. Thyrotoxicosis without elevated serum triiodothyroxine levels during diabetic ketoacidosis. *Arch Intern Med* 1980;140:408–10.

Lobular carcinoma-in-situ within a fibroadenoma of the breast

Ajay K Shah, Ranganath Pathak, Subhendra N Banerjee, Ashutosh Kaul, Masooma Niazi, Hanasoge T Girishkumar

Summary

We present a case of an in-situ lobular carcinoma within an otherwise benign fibroadenoma in a 45-year-old woman.

Keywords: fibroadenoma; carcinoma-in-situ

Fibroadenoma are one of the most common benign tumours of the breast. We present a case of an in-situ lobular carcinoma within an otherwise benign fibroadenoma.

Case report

A 45-year-old woman presented with a painless mass in her right breast which she had discovered one week earlier. She was pre-menopausal and had no history or any known risk factors for breast cancer. A firm, well-defined, mobile mass, 1.5 × 1 cm in diameter was found in the upper inner quadrant of the right breast. No enlarged axillary or supraclavicular lymph nodes were palpable. Mammography revealed a well-circumscribed density corresponding to the palpable mass. Fine-needle aspiration yielded benign cells. A diagnosis of fibroadenoma was made. Three months later when the mass had grown to 2.5 × 2 cm, the patient requested surgery. Local excision of the mass was therefore done. Histological examination of the mass revealed a fibroadenoma with a focus of lobular carcinoma-in-situ that was completely confined within the fibroadenoma (figures 1 and 2).² After discussing treatment options with the patient, a policy of continued surveillance was decided upon. The patient remains asymptomatic 25 months later.

Department of Surgery and Pathology, Bronx-Lebanon Hospital Center, Bronx, NY 10457, USA
 A K Shah
 R Pathak
 S N Banerjee
 A Kaul
 M Niazi
 H T Girishkumar

Correspondence to
 Mrs S King, Administrative Coordinator, Surgical Residency Training Program, Bronx-Lebanon Hospital Center, 1650 Selwyn Avenue, Suite 4A, Bronx, NY 10457, USA

Accepted 19 November 1998

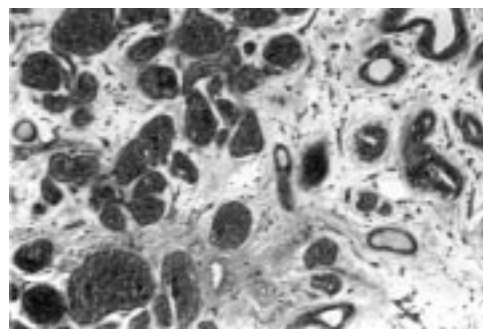


Figure 2 At higher magnification, the affected glands are distended and filled by a uniform cell population (Haematoxylin & Eosin × 100)

Discussion

Carcinoma within a breast fibroadenoma is very rare, having a reported incidence of 0.1–0.3%.^{1,2} As in our case, patients with these lesions typically are older than patients with fibroadenoma, having a mean age of 42 years. Although this is similar to the peak age reported for a lobular carcinoma-in-situ, it is considerably older than the 20–25 year average age of patients with fibroadenomas.³

Pre-operative diagnosis of these lesions is difficult because their presenting features are similar to those of benign fibroadenoma. Mammography may reveal an abnormality, but rarely indicates malignancy.³ As in our case, the diagnosis usually is a histological surprise.

Fibroadenomas have been found to contain both in-situ and invasive malignancies.^{1–4} In 66% of the reported cases of carcinomas occurring in a fibroadenoma, the malignancy has been an in-situ lesion; in 34% of cases, the cancer is invasive.³ In 65% of patients with an in-situ lesion in a fibroadenoma, the lesion is lobular carcinoma-in-situ.³ About two-thirds of the carcinomas arising within a fibroadenoma have lobular morphology; the rest are ductal or mixed ductal and lobular.^{2–4}

The biological behaviour of a carcinoma occurring in a fibroadenoma is no different from that of breast carcinoma unrelated to fibroadenoma.^{2,5} Although the treatment of invasive cancer within a fibroadenoma is similar to that of carcinoma of the breast, the treatment of in-situ cancer is less well defined. Thirty-three per cent of patients with lobular carcinoma-in-situ in a fibroadenoma develop an invasive carcinoma, intraductal or lobular,

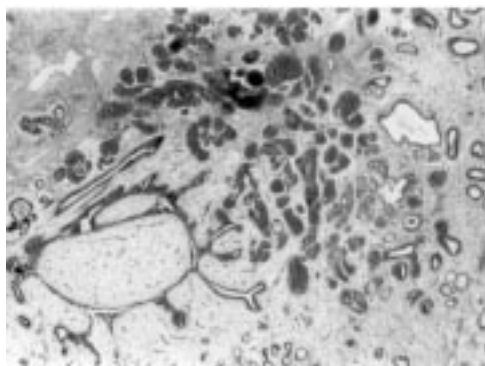


Figure 1 Lobular carcinoma-in-situ within fibroadenoma (Haematoxylin & Eosin × 40)